

# Facet Joint Syndrome: Pathophysiology, Diagnosis, and Treatment

Ruihuan Du<sup>1</sup>, Gang Xu<sup>1,2</sup>, Xujue Bai<sup>1</sup>, Zhonghai Li<sup>1,2</sup>

<sup>1</sup>Department of Orthopedics, First Affiliated Hospital of Dalian Medical University, Dalian, People's Republic of China; <sup>2</sup>Key Laboratory of Molecular Mechanism for Repair and Remodeling of Orthopedic Diseases, Dalian, People's Republic of China

Correspondence: Zhonghai Li, The Third Department of the First Affiliated Hospital of Dalian Medical University, No. 5 Longbin Road, Development Zone, Dalian, 116011, People's Republic of China, Tel +86-18098876419, Fax +86-411-83635963, Email lizhonghaispine@126.com

**Abstract:** Facet joint osteoarthritis (OA) is the most frequent form of facet joint syndrome. Medical history, referred pain patterns, physical examination, and diagnostic imaging studies (standard radiographs, magnetic resonance imaging, computed tomography and single-photon emission computed tomography) may suggest but not confirm lumbar facet joint (LFJ) syndrome as a source of low back pain (LBP). However, the diagnosis and treatment of facet joint syndrome is still controversial and needs further study. It is widely acknowledged that block with local anesthetic is perhaps the most effective method to establish a diagnosis of pain from LFJ. Particularly, there are different rates of success among different populations selected for diagnostic block with various positive criteria. Currently, in addition to conservative treatments for pain such as painkillers, functional exercises, and massage, there are many other methods, including block, denervation of the nerves that innervate the joints by radiofrequency, freezing or endoscopy, and injections. Due to the limited duration of pain relief from neurolysis of medial branch, many scholars have recently turned their targets to dorsal roots and LFJ capsules. Therefore, we reviewed the latest research progress of facet joint syndrome from diagnosis to treatment.

**Keywords:** low back pain, medial branch, block, radiofrequency, neurolysis

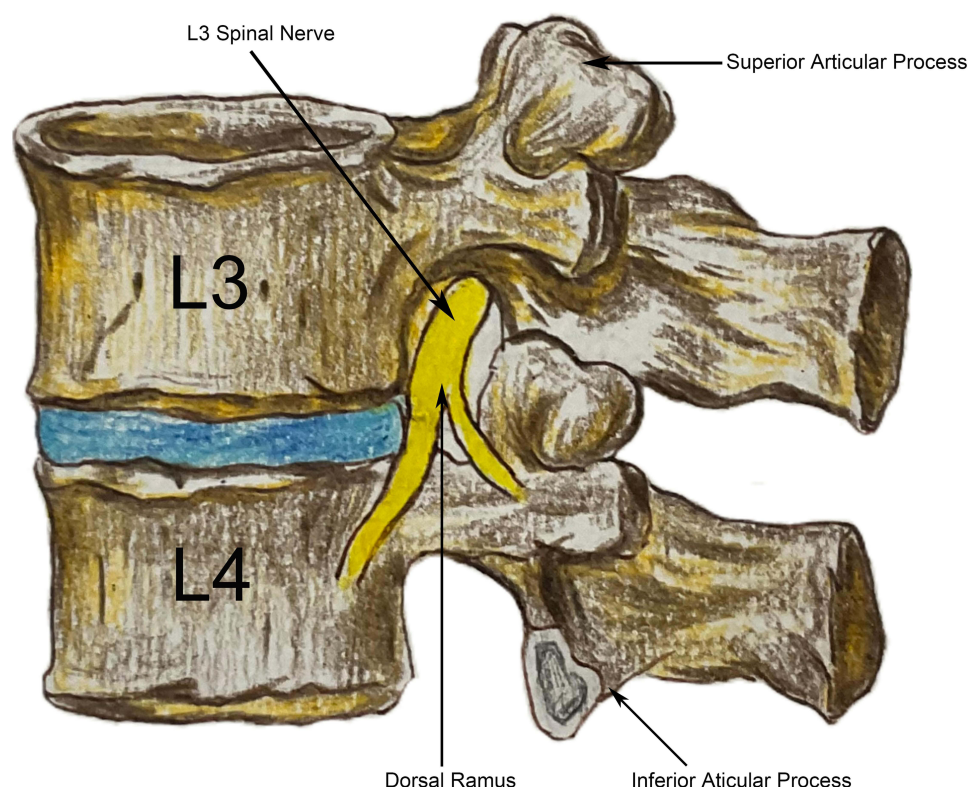
## Introduction

Low back pain (LBP) is a very common and disabling disorder. People of various ages experience LBP and their quality of life is reduced. But in many cases, LBP is overlooked and only treated when it affects mobility. Mechanical conditions are the most common causes of LBP, including the complex consisting of two lumbar facet joints (LFJ), and one intervertebral disc, all of which can cause pain and restriction of motion. Facetogenic chronic LBP, known as LFJ syndrome, accounts for 15 to 41% of patients with LBP.<sup>1</sup> Facetogenic chronic LBP in general is a leading cause of disability and a significant cause of reduced quality of life.<sup>2</sup> LFJ have an important impact on the entire lumbar vertebral structure. However, many people do not pay enough attention to facetogenic chronic LBP. There are many controversies in the diagnosis, treatment, and treatment efficacy of LFJ syndrome. In addition, there are many diagnostic errors. And with the progress of research, there are many kinds of treatment methods, but each has advantages and disadvantages. Controversy remains on which treatment option should be selected. There is no clear conclusion about when we should use conservative treatment, when to use interventional treatment, or surgical treatment, and how long these treatments can relieve pain, and which of these methods is better. So, we summarized the LFJ syndrome, hoping to provide a reliable basis for treatment of facetogenic chronic LBP.

## Anatomy of LFJ

### LFJ Structure

Each lumbar spinal segment consists of an intervertebral disc and posterior paired LFJ comprising a “three-joint complex”, where each component influences the other two, with degenerative changes in one joint affecting the biomechanics of the whole complex. LFJ are diarthrodial, from the superior and inferior articular processes of two adjacent lumbar vertebrae (Figure 1). They are synovial joints as a fibrous capsule encompasses the bone and articulating

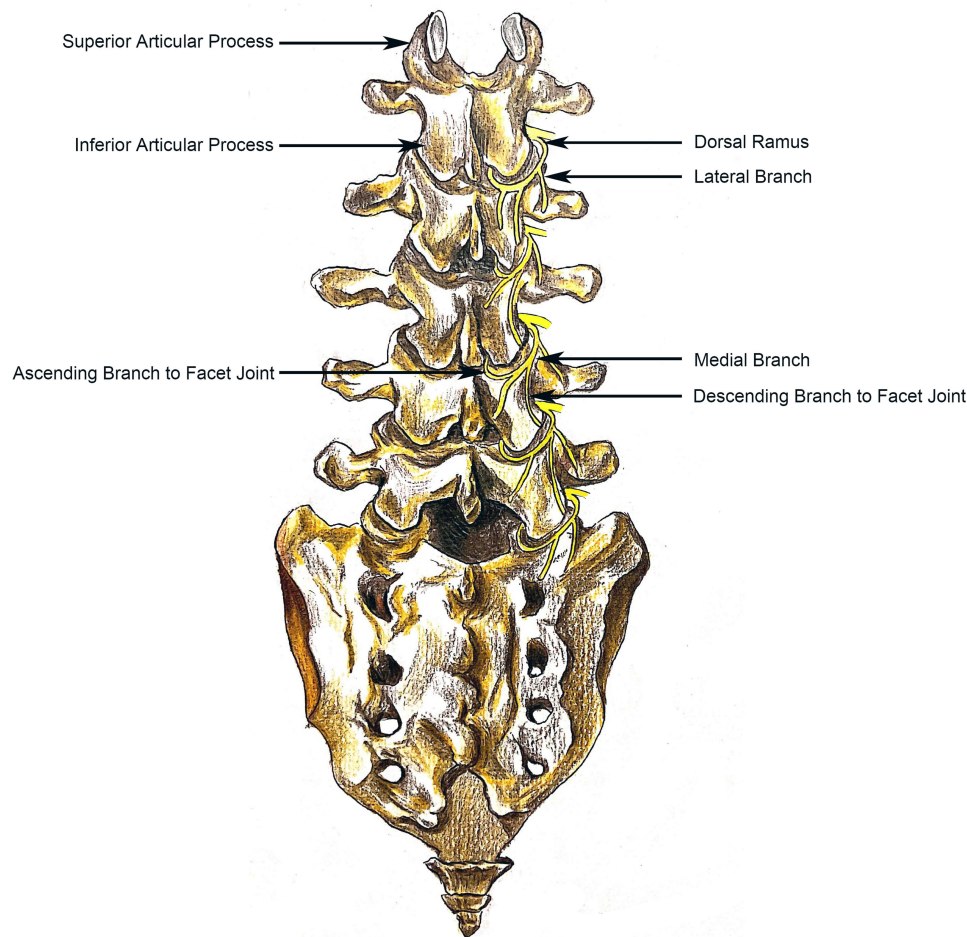


**Figure 1** Lateral views of the lumbar vertebrae and their LFJ.

cartilage and is continuous with the periosteum.<sup>3</sup> Articular capsule of the LFJ, simple like other synovial joints, is divided into two layers.<sup>4</sup> However, the inner layer of the capsule, a thin and sleeve-like synovial membrane, consists of fiber and adipose tissue.<sup>5</sup> Particularly, synovial membrane projects from the joint capsule at the superior and inferior poles of the joint and enters between the articular facets to form fibro-adipose meniscoid, which can enhance joint stability and disperse the force.<sup>5,6</sup> Besides, the joint also contains synovial fluid which is kept in place by the inner membrane.

## Innervation

The medial branch, from the dorsal ramus of the lumbar spinal nerve, passes through the transverse process and runs under the collateral ligament. At the junction of the superior articular process and the root of the transverse process, the medial branch gives off downstream nerve branches, including ascending branch and descending branch to LFJ, both of which provide sensory innervation to the LFJ. The ascending branch goes to the LFJ capsule at the same level, and the descending branch goes down to the next lower LFJ capsule. In summary, each medial branch innervates the LFJ at same level and the next lower joint, and each LFJ receives the innervation from at least 2 segments of medial branch (the adjacent same level and the upper level) (Figure 2). So, the course of the medial branch is clinically significant for the treatment of facetogenic chronic LBP. Dorsal ramus also divides into lateral branch and sometimes the intermediate branch, and although they provide iliolumbar musculature and cutaneous innervation, they may contribute to generating LBP.<sup>7</sup> Bogduk et al<sup>8</sup> studied the anatomy of L1-L5 dorsal ramus and its branches in human cadavers as follows. 1) The medial branches from the dorsal rami of L1-L4 lumbar spinal nerves assume a constant and similar course. At the L1-L4 levels, the dorsal rami divide into medial and lateral branches within the intertransverse ligaments. Each medial branch runs across the root of the adjacent superior articular process, the branches of which innervate the LFJ at same level and the next lower joint. 2) The L5 dorsal ramus, which is much longer than L1-L4 dorsal ramus, runs along a groove between the ala of the sacrum and its superior articular process. At the caudal edge of the articular process, the ramus divides into medial and lateral branches, and the medial branch supplies the L5-S1 articulation. In addition to the nerve



**Figure 2** The course of the medial branch of dorsal ramus from the lumbar spinal nerve.

distribution in the joint capsule, Giles et al<sup>9</sup> found that there are myelinated nerve fibers on the synovial folds, and these nerve endings function as nociceptors.

However, the innervation of LFJ may be more complicated than we understand. Sakuma et al<sup>10</sup> believed that the rat L5-S1 facet joint is multi-segmental, innervated from the L1 to S1 dorsal root ganglia. Kaplan et al<sup>11</sup> demonstrated that 11% of individuals who received medial branch block (MBB) would continue to experience pain from LFJ capsular distension in an experiment, which suggested aberrant innervation. Shuang et al<sup>12</sup> dissected the lumbar spine of 12 adult cadavers (24 sides) and measured the distances between the junction of the medial branch and the root of the transverse process. They found that apart from the distances of L3 and L4, there was a significant difference between the median line distances of L1-L5. Besides, the innervation of the LFJ may be a non-segmental innervation. Takahashi et al<sup>13</sup> found that the nerve fibers of L1-L5 dorsal root ganglia joins nerve, supplying the rat's L5-S1 LFJ, by retrograde nerve tracing method. Kanakarajan et al<sup>14</sup> used suprathreshold sensory stimulation to map facetogenic LBP, and they found supra-threshold stimulation of target nerves completely covered the usually painful area in 14 of 15 participants. Among them, 9 patients felt pain or paresthesia during suprathreshold stimulation, exceeding the normally painful area.

## Pathogenesis

### Degenerative Process

Anatomically, the LFJ is the only synovial joint in the spine that has a similar pathological degenerative process to appendicular joints, involving the cartilage, subchondral bone, synovium, joint capsule, and periarticular soft tissues. LFJ osteoarthritis (OA) is so common that it is the most frequent form of facetogenic LBP. Elevated subchondral bone

resorption and turnover have been found in LFJ OA.<sup>15</sup> Li et al<sup>16</sup> found that degeneration of LFJ was so common that it occurred as early as the age of 15 years. Suri et al<sup>17</sup> assessed 252 older adults (mean age 67 years) who received standardized computed tomography (CT), and found that severe LFJ OA was more common in participants with LBP than those without, which highly suggested that LFJ played a major role in LBP in the elderly population. In a study on 647 cadaveric lumbar, Eubanks et al<sup>18</sup> found that degenerative changes are universal findings with highest prevalence in L4-L5 spinal level. Kalichman et al<sup>19</sup> also found that prevalence of LFJ OA increased with age, with the highest prevalence at the L4-L5 spinal level. In a word, the degeneration of LFJ played an important role in LBP. However, they failed to find an association between LFJ OA (identified at any spinal level by multidetector CT) and LBP in a community-based study population. Ko et al<sup>20</sup> thought that lumbosacral LFJ OA was not associated with LBP at any spinal level and age except at L3-4 and L5-S1 in women.

Each component, in “three-joint complex”, influences the other two, with degenerative changes in one joint affecting the biomechanics of the whole complex. Previously, it was thought that LFJ degeneration was secondary to lumbar disc degeneration, but in recent years, it has been discovered that LFJ diseases can precede the degeneration of the intervertebral disc. Song et al<sup>21</sup> found that each individual joint degeneration influences the other 2 in the lumbar 3-joint complex, and most LFJ OA probably appeared at the segment with intervertebral disc degeneration of more than grade III by comparing date of 152 participants who underwent CT in the clinostat position. Bashkuev et al<sup>22</sup> suggested that the appearance of LFJ degeneration increasingly influences the disc loading, and that intervertebral disc and LFJ degeneration affect each other. Goda et al<sup>23</sup> reached a conclusion that degenerative changes of the LFJ in patients with lumbar spondylolysis were more severe than those without spondylolysis. In contrast, LFJ OA has also been found in some patients with non-lumbar disc degeneration, which may be affected by the biomechanics of the other department of spine.<sup>24</sup> Eubanks et al<sup>25</sup> put forward that LFJ OA often occurs before changes of disc degeneration in younger individuals.

## Inflammation

With the advancement of research on the innervation and OA of LFJ, we have noticed the inflammatory act as an important part of facetogenic LBP. In addition to the joint capsule, there are also nerve fibers in the synovium.<sup>9</sup> It means that inflammation or trauma to the LFJ causes pain through the synovial nerve fibers, without necessarily causing joint capsule lesions. Kim et al<sup>26</sup> suggested that increased inflammatory and angiogenic features play an important role in the progression of facetogenic LBP and serve as a link between joint degeneration and neurological stimulation of afferent pain fibers, by comparing LFJ from patients undergoing spinal reconstruction surgery and cadaveric donors with no history of LBP. Igarashi et al<sup>27</sup> proved that there were high levels of inflammatory cytokines, such as IL-1 beta, TNF-alpha, and IL-6, in LFJ tissue in lumbar disc herniation and lumbar spinal canal stenosis, which suggested that inflammatory cytokines in degenerated LFJ may have some relation to the cause of pain in degenerative lumbar disorders. Besides, Sakuma et al<sup>10</sup> discovered the exaltation of TNF receptor expression in dorsal root ganglia neurons innervating the LFJ following LFJ injury in rats using a retrograde nerve transport method followed by immunohistochemistry.

## LFJ Orientation and Symmetry

The normal LFJ allow for flexion and extension of the spine while limiting rotation and preventing the vertebrae from slipping over each other. LFJ parameters, including facet joint orientation (FJO) and facet joint tropism (FJT), related to biomechanics of the corresponding segment, have a significant influence on the degenerative process of LFJ and intervertebral discs, which play a significant role in LBP (Table 1). FJT increased at lower lumbar levels.<sup>28</sup> The axial and sagittal orientation of facet joints in the lower lumbar vertebra, especially L4/5, was negatively correlated with age.<sup>29</sup> There have been many studies that demonstrated a close association between FJO and FJT with lumbar degeneration.<sup>28,30,31</sup> There were other studies<sup>32–35</sup> that have confirmed that the directionality and symmetry of the LFJ are closely related to LFJ degeneration and degenerative lumbar spondylolisthesis. Linov et al<sup>36</sup> confirmed a significant association between sagittal orientation and OA of the LFJ at level L4-L5 in a cross-sectional study. Yang et al<sup>37</sup> demonstrated that FJT may play an important role in the pathogenesis of lumbar degenerative diseases, using finite



**Table 1** Studies Evaluating the Influence of LFJ Parameters on the Degenerative Process of LFJ

Authors, Years	Patients and Methods	Results and Conclusions
Ke et al, <sup>38</sup> 2021	A biomechanical modeling was performed to evaluating influences of vertebral FJO and FJT.	The combination of FJO and FJT has an important impact on the corresponding disc and LFJ, but FJT played a more significant role.
Li et al, <sup>39</sup> 2020	Retrospective study comparing FJO and FJT between recurrent lumbar disc herniation group and the non-recurrent group.	With the decrease of FJO, the risk of recurrent lumbar disc herniation increases continuously. The incidence of recurrent lumbar disc herniation increases with the increase of FJT.
Ekşi et al, <sup>28</sup> 2020	Retrospective review evaluating association between FJO and FJT with lumbar intervertebral disc degeneration in 123 pts.	Intervertebral disc degeneration at L4-L5 was associated with more coronal aligned L1-L2 and misaligned L5-S1.
Yang et al, <sup>37</sup> 2020	Retrospective study explored the association between facet joint parameters and LBP in 542 pts who were divided into LBP group and non-LBP group.	FJT may play a more important role in the pathogenesis of LBP.
Degulmadi et al, <sup>30</sup> 2019	Retrospective study on the relationship of both FJT and the sagittally aligned facet joint with lumbar disc herniation and degenerative spondylolisthesis in 250 consecutive pts who underwent surgery for lumbar disc herniation and degenerative spondylolisthesis.	Both sagittally aligned facet and FJT play a significant role in lumbar disc herniation degenerative spondylolisthesis.
Wang et al, <sup>32</sup> 2019	A case-control study comparing facet angles in 42 adults with degenerative lumbar spondylolisthesis and 50 controls.	FJO is associated with degenerative lumbar spondylolisthesis at L4-5.
Jiang et al, <sup>43</sup> 2019	Retrospective study involving result of FJO, grade of intervertebral disk degeneration, vertebral translation, and angular variation in 450 pts.	Disk degeneration was associated with FJO only at L5-S1.
Guo et al, <sup>33</sup> 2019	A case-control study compared 90 pts with L4-L5 degenerative lumbar spondylolisthesis and 90 with L4-L5 lumbar disc herniation or spinal stenosis to evaluate the facet joint angle.	Facet joint angle greater than 60.19° is more likely to occur in lumbar spondylolisthesis.
Fukushima et al <sup>35</sup> 2019	A case-control study assessed 25 pts who had degenerative spondylolisthesis at L3 and compared them to 50 other age- and gender-matched lumbar spinal stenosis pts without any degenerative spondylolisthesis.	L3-L4 LFJ in the L3 degenerative spondylolisthesis group were significantly more sagittally oriented than in the control group.
Schleich et al, <sup>31</sup> 2016	Orientation of facet tropism and sagittal facet joint were assessed for L3/4, L4/5 and L5/S1 in 25 young, healthy volunteers without any history of lumbar spine pathologies.	FJT and sagittal orientation of the facet joint represent risk factors for the development of early biochemical alterations of lumbar intervertebral discs.
Samartzis et al, <sup>44</sup> 2016	Retrospective study that included 349 pts with single-level degenerative spondylolisthesis; 82 had no L4-L5 degenerative spondylolisthesis and 267 had L4-L5 degenerative spondylolisthesis. Facet joint angulations and tropism between groups were assessed.	FJT played a significant role in degenerative spondylolisthesis.
Chen et al <sup>41</sup> 2014	Retrospective study assessed facet joint angulation in 60 pts with L4 degenerative spondylolisthesis and 56 healthy volunteers.	Facet joint angulation may be risk factor of the development of degenerative spondylolisthesis.
Linov et al, <sup>36</sup> 2013	Cross-sectional study evaluating facet joint OA, FJT and FJO, and the association between facet joint OA.	A significant association between sagittal orientation and OA of the LFJ at level L4-L5 was confirmed.
Kim et al, <sup>45</sup> 2013	Models, established by finite element analysis, was applied to analyze facet contact forces.	FJT could make the corresponding segment more vulnerable to external moments or anterior shear force.
Mahato et al <sup>40</sup> 2011	Both the superior articulating facets in the normal as well as in transition associated sacra were measured for (1) height, (2) width, (3) surface area, and (4) angulation of the articular surfaces with reference to the midsagittal plane.	L5-S1 transitions possess altered facet morphology. These alterations are possibly related to LBP situations.
Kalichman et al, <sup>34</sup> 2009	A cross-sectional study, using multiple logistic regression models examined the association between lumbar spine FJO, FJT, and LFJ OA and degenerative spondylolisthesis.	A significant association between sagittal orientation and osteoarthritis of the LFJ at L4-L5 and degenerative spondylolisthesis was found.

(Continued)

**Table I** (Continued).

Authors, Years	Patients and Methods	Results and Conclusions
Dai et al, <sup>46</sup> 2001	A case-control study assessed the orientation and tropism of the LFJ at L4-L5 level in 53 pts with degenerative L4-L5 spondylolisthesis and 53 age- and sex-matched normal control subjects.	Morphological abnormalities of the LFJ are a predisposing factor in the development of degenerative spondylolisthesis.
Ko et al, <sup>47</sup> 1997	A case-control study compared facet angle between 33 pts without disc herniation and 27 pts with disc herniation.	This study did not show that FJT plays a significant role in disc herniation.
Cinotti et al, <sup>48</sup> 1997	A case-control study compared facet angle between 27 pts without spondylolisthesis and 27 pts with degenerative spondylolisthesis.	Abnormal sagittal orientation of LFJ plays major roles among possible factors predisposing to degenerative spondylolisthesis.

**Abbreviations:** FJO, facet joint orientation; FJT, facet joint tropism; LFJ, lumbar facet joint; pts, patients; LBP, low back pain; OA, osteoarthritis.

element analysis and contour maps visualization. Ke et al<sup>38</sup> found that the combination of FJO and FJT played an important role in the development of lumbar degeneration, including disc and LFJ. More importantly, FJO and FJT do not affect the disc at only the corresponding level; the lumbar spine should be evaluated as a whole.<sup>28</sup> Li et al<sup>39</sup> came to similar conclusions that LFJ parameters significantly influence the biomechanics of the corresponding segment, which may be related to LFJ degeneration. Mahato et al<sup>40</sup> observed asymmetry in LFJ, which is possibly related to LBP. Chen et al<sup>41</sup> reported that LFJ angulation may be a risk factor of the development of degenerative spondylolisthesis. Weinberg et al<sup>42</sup> showed that a more sagittal orientation of the LFJ and increased tropism were risk factors for LFJ arthritis by measuring a total of 576 cadaveric lumbar spines.

## Clinical Presentation

The clinical diagnosis of facetogenic LBP is still debated. Facetogenic LBP is also known as non-specific LBP, the clinical presentation of which is lumbosacral pain with or without sciatica. Synovial and subchondral cysts can extend posteriorly to the LFJ but also anteriorly in the spinal cord or neuroforamen. So, in space-occupying spinal lesions, such as osteophytes or synovial cysts, radiating pain may reach the foot, mimicking sciatic pain. In 1911, Goldthwaite first described that LFJ is a source of LBP. In 1927, Putti proposed that the degeneration and inflammation of the LFJ may cause sciatica through nerve irritation. In 1933, Ghormhley named a symptom originating from the LFJ “facet syndrome”, which was lumbosacral pain with or without sciatica. Facet syndrome included local pain and pseudo radicular radiation with variability of the distribution of referral patterns of pain.<sup>19</sup> Facetogenic LBP may be referred distally into the lower limb, thereby mimicking sciatica, and “pseudo-radicular” lumbar pain typically radiates unilateral or bilaterally to the buttock and the trochanteric region (from the L4 and L5 levels), the groin and the thighs (from L2-L5), ending above the knee, without neurological deficits.<sup>49</sup> Campos et al<sup>50</sup> thought that patients with facetogenic LBP may have symptoms such as lumbar paraspinal palpation with increased pain; and increased pain during one or more of the following: 1) extension (more than flexion)/rotation, 2) extension/side flexion, and 3) extension/rotation. Gómez et al<sup>51</sup> emphasized its characteristics as follows, 1) improvement with rest, 2) absence of root pattern, may have pseudoradicular pattern, however, the pain is more lumbar than pain in the leg and 3) clinical signs. But this kind of pain does not resemble sciatica as it spreads through dorsal side of the leg and reaches the feet and toes.<sup>52</sup> Laslett et al<sup>53</sup> found that a cluster of clinical signs (“Revel’s criteria”), consisting of 7 clinical signs, may be valuable in predicting the results of an initial screening ZJ block, with a sensitivity of 92% and a specificity of 80%. Although, nowadays pain produced by the LFJ has a few diagnostic scales and even though many scientists have tried to summarize the clinical features of facetogenic LBP,<sup>51,53</sup> they cannot make a diagnosis based on it. Due to clinical heterogeneity, Maas et al<sup>54</sup> disapproved the diagnostic accuracy of patient history and/or physical examination to identify facetogenic LBP, which depended on a diagnostic block.

And hypertrophy of the facet, which is advanced deterioration of the LFJ, can mimic lumbar disc hernias with sciatica-like pain.<sup>52</sup> Besides, spinal synovial cysts may cause symptoms if they cause canal stenosis or nerve compression

at the level of the lateral recess.<sup>55</sup> In Parlier-Cuau et al's research,<sup>56</sup> 30 patients had nerve root pain due to an LFJ synovial cyst. Hohenberger et al<sup>57</sup> pointed out that 95.1% of patients with spinal synovial cysts had experienced local and radicular pain as the predominant symptom, and 47.5% patients appeared to have preoperative sensory and motor deficits. Particularly, Odonkor et al<sup>58</sup> pointed out, inciting events are common in patients diagnosed with facetogenic LBP and may be associated with a positive outcome. Hughey et al<sup>59</sup> showed an algorithm that compares, including starting "Oswestry disability index", pain scores, and both gender and smoking history, favorably to that of diagnostic MBB in terms of prediction accuracy, which may improve selecting patients with LFJ syndrome.

## Imaging Findings

### X-Ray Imaging: Radiographs and CT

Radiography is the first-line modality to assess spinal alignment and to detect gross pathology of the LFJ. However, radiography is rather insensitive and does not provide detailed information on the LFJ. Radiographs show degenerative changes of LFJ in patients with or without pain. CT is the leading imaging modality for diagnosis of LFJ diseases. Compared with radiography, CT provides excellent bone detail and is highly sensitive in detecting calcifications. In particular, standard radiographs can show pathological changes especially in severe disease, while CT is the preferred method for imaging LFJ OA. LFJ OA, not simply of LFJ cartilage, is a failure of the whole joint,<sup>60</sup> including joint space narrowing, sclerosis, subchondral sclerosis and erosions, cartilage thinning, calcification of the joint capsule, hypertrophy of articular processes and of the ligamentum flavum causing impingement of the foramina and osteophytes.<sup>49</sup> Secondary signs include vacuum joint phenomenon (intra-articular gas), joint effusion and associated degenerative spondylolisthesis. Pathria et al<sup>61</sup> indicated that oblique radiography, compared with other positions, was most accurate in distinguishing the presence from the absence of disease; but it is insensitive compared with CT. LFJ OA is so common that many authors thought more than 90% of people suffered from it during their lives.<sup>17–20</sup> However, Kalichman et al<sup>19</sup> failed to find an association between LFJ OA, identified by multidetector CT, at any spinal level and LBP in a community-based study population. Similarly, Suri et al<sup>17</sup> found that severe LFJ OA also appeared in participants without LBP.

### Magnetic Resonance Imaging (MRI)

Magnetic resonance imaging (MRI) is a noninvasive and nonionizing modality that is excellent in evaluating soft tissues and edema-like signal intensity in bone and soft tissue, and that in the evaluation of LFJ degeneration is debated. Imaging markers which may be associated with symptomatic LFJ OA include subchondral BMLs on MRI.<sup>60</sup> Enokida et al<sup>62</sup> investigated T2 value of 60 volunteers, aged from 20s to 70s (10 subjects in each decade; 5 male, 5 female), with or without lumbar intervertebral disc, and they suggested that T2 value of LFJ was significantly increased as age rose, and that T2 mapping could evaluate the degenerative changes of LFJ related to aging. Hansen et al<sup>63</sup> confirmed that standing positional MRI has acceptable reproducibility on evaluation of the degenerative lumbar spine. D'Aprile et al<sup>64</sup> put forward that the implementation of MRI T2-weighted sequences with Fat Saturation and contrast enhanced T1-weighted sequences with Fat Saturation in addition to the standard MRI protocol could allow a better identification of degenerative-inflammatory changes. Weishaupt et al<sup>65</sup> thought that CT and MRI are equally useful regarding LFJ OA, and that CT is not necessary, with the presence of an MRI examination, for the assessment of LFJ degeneration. CT, which shows the high contrast between bone structures and the surrounding soft tissues, is better able to demonstrate the degenerative changes of the LFJ, while MRI clearly presents advantages of better assessing the immediate consequences of LFJ degeneration, such as surrounding neural structure impingement. However, degenerative changes of LFJ are even found on MRI in patients without lumbar spinal pain.<sup>62</sup> Equally, Little et al<sup>66</sup> showed that articular cartilage degeneration with subchondral sclerosis and articular cartilage degeneration with osteophyte formation can be observed on MRI in LFJ OA, and they found that the articular cartilage subscale had acceptable intra-observer and inter-observer reliability, while scales for subchondral bone sclerosis and osteophyte formation did not achieve acceptable reliability. In patients with facetogenic LBP, Chang et al<sup>67</sup> did not recommend the routine use of contrast-enhanced MRI, which has no significant effect compared with MRI. Sato et al<sup>68</sup> recommended using MRI for selection of laterality in the capsular thickness for LBP patients to discriminate candidates for future severe degenerative changes of the articular cartilage in the lumbar spine.

## Single-Photon Emission Computed Tomography (SPECT)

Single-photon emission computed tomography (SPECT) is very sensitive to OA and inflammation, however, this test may lack specificity, and many patients with positive imaging have no clinical pain characteristics. Therefore, SPECT is not a routine examination. A study showed that the discovery of inflammation is more useful than MRI when doctors make diagnosis of LFJ OA.<sup>49</sup> They also talked about the fact that increased osteoblastic activity along with synovial changes secondary to inflammation or hyperemia associated with bone remodeling can be discovered through radio-nuclide bone scintigraphy, using <sup>99m</sup>Tc labeled bisphosphonates.<sup>49</sup> However, SPECT/CT has the ability to precisely localize scintigraphically active LFJ, the metabolism of which is active, but lacks specificity for inflammation, and may provide significant improvement in the diagnosis and treatment of patients with LBP.<sup>69</sup> Holder et al<sup>70</sup> also agreed that LFJ with abnormal increased uptake were seen on SPECT, and that there was high sensitivity, but somewhat lower specificity. In a randomized, double-blind placebo-controlled trial, 29 patients, with a pain clinician, received a series of three fluoroscopically guided MBB, with result showing that 24% (7 of 29) of patients had a positive response and 76% (22 of 29) had a negative response after blocks, while among individuals who had positive blocks, 4 of 7 also had positive SPECT scans, and 17 of 22 had negative SPECT scans.<sup>71</sup> So, the authors concluded that SPECT should not be recommended as a first-line diagnostic tool prior to MBB.<sup>71</sup>

## Management

In recent years, the treatment of facet joint syndrome has been greatly developed. In general, the principle of management involves anti-inflammatory and analgesic treatment of OA of LFJ. Intra-articular injections of drugs can reduce pain by anti-inflammatory or analgesic routes, or by facilitating facet joint repair. In addition, the nerves that supply the facet joints can be anesthetized or destroyed to block the transmission of pain. Different treatment methods have their advantages and disadvantages, and their efficacy is controversial. The characteristics of different treatment methods are summarized as shown in Table 2.

## MBB

Blocking is the use of anesthetics to block the transmission of pain signals from the nerves, but it will not fundamentally solve the pathology of the small joints themselves. LFJ is innervated by at least 2 level medial branch (the same level and the upper level). So, the MBB should be performed on at least two level nerves using the local anesthetic (lidocaine and/or bupivacaine) with or without steroids.<sup>72</sup> In addition to MBB,<sup>73</sup> there are two ways to achieve the aim of blocking,

**Table 2** Characteristics of Different Treatments for Facet Joint Syndrome

Types of Treatment	Characteristics
MBB	Anesthetize the nerves innervating LFJ by local anesthetics to achieve short-term pain relief. It is often used in the diagnosis of facet joint syndrome.
Steroid Injections	Intra-articular injections are usually a mixture of steroid and local anesthetics. Pain relief is shorter than with radiofrequency ablation.
Medial Branch Radiofrequency Ablation	Medial branch radiofrequency ablation is a mainstream minimally invasive procedure for facet joint syndrome. However, some patients may have variation of medial branch anatomy, and a few patients have no pain relief after radiofrequency ablation.
Capsule Radiofrequency	Percutaneous radiofrequency to the LFJ capsule is easier than medial branch radiofrequency, and capsule radiofrequency leads to an extended period of pain relief compared to the medial branch radiofrequency.
Cryoneurolysis	Using a gas-cooled cryoprobe to freeze the nerve with an ice-cold temperature.
Chemical Neurolysis	Nerve damage with chemicals. Nerve regeneration is potentially dangerous to the formation of neuroma. It is rarely used.
Dorsal Root Neurotomy	Dorsal root neurotomy maintained significant relief of pain, longer than medial branch denervation. But there are few related studies.
Endoscopic Neurotomy	Endoscopic neurotomy can directly observe the nerve. Avoids the inconvenience of anatomical variation. Endoscopic neurotomy is more effective than percutaneous radiofrequency.

**Abbreviations:** MBB, medial branch block; LFJ, lumbar facet joint.



including pericapsular facet injections<sup>74</sup> and intra-articular injections.<sup>75</sup> Sadeghian et al<sup>76</sup> pointed out that nerve and LFJ blocks can both be effectively performed with effects lasting for a mean of 2 months. Kershen et al<sup>77</sup> demonstrated that intra-articular and periarticular with anesthetic/steroid mixture both provide statistically significant pain relief immediately and 1 week post injection. However, Cohen et al<sup>78</sup> suggested that MBB appears to have little long-term utility compared with facet injections, both treatment methods using bupivacaine and corticosteroid. Recently, a review showed evidence that MBB achieved higher effect than intra-articular blocks in short- and long-term relief.<sup>79</sup> Though these drugs are known to be short-acting, Liu et al<sup>80</sup> found 35% (51 of 146) patients experience protracted relief of LBP after diagnostic MBB alone. And they proved the relation between protracted relief and patients with LBP symptom duration of < 6 months and unilateral back pain symptoms.<sup>80</sup> The length of time for pain relief after block is related to drug metering, but the reason for protracted relief of LBP after block is unknown.

In theory, MBB, compared to intra-articular injection, has a direct link to medial branch neurotomy. It is widely acknowledged that MBB with local anesthetic is perhaps the most accepted and reliable tool to establish a diagnosis of facetogenic LBP.<sup>81</sup> It seems that MBB is technically easier than intra-articular injection to perform using anatomic landmarks, as intra-articular blocks show less anatomical accuracy.<sup>49</sup> Birkenmaier et al<sup>74</sup> showed that MBB is better than pericapsular blocks in diagnosing patients with facetogenic LBP. However, studies have shown that MBB also has false-positive rate.<sup>73</sup> Feigl et al<sup>82</sup> did research on cadavers and reported that electrodes were placed accurately parallel to nerve and beside it under fluoroscopy guidance, while under CT guidance, electrodes often failed to reach the nerve, and there is more distance from nerve even if parallel to it. Kennedy et al<sup>83</sup> found that during MBB, unintentional vascular uptake may contribute to occasional false-negative responses. In conclusion, there are multiple reasons for false-positive blocks including the placebo effect, spread of injectate to other pain-generating structures, excessive local anesthetic administration, and the injudicious use of sedation.<sup>84</sup>

### The Degree of Relief That Should Occur

There are different standard degrees of relief after blocks. Changes in the degree of relief obtained, and controlling for duration, all affect whether a reported positive response represents a true positive. A specific criterion, for an optimal selection, is ideally complete relief of pain following an MBB after an anatomically accurate block under guidance.<sup>49</sup> MacVicar et al<sup>85</sup> used a selection paradigm, 100% pain relief with dual comparative MBB, to select patients for lumbar medial branch denervation. In research directed by Conger et al, a positive set of blocks was defined as 80% reduction in pain.<sup>86</sup> There are also authors who defined positive diagnostic block as 50% or more relief of participants after intra-articular and MBB.<sup>78</sup>

Finlayson et al<sup>87</sup> suggested that a positive block, as well as the number of positive blocks required before proceeding with radiofrequency ablation is debated. On one hand, a more conservative approach such as choosing an 80% threshold and following two diagnostic MBB would maximize the probability of a successful radiofrequency ablation,<sup>88</sup> but at the cost of excluding a significant number of patients who may have benefited from the procedure.<sup>87</sup> On the other hand, using less stringent methods, employing a minimum threshold of 50% pain reduction following a single diagnostic MBB to select patients, which is associated with a high false-positive rate ranging from 25% to 45%, would allow a greater number of individuals to access treatment.<sup>89</sup>

### The Number of Blocks and the Levels Which Should Be Targeted

A definitive diagnosis of pain from LFJ may require blocks at two separate sessions, but it is debated. The patients selected by two time blocks are more accurate, while the patients who have only been confirmed by one time block will be more comprehensive. The MBB should be performed, at least, on two level nerves, because of 2 level medial branch (the same level and the upper level), supplying one LFJ. There is a high false-positive rate (30–45%) when performing a single-level block only.<sup>49</sup> Cohen et al<sup>90</sup> found that patients who were selected by comparative blocks done with lidocaine and bupivacaine, have the best radiofrequency denervation success rates, compared with the other two groups of patients selected by clinical findings or a single diagnostic block. Abd-Elseyed et al<sup>91</sup> thought that one prognostic block can be sufficient to move forward with radiofrequency ablation. Because in their research, major patients also receive a successful second prognostic block, who receive a successful first prognostic block.<sup>91</sup> Diagnostic MBB, to

block a single joint, should be performed with a minimum of two level medial branches, including the same level and the level above.<sup>8,12,92</sup> Particularly, Schneider et al<sup>92</sup> recently reached a result in a systematic review, ie, treatment effect varied by selection criteria and procedural technique as followings: 1) more patients selected via dual MBB, compared with single MBB, achieved at least 50% pain relief treated via perpendicular technique; 2) two diagnostic MBB with 100% pain relief is the most accurate patient selection.

### Injected Drugs and Volume

The anatomy, face validity, target specificity and injection position of lumbar MBB using local anesthetics, have been established in cadavers in normal and volunteers.<sup>11,92–95</sup> Local anesthetics (lidocaine and/or bupivacaine) act by blocking neuronal transmission and, to some extent, may also have an anti-inflammatory effect.<sup>96</sup> One approach, intra-articular infiltration of corticoid and anesthetics, may benefit only those with an inflammatory process.<sup>97</sup> Dreyfuss et al<sup>93</sup> pointed out that contrast medium must be used before the injection of local anesthetics to guard against false-negative responses due to intravenous uptake. With this method, we may be able to avoid errors when making a diagnosis.

The dose of local anesthetics may influence the false positive of diagnostic MBB. Schneider et al<sup>92</sup> pointed out that the target nerve will be captured with a small volume of local anesthetic (0.3–0.5 mL), but any other structure, that is potentially an alternative source of pain, will not be anesthetized. Wahezi et al<sup>95</sup> found that 0.25 mL total volume for a lumbar MBB may provide greater specificity for radiofrequency ablation planning, because a 0.5-mL injectate volume during lumbar MBB, on six cadavers, would affect the distal branches of the adjacent medial branches, compared with 0.25-mL injectate volume. Moreover, Kennedy et al<sup>83</sup> found that DS uncovered inadvertent vascular uptake in 27 of the 344 blocks, except for 34 other patients discovered by live fluoroscopy.

## Intra-Articular LFJ Injection

### Steroid Injections

OA is mainly the degeneration of cartilage, which is painful with the stimulation of inflammation. The steroid plays an important role in the treatment of OA, which is used for LFJ injection mainly presenting analgesic and/or anti-inflammatory properties (Table 3). Besides, multilevel LFJ injections may be more effective in terms of pain relief. Steroids play a dual role in the management of pain in OA, as they interrupt nociceptive inputs at central and peripheral level and mitigate the pro-inflammatory environment present in affected joints.<sup>96</sup> Multilevel LFJ injections are clinically more effective than only two-level lower level lumbar injections.<sup>98</sup> Kwak et al<sup>99</sup> demonstrated a significant decrease in facetogenic LBP after corticosteroid injection, regardless of the severity of LFJ OA. Sae-Jung et al<sup>100</sup> found that, with 80 mg injection of methylprednisolone into each symptomatic LFJ, the best treatment effect was found at four weeks after which pain level gradually increased. Ribeiro et al<sup>101</sup> showed that steroids, through intra-articular or intramuscular injection, were effective for patients with facetogenic LBP.

Although intra-articular injection of steroids has a certain effect, a large proportion of patients cannot obtain long-term relief. Kennedy et al<sup>102</sup> conducted a double-blind, prospective, randomized and placebo-controlled trial. In their experiment, 28 patients with confirmed facetogenic LBP via dual comparative MBB, were randomized to receive either intra-articular corticosteroid or saline. The result showed that there is no statistically significant difference in the need for radiofrequency neurotomy between saline and corticosteroid groups. One year later, they did a similar trial with more subjects. Through this trial, Kennedy et al<sup>103</sup> demonstrated that intra-articular corticosteroids were not effective in reducing the need for radiofrequency ablation of the medial branches in those with dual MBB-confirmed facetogenic LBP. They did it as follows: 56 patients who had  $\geq 80\%$  pain relief during an initial screening MBB joined a randomized, double blind, placebo-controlled study, and then they received a second confirmatory MBB and concurrent intra-articular injection of either corticosteroid or saline per randomization.<sup>103</sup> Snidvongs et al<sup>104</sup> have not drawn any conclusions about the clinical effectiveness of intra-articular LFJ injections in the management of facetogenic LBP, this may be due to the small number of participants.

**Table 3** Clinical Trials Evaluating Intra-Articular Steroid Injections for Lumbar Facetogenic LBP

Author, Year	Number and Type of Patients	Follow-Up Period	Results
Kennedy et al, <sup>103</sup> 2019	56 consecutive pts who had $\geq 80\%$ pain relief during an initial screening MBB were randomly divided into two groups. After second MBB, 29 of 56 received intra-articular corticosteroid, of whom 24 also had a positive MBB. 27 of 56 received intra-articular injection of saline into the LFJ during the confirmatory MBB, of whom 22 also had a positive MBB.	1 year.	There was no statistically significant difference in the need for a radiofrequency ablation between the groups (16/24 steroid, 67%) vs (15/22 saline, 68%).
Kennedy et al, <sup>102</sup> 2018	28 pts with facetogenic chronic LBP confirmed by MBB were randomly divided into two groups. Two groups received either intra-articular corticosteroid or saline.	1 year.	No statistically significant difference in the need for radiofrequency neurotomy between the groups.
Lakemeier et al, <sup>105</sup> 2016	56 pts with LBP were randomly assigned to 29 pts who received intra-articular steroid infiltrations, and 27 pts who underwent radiofrequency denervation.	6 months.	24 of 29 pts in the steroid injection group and 26 of 27 pts in the denervation group completed the 6-month follow-up. There were no significant differences between the 2 groups for pain relief and functional improvement.
Ribeiro et al, <sup>101</sup> 2013	60 pts with LFJ syndrome randomly received triamcinolone hex acetate intra-articular injection, or triamcinolone acetate intramuscular injection.	24 weeks.	Both treatments were effective, with a slight superiority of the intra-articular injection of steroids over intramuscular injection.
Pneumatics et al, <sup>106</sup> 2006	47 pts with LBP were scheduled and randomized in a 2:1 ratio to undergo intra-articular local anesthetic and steroid injections.	6 months.	At 1 month, 13 of 15 pts had improvement in pain score of greater than 1 standard deviation whereas improvement occurred in only two of 16 pts in group A2 and five of 16 pts in group B.
Fuchs et al, <sup>107</sup> 2005	60 pts were included in this randomized, controlled, blind-observer clinical study and randomly assigned to two groups to receive 10 mg sodium hyaluronate or 10 mg glucocorticoids per facet joint.	6 months.	Pts who received sodium hyaluronate injections experienced a 40% decrease in pain scores vs a 56% reduction in those pts who received steroid.
Carette et al, <sup>108</sup> 1991	95 pts with LBP who reported immediate relief of their pain after injections of local anesthetic into the LFJ. They were randomly assigned to receive, under fluoroscopic guidance, injections of either methylprednisolone acetate (20 mg; n = 49) or isotonic saline (n = 48) in the same LFJ.	6 months.	After one month, 42% of the pts who received methylprednisolone and 33% of those who received placebo reported marked or very marked improvement. At the six-month evaluation, the pts treated with methylprednisolone reported more improvement, less pain and less physical disability.

**Abbreviations:** MBB, medial branch block; pts, patients; LFJ, lumbar facet joint; LBP, low back pain.

## Other Injections

Hyaluronic acid plays the role of lubricating the articular surface and relieves pain by reducing the friction of the articular surface. However, the intrinsic anatomy of the LFJ may limit the efficacy of hyaluronic acid: this compound is injected within the capsule, but in a restricted anatomical space it is difficult to establish how much actually reaches the bony interface between the two articular processes. Annaswamy et al<sup>109</sup> compared hyaluronate with triamcinolone (steroid) injections in treating facetogenic LBP, and they found that hyaluronate showed significant short- and long-term functional improvement and short-term pain improvement; triamcinolone showed only significant short-term functional benefit.

Platelet-rich plasma intra-articular injection benefits LFJ syndrome, and may have anti-inflammatory and cartilage protection effects. Urits et al<sup>110</sup> suggested that platelet-rich plasma injection may be of benefit in the treatment of facetogenic LBP, as platelet-rich plasma may provide pain relief and chondroprotection. Wu et al<sup>111</sup> pointed out that autologous platelet-rich plasma and local anesthetic/corticosteroid in intra-articular injection were both effective and safe for the treatment of LFJ syndrome, however, subjective satisfaction and objective success rate of local anesthetic/corticosteroid decreased while for platelet-rich plasma, they increased over time. Sanapati et al<sup>112</sup> reported a systematic review and they found that the qualitative evidence for LFJ injections with platelet-rich plasma is Level IV (on a scale of Level I through V), based on one high-quality randomized controlled trial and 2 moderate-quality observational studies.

Recently, some new substances, including bone marrow mesenchymal stem exosomes, membrane-umbilical cord and sarapin, have been found to play an important role in treating LFJ syndrome. Li et al<sup>113</sup> proved that bone marrow

mesenchymal stem exosomes could relieve pain of LFJ OA via abrogation of aberrant CGRP-positive nerve and abnormal H-type vessel formation in the subchondral bone of LFJ. Gołębiowski et al<sup>114</sup> supported the safety and effectiveness of amniotic membrane/umbilical cord particulate for treatment of lumbar. Bennett et al<sup>115</sup> came to the same conclusion as Gołębiowski, and they pointed out that it is still effective 6 months after receiving intra-articular injection of 50 mg particulate amniotic membrane-umbilical cord suspended in preservative-free saline. Sarapin is a plant-derived suspension obtained by Sarraceniaceae pupurin, and acts on pain pathways by obliterating the potential of C-fibers; however, the molecule responsible for this mechanism has not yet been identified.<sup>96</sup>

## Medial Branch Radiofrequency Ablation

Medial branch radiofrequency ablation is a method like MBB. In theory, both of them can serve the purpose of pain relief. However, pain relief may be longer with medial branch radiofrequency ablation, by coagulating the nerve with a heat lesion. Radiofrequency techniques include thermal, pulsed, and cooled radiofrequency. Perolat et al<sup>49</sup> pointed out that radiofrequency energy is delivered to the nerves or tissues and denatures the nerve for pain relief by increasing the temperature around the radiofrequency needle tip. They also found that nerve cells would undergo necrosis when exposed to temperature > 45°C.<sup>49</sup> Most scholars believe that a temperature of 90 degrees or higher has a good nerve ablation effect.<sup>84,88,116,117</sup> Compared with thermal radiofrequency, pulsed radiofrequency is a temperature-independent therapeutic method with lower temperature<sup>118</sup> and pulsed radiofrequency has some of the following characteristics: 1) electrode tip temperature not exceeding 42°C; 2) duration of 240 s.<sup>119</sup> Thermal radiofrequency may be the most effective way for medial branch ablation. However, radiofrequency causes diffuse tissue damage due to destructive temperatures, while pulsed radiofrequency prevents the unwanted adverse effect of irreversible tissue damage, with a maximum temperature reaching 42°C.<sup>120</sup> Nerve destructive temperatures could be avoided using pulsed radiofrequency, which allows time for the heat to dissipate, minimizing the risk of thermal tissue injury.<sup>121</sup> Particularly, cooled radiofrequency uses internally cooled radiofrequency probes to increase lesion size.<sup>122,123</sup> So, cooled radiofrequency, theoretically, can increase the chance of complete denervation.

Radiofrequency neurotomy, with light intravenous sedation or/and local anesthesia, is a minimally invasive procedure.<sup>120</sup> Radiofrequency electrodes, under imaging guidance, need to be placed properly, parallel to the medial branch nerves, to increase chance of nerve capture within the radius of the thermal lesion.<sup>120</sup> Because thermal radiofrequency lesion develops horizontally along the shaft of the needle, with very little tissue destruction occurring distal to the tip.<sup>84</sup> It is worth noting that pulsed radiofrequency probes need to be perpendicular to the nerves at the angle between the superior articular process and the transverse one for L1–4 levels, while for the L5 level, pulsed radiofrequency probes are directly toward the junction of the superior articular process and the top border of the sacral crest.<sup>119</sup> Besides, to avoid missing the targeted nerves, optimizing sensory threshold may serve as an additional buffer.<sup>124</sup> Lesion size is also dependent on probe size, electrode temperature, and duration of the current.<sup>121</sup> Paulsen et al<sup>88</sup> reported that denervation was performed at 90 °C for 60 seconds at the distal and the proximal lateral part of the LFJ capsule. In particular, some scholars have even proposed that longer denervation times for up to 180 seconds may be needed to ensure that the nerves are denervated.<sup>116,117</sup> Furthermore, multiple electrodes may be needed to increase the chance of successive nerves denervation.<sup>125</sup> In conclusion, the longer the time as well as the higher the temperature, the radiofrequency lesion size will be bigger, and there could be a difference in radiofrequency lesion size due to needle size and placement of radiofrequency denervation.<sup>89,116,126</sup>

Radiofrequency neurolysis is a traditional interventional management, which is effective in pain relief for patients with LFJ syndrome (Table 4). The use of pulsed radiofrequency appears to be less effective in the long term, and cannot replace thermal lumbar medial branch neurotomy. Particularly, cooled radiofrequency was the most effective. Måwe et al<sup>127</sup> demonstrated, in an observational study, the obvious short-term and long-term improvement of the radiofrequency ablation treated patients. Chen et al<sup>128</sup> demonstrated the effective application of radiofrequency neurotomy on facetogenic chronic LBP via a meta-analysis. Janapala et al<sup>129</sup> reported a systematic review and meta-analysis including 12 randomized controlled trials, and they found that the short-term and long-term efficacy of lumbar radiofrequency neurotomy were debated. Al-Najjim et al<sup>130</sup> conducted a systematic review including 4 studies with randomized controlled trials, which compared the outcome of radiofrequency denervation compared to sham or placebo

**Table 4** Outcomes for Randomized, Controlled Studies Assessing Medial Branch Radiofrequency Denervation for Facetogenic LBP

Author, Year	Number and Interventions	Follow-Up Period	Results
Song et al, <sup>137</sup> 2019	40 pts with facetogenic LBP were randomly assigned to two groups. The control group (20 pts) had X-ray-assisted radiofrequency neurotomy and the experimental group (20 pts) underwent endoscopic neurotomy of the lumbar medial branch.	2 years.	The pts who received radiofrequency neurotomy demonstrated successful treatment results at 3 weeks, 6 months, and 1 year after surgery. The endoscopic neurotomy group demonstrated more prolonged successful treatment outcomes compared with the radiofrequency neurotomy group at 2 years.
Moussa et al, <sup>138</sup> 2016	120 pts with facetogenic LBP were randomly divided into three equal groups. Group 1 was submitted to percutaneous radiofrequency coagulation of the facet joint capsule, group 2 underwent percutaneous denervation of the medial dorsal branch and group 3 did not receive radiofrequency lesioning. All pts had local injection of a mixture of local anesthetic and steroid.	3 years.	The control group lost improvement by 1-year follow-up. At 2 years' follow-up, the joint capsule denervation group maintained significant improvement whereas the medial branch denervation group lost its significant effect.
Van et al, <sup>139</sup> 2016	60 pts with facetogenic LBP after a diagnostic facet joint test block were randomly assigned to two groups. In the treatment group, a percutaneous radiofrequency heat lesion was applied to the medial branch of the primary dorsal ramus. In the sham group, the same procedure was undertaken without the radiofrequency lesion.	3 months.	There was no statistically significant difference with the passage of time between the groups.
Van et al, <sup>140</sup> 2005	81 pts with facetogenic LBP, verified by diagnostic block. Pts were randomly assigned to two groups. One had radiofrequency facet joint denervation. The other underwent the same procedure without radiofrequency.	1 years.	No differences between radiofrequency facet joint denervation (n=40; success 27.5%) and sham (n=41; success 29.3%).
Leclaire et al, <sup>141</sup> 2001	70 pts with facetogenic LBP were assigned randomly to receive percutaneous radiofrequency articular facet denervation under fluoroscopic guidance or the same procedure without effective denervation.	12 weeks.	At 4 weeks, the Roland-Morris score had improved by a mean of 8.4% in the neurotomy group and 2.2% in the placebo group, showing a treatment effect of 6.2%. At 12 weeks, neither functional disability nor the pain level showed any treatment effect.
Van et al, <sup>142</sup> 1999	31 pts with facetogenic LBP were randomly assigned to one of two treatment groups. Treatment group (15 pts) received radiofrequency lesion of the dorsal ramus of the segmental nerve roots. Pts in the control group (n = 16) underwent the same procedure but without use of a radiofrequency current.	12 months.	There were 10 successful pts in the radiofrequency group (n = 15) and 6 in the sham group (n = 16). 3, 6, and 12 months after treatment, there were significantly more successful pts in the radiofrequency group compared with the sham group.

**Abbreviations:** pts, patients; LBP, low back pain.

procedures for the treatment of facetogenic LBP. And they found that there is conflicting evidence at an intermediate 3–6-month stage, however; one study demonstrated statistical significance of radiofrequency denervation at 3 months. In a retrospective cohort analysis, Starr et al<sup>131</sup> found that 33.1% of 44,936 patients received secondary radiofrequency ablations. Particularly, Juch et al<sup>132</sup> did not support the use of radiofrequency denervation to treat facetogenic chronic LBP. Because in 3 randomized clinical trials of participants with LBP originating in the LFJ and other body structures, radiofrequency denervation combined with a standardized exercise program resulted in either no improvement or no clinically important improvement in chronic LBP compared with a standardized exercise program alone. Contreras et al<sup>133</sup> reported a systematic review, and they found 3 randomized clinical trials comprising 103 patients, all of which showed greater pain control and better functionality with cooled radiofrequency compared with pulsed radiofrequency. Rotstein et al<sup>119</sup> also proved the efficiency of pulsed radiofrequency which is effective for a short period after medial branch denaturing. But they also found that effectivity of pulsed radiofrequency is weaker than conventional radiofrequency.<sup>119</sup> Çetin et al<sup>134</sup> compared the effect between thermal radiofrequency and pulsed radiofrequency for facetogenic LBP, and they found that patients who received thermal radiofrequency were more satisfied with the treatment after 2 years follow-up. Although the success rate of cooled radiofrequency was higher than thermal radiofrequency, this difference was not statistically significant.<sup>120</sup> This result may be limited by short follow-up time. However, in a systematic review and meta-analysis conducted by Shih et al, they found that cooled radiofrequency



was the most effective, followed by thermal radiofrequency and then pulsed radiofrequency as the least, respectively, for the follow-up visit at 6 months.<sup>118</sup> Besides, clinical randomized and controlled studies demonstrated that treating patients with pulsed dose radiofrequency prior to continuous thermal radiofrequency ablation can result in patients having less post-procedural pain during the first 24 hours and also reduce analgesic requirements.<sup>135</sup> To demonstrate the effectiveness of thermal radiofrequency ablation combined with corticosteroid injection for facetogenic LBP, Le et al<sup>136</sup> conducted a prospective observational study including 82 patients and the results showed that during 24 months' follow-up, only 5 patients required another radiofrequency neurotomy procedure (6.1%).

## Capsule Radiofrequency

Intra-articular radiofrequency and modified radiofrequency, sparing the multifidus, may both be more effective, compared with traditional dorsal medial branch ablation RF. Russo et al<sup>143</sup> described a modified radiofrequency ablation technique that targets the capsule and spares the multifidus. And they found that effectiveness and safety of modified radiofrequency were similar to traditional medial branch radiofrequency ablation. Moussa et al<sup>138</sup> discovered that pulsed radiofrequency coagulation of the capsule instead of the medial branch directly has a more lasting effect: 1) at 2 years' follow-up, the joint capsule denervation group maintained significant development whereas the medial branch denervation group lost its significant effect. 2) By the end of follow-up period, only joint capsule denervation group maintained significant improvement. Jacobson et al<sup>144</sup> also agree with this point of view, and they demonstrated that the facet capsule radiofrequency can provide long-term and more extensive pain relief, to coagulate lumbar facet cysts to prevent recurrence, by combining it with traditional lumbar radiofrequency ablation. Chang et al<sup>145</sup> pointed out intra-articular pulsed radiofrequency may be a potential treatment for facetogenic LBP. In their experiment, 10 of 20 patients still maintained 50% or greater pain relief at 6 months after intra-articular pulsed radiofrequency, and special attention is that radiologist scored with intra-articular arthrograms were very good. Similarly, Do et al<sup>146</sup> also supported intra-articular pulsed radiofrequency and they found relief of pain persisted for at least 6 months after the procedure for patients who suffered from facetogenic LBP.

## Cryoneurolysis

Cryoneurolysis, using a gas-cooled cryoprobe to freeze the nerve with an ice-cold temperature, replicates the same relief by medial branch radiofrequency. This technology is based on a rapid decompression of gas (either N<sub>2</sub>O or CO<sub>2</sub>) at the extremity of the probe.<sup>49</sup> Commonly, the tip of the cryoprobe reaches a temperature of -50°C.<sup>74,147</sup> It is worth mentioning that cryoneurolysis has the following advantages: reversibility, repeatability, and decreased incidence of complications such as neuroma formation or neuritis.<sup>148</sup> Compared with radiofrequency, the lesions created by cryoprobes are much bigger. So, the cryoprobes do not need to be completely parallel to the target nerves like radio frequency probes. But it is well recognized that probes should be parallel rather than perpendicular to the target nerve.<sup>149</sup> After accurate positioning of the probe under imaging guidance, sensory stimulation and motor stimulation were performed to confirm the proximity to the nerve.<sup>147</sup> And then, Kastler et al<sup>150</sup> draw conclusions via in vitro experiments that ultrasound is a useful tool to monitor the formation of ice ball during a cryoneurolysis freezing cycle. When using a cryoprobe, the neutral electrode is exclusively required for neurostimulation, which allows for continued stimulation during denervation to confirm cessation of pain or multifidus activity.<sup>147</sup> For the purpose mentioned previously, the patient must be conscious to respond to sensory and motor stimulation. If necessary, the smallest dose of sedation should also be used. Besides, all nerve fibers stop conducting at -20°C, so ice-cold temperatures created by cryoneurolysis procedure induce a conduction block. The patient's pain is tolerable. Kastler et al<sup>151</sup> suggested that, after cryoneurolysis, the mean improvement of patients with facetogenic LBP was maintained at 77% at 12 months.

## Chemical Neurolysis

Chemical neurolysis is the use of chemical reagents to ablate the nerves, thereby achieving the purpose of pain relief. Chemical reagents usually include alcohol and phenol. However, due to the many side effects of this method, it is rarely used nowadays compared with radiofrequency ablation. The use of chemical neurolysis techniques can be an effective method to accomplish a larger, thorough lesioning when compared to a radiofrequency neurolysis needle.<sup>152</sup> The

concentration of alcohol used for chemical neurolysis commonly ranges from 30% to 100% solution.<sup>153</sup> And the efficacy of 3% phenol in saline is comparable to that of 40% alcohol. Furthermore, alcohol injection usually causes temporary severe pain, while aqueous phenol does not cause violent pain. Afifi et al<sup>154</sup> conducted a prospective cohort study including 95 patients to compare the effect of neurolysis by radiofrequency ablation to chemical ablation. Among patients, 30 patients underwent radiofrequency ablation, 30 patients were treated with ethyl alcohol 95%, and 35 individuals were treated with glycerol 20%. They found that, 12 months after intervention, the effect of radiofrequency ablation is significantly better than that of the other two methods.<sup>154</sup> Chemical neurolysis also has shortcomings. These chemical agents may lead to sequelae in the axonal membrane called deafferentation pain sequelae, which may be associated with painful paresthesia.<sup>49</sup> Nerve regeneration is potentially dangerous to the formation of neuroma.<sup>155</sup>

## Dorsal Root Neurotomy

Dorsal root is the source of the medial branch nerve. Dorsal root neurotomy is better than denervation of the medial branch. More importantly, at 2 years follow-up, the patients who received pulsed radiofrequency treatment of the dorsal root ganglia group maintained significant relief of pain, while the medial branch denervation lost its significant effect.<sup>156</sup> Meloncelli et al<sup>7</sup> conducted a study including 50 patients who were previously treated with percutaneous radiofrequency or at their first intervention, and all patients maintained pain relief two years after the treatment. Unlike MBB, L5 dorsal ramus block may provide long-term pain relief of facetogenic pain. Retrospective and case-control research involved a total of 326 patients selected by controlled comparative local anesthetic blocks.<sup>157</sup> 99 patients received L5 dorsal ramus block and 227 received lumbar radiofrequency neurotomy. Significant pain relief was recorded in 100%, 99%, and 79% of the patients in the LFJ nerve block group, whereas, it was 100%, 74%, and 65% in the radiofrequency neurotomy group at 3, 6, and 12 months follow-up.<sup>157</sup> So L5 dorsal ramus block could be a potentially more effective treatment.

## Endoscopic Neurotomy

Endoscopic neurotomy is an open surgery, in which the nerve can be directly observed. Compared with interventional surgery, endoscopic neurotomy is more effective than traditional percutaneous radiofrequency. Besides, at least two nerves need to be cut for one LFJ like the interventional surgery. To evaluate the long-term outcomes for patients who underwent endoscopic neurotomy versus radiofrequency for facetogenic LBP, Du et al<sup>158</sup> enrolled 55 patients undergoing facetogenic LBP with a positive diagnostic MBB. In this study, 19 patients underwent endoscopic neurotomy, and 36 underwent radiofrequency. The results showed that both endoscopic neurotomy and radiofrequency were effective in reducing pain at 6 months and 12 months compared with baseline. Endoscopic neurotomy had significantly better efficacy than radiofrequency at 6 and 12 months. The study even showed pain relief lasting up to 20 months after radiofrequency therapy.<sup>158</sup> However, patients were not randomized to different groups in this study, and that may have made a difference. Xue et al<sup>159</sup> reported that percutaneous radiofrequency ablation under endoscopic guidance had longer pain relief than traditional medial branch radiofrequency, with more accurate denervation. Song et al<sup>137</sup> demonstrated that endoscopic neurotomy of lumbar medial branch was better than radiofrequency neurotomy, and endoscopic neurotomy has longer effectiveness. Woiciechowsky et al<sup>160</sup> found that 28 patients who received endoscopic LFJ denervation of three facets on the left and right side with one incision on each side, achieved average pain relief lasting 7.8 months. Woiciechowsky et al<sup>161</sup> further compared the efficacy of endoscopic neurotomy and percutaneous radiofrequency in a randomized controlled study including 40 patients. And the results showed that both endoscopic neurotomy and percutaneous radiofrequency reduced pain and improved functionality. However, the effects decreased or disappeared in the percutaneous radiofrequency group after 12 months, whereas there was still a strong significant improvement in the endoscopic neurotomy group.<sup>161</sup> Walter et al<sup>162</sup> also affirmed the effect of medial branch denervation via endoscope, which has the advantage of visualization of the LFJ and the target nerve. In an article written by Walter et al,<sup>163</sup> they mentioned enduring facetogenic LBP relief only in patients treated endoscopically, whereas patients undergoing radiofrequency ablation reported a return of pain some months after intervention. Meloncelli et al<sup>7</sup> found that the patients undergoing endoscopic neurotomy, got significant analgesia for at least 2 years.

## Conclusion

The most frequent form of facet pathology is LFJ OA. Medical history, referred pain patterns, physical examination, and diagnostic imaging studies (standard radiographs, MRI, CT and SPECT) may suggest but not confirm LFJ syndrome as a source of LBP. However, patients who have been diagnosed with OA on imaging findings, may not have the clinical pain. Nevertheless, imaging examination is still necessary. Other pathologies (vertebral body fractures, malignancies, and so on) have to be excluded radiologically. In addition, other information of patients is also helpful for diagnosis. There are still some difficulties in its treatment, mainly because there is still some controversy about the diagnosis of facetogenic LBP. In particular, the positive criteria for diagnostic block are different, and the prognosis of patients after treatment is different. Recently, in addition to conservative treatments for pain, many minimally invasive procedures, such as radiofrequency ablation, cryoneurolysis and chemical neurolysis, struggle to provide permanent pain relief, which may be related to nerve regeneration. In this case, endoscopic neurotomy may have certain advantages, by which nerves can also be directly observed. Particularly, due to the limited time of pain relief from neurolysis of medial branch, dorsal roots and LFJ capsules have recently received attention. We look forward to further research on the diagnosis of facetogenic LBP in the future, based on the patient's medical history, clinical manifestations, imaging manifestations and diagnostic block. We also look forward to obtaining treatments that allow patients to obtain permanent pain relief.

## Abbreviations

OA, osteoarthritis; LFJ, lumbar facet joint; LBP, low back pain.

## Acknowledgments

The authors are grateful for the support of the open project of the Science and Technology Innovation Foundation of Dalian (2022JJ12SN045), the Natural Science Foundation of Liaoning Province (2022-MS-322) and the open project of Key Laboratory for Micro/Nano Technology and System of Liaoning Province, Dalian University of Technology (20210101).

## Author Contributions

All authors made a significant contribution to the work reported, whether that is in the conception, study design, execution, acquisition of data, analysis and interpretation, or in all these areas; took part in drafting, revising or critically reviewing the article; gave final approval of the version to be published; have agreed on the journal to which the article has been submitted; and agree to be accountable for all aspects of the work. ZL (lizhonghaispine@126.com) takes responsibility for the integrity of the work as a whole, from inception to finished article.

## Funding

This study was supported by the Science and Technology Innovation Foundation of Dalian (2022JJ12SN045), the Natural Science Foundation of Liaoning Province (2022-MS-322) and the open project of Key Laboratory for Micro/Nano Technology and System of Liaoning Province, Dalian University of Technology (20210101). The funders had no role in the study design, data collection and analysis, decision to publish, or preparation of the manuscript.

## Disclosure

The authors report no conflicts of interest in this work.

## References

1. Curtis L, Shah N, Padalia D. Facet Joint Disease. In: *StatPearls*. Treasure Island (FL): StatPearls Publishing Copyright © 2021, StatPearls Publishing LLC; 2021.
2. Wang JC, Le DT, Alem N. Facet joint injection. *Eur Spine J*. 2021;2021:1–13.
3. Kapetanakis S, Gkantsinikoudis N. Anatomy of lumbar facet joint: a comprehensive review. *Folia Morphologica*. 2020;80(4):799–805.
4. Yamashita T, Minaki Y, Ozaktay AC, Cavanaugh JM, King AI. A morphological study of the fibrous capsule of the human lumbar facet joint. *Spine*. 1996;21(5):538–543. doi:10.1097/00007632-199603010-00002
5. Engel R, Bogduk N. The menisci of the lumbar zygapophysial joints. *J Anat*. 1982;135(Pt 4):795–809.

6. Bogduk N, Engel R. The menisci of the lumbar zygapophyseal joints. A review of their anatomy and clinical significance. *Spine*. 1984;9(5):454–460. doi:10.1097/00007632-198407000-00006
7. Meloncelli S, Germani G, Urti I, et al. Endoscopic radiofrequency facet joint treatment in patients with low back pain: technique and long-term results. A prospective cohort study. *Ther Adv Musculoskelet Dis*. 2020;12:1759720x20958979.
8. Bogduk N, Long DM. The anatomy of the so-called “articular nerves” and their relationship to facet denervation in the treatment of low-back pain. *J Neurosurg*. 1979;51(2):172–177. doi:10.3171/jns.1979.51.2.0172
9. Giles LG, Taylor JR. Human zygapophyseal joint capsule and synovial fold innervation. *Br J Rheumatol*. 1987;26(2):93–98. doi:10.1093/rheumatology/26.2.93
10. Sakuma Y, Ohtori S, Miyagi M, et al. Up-regulation of p55 TNF alpha-receptor in dorsal root ganglia neurons following lumbar facet joint injury in rats. *Eur Spine J*. 2007;16(8):1273–1278. doi:10.1007/s00586-007-0365-3
11. Kaplan M, Dreyfuss P, Halbrook B, Bogduk N. The ability of lumbar medial branch blocks to anesthetize the zygapophysial joint. A physiologic challenge. *Spine*. 1998;23(17):1847–1852.
12. Shuang F, Hou SX, Zhu JL, et al. Clinical anatomy and measurement of the medial branch of the spinal dorsal ramus. *Medicine*. 2015;94(52):e2367. doi:10.1097/MD.0000000000002367
13. Takahashi Y, Ohtori S, Takahashi K. Dorsoventral organization of sensory nerves in the lumbar spine as indicated by double labeling of dorsal root ganglion neurons. *J Orthop Sci*. 2010;15(4):578–583. doi:10.1007/s00776-010-1482-0
14. Kanakarajan S, Fernando K, Dharmavaram S, Galley HF. Sensory mapping of lumbar facet joint pain: a feasibility study. *Br J Pain*. 2021;15(1):64–68. doi:10.1177/2049463719886890
15. Netzer C, Distel P, Wolfgram U, et al. Comparative analysis of bone structural parameters reveals subchondral cortical plate resorption and increased trabecular bone remodeling in human facet joint osteoarthritis. *Int J Mol Sci*. 2018;19(3):845.
16. Li J, Muehleman C, Abe Y, Masuda K. Prevalence of facet joint degeneration in association with intervertebral joint degeneration in a sample of organ donors. *J Orthop Res*. 2011;29(8):1267–1274. doi:10.1002/jor.21387
17. Suri P, Hunter DJ, Rainville J, Guermazi A, Katz JN. Presence and extent of severe facet joint osteoarthritis are associated with back pain in older adults. *Osteoartr Cartil*. 2013;21(9):1199–1206. doi:10.1016/j.joca.2013.05.013
18. Eubanks JD, Lee MJ, Cassinelli E, Ahn NU. Prevalence of lumbar facet arthrosis and its relationship to age, sex, and race: an anatomic study of cadaveric specimens. *Spine*. 2007;32(19):2058–2062. doi:10.1097/BRS.0b013e318145a3a9
19. Kalichman L, Li L, Kim DH, et al. Facet joint osteoarthritis and low back pain in the community-based population. *Spine*. 2008;33(23):2560–2565. doi:10.1097/BRS.0b013e318184ef95
20. Ko S, Vaccaro AR, Lee S, Lee J, Chang H. The prevalence of lumbar spine facet joint osteoarthritis and its association with low back pain in selected Korean populations. *Clin Orthop Surg*. 2014;6(4):385–391. doi:10.4055/cios.2014.6.4.385
21. Song Q, Liu X, Chen DJ, et al. Evaluation of MRI and CT parameters to analyze the correlation between disc and facet joint degeneration in the lumbar three-joint complex. *BMC Musculoskelet Disord*. 2019;98(40):e17336.
22. Bashkuev M, Reitmaier S, Schmidt H. Relationship between intervertebral disc and facet joint degeneration: a probabilistic finite element model study. *J Biomech*. 2020;102:109518. doi:10.1016/j.jbiomech.2019.109518
23. Goda Y, Sakai T, Harada T, et al. Degenerative changes of the facet joints in adults with lumbar spondylolysis. *Clin Spine Surg*. 2017;30(6):E738–e742. doi:10.1097/BSD.0000000000000217
24. Suri P, Miyakoshi A, Hunter DJ, et al. Does lumbar spinal degeneration begin with the anterior structures? A study of the observed epidemiology in a community-based population. *BMC Musculoskelet Disord*. 2011;12:202. doi:10.1186/1471-2474-12-202
25. Eubanks JD, Lee MJ, Cassinelli E, Ahn NU. Does lumbar facet arthrosis precede disc degeneration? A postmortem study. *Clin Orthop Relat Res*. 2007;464:184–189. doi:10.1097/BLO.0b013e3181583d4e
26. Kim JS, Ali MH, Wydra F, et al. Characterization of degenerative human facet joints and facet joint capsular tissues. *Osteoartr Cartil*. 2015;23(12):2242–2251. doi:10.1016/j.joca.2015.06.009
27. Igarashi A, Kikuchi S, Konno S, Olmarker K. Inflammatory cytokines released from the facet joint tissue in degenerative lumbar spinal disorders. *Spine*. 2004;29(19):2091–2095. doi:10.1097/01.brs.0000141265.55411.30
28. Ekşi M, Özcan-ekşi EE, Orhun Ö, Huet SE, Turgut VU, Pamir MN. Association between facet joint orientation/tropism and lumbar intervertebral disc degeneration. *Br J Neurosurg*. 2020;1–8. doi:10.1080/02688697.2020.1864289
29. Morimoto M, Higashino K, Manabe H, et al. Age-related changes in axial and sagittal orientation of the facet joints: comparison with changes in degenerative spondylolisthesis. *J Orthop Sci*. 2019;24(1):50–56. doi:10.1016/j.jos.2018.08.028
30. Degulmadi D, Dave B, Krishnan A, Patel D. The relationship of facet joint orientation and tropism with lumbar disc herniation and degenerative spondylolisthesis in the lower lumbar spine. *Asian Spine J*. 2019;13(1):22–28. doi:10.31616/asj.2018.0116
31. Schleich C, Müller-Lutz A, Blum K, et al. Facet tropism and facet joint orientation: risk factors for the development of early biochemical alterations of lumbar intervertebral discs. *Osteoartr Cartil*. 2016;24(10):1761–1768. doi:10.1016/j.joca.2016.05.004
32. Wang H, Wu Z. Association between irregular orientation of facet orientation and degenerative lumbar spondylolisthesis. *World Neurosurg*. 2019;131:e298–e302. doi:10.1016/j.wneu.2019.07.141
33. Guo M, Kong C, Sun S, Sun X, Li X, Lu S. Predictors of L4-L5 degenerative lumbar spondylolisthesis: L4 inclination angle and facet joint angle. *World Neurosurg*. 2019;130:e680–e686. doi:10.1016/j.wneu.2019.06.188
34. Kalichman L, Suri P, Guermazi A, Li L, Hunter DJ. Facet orientation and tropism: associations with facet joint osteoarthritis and degeneratives. *Spine*. 2009;34(16):E579–E585. doi:10.1097/BRS.0b013e3181aa2acb
35. Fukushima M, Oshima Y, Oka H, et al. Potential pathological mechanisms of L3 degenerative spondylolisthesis in lumbar spinal stenosis patients: a case-control study. *J Orthop Sci*. 2019;24(4):596–600. doi:10.1016/j.jos.2018.12.002
36. Linov L, Klindukhov A, Li L, Kalichman L. Lumbar facet joint orientation and osteoarthritis: a cross-sectional study. *J Back Musculoskelet Rehabil*. 2013;26(4):421–426. doi:10.3233/BMR-130401
37. Yang M, Wang N, Xu X, et al. Facet joint parameters which may act as risk factors for chronic low back pain. *J Orthop Surg Res*. 2020;15(1):185. doi:10.1186/s13018-020-01706-6
38. Ke S, He X, Yang M, Wang S, Song X, Li Z. The biomechanical influence of facet joint parameters on corresponding segment in the lumbar spine: a new visualization method. *Spine j*. 2021;21(12):2112–2121. doi:10.1016/j.spinee.2021.05.024

39. Li Z, Gui G, Zhang Y, et al. Are facet joint parameters risk factors for recurrent lumbar disc herniation? A pilot study in a Chinese population. *J Orthop Surg Res*. 2020;77:36–40.
40. Mahato NK. Facet dimensions, orientation, and symmetry at L5-S1 junction in lumbosacral transitional States. *Spine*. 2011;36(9):E569–E573. doi:10.1097/BRS.0b013e3181f6ecb2
41. Chen Q, Ding W, Shen Y, et al. 第4腰椎退变性滑脱与影像学参数的关系分析 [Correlation between the 4th lumbar degenerative spondylolisthesis and radiographic parameters]. *Zhonghua Wai Ke Za Zhi*. 2014;52(2):122–126. Chinese.
42. Weinberg DS, Liu RW, Xie KK, Morris WZ, Gebhart JJ, Gordon ZL. Increased and decreased pelvic incidence, sagittal facet joint orientations are associated with lumbar spine osteoarthritis in a large cadaveric collection. *Int Orthop*. 2017;41(8):1593–1600. doi:10.1007/s00264-017-3426-1
43. Jiang X, Chen D, Li Z, Lou Y. Correlation between lumbar spine facet joint orientation and intervertebral disk degeneration: a positional MRI analysis. *J Neurol Surg a Cent Eur Neurosurg*. 2019;80(4):255–261. doi:10.1055/s-0039-1683450
44. Samartzis D, Cheung JP, Rajasekaran S, et al. Critical values of facet joint angulation and tropism in the development of lumbar degenerative spondylolisthesis: an international, large-scale multicenter study by the AOSpine Asia Pacific Research Collaboration Consortium. *Global Spine J*. 2016;6(5):414–421. doi:10.1055/s-0035-1564417
45. Kim HJ, Chun HJ, Lee HM, et al. The biomechanical influence of the facet joint orientation and the facet tropism in the lumbar spine. *Spine J*. 2013;13(10):1301–1308. doi:10.1016/j.spinee.2013.06.025
46. Dai LY. Orientation and tropism of lumbar facet joints in degenerative spondylolisthesis. *Int Orthop*. 2001;25(1):40–42. doi:10.1007/s002640000201
47. Ko HY, Park BK. Facet tropism in lumbar motion segments and its significance in disc herniation. *Arch Phys Med Rehabil*. 1997;78(11):1211–1214. doi:10.1016/S0003-9993(97)90334-8
48. Cinotti G, Postacchini F, Fassari F, Urso S. Predisposing factors in degenerative spondylolisthesis. A radiographic and CT study. *Int Orthop*. 1997;21(5):337–342. doi:10.1007/s002640050180
49. Perolat R, Kastler A, Nicot B, et al. Facet joint syndrome: from diagnosis to interventional management. *Insights Imaging*. 2018;9(5):773–789. doi:10.1007/s13244-018-0638-x
50. Campos WK, Linhares MN, Sarda J, et al. Predictors of pain recurrence after lumbar facet joint injections. *Front Neurosci*. 2019;13:958. doi:10.3389/fnins.2019.00958
51. Gómez Vega JC, Acevedo-González JC. Clinical diagnosis scale for pain lumbar of facet origin: systematic review of literature and pilot study. *Neurocirugia*. 2019;30(3):133–143. doi:10.1016/j.neucir.2018.05.004
52. Yasar D, Korgun O, Emine D. Radiofrequency and methylprednisolone in treatment of lower back pain caused by facet joint syndrome: comparison of the outcomes. *Asian J Neurosurg*. 2018;13(2):283–287. doi:10.4103/1793-5482.228569
53. Laslett M, Oberg B, Aprill CN, McDonald B. Zygapophysial joint blocks in chronic low back pain: a test of Revel's model as a screening test. *BMC Musculoskelet Disord*. 2004;5:43. doi:10.1186/1471-2474-5-43
54. Maas ET, Juch JN, Ostelo RW, et al. Systematic review of patient history and physical examination to diagnose chronic low back pain originating from the facet joints. *Eur J Pain*. 2017;21(3):403–414. doi:10.1002/ejp.963
55. Khan AM, Girardi F. Spinal lumbar synovial cysts. Diagnosis and management challenge. *Eur Spine J*. 2006;15(8):1176–1182. doi:10.1007/s00586-005-0009-4
56. Parlier-Cuau C, Wybier M, Nizard R, Champsaur P, Le Hir P, Laredo JD. Symptomatic lumbar facet joint synovial cysts: clinical assessment of facet joint steroid injection after 1 and 6 months and long-term follow-up in 30 patients. *Radiology*. 1999;210(2):509–513. doi:10.1148/radiology.210.2.r99fe60509
57. Hohenberger C, Brawanski A, Ullrich OW, Höhne J, Zeman F, Schebesch KM. Degenerative symptomatic spinal synovial cysts: clinical presentation and functional outcome. *J Clin Neurosci*. 2019;62:112–116. doi:10.1016/j.jocn.2018.12.006
58. Odonkor CA, Chen Y, Adekoya P, et al. Inciting events associated with lumbar facet joint pain. *Anesth Analg*. 2018;126(1):280–288. doi:10.1213/ANE.0000000000002242
59. Hughey S, Cole J, Booth G, et al. Predicting treatment success with facet syndrome: an algorithm to predict lumbar radiofrequency ablation responders in a military population. *Pain Med*. 2021;22(2):266–272. doi:10.1093/pm/pnaa381
60. Gellhorn AC, Katz JN, Suri P. Osteoarthritis of the spine: the facet joints. *Nat Rev Rheumatol*. 2013;9(4):216–224. doi:10.1038/nrrheum.2012.199
61. Pathria M, Sartoris DJ, Resnick D. Osteoarthritis of the facet joints: accuracy of oblique radiographic assessment. *Radiology*. 1987;164(1):227–230. doi:10.1148/radiology.164.1.3588910
62. Enokida S, Tanishima S, Tanida A, et al. Evaluation of age-related changes in lumbar facet joints using T2 mapping. *J Orthop Sci*. 2020;25(1):46–51. doi:10.1016/j.jos.2019.02.017
63. Hansen BB, Hansen P, Christensen AF, et al. Reliability of standing weight-bearing (0.25T) MR imaging findings and positional changes in the lumbar spine. *Skeletal Radiol*. 2018;47(1):25–35. doi:10.1007/s00256-017-2746-y
64. D'Aprile P, Nasuto M, Tarantino A, cornacchia S, Guglielmi G, Jenkins JR. Magnetic Resonance Imaging in degenerative disease of the lumbar spine: fat Saturation technique and contrast medium. *Acta Biomedica*. 2018;89(1-s):208–219. doi:10.23750/abm.v89i1-S.7024
65. Weishaupt D, Zanetti M, Boos N, Hodler J. MR imaging and CT in osteoarthritis of the lumbar facet joints. *Skeletal Radiol*. 1999;28(4):215–219. doi:10.1007/s002560050503
66. Little JW, Grieve T, Cantu J, et al. Reliability of human lumbar facet joint degeneration severity assessed by magnetic resonance imaging. *Biomed Res Int*. 2020;43(1):43–49.
67. Chang MC, Yi YG, Yang HE, Lee JH, Kim JH, Do KH. The clinical ability of contrast-enhanced magnetic resonance imaging to predict treatment outcomes for lumbar facet joint pain. *Ann Palliat Med*. 2021;10(2):1431–1437. doi:10.21037/apm-20-313
68. Sato S, Oguma H, Murakami G, Noriyasu S. Morphometrical study of the joint surface and capsule of the lumbar zygapophysial joint with special reference to their laterality. *Okajimas Folia Anat Jpn*. 2002;79(1):43–53. doi:10.2535/ofaj.79.43
69. Russo VM, Dhawan RT, Baudracco I, Dharmarajah N, Lazzarino AI, Casey AT. Hybrid bone SPECT/CT imaging in evaluation of chronic low back pain: correlation with facet joint arthropathy. *World Neurosurg*. 2017;107:732–738. doi:10.1016/j.wneu.2017.08.092
70. Holder LE, Machin JL, Asdourian PL, Links JM, Sexton CC. Planar and high-resolution SPECT bone imaging in the diagnosis of facet syndrome. *J Nucl Med*. 1995;36(1):37–44.



71. Freiermuth D, Kretschmar M, Bilecen D, et al. Correlation of (99m) Tc-DPD SPECT/CT scan findings and diagnostic blockades of lumbar medial branches in patients with unspecific low back pain in a randomized-controlled trial. *Pain Med.* 2015;16(10):1916–1922. doi:10.1111/pme.12841
72. Won HS, Yang M, Kim Y-D. Facet joint injections for management of low back pain: a clinically focused review. *Anesth Pain Med.* 2020;15(1):8–18. doi:10.17085/apm.2020.15.1.8
73. Manchikanti L, Kosanovic R, Pampati V, et al. Low back pain and diagnostic lumbar facet joint nerve blocks: assessment of prevalence, false-positive rates, and a philosophical paradigm shift from an acute to a chronic pain model. *Pain Phys.* 2020;23(5):519–530. doi:10.36076/ppj.2020/23/519
74. Birkenmaier C, Veihelmann A, Trouillier HH, Hausdorf J, von Schulze Pellengahr C. Medial branch blocks versus pericapsular blocks in selecting patients for percutaneous cryodestruction of lumbar facet joints. *Reg Anesth Pain Med.* 2007;32(1):27–33. doi:10.1016/j.rapm.2006.08.014
75. Maldjian C, Mesgarzadeh M, Tehranzadeh J. Diagnostic and therapeutic features of facet and sacroiliac joint injection. Anatomy, pathophysiology, and technique. *Radiol Clin North Am.* 1998;36(3):497–508. doi:10.1016/S0033-8389(05)70039-7
76. Sadeghian H, Motiei-Langroudi R. Sonography guided lumbar nerve and facet blocks: the first report of clinical outcome from Iran. *Radiography.* 2018;24(1):52–56. doi:10.1016/j.radi.2017.08.005
77. Kershen LM, Nacey NC, Patrie JT, Fox MG. Fluoroscopically guided facet injections: comparison of intra-articular and periarticular steroid and anesthetic injection on immediate and short-term pain relief. *Ame J Neuroradiol.* 2018;39(11):2161–2165. doi:10.3174/ajnr.A5805
78. Cohen SP, Doshi TL, Constantinescu OC, et al. Effectiveness of lumbar facet joint blocks and predictive value before radiofrequency denervation: the facet treatment study (FACTS), a randomized, controlled clinical trial. *Anesthesiology.* 2018;129(3):517–535. doi:10.1097/ALN.0000000000002274
79. Manchikanti L, Hirsch JA, Falco FJ, Boswell MV. Management of lumbar zygapophysial (facet) joint pain. *World J Orthop.* 2016;7(5):315–337. doi:10.5312/wjo.v7.i5.315
80. Liu M, Shaparin N, Nair S, Kim RS, Hascalovici JR. Chronic low back pain: the therapeutic benefits of diagnostic medial branch nerve blocks. *Pain Phys.* 2021;24(4):E521–e528.
81. Latini E, Curci ER, Nusca SM, et al. Medical ozone therapy in facet joint syndrome: an overview of sonoanatomy, ultrasound-guided injection techniques and potential mechanism of action. *Med Gas Res.* 2021;11(4):145–151. doi:10.4103/2045-9912.318859
82. Feigl GC, Dreu M, Kastner M, et al. Thermocoagulation of the medial branch of the dorsal branch of the lumbar spinal nerve: fluoroscopy versus CT. *Pain Med.* 2017;18(1):36–40. doi:10.1093/pm/pnw116
83. Kennedy DJ, Mattie R, Scott hamilton A, Conrad B, Smuck M. Detection of intravascular injection during lumbar medial branch blocks: a comparison of aspiration, live fluoroscopy, and digital subtraction technology. *Pain Med.* 2016;17(6):1031–1036. doi:10.1093/pm/pnw073
84. Provenzano DA, Buvanendran A, de León-Casasola OA, Narouze S, Cohen SP. Interpreting the MINT randomized trials evaluating radiofrequency ablation for lumbar facet and sacroiliac joint pain: a call from ASRA for better education, study design, and performance. *Reg Anesth Pain Med.* 2018;43(1):68–71. doi:10.1097/AAP.0000000000000699
85. MacVicar J, Borowczyk JM, MacVicar AM, Loughnan BM, Bogduk N. Lumbar medial branch radiofrequency neurotomy in New Zealand. *Pain Med.* 2013;14(5):639–645. doi:10.1111/pme.12000
86. Conger A, Burnham T, Salazar F, et al. The effectiveness of radiofrequency ablation of medial branch nerves for chronic lumbar facet joint syndrome in patients selected by guideline-concordant dual comparative medial branch blocks. *Pain Med.* 2020;21(5):902–909. doi:10.1093/pm/pnz248
87. Finlayson RJ, Curatolo M. Consensus practice guidelines on interventions for lumbar facet joint pain: finding a path through troubled waters. *Reg Anesth Pain Med.* 2020;45(6):397–398. doi:10.1136/rapm-2020-101597
88. Paulsen RT, Carreon L, Busch F, Isenberg-Jørgensen A. A pilot cohort study of lumbar facet joint denervation in patients with chronic low-back pain. *Dan Med J.* 2019;66(3):A5533.
89. Vorobeychik Y, Stojanovic MP, McCormick ZL. Radiofrequency denervation for chronic low back pain. *JAMA.* 2017;318(22):2254–2255. doi:10.1001/jama.2017.16386
90. Cohen SP, Williams KA, Kurihara C, et al. Multicenter, randomized, comparative cost-effectiveness study comparing 0, 1, and 2 diagnostic medial branch (facet joint nerve) block treatment paradigms before lumbar facet radiofrequency denervation. *Anesthesiology.* 2010;113(2):395–405. doi:10.1097/ALN.0b013e3181e33ae5
91. Abd-Elseyed A, Narel E, Loebertman M. Is a one prognostic block sufficient to proceed with radiofrequency ablation? A single center experience. *Curr Pain Headache Rep.* 2020;24(6):23. doi:10.1007/s11916-020-00858-8
92. Schneider BJ, Doan L, Maes MK, Martinez KR, Gonzalez Cota A, Bogduk N. Systematic review of the effectiveness of lumbar medial branch thermal radiofrequency neurotomy, stratified for diagnostic methods and procedural technique. *Pain Med.* 2020;21(6):1122–1141. doi:10.1093/pm/pnz349
93. Dreyfuss P, Schwarzer AC, Lau P, Bogduk N. Specificity of lumbar medial branch and L5 dorsal ramus blocks. A computed tomography study. *Spine.* 1997;22(8):895–902.
94. Manchikanti L, Pampati V, Fellows B, Bakhit CE. The diagnostic validity and therapeutic value of lumbar facet joint nerve blocks with or without adjuvant agents. *Curr Rev Pain.* 2000;4(5):337–344. doi:10.1007/s11916-000-0016-4
95. Wahezi SE, Alexeev E, Georgy JS, et al. Lumbar medial branch block volume-dependent dispersion patterns as a predictor for ablation success: a cadaveric study. *PM R.* 2018;10(6):616–622. doi:10.1016/j.pmrj.2017.11.011
96. Baroncini A, Maffulli N, Eschweiler J, Knobe M, Tingart M, Migliorini F. Management of facet joints osteoarthritis associated with chronic low back pain: a systematic review. *Surgeon.* 2021;19(6):e512–e518. doi:10.1016/j.surge.2020.12.004
97. Rodrigues JC, Poetscher AW. Prognostic factors in low back pain individuals undergoing steroid and anaesthetic intra-articular facet joint infiltration: a protocol for a prospective, longitudinal, cohort study. *BMJ Open.* 2019;9(7):e026903.
98. Ozcamdalli M, Misir A, Oguzkaya S, Kizkapan TB, Turk OI, Uzun E. The effect of lumbar facet joint injection levels on spinopelvic parameters and functional outcome. *J Back Musculoskelet Rehabil.* 2021;34(1):103–109. doi:10.3233/BMR-200067
99. Kwak DG, Kwak SG, Lee AY, Chang MC. Outcome of intra-articular lumbar facet joint corticosteroid injection according to the severity of facet joint arthritis. *Exp Ther Med.* 2019;18(5):4132–4136. doi:10.3892/etm.2019.8031

100. Sae-Jung S, Jirattananphochai K. Outcomes of lumbar facet syndrome treated with oral diclofenac or methylprednisolone facet injection: a randomized trial. *Int Orthop*. 2016;40(6):1091–1098. doi:10.1007/s00264-016-3154-y
101. Ribeiro LH, Furtado RN, Konai MS, Andreo AB, Rosenfeld A, Natour J. Effect of facet joint injection versus systemic steroids in low back pain: a randomized controlled trial. *Spine*. 2013;38(23):1995–2002. doi:10.1097/BRS.0b013e3182a76df1
102. Kennedy DJ, Huynh L, Wong J, et al. Corticosteroid injections into lumbar facet joints: a prospective, randomized, double-blind placebo-controlled trial. *Am J Phys Med Rehabil*. 2018;97(10):741–746. doi:10.1097/PHM.0000000000000960
103. Kennedy DJ, Fraiser R, Zheng P, et al. Intra-articular steroids vs saline for lumbar Z-joint pain: a prospective, randomized, double-blind placebo-controlled trial. *Pain Med*. 2019;20(2):246–251. doi:10.1093/pm/pny225
104. Snidvongs S, Taylor RS, Ahmad A, et al. Facet-joint injections for non-specific low back pain: a feasibility RCT. *Health Technol Assess*. 2017;21(74):1–130. doi:10.3310/hta21740
105. Lakemeier S, Lind M, Schultz W, et al. A comparison of intraarticular lumbar facet joint steroid injections and lumbar facet joint radiofrequency denervation in the treatment of low back pain: a randomized, controlled, double-blind trial. *Anesth Analg*. 2013;117(1):228–235. doi:10.1213/ANE.0b013e3182910c4d
106. Pneumatics SG, Chatziioannou SN, Hipp JA, Moore WH, Esses SI. Low back pain: prediction of short-term outcome of facet joint injection with bone scintigraphy. *Radiology*. 2006;238(2):693–698. doi:10.1148/radiol.2382041930
107. Fuchs S, Erbe T, Fischer HL, Tibesku CO. Intraarticular hyaluronic acid versus glucocorticoid injections for nonradicular pain in the lumbar spine. *J Vasc Interv Radiol*. 2005;16(11):1493–1498. doi:10.1097/01.RVI.0000175334.60638.3F
108. Carette S, Marcoux S, Truchon R, et al. A controlled trial of corticosteroid injections into facet joints for chronic low back pain. *N Engl J Med*. 1991;325(14):1002–1007. doi:10.1056/NEJM199110033251405
109. Annaswamy TM, Armstead C, Carlson L, Elkins NJ, Kocak D, Bierner SM. Intra-articular triamcinolone versus hyaluronate injections for low back pain with symptoms suggestive of lumbar zygapophyseal joint arthropathy: a pragmatic, double-blind randomized controlled trial. *Am J Phys Med Rehabil*. 2018;97(4):278–284. doi:10.1097/PHM.0000000000000879
110. Urits I, Viswanath O, Galasso AC, et al. Platelet-rich plasma for the treatment of low back pain: a comprehensive review. *Curr Pain Headache Rep*. 2019;23(7):52. doi:10.1007/s11916-019-0797-6
111. Wu J, Zhou J, Liu C, et al. A prospective study comparing platelet-rich plasma and local anesthetic (LA)/corticosteroid in intra-articular injection for the treatment of lumbar facet joint syndrome. *Pain Pract*. 2017;17(7):914–924. doi:10.1111/papr.12544
112. Sanapati J, Manchikanti L, Atluri S, et al. Do regenerative medicine therapies provide long-term relief in chronic low back pain: a systematic review and metaanalysis. *Pain Phys*. 2018;21(6):515–540.
113. Li J, Ding Z, Li Y, et al. BMSCs-derived exosomes ameliorate pain via abrogation of aberrant nerve invasion in subchondral bone in lumbar facet joint osteoarthritis. *J Orthop Res*. 2020;38(3):670–679. doi:10.1002/jor.24497
114. Gołębiowski M, Castellanos R, Gołębiowski M. Injectable amniotic membrane/umbilical cord particulate for facet joint syndrome: a retrospective, single-center study. *J Clin Med*. 2021;10(17). doi:10.3390/jcm10173884
115. Bennett DS. Cryopreserved amniotic membrane and umbilical cord particulate for managing pain caused by facet joint syndrome: a case series. *Medicine*. 2019;98(10):e14745. doi:10.1097/MD.00000000000014745
116. Cosman ER, Dolensky JR, Hoffman RA. Factors that affect radiofrequency heat lesion size. *Pain Med*. 2014;15(12):2020–2036. doi:10.1111/pme.12566
117. Provenzano DA, Watson TW, Somers DL. The interaction between the composition of preinjected fluids and duration of radiofrequency on lesion size. *Reg Anesth Pain Med*. 2015;40(2):112–124. doi:10.1097/AAP.0000000000000207
118. Shih CL, Shen PC, Lu CC, et al. A comparison of efficacy among different radiofrequency ablation techniques for the treatment of lumbar facet joint and sacroiliac joint pain: a systematic review and meta-analysis. *Clin Neurol Neurosurg*. 2020;195:105854. doi:10.1016/j.clineuro.2020.105854
119. Rotstein AH, Roebert J, Grabinski R, et al. Pulsed radiofrequency for lumbar facet joint pain: a viable therapeutic option? A retrospective observational study. *Sports Med*. 2020;9(2):573–582.
120. McCormick ZL, Choi H, Reddy R, et al. Randomized prospective trial of cooled versus traditional radiofrequency ablation of the medial branch nerves for the treatment of lumbar facet joint pain. *Reg Anesth Pain Med*. 2019;44(3):389–397. doi:10.1136/rapm-2018-000035
121. Wray JK, Dixon B, Przkora R. Radiofrequency Ablation. In: *StatPearls*. Treasure Island (FL): StatPearls Publishing; Copyright © 2021, StatPearls Publishing LLC; 2021.
122. Kocayigit H, Beyaz SG. Comparison of cooled and conventional radiofrequency applications for the treatment of osteoarthritic knee pain. *J Anaesthesiol Clin Pharmacol*. 2021;37(3):464–468. doi:10.4103/joacp.JOACP\_126\_19
123. Chou SH, Shen PC, Lu CC. Comparison of efficacy among three radiofrequency ablation techniques for treating knee osteoarthritis: a systematic review and meta-analysis. *Int J Environ Res Public Health*. 2021;18:14.
124. Shi W, Rudra R, Vu TN, Gordin Y, Smith R, Kunselman AR. Sensory stimulation threshold: a viable tool to improve the outcome of lumbar facet radiofrequency denervation? *J Pain Re*. 2021;14:2113–2119. doi:10.2147/JPR.S319622
125. Bogduk N, Dreyfuss P, Govind J. A narrative review of lumbar medial branch neurotomy for the treatment of back pain. *Pain Med*. 2009;10(6):1035–1045. doi:10.1111/j.1526-4637.2009.00692.x
126. Rimmalapudi V, Buchalter J, Calodney A. Radiofrequency denervation for chronic low back pain. *JAMA*. 2017;318(22):2255–2256. doi:10.1001/jama.2017.16378
127. Måwe L, Thorén LM, Kvarstein G. Responses after spinal interventions in a clinical pain practice - a pragmatic observational study. *Scand J Pain*. 2020;20(3):469–482. doi:10.1515/sjpain-2019-0126
128. Chen CH, Weng PW, Wu LC, Chiang YF, Chiang CJ. Radiofrequency neurotomy in chronic lumbar and sacroiliac joint pain: a meta-analysis. *Medicine*. 2019;98(26):e16230. doi:10.1097/MD.00000000000016230
129. Janapala RN, Manchikanti L, Sanapati MR. Efficacy of radiofrequency neurotomy in chronic low back pain: a systematic review and meta-analysis. *J Pain Res*. 2021;14:2859–2891. doi:10.2147/JPR.S323362
130. Al-Najjim M, Shah R, Rahuma M, Gabbar OA. Lumbar facet joint injection in treating low back pain: radiofrequency denervation versus SHAM procedure. Systematic review. *J Orthopa*. 2018;15(1):1–8. doi:10.1016/j.jor.2017.10.001

131. Starr JB, Gold LS, McCormick Z, Suri P, Friedly J. Repeat procedures and prescription opioid use after lumbar medial branch nerve radiofrequency ablation in commercially insured patients. *Spine J*. 2020;20(3):344–351. doi:10.1016/j.spinee.2019.10.005
132. Juch JNS, Maas ET, Ostelo R, et al. Effect of radiofrequency denervation on pain intensity among patients with chronic low back pain: the mint randomized clinical trials. *JAMA*. 2017;318(1):68–81. doi:10.1001/jama.2017.7918
133. Contreras Lopez WO, Navarro PA, Vargas MD, Alape E, Camacho Lopez PA. Pulsed radiofrequency versus continuous radiofrequency for facet joint low back pain: a systematic review. *World Neurosurg*. 2019;122:390–396. doi:10.1016/j.wneu.2018.10.191
134. Çetin A, Yektaş A. Evaluation of the short- and long-term effectiveness of pulsed radiofrequency and conventional radiofrequency performed for medial branch block in patients with lumbar facet joint pain. *Pain Res Manag*. 2018;2018:7492753. doi:10.1155/2018/7492753
135. Arsanious D, Gage E, Koning J, et al. Pulsed dose radiofrequency before ablation of medial branch of the lumbar dorsal ramus for zygapophyseal joint pain reduces post-procedural pain. *Pain Phys*. 2016;19(7):477–484. doi:10.36076/ppj/2016.19.477
136. Le VT, Do PT, Nguyen AM, Nguyen Dao LT. Thermal radiofrequency ablation combined with corticosteroid injection in management of lumbar facet joint pain: a single-center study in Vietnam. *World Neurosurg*. 2022;166(237–243.e1):237–243.e1. doi:10.1016/j.wneu.2022.07.122
137. Song K, Li Z, Shuang F, et al. Comparison of the effectiveness of radiofrequency neurotomy and endoscopic neurotomy of lumbar medial branch for facetogenic chronic low back pain: a randomized controlled trial. *World Neurosurg*. 2019;126:e109–e115. doi:10.1016/j.wneu.2019.01.251
138. Moussa WM, Khedr W. Percutaneous radiofrequency facet capsule denervation as an alternative target in lumbar facet syndrome. *Clin Neurol Neurosurg*. 2016;150:96–104. doi:10.1016/j.clineuro.2016.09.004
139. van Tilburg CW, Stronks DL, Groeneweg JG, Huygen FJ. Randomised sham-controlled double-blind multicentre clinical trial to ascertain the effect of percutaneous radiofrequency treatment for lumbar facet joint pain. *Bone Joint J*. 2016;98-B(11):1526–1533. doi:10.1302/0301-620X.98B11.BJJ-2016-0379.R2
140. van Wijk RM, Geurts JW, Wynne HJ, et al. Radiofrequency denervation of lumbar facet joints in the treatment of chronic low back pain: a randomized, double-blind, sham lesion-controlled trial. *Clin J Pain*. 2005;21(4):335–344. doi:10.1097/01.aip.0000120792.69705.c9
141. Leclaire R, Fortin L, Lambert R, Bergeron YM, Rossignol M. Radiofrequency facet joint denervation in the treatment of low back pain: a placebo-controlled clinical trial to assess efficacy. *Spine*. 2001;26(13):1411–6; discussion 1417. doi:10.1097/00007632-200107010-00003
142. Van Kleef M, Barendse GA, Kessels A, Voets HM, Weber WE, de Lange S. Randomized trial of radiofrequency lumbar facet denervation for chronic low back pain. *Spine*. 1999;24(18):1937–1942. doi:10.1097/00007632-199909150-00013
143. Russo MA, Santarelli DM. Development and description of a new multifidus-sparing radiofrequency neurotomy technique for facet joint pain. *Pain Pract*. 2021;21(7):747–758. doi:10.1111/papr.13010
144. Jacobson RE, Palea O, Granville M. Bipolar radiofrequency facet ablation of the lumbar facet capsule: an adjunct to conventional radiofrequency ablation for pain management. *Cureus*. 2017;9(9):e1635. doi:10.7759/cureus.1635
145. Chang MC, Cho YW, Ahn DH, Do KH. Intraarticular pulsed radiofrequency to treat refractory lumbar facet joint pain in patients with low back pain. *World Neurosurg*. 2018;112:e140–e144. doi:10.1016/j.wneu.2017.12.181
146. Do KH, Ahn SH, Cho YW, Chang MC. Comparison of intra-articular lumbar facet joint pulsed radiofrequency and intra-articular lumbar facet joint corticosteroid injection for management of lumbar facet joint pain: a randomized controlled trial. *Medicine*. 2017;96(13):e6524. doi:10.1097/MD.00000000000006524
147. Birkenmaier C, Veihelmann A, Trouillier H, et al. Percutaneous cryodenervation of lumbar facet joints: a prospective clinical trial. *Int Orthop*. 2007;31(4):525–530. doi:10.1007/s00264-006-0208-6
148. Bittman RW, Behbahani K, Gonzalez F, Prologo JD. Interventional cryoneurolysis: what is the same, what is different, what is new? *Semin Intervent Radiol*. 2019;36(5):374–380. doi:10.1055/s-0039-1696705
149. Lau P, Mercer S, Govind J, Bogduk N. The surgical anatomy of lumbar medial branch neurotomy (facet denervation). *Pain Med*. 2004;5(3):289–298. doi:10.1111/j.1526-4637.2004.04042.x
150. Kastler A, Gruber H, Gizewski E, Loizides A. Ultrasound assessment of ice-ball formation by cryoneurolysis device in an ex vivo model. *Reg Anesth Pain Med*. 2018;43(6):631–633. doi:10.1097/AAP.0000000000000793
151. Kastler A, Kogl N, Gruber H, Skalla E, Loizides A. Lumbar medial branch cryoneurolysis under ultrasound guidance: initial report of five cases. *Med Ultrason*. 2020;22(3):293–298. doi:10.11152/mu-2529
152. Dass RM, Kim E, Kim H-K, Lee JY, Lee HJ, Rhee SJ. Alcohol neurolysis of genicular nerve for chronic knee pain. *Korean J Pain*. 2019;32(3):223–227. doi:10.3344/kjp.2019.32.3.223
153. Kesikburun S, Yaşar E, Uran A, Adigüzel E, Yilmaz B. Ultrasound-guided genicular nerve pulsed radiofrequency treatment for painful knee osteoarthritis: a preliminary report. *Pain Phys*. 2016;19(5):E751–E759. doi:10.36076/ppj/2019.19.E751
154. Afifi A, Ringe M, Sobottke R, Oikonomidis S, Paul Johan Teuben M. Lumbar facet joint radiofrequency denervation therapy for chronic low back pain: enhanced outcome compared with chemical neurolysis (ethyl alcohol 95% or glycerol 20%). *Int J Spine Surg*. 2022;16(1):33–41. doi:10.14444/8175
155. Evans PJ, Lloyd JW, Jack TM. Cryoanalgesia for intractable perineal pain. *J R Soc Med*. 1981;74(11):804–809. doi:10.1177/014107688107401106
156. Moussa WM, Khedr W, Elsayy M. Percutaneous pulsed radiofrequency treatment of dorsal root ganglion for treatment of lumbar facet syndrome. *Clin Neurol Neurosurg*. 2020;199:106253. doi:10.1016/j.clineuro.2020.106253
157. Manchikanti L, Kosanovic R, Pampati V, et al. Equivalent outcomes of lumbar therapeutic facet joint nerve blocks and radiofrequency neurotomy: comparative evaluation of clinical outcomes and cost utility. *Pain Phys*. 2022;25(2):179–192.
158. Du T, Lu G, Li J, et al. Pain-free survival after endoscopic rhizotomy versus radiofrequency for lumbar facet joint pain: a real-world comparison study. *Pain Phys*. 2022;25(1):E87–E94.
159. Xue Y, Ding T, Wang D. Endoscopic rhizotomy for chronic lumbar zygapophysial joint pain. *J Orthop Surg Res*. 2020;15(1):4. doi:10.1186/s13018-019-1533-y
160. Woiciechowsky C, Richter LM. Endoscopic 4-MHz radiofrequency treatment of facet joint syndrome is more than just denervation: one incision for three facets. *J Neurol Surg A Cent Eur Neurosurg*. 2020;81(3):238–242. doi:10.1055/s-0039-1698397

161. Woiciechowsky C. Comparison of endoscopic facet joint denervation to the percutaneous technique regarding efficacy in patients with low back pain: a randomized controlled trial. *Spine*. 2022;47(17):1187–1193. doi:10.1097/BRS.0000000000004392
162. Walter SG, Struwe C, Scheidt S, et al. Endoscopic facet joint denervation for treatment of chronic lower back pain. *Clin Neurol Neurosurg*. 2020;195:105904. doi:10.1016/j.clineuro.2020.105904
163. Walter SG, Schildberg FA, Rommelspacher Y. Endoscopic sacrolumbar facet joint denervation in osteoarthritic and degenerated zygapophyseal joints. *Arthrosc Techn*. 2018;7(12):e1275–e1279. doi:10.1016/j.eats.2018.08.014

## Journal of Pain Research

Dovepress

### Publish your work in this journal

The Journal of Pain Research is an international, peer reviewed, open access, online journal that welcomes laboratory and clinical findings in the fields of pain research and the prevention and management of pain. Original research, reviews, symposium reports, hypothesis formation and commentaries are all considered for publication. The manuscript management system is completely online and includes a very quick and fair peer-review system, which is all easy to use. Visit <http://www.dovepress.com/testimonials.php> to read real quotes from published authors.

Submit your manuscript here: <https://www.dovepress.com/journal-of-pain-research-journal>