

A Metastatic Cervical Adenocarcinoma Patient Carrying *HER2* G292R Achieved Complete Response Upon Pyrotinib Treatment

Jing Liu^{1,*}
 Yanhong Zhuo^{2,*}
 Feng Wang^{3,*}
 Zirong Li^{4,*}
 Yibin Lin¹
 Li Li¹
 Junping Pan⁵
 Yanwen Song⁵
 Haiwei Du⁶
 Chanhe Li⁷
 Qin Xu¹

¹Department of Gynecology, Fujian Medical University Cancer Hospital & Fujian Cancer Hospital, Fuzhou, People's Republic of China; ²Department of Radiotherapy, Zhangzhou Hospital & Teaching Hospital of Fujian Medical University, Zhangzhou, People's Republic of China; ³Department of Outpatient, Fujian Hospital of People's Armed Police, Fuzhou, People's Republic of China; ⁴Department of Radiation Oncology, Longyan First Hospital Affiliated to Fujian Medical University, Longyan, People's Republic of China; ⁵Department of Radiotherapy, Fujian Medical University Cancer Hospital & Fujian Cancer Hospital, Fuzhou, People's Republic of China; ⁶Department of Data Science, Burning Rock Biotech, Guangzhou, People's Republic of China; ⁷Department of Medicine, Burning Rock Biotech, Guangzhou, People's Republic of China

*These authors contributed equally to this work

Correspondence: Qin Xu
 Department of Gynecology, Fujian Medical University Cancer Hospital & Fujian Cancer Hospital, No. 420 Fuma Road, Fuzhou, 350014, Fujian, People's Republic of China
 Email xqin772836@163.com

Abstract: Cervical cancer patients who develop distant metastasis are rarely curable with very limited treatment options. Chemotherapy is often administered but with limited efficacy. Immunotherapy and anti-angiogenesis therapy are recommended for selected cases of recurrent or metastatic cervical cancers. The clinical efficacy of inhibitors targeting *HER2*, a commonly mutated gene in cervical cancer, has not been elucidated. Herein, we report a metastatic cervical adenocarcinoma patient carrying *HER2* G292R who benefited from pyrotinib after progression on radio-chemotherapy, achieving complete response (CR) with a progression-free survival of 25 months and counting. Our study sheds light on the treatment options for previously treated metastatic cervical adenocarcinoma patients harboring activating *HER2* mutations.

Keywords: cervical cancer, adenocarcinoma, *HER2*, pyrotinib, complete response

Introduction

Cervical cancer is one of the leading causes of morbidity and cancer deaths in women worldwide and in China.^{1,2} Local radiotherapy, chemotherapy or the combination of chemotherapy and bevacizumab are the standard first-line treatment for recurrent and metastatic cervical cancer,³ but the current options for second-line and beyond treatment of cervical cancer remain limited.

HER2 (*ERBB2*) encodes the epidermal growth factor family member of receptor tyrosine kinases (RTKs). Somatic *HER2* alterations including *HER2* single nucleotide variants and *HER2* amplification, occurring in 14% of cervical cancers, are considered to be oncogenic and associated with poor prognosis.⁴ Pyrotinib, an irreversible pan-HER tyrosine kinase inhibitor against EGFR, *HER2* and *HER4*, combined with capecitabine has been approved by China National Medical Products Administration for the treatment of patients with *HER2*-overexpressing advanced or metastatic breast cancer who have been previously treated with anthracycline or taxane chemotherapy.⁵ Whether patients with *HER2*-mutant cervical cancer benefit from pyrotinib treatment has not been documented. In this study, we report the first clinical evidence of the efficacy of pyrotinib in a poorly differentiated metastatic cervical adenocarcinoma patient carrying *HER2* G292R who progressed on radio-chemotherapy.

Case Presentation

A woman in her 40s presented with irregular vaginal bleeding and was referred to our clinic in May 2018. The patient's treatment history is shown in Figure 1. She was

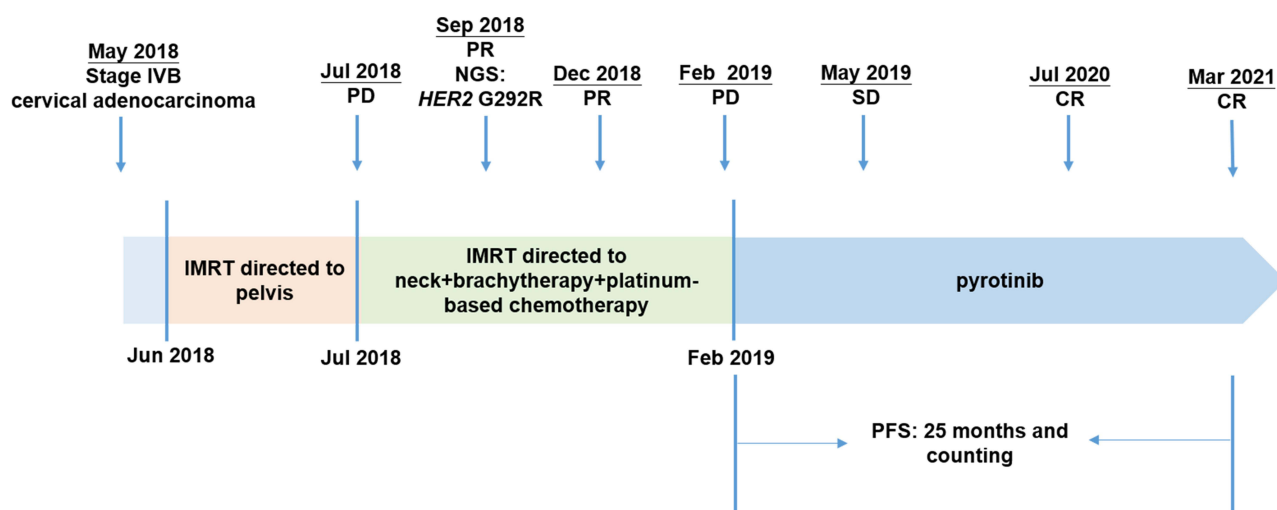


Figure 1 A summary of patient's treatment history.

Abbreviations: PR, partial response; PD, progressive disease; SD, stable disease; CR, complete response; PFS, progression-free survival; NGS, next-generation sequencing; HER2, ERBB2 receptor tyrosine kinase 2; IMRT, intensity-modulated radiation therapy.

diagnosed with stage IVB cervical adenocarcinoma (the red arrow in Figure 2A) with metastases to parametrial lymph node, retroperitoneal lymph node, pelvic lymph node, and neck lymph node. Hematoxylin & eosin (H&E) staining showed a primary cervical carcinoma (Figure 3A) and the metastases to neck lymph node (Figure 3B). Immunohistochemistry staining was performed on the primary cervical tumor and demonstrated that 1% of tumor cells were positive for HER2 overexpression (Figure 3C). The patient refused to receive chemotherapy at the beginning of treatment and instead received intensity-modulated radiation therapy (IMRT) on pelvis. Unfortunately, she developed

metastases to liver (the red arrow in Figure 2B) and left supraclavicular lymph node two weeks later. Under the consent of the patient, IMRT directed to neck in combination with brachytherapy and platinum-based chemotherapy (paclitaxel and nedaplatin) were administered in July 2018. The pelvic magnetic resonance imaging (MRI), abdominal MRI, and chest computed tomography (CT) scans in September 2018 demonstrated partial response (PR) in parametrial lymph node, retroperitoneal lymph node, pelvic lymph node, and metastatic liver tumor (the red arrow in Figure 2C). Re-examination in December 2018 demonstrated the complete remission of the primary cervical tumor. The

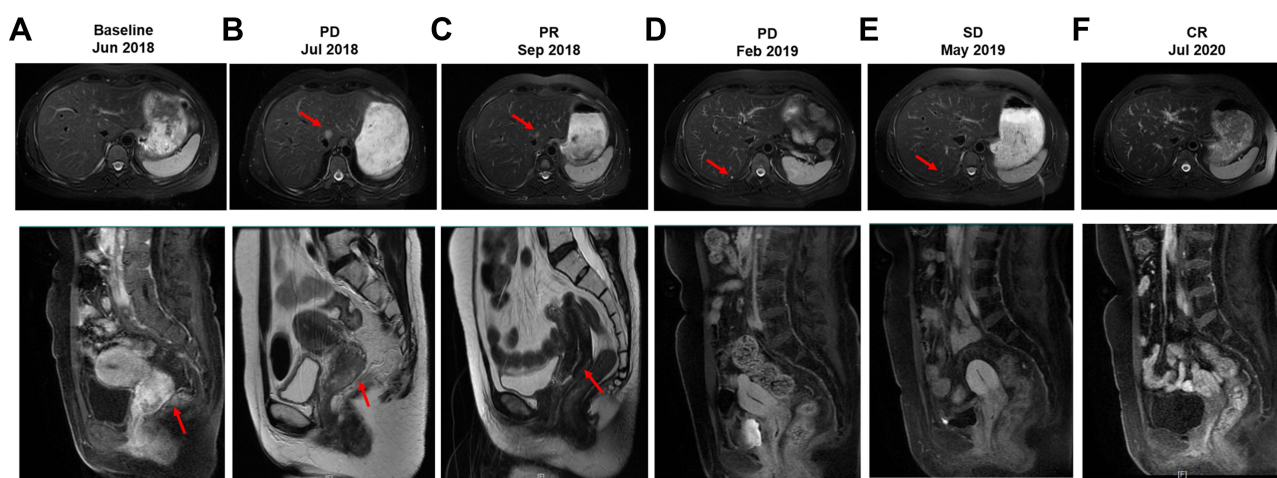


Figure 2 Magnetic resonance imaging (MRI) of the liver (upper) and cervical (lower) lesions at treatment milestones. (A) at baseline; (B) two weeks after IMRT directed to pelvis; (C) two months after IMRT directed to neck combined with brachytherapy and platinum-based chemotherapy (PR); (D) seven months after IMRT directed to neck combined with brachytherapy and platinum-based chemotherapy (PD). (E) three months after pyrotinib treatment (SD); (F) seventeen months after pyrotinib treatment (CR). The red arrows in upper and lower panels indicated metastatic liver lesion and the primary cervical adenocarcinoma, respectively.

Abbreviations: PR, partial response; PD, progressive disease; SD, stable disease; CR, complete response; IMRT, intensity-modulated radiation therapy.

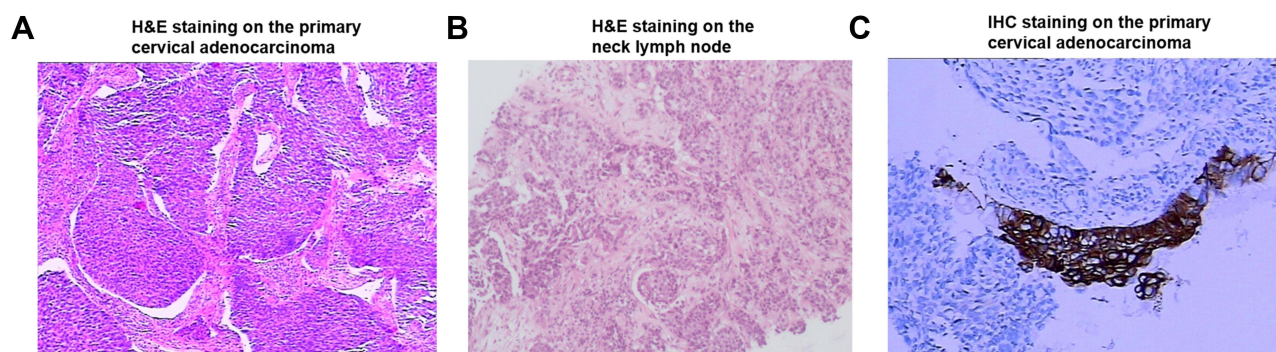


Figure 3 Hematoxylin & eosin (H&E)/immunohistochemistry (IHC) staining on the primary cervical adenocarcinoma/neck lymph node. **(A)** H&E staining on the primary cervical adenocarcinoma; **(B)** H&E staining on the neck lymph node; **(C)** IHC staining for HER2 on the primary cervical adenocarcinoma.

Abbreviations: H&E, hematoxylin & eosin; IHC, immunohistochemistry; HER2, ERBB2 receptor tyrosine kinase 2.

tumor assessment remained PR in metastatic liver tumor. In February 2019, the patient experienced disease progression with the newly developed metastatic liver lesion (the red arrow in Figure 2D). The patient was subsequently treated with oral pyrotinib (400 mg/day) based on the presence of *HER2* G292R with an allele frequency of 11.49%, negative *HER2* amplification, and microsatellite stable (MSS) in cervical biopsy detected by capture-based targeted sequencing (Burning Rock Biotech, Guangzhou, China) using a panel consisting of 520 cancer-related genes prior to pyrotinib treatment. Due to the intolerant hand-foot syndrome as the pyrotinib-related adverse event, the dose of pyrotinib was reduced to 240 mg/day. The patient achieved stable disease in May 2019 (Figure 2E) and the complete response in the metastatic liver tumor (the red arrow in Figure 2F) and metastases to lymph nodes in July 2020. She remained as tumor-free for 8 months and counting at the time of manuscript submission.

Discussion

To the best of our knowledge, this is the first to demonstrate the clinical efficacy of pyrotinib in a cervical cancer patient harboring *HER2* G292R who progressed on radiochemotherapy.

Currently, no *HER2* or pan-*HER* inhibitors have been approved for *HER2*-mutant cervical cancers, owing to the fact that the clinical efficacy of *HER2* or pan-*HER* inhibitors against *HER2* mutations remains elusive in cervical cancer. *HER2* G292R, which affects the extracellular domain of *HER2*, has been identified in non-small-cell lung cancer, breast cancer, and gallbladder carcinoma.^{6,7} *HER2* G292R potentially leads to a gain of function of *HER2* protein. In vitro studies have demonstrated that overexpression of *HER2*

G292R increase gallbladder cancer cell proliferation.⁶ This mutation has not been reported in cervical cancers before.

Pyrotinib has been approved for *HER2*-positive breast cancer.⁵ Previous studies have demonstrated the efficacy of pyrotinib against *HER2*-mutant solid tumors. A phase I basket trial completed in the United States has showed that patients with *HER2*-mutant lung cancer and other solid tumors obtained clinical benefit from pyrotinib treatment with a median progression-free survival (PFS) of 4.4 and 5.3 months, respectively.⁸ A multicenter, open-label Phase II study has demonstrated that pyrotinib showed promising antitumor activity with an objective response rate of 30% and a PFS of 6.9 months in Chinese patients with *HER2*-mutant lung adenocarcinoma who progressed on platinum-based chemotherapy.⁹ However, patients with cervical cancer or harboring *HER2* G292R are not included in the above studies. Several activating *HER2* mutations occurring in the extracellular domain of *HER2* protein have been identified in solid tumors, including G265K, G292R, G309A/E, S310F, S310Y, and E405D.^{4,6,10,11} *HER2* G309A/E, S310F, and E405D mutations have been shown to respond to afatinib or neratinib in vitro or in vivo.^{4,10} A prior study has demonstrated that 5.8% of cervical tumors carry *HER2* extracellular domain mutations.⁴ The most common subtype of *HER2* mutations in cervical cancer is S310F/Y,⁴ in contrast to the *HER2* exon 20 insertions and V777/L755 missense mutations most commonly found in lung cancer and breast cancer, respectively. Cervical cancers carrying S310F or E405D are sensitive to afatinib or neratinib in vitro.⁴ The SUMMIT basket trial has demonstrated the promising activity of neratinib in patients with breast, cervical, and biliary cancers carrying *HER2* mutations.¹² The updated results from SUMMIT basket trial have demonstrated that 4 of 16 *HER2*-mutant cervical cancer patients derived objective response to

neratinib with a median PFS of 7.0 months. All responders harbored *HER2* S310F mutations, including one who achieved complete response to neratinib.¹³ In this study, the *HER2* G292R-positive patient derived complete remission of the primary cervical adenocarcinoma when treated with radio-chemotherapy. The patient subsequently derived complete remission of the metastatic tumors and remained in complete remission of the primary cervical tumor when treated with pyrotinib with a PFS of 25 months and counting. Both previous studies and ours suggest that *HER2* extracellular domain mutations might be the promising therapeutic target in cervical cancer. Large cohorts and clinical trials are needed to further evaluate the efficacy of pan-HER inhibitor pyrotinib against *HER2* G292R and other *HER2* extracellular domain mutations in cervical cancer.

In summary, we revealed the first clinical evidence that a metastatic cervical adenocarcinoma patient carrying *HER2* G292R mutation achieved CR with a PFS of 25 months and counting upon pyrotinib treatment. Our data shed light on the treatment options for previously treated advanced cervical adenocarcinoma patients harboring this or other activating *HER2* mutations.

Ethics Statement

This study was approved by the Ethics Committee of Fujian Cancer Hospital. Patient provided informed consent to the study and permitted the use of tumor tissue. Written informed consent was obtained from the patient for publication of this case report.

Funding

This study was supported by Natural Science Foundation of Fujian Province (No.2020J011126) and Joint Funds for the Innovation of Science and Technology Program of Fujian Province, China (No.2018Y9110).

Disclosure

The authors have no conflicts of interest to declare.

References

1. Siegel RL, Miller KD, Jemal A. Cancer statistics, 2020. *CA Cancer J Clin.* 2020;70(1):7–30. doi:10.3322/caac.21590
2. Chen W, Zheng R, Baade PD, et al. Cancer statistics in China, 2015. *CA Cancer J Clin.* 2016;66(2):115–132. doi:10.3322/caac.21338
3. NCCN Clinical Practice Guidelines in Oncology. Cervical cancer Version 1.2021. Available from: www.nccn.org. Accessed August 31, 2021.
4. Zammataro L, Lopez S, Bellone S, et al. Whole-exome sequencing of cervical carcinomas identifies activating ERBB2 and PIK3CA mutations as targets for combination therapy. *Proc Natl Acad Sci U S A.* 2019;116(45):22730–22736. doi:10.1073/pnas.1911385116
5. Blair HA. Pyrotinib: first global approval. *Drugs.* 2018;78(16):1751–1755. doi:10.1007/s40265-018-0997-0
6. Li M, Zhang Z, Li X, et al. Whole-exome and targeted gene sequencing of gallbladder carcinoma identifies recurrent mutations in the ErbB pathway. *Nat Genet.* 2014;46(8):872–876. doi:10.1038/ng.3030
7. Chakravarty D, Gao J, Phillips SM, et al. OncoKB: a precision oncology knowledge base. *JCO Precis Oncol.* 2017;1:1–6. doi:10.1200/po.17.00011
8. Li BT, Li T, Johnson ML, et al. Safety and efficacy of pyrotinib in patients with NSCLC and other advanced solid tumors with activating *HER2* alterations: a Phase I basket trial. *J Clin Oncol.* 2020;38(15_suppl):3510. *WCLC Abstrac #3510*. doi:10.1200/JCO.2020.38.15_suppl.3510
9. Zhou C, Li X, Wang Q, et al. Pyrotinib in *HER2*-mutant advanced lung adenocarcinoma after platinum-based chemotherapy: a multicenter, open-label, single-arm, Phase II Study. *J Clin Oncol.* 2020;38(24):2753–2761. doi:10.1200/jco.20.00297
10. Bose R, Kavuri SM, Searleman AC, et al. Activating *HER2* mutations in *HER2* gene amplification negative breast cancer. *Cancer Discov.* 2013;3(2):224–237. doi:10.1158/2159-8290.cd-12-0349
11. Greulich H, Kaplan B, Mertins P, et al. Functional analysis of receptor tyrosine kinase mutations in lung cancer identifies oncogenic extracellular domain mutations of ERBB2. *Proc Natl Acad Sci U S A.* 2012;109(36):14476–14481. doi:10.1073/pnas.1203201109
12. Hyman DM, Piha-Paul SA, Won H, et al. *HER* kinase inhibition in patients with *HER2*- and *HER3*-mutant cancers. *Nature.* 2018;554(7691):189–194. doi:10.1038/nature25475
13. Oaknin A, Friedman CF, Roman LD, et al. Neratinib in patients with *HER2*-mutant, metastatic cervical cancer: findings from the Phase 2 SUMMIT basket trial. *Gynecol Oncol.* 2020;159(1):150–156. doi:10.1016/j.ygyno.2020.07.025

OncoTargets and Therapy

Publish your work in this journal

OncoTargets and Therapy is an international, peer-reviewed, open access journal focusing on the pathological basis of all cancers, potential targets for therapy and treatment protocols employed to improve the management of cancer patients. The journal also focuses on the impact of management programs and new therapeutic

agents and protocols on patient perspectives such as quality of life, adherence and satisfaction. The manuscript management system is completely online and includes a very quick and fair peer-review system, which is all easy to use. Visit <http://www.dovepress.com/testimonials.php> to read real quotes from published authors.

Submit your manuscript here: <https://www.dovepress.com/oncotargets-and-therapy-journal>

Dovepress