

# Correlation between the matrix metalloproteinase-9 activity and chondroitin sulfate concentrations in tear fluid after laser *in situ* keratomileusis

Tetsuya Mutoh  
Masaya Nishio  
Yukihiro Matsumoto  
Kiyomi Arai

Department of Ophthalmology,  
Dokkyo Medical University Koshigaya  
Hospital, Koshigaya, Saitama, Japan

**Aims:** The aim of the present study was to evaluate the correlation between matrix metalloproteinase-9 (MMP-9) and chondroitin sulfate (CS) concentrations in human tear fluid following laser *in situ* keratomileusis (LASIK).

**Methods:** Twelve eyes from six patients who had no ocular complaints except for refractive errors, and who had undergone LASIK, were enrolled in this study. We measured the concentrations of chondroitin 4 sulfate (C4S), chondroitin 6 sulfate (C6S), and MMP-9 activity with an enzyme-linked immunosorbent assay and an enzyme immunocapture activity assay preoperatively and postoperatively on days 1 and 4, week 1, and at 1 and 3 months.

**Results:** Although the preoperative MMP-9 activity and the C4S concentration were highly correlated ( $r = 0.900$ ;  $P < 0.001$ ), they were not postoperatively correlated at month 1. Although the preoperative MMP-9 activity and the C6S concentration were highly correlated ( $r = 0.885$ ;  $P < 0.001$ ), they were not postoperatively correlated at either week 1 or months 1 and 3.

**Conclusions:** The correlation appeared to be collapsed by LASIK, and it did not recover to the preoperative score at 3 months post-surgery. Our study indicates that the corneal wound healing was not terminated at 3 months following LASIK.

**Keywords:** preoperative correlation, postoperative correlation, wound healing, refractive errors, human cornea

## Introduction

By degenerating superfluous extracellular matrix,<sup>1</sup> matrix metalloproteinases (MMPs) play an important role in tissue remodeling and wound healing.<sup>2</sup> In the ophthalmologic area, MMPs also play an important role in corneal wound healing,<sup>3</sup> and more than 28 subtypes have been identified thus far.<sup>4</sup>

Chondroitin sulfate (CS), a type of glycosaminoglycan, exists in various organs and is essential for corneal wound healing.<sup>5-7</sup> Chondroitin 4 sulfate (C4S) and chondroitin 6 sulfate (C6S) are sulfated isomers.<sup>5-7</sup> The majority of the glycosaminoglycans in the tear fluid are CS6. Both MMPs and CS are detectable in human tear fluid.<sup>1,5,6,8</sup> Matrix metalloproteinase-9 (MMP-9) was found to be expressed in corneal wound healing in animal experiments<sup>9,10</sup> and CS participates in corneal wound healing after laser *in situ* keratomileusis (LASIK) as assessed in a clinical study.<sup>5</sup> CS increased MMPs activity in corneal explant cultures.<sup>11</sup> MMP-9 and CS deeply participate in corneal ectasia which occurred several years after LASIK.<sup>12</sup> Based on the findings of these previous reports,

Correspondence: Tetsuya Mutoh  
Department of Ophthalmology, Dokkyo  
Medical University Koshigaya Hospital,  
Koshigaya, Saitama 343-8555, Japan  
Tel +81 48 965 1111  
Fax +81 48 965 1127  
Email mtetsuya@dokkyomed.ac.jp

we therefore consider the relationship between MMP-9 and CS to be very important in corneal wound healing.

By measuring the levels of MMP-9 activity and the concentrations of C4S and C6S in human tear fluid from patients undergoing myopic or myopic astigmatic LASIK, we evaluated whether MMP-9 activity is postoperatively correlated with the C4S and C6S concentrations up to 3 months.

## Materials and methods

The protocol of this study was approved by the institutional review board of the Dokkyo Medical University, and all participating patients provided written informed consent.

Twelve eyes of six patients who underwent myopic or myopic astigmatic LASIK were included in the present study (mean age  $\pm$  standard deviation,  $30.0 \pm 6.4$  years). The patients had no ocular complaints except for the refractive errors, and they had not undergone any previous ocular surgery.

## LASIK

Simultaneous binocular LASIK was performed in all patients. The VISXR Star S3 excimer laser (VISX USA Inc., Santa Clara, CA, USA); wavelength, 193 nm; fluence, 160 mJ/cm<sup>2</sup>; pulse rate, 10 Hz and the Moria LASIK M2 microkeratome (Moria KK, Tokyo, Japan) were used. The eye tracking system of the excimer laser was activated during the procedure.

A corneal flap was created using the microkeratome and was then lifted. The planned laser ablation was performed on the corneal stroma; the corneal flap and stromal bed then were washed using 0.3 mM oxyglutathione solution. The corneal flap was returned to the original position and spontaneously reattached. After the procedure, 0.5% levofloxacin and 0.1% betamethasone sodium phosphate were bilaterally instilled. The patients then applied 0.5% levofloxacin, 0.1% fluorometholone, and 0.3% sodium hyaluronate 4 times daily for 1 week after surgery. One week later, 0.5% levofloxacin and 0.1% fluorometholone were tapered to twice daily and discontinued 1 month postoperatively, and 0.3% sodium hyaluronate was applied as needed.

## Sampling tear fluid

Tear fluid was collected from the lower conjunctival sac with a microcapillary tube (Minicaps, Hirschmann Laborgerate, Osaka, Japan); capillary length, 32 mm; maximum volume, 0.5  $\mu$ L). We did not touch the conjunctiva to prevent conjunctival stimulation and reflex tearing. The collection time was 30 s. When the capillary filled with tear fluid within 30 s, additional capillaries were immediately applied to the

conjunctival sac until 30 s. No topical anesthesia was applied during the collection process, and no topical agents were used within 30 min before the collection of the tear fluid. The tear volume was calculated by measuring the height of the tear fluid in the microcapillary tube. We collected 0.3 to 3  $\mu$ L of tear fluid from each patient and formulated the samples by diluting the collected tear fluid with 200  $\mu$ L of saline. The samples were frozen immediately at  $-40^{\circ}\text{C}$  after collection until the measurements were performed. Tear fluid was preoperatively collected and postoperatively on days 1 and 4, at 1 week, and 1 and 3 months. All samples were collected by the same investigator.

## MMP-9 specific enzyme immunocapture activity assay

The concentrations of each CS isomer in the tear fluid were measured by a sandwich enzyme-linked immunosorbent assay, as reported previously.<sup>5</sup> The MMP-9 activity was measured with enzyme immunocapture activity assay (Biotrak Matrix Metalloproteinase-9 Activity Assay System, GE Healthcare Bio-Sciences KK, Tokyo, Japan).

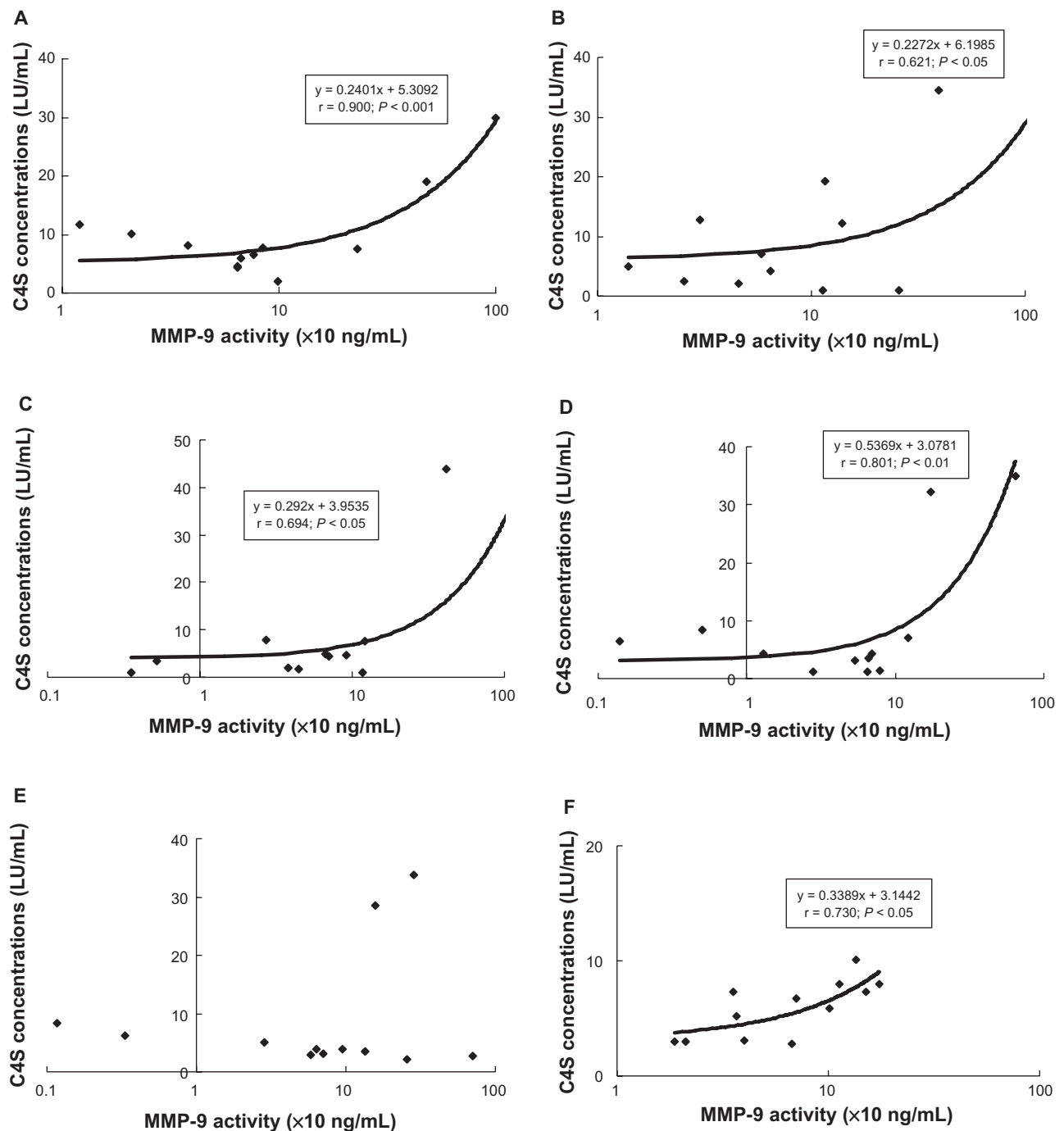
The 20- $\mu$ L samples and MMP-9 standard solution were placed in the wells of microplates that were precoated with anti-MMP-9 antibody, reacted, fixed at  $4^{\circ}\text{C}$  overnight, and immunocaptured. After washing, active MMP-9 was detected through the activation of the modified pro-detection enzyme and subsequent cleavage of its chromogenic peptide substrate. The resulting coloration was read at 405 nm in a microtitre plate spectrophotometer (Spectra Fluor, Xfluoer ver.4.03, Tecan Austria GmbH, Grödig, Austria). The concentration of active MMP-9 in a sample was determined by interpolation from a standard curve.<sup>13</sup>

## Statistical analysis

The MMP-9 activity and the concentrations of CS isomers in the tear fluid were analyzed by Pearson's product-moment correlation. *P*-values of less than 0.05 were considered to be statistically significant using Fisher's *r* to *z* transformation.

## Results

The uncorrected distance visual acuity recovered to 1.5 in all patients. Only superficial punctate keratopathy was observed as a perioperative complication in two eyes 1 week postoperatively and in one eye 1 month postoperatively. Figure 1 shows the correlation between the MMP-9 activity and C4S concentration in the tear fluid. The preoperative correlation was high ( $r = 0.900$ ;  $P < 0.001$ ), but it disappeared at postoperative month 1. Although a correlation was present at



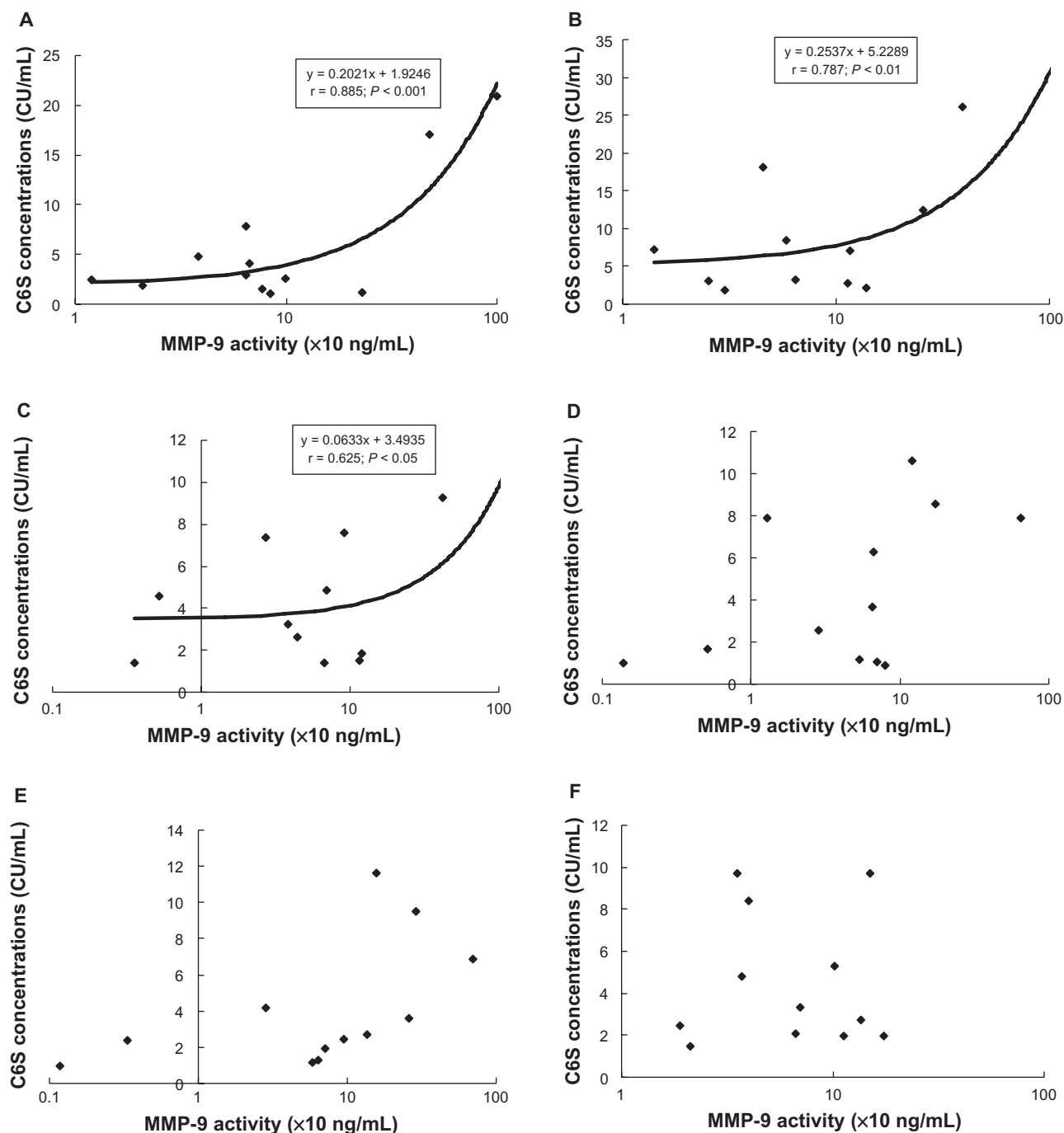
**Figure 1** Correlation of matrix metalloproteinase-9 (MMP-9) activity and Chondroitin 4 sulfate (C4S) concentrations at each time point with (A) preoperative score ( $r = 0.900$ ;  $P < 0.001$ ), (B) postoperative day 1 ( $r = 0.621$ ;  $P < 0.05$ ), (C) postoperative day 4 ( $r = 0.694$ ;  $P < 0.05$ ), (D) postoperative week 1 ( $r = 0.801$ ;  $P < 0.01$ ), (E) postoperative month 1, and (F) postoperative month 3 ( $r = 0.730$ ;  $P < 0.05$ ).  $r$  = correlation coefficient.

postoperative days 1 ( $r = 0.621$ ;  $P < 0.05$ ) and 4 ( $r = 0.694$ ;  $P < 0.05$ ), 1 week ( $r = 0.801$ ;  $P < 0.01$ ) and 3 months ( $r = 0.730$ ;  $P < 0.05$ ), it was weaker than was found preoperatively. Figure 2 shows the correlation between the MMP-9 activity and C6S concentration in the tear fluid. The preoperative correlation was high ( $r = 0.885$ ;  $P < 0.001$ ), but was not present at postoperative week 1, or at months 1 and 3.

Although the correlation existed at postoperative days 1 ( $r = 0.787$ ;  $P < 0.01$ ) and 4 ( $r = 0.625$ ;  $P < 0.05$ ), it was lower than the preoperatively measured score just as C4S.

## Discussion

The correlation changed between the MMP-9 activity and CS concentrations before and after LASIK. There



**Figure 2** Correlation of matrix metalloproteinase-9 (MMP-9) activity and Chondroitin 6 sulfate (C6S) concentrations at each time point with (A) preoperative score ( $r = 0.885$ ;  $P < 0.001$ ), (B) postoperative day 1 ( $r = 0.787$ ;  $P < 0.01$ ), (C) postoperative day 4 ( $r = 0.625$ ;  $P < 0.05$ ), (D) postoperative week 1, (E) postoperative month 1, and (F) postoperative month 3.  $r$  = correlation coefficient.

was high correlation between the MMP-9 activity and CS concentrations preoperatively. When the ocular surface is normal before surgery, the MMP-9 activity and CS concentrations are well correlated, and the environment is stable. However, this correlation disappeared or declined after LASIK. We hypothesized that this change was caused by LASIK, and the correlation between the MMP-9 activity

and CS concentrations did not recover to the preoperative levels even by 3 months following LASIK. These results indicated that the corneal wound healing did not terminate at 3 months after LASIK. A study in rabbits reported that material positive for periodic acid Schiff and disorganized collagen fibers were even seen 9 months after LASIK, and the corneal wound healing still had not ceased.<sup>14</sup> From these

findings, it is likely that the corneal wound healing lasts for a long period following LASIK, implying that the insufficient attachment between the corneal flap and the corneal bed lasts for a prolonged period. There were a few subjects in which the dislocation of corneal flaps,<sup>15,16</sup> or ectasia which consisted of a progressive deformation and thinning of the cornea<sup>12</sup> after LASIK, and these cases appear to be related to corneal wound healing. Although no case of either a dislocation of corneal flaps or ectasia has occurred so far, there is a possibility for such an occurrence. We must therefore carefully observe all patients who undergo LASIK for a long period of time.

To evaluate the MMP-9 and CS isomers, we chose patients undergoing LASIK partly because there have been no previous studies of perioperative MMP-9 activity and CS concentrations in the tear fluid in that series. In addition, many more patients have recently undergone LASIK. Finally, the cornea after LASIK is seriously injured and may be a good model of corneal wound healing.

We used topical corticosteroids in the present study, which may be a factor that affected the corneal wound healing. Topical corticosteroids might affect the change in MMP-9 activity and CS concentrations and thereby impact corneal wound healing. However, there was not a great effect on the refraction stability or the occurrence of diffuse lamellar keratitis,<sup>17,18</sup> and the beneficial effects of topical corticosteroids are limited for corneal wound healing.<sup>5</sup>

According to Sobrin et al, MMP-3 independently activated MMP-9 on the ocular surface, and doxycycline decreased MMP-9 activity in corneal epithelial cultures.<sup>8</sup> Zylberberg et al found that both pro-MMP-2 and pro-MMP-9 were secreted by the lacrimal gland, and were likely up-regulated by estrogen.<sup>19</sup> Kobayashi reported that leptomycin B reduced MMP-9 expression.<sup>4</sup> During corneal wound healing, transforming growth factor- $\beta$  and MMPs are involved in the synthesis and decomposition of the extracellular matrix.<sup>20,21</sup> Taken together, MMPs interact with many factors by complex mechanisms, are well balanced with each other, and have important roles in the corneal wound-healing process.

Although the preoperative MMP-9 activity and CS concentrations were highly correlated, we found that this correlation disappeared or declined after LASIK in the present series. The corneal wound healing may require 3 months or more following LASIK because the correlation did not recover to the preoperative correlation levels at 3 months after the procedure. Clarifying the correlation between MMP-9 and CS may elucidate or aid in the prevention of dislocation of corneal flaps and ectasia following LASIK.

## Acknowledgments

The authors deeply thank Professor Makoto Chikuda and Doctor Koji Kadoya from the Department of Ophthalmology, Dokkyo Medical University, Koshigaya Hospital for supervising the research project. All research members are acknowledged for the biochemical analysis in the Research Institute for Medical Science, Dokkyo Medical University, Koshigaya Hospital.

## Disclosure

The authors report no conflicts of interest in this work.

## References

- Leonardi A, Brun P, Abatangelo G, Plebani M, Secchi AG. Tear levels and activity of matrix metalloproteinase (MMP)-1 and MMP-9 in vernal keratoconjunctivitis. *Invest Ophthalmol Vis Sci*. 2003;44:3052–3058.
- Hanemaaijer R, Visser H, Kontinen YT, Koolwijk P, Verheijen JH. A novel and simple immunocapture assay for determination of gelatinase-B (MMP-9) activities in biological fluids: saliva from patients with Sjögren's syndrome contain increased latent and active gelatinase-B levels. *Matrix Biol*. 1998;17:657–665.
- Hadassah J, Bhuvaneshwari N, Rao U, Sehgal PK. Evaluation of succinylated collagen bandage lenses in corneal healing by the expression of matrix metalloproteinases (MMP-2 and MMP-9) in tear fluid. *Ophthalmic Res*. 2009;42:64–72.
- Kobayashi T. Role of matrix metalloproteinase-9 expression on cutaneous inflammation: Possible treatment by leptomycin B application. *Inflammation and Regeneration*. 2004;24:578–583.
- Nishio M, Arai K. Quantitative analysis of chondroitin sulfate in tear fluids following laser in situ keratomileusis. *Ophthalmic Res*. 2006;38:274–279.
- Oya T, Obata H, Miyata K, Tsuru T, Miyauchi S. Quantitative analysis of glycosaminoglycans in tear fluids in normal human eyes and eyes with corneal epithelial disorders. *Jpn J Ophthalmol Soc*. 1995;99:302–307.
- Oya T, Obata H, Miyata K, et al. Quantitative analysis of glycosaminoglycans in tear fluids during corneal epithelial wound healing in rabbits. *Jpn J Ophthalmol Soc*. 1994;98:1049–1055.
- Sobrin L, Liu Z, Monroy DC, et al. Regulation of MMP-9 activity in human tear fluid and corneal epithelial culture supernatant. *Invest Ophthalmol Vis Sci*. 2000;41:1703–1709.
- Azar DT, Hahn TW, Jain S, Yeh YC, Stetler-Stevenson WG. Matrix metalloproteinases are expressed during corneal wound healing after excimer laser keratectomy. *Cornea*. 1996;15:18–24.
- Mulholland B, Tuft SJ, Khaw PT. Matrix metalloproteinase distribution during early corneal wound healing. *Eye*. 2005;19:584–588.
- Isnard N, Robert L, Renard G. Effect of sulfated GAGs on the expression and activation of MMP-2 and MMP-9 in corneal and dermal explant cultures. *Cell Biol Int*. 2003;27:779–784.
- Esquenazi S, Esquenazi I, Grunstein L, He J, Bazan H. Immunohistological evaluation of the healing response at the flap interface in patients with LASIK ectasia requiring penetrating keratoplasty. *J Refract Surg*. 2009;25:739–746.
- Verheijen JH, Nieuwenbroek NME, Beekman B, et al. Modified proenzymes as artificial substrates for proteolytic enzymes: colorimetric assay of bacterial collagenase and matrix metalloproteinase activity using modified pro-urokinase. *Biochem J*. 1997;323:603–609.
- Kato T, Nakayasu K, Hosoda Y, Watanabe Y, Kanai A. Corneal wound healing following laser in situ keratomileusis (LASIK): a histopathological study in rabbits. *Br J Ophthalmol*. 1999;83:1302–1305.

15. Nowroozzadeh MH. Early flap dislocation with perioperative brimonidine use in laser in situ keratomileusis. *J Cataract Refract Surg*. 2010; 36:368.
16. Oh-i K, Mori H, Kubo M, et al. LASIK flap dislocation by blunt trauma seven weeks after surgery. *J Refract Surg*. 2005;21:93–94.
17. Baek SH, Chang JH, Choi SY, et al. The effect of topical corticosteroids on refractive outcome and corneal haze after photorefractive keratectomy. *J Refract Surg*. 1997;13:644–652.
18. Price FW Jr, Willes L, Price M, Lyng A, Ries JA. A prospective, randomized comparison of the use versus non-use of topical corticosteroids after laser in situ keratomileusis. *Ophthalmology*. 2001;108:1236–1244.
19. Zylberberg C, Seamon V, Ponomareva O, Vellala K, Deighan M, Azzarolo AM. Estrogen upregulation of metalloproteinase-2 and -9 expression in rabbit lacrimal glands. *Exp Eye Res*. 2007;84:960–972.
20. Matsubara M, Girard MT, Kublin CL, Cintron C, Fini ME. Differential roles for two gelatinolytic enzymes of the matrix metalloproteinase family in the remodeling cornea. *Dev Biol*. 1991;147:425–439.
21. Gipson IK, Inatomi T. Extracellular matrix and growth factors in corneal wound healing. *Curr Opin Ophthalmol*. 1995;6:3–10.

## Clinical Ophthalmology

### Publish your work in this journal

Clinical Ophthalmology is an international, peer-reviewed journal covering all subspecialties within ophthalmology. Key topics include: Optometry; Visual science; Pharmacology and drug therapy in eye diseases; Basic Sciences; Primary and Secondary eye care; Patient Safety and Quality of Care Improvements. This journal is indexed on

Submit your manuscript here: <http://www.dovepress.com/clinical-ophthalmology-journal>

Dovepress

PubMed Central and CAS, and is the official journal of The Society of Clinical Ophthalmology (SCO). The manuscript management system is completely online and includes a very quick and fair peer-review system, which is all easy to use. Visit <http://www.dovepress.com/testimonials.php> to read real quotes from published authors.