

Clostridium histolyticum (AA4500) for the Treatment of Adhesive Capsulitis of the Shoulder: A Randomised Double-Blind, Placebo-Controlled Study for the Safety and Efficacy of Collagenase – Single Site Report

This article was published in the following Dove Press journal:
Drug Design, Development and Therapy

Jane Fitzpatrick^{1,2}
Christen Richardson³
Ianiv Klaber⁴
Martin D Richardson¹

¹Centre for Health and Exercise Sports Medicine, School of Health Sciences, Faculty of Medicine, Dentistry and Health Sciences, University of Melbourne, Parkville, VIC, Australia; ²Joint Health Institute, Melbourne, VIC, Australia; ³Medical School, College of Health and Medicine, Australian National University, Acton, ACT, Australia; ⁴Orthopaedic Surgery Department, School of Medicine, Pontifical Catholic University of Chile, Santiago, Chile

Background/Hypothesis: Adhesive capsulitis of the shoulder results in pain and restricted movement of the glenohumeral joint. Hypothesis: There would be a difference in active range of movement in the affected shoulder of patients with adhesive capsulitis after receiving a series of injections of collagenase *Clostridium histolyticum* (CCH) compared to placebo.

Methods: This study reports the results from a single site that was part of a 321-participant, multicenter, double-blind, prospective parallel-group, randomized controlled clinical trial. Inclusion criteria: over 18 years of age, unilateral idiopathic adhesive capsulitis for >3 months, but <12 months. Exclusion criteria: recent physical therapy, injections, subacromial impingement, calcific tendonitis or glenohumeral joint arthritis in the affected shoulder. Subjects were randomized 3:1 to receive CCH 0.58 mg or placebo under ultrasound guidance. Injections were on days 1, 22, and 43. The primary outcome measure was a functional assessment of active range of movement.

Results: Overall, 37 patients were screened, 26 subjects were excluded, and 11 subjects were randomly assigned to the treatment group (n=9) or the control group (n=2). Both control and treatment groups showed improvement in ROM between baseline and day 95. In the treatment group, AROM improved from the baseline of 272.89° (SD 86.25) to 462.11° (SD 96.89) and the control group from 246.00° (SD 5.66) to 451.50° (SD 50.20) at day 95 with no statistical difference between groups p=0.78. Site data were in line with the whole study findings. Treatment-related adverse events at the injection site, including haematoma (bruising) and localised pain and swelling, were common.

Conclusion: Although the participants showed improvement in function, statistical significance was neither reached in the site nor the overall study cohort. Given the adverse events and the potential risks of the procedure, we would not recommend this drug for the treatment of adhesive capsulitis of the shoulder.

Level of Evidence: 2, cohort from one site of RCT.

Keywords: adhesive capsulitis, frozen shoulder, collagenase

Correspondence: Jane Fitzpatrick
Centre for Health and Exercise Sports Medicine, School of Health Sciences, Faculty of Medicine, Dentistry and Health Sciences, University of Melbourne, Level 7, Allan Gilbert Building, 161 Barry Street, Melbourne, VIC, Australia
Email jane.fitzpatrick@unimelb.edu.au

Plain Language Summary

Adhesive capsulitis is a condition of the shoulder joint which frequently results in a painful loss of movement. It has been difficult to treat and may last for many years. This study tested a new drug (which has been used in Dupuytren's contractures of the hand before) to see whether it could improve the movement in the affected shoulder of patients with adhesive capsulitis. The results showed improvement in both the patients who received the new drug

as well as those who had a placebo injection and shoulder exercises. It also showed substantial side effects at the shoulder of bruising. The authors feel they could not recommend the drug for the treatment of this condition.

Introduction

Background

Adhesive capsulitis (AC) or frozen shoulder is a musculoskeletal condition characterized by pain and restricted movement of the glenohumeral joint. Its reported incidence is 3–5% in the general population.⁸

Whilst it has been described as a condition of unknown aetiology, there are several risk factors described for adhesive capsulitis. These include female sex, age over 40 years, prolonged immobilisation of the shoulder, diabetes mellitus, thyroid disease, stroke, myocardial infarction, and autoimmune disease.¹⁰ The natural history of primary adhesive capsulitis is characterised by a gradual onset and progression of symptoms. Secondary adhesive capsulitis is generally caused by trauma, surgery or subsequent immobilisation, and the symptoms usually present soon after the traumatic incident.⁸

The diagnosis is made clinically, with symptoms of pain lying on the affected side and signs of restricted external rotation of the shoulder.¹²

Magnetic resonance imaging (MRI) scans demonstrating thickened synovium or capsule, adhesions within the subacromial or subdeltoid bursa, adhesions related to the long head biceps tendon or obliteration of the axillary fold secondary to adhesions are indicative of frozen shoulder.⁸ A high T2 intensity signal on MRI scan of the inferior glenohumeral ligament is also indicative of AC.¹⁰

The pathophysiology of AC is postulated to be an immunological response to an inflammatory synovitis which results in fibrosis of the capsule.¹² Manske, Prohaska⁸ described three distinct clinical phases in the progression of AC. The first termed the “freezing” (the inflammatory) stage is the most painful. This stage is characterised by acute synovitis of the glenohumeral joint, with a progressive loss of both active and passive range of movement (ROM) as the condition progresses. The second, “frozen” stage is characterised by restricted external rotation of the glenohumeral joint, with ongoing shoulder pain. The final, “thawing” stage is characterised by a gradual reduction in pain and some return of shoulder mobility.

Despite AC having a “benign prognosis” (most patients regain at least partial ROM) even with no medical

intervention, the long-lasting and profoundly debilitating course of the disease (up to 3 years) and the limited recovery of the ROM have motivated the pursuit of a myriad of treatment alternatives. Treatments are aimed at pain relief and restoration of ROM. Non-operative treatments include oral non-steroidal anti-inflammatory medications or corticosteroids, intra-articular glucocorticoid injections and capsular distention injections. Non-steroidal anti-inflammatory drugs have been shown to reduce pain in the freezing stage, although the effect is not sustained in the longer term.⁸ Intra-articular injections of glucocorticoids provide short-term relief and are typically performed as a sub-acromial or glenohumeral injection.⁸ Capsular distention injections or hydro-dilatation procedures involve stretching the capsule to its limits by injecting local anaesthetics, saline solution and glucocorticoids into the affected joint.⁷ Capsular distention has been shown to increase ROM, with the effect lasting over a year.¹⁵ Physiotherapy, whilst playing an important role post-operatively, has shown to offer little benefit when used as the sole treatment for AC.² Physiotherapy is best implemented once patients are beyond the painful freezing stage.⁶ Repeated nerve blocks of the suprascapular nerve have been shown to improve the quality of life and functional capacity of some patients.⁴

Surgical interventions are considered following failed conservative treatment. Manipulation under anaesthetic (MUA) or arthroscopic capsulotomy improves ROM and is enhanced by post-operative physiotherapy.⁵

As many of these treatments improve pain but not necessarily ROM, or offer a limited benefit in terms of ROM, there is a need to consider conservative treatments that may impact on both pain and function in the long term. A previous randomised controlled pilot study in 60 participants with AC had demonstrated that 53 participants improved their ROM after a series of collagenase *Clostridium histolyticum* (AA4500) injections.¹ Collagenase *Clostridium histolyticum* (CCH) is a combination of two collagenases (CCH-I and CCH-II) and is an FDA-approved enzymatic injection treatment for Dupuytren's contracture. It was postulated that the effects of CCH seen in Dupuytren's contracture may be similar if used for management of AC, providing in this case a clinically significant increase in the ROM.

This report describes the results from one site (including 11 participants) from a multi-centre trial of 321 participants looking at the effectiveness of a series of CCH injections for AC.

Objective

There would be a difference in active range of movement in the affected shoulder of patients with adhesive capsulitis after receiving a series of injection of CCH when compared to a placebo.

Methods

Trial Design

This study reports the results from a single site (Richmond, Australia) that was part of a multicenter double-blind prospective parallel-group randomised controlled clinical trial. The trial was registered with www.ClinicalTrials.gov NCT02006719 and received site ethics approval from Bellberry 2013–10-535. The subjects, Clinical Investigator (treating physician), and investigators examining the data were blinded to the treatment allocation and results until the end of the study following statistical analysis. Informed consent was obtained from participants and CONSORT guidelines followed. No changes were made to the trial design after commencement. The protocol is available in the [supplementary material](#).

Subject Selection

Participants were enrolled in the study from June 2014 – September 2014, if they were over 18 years of age and presented with symptoms of unilateral idiopathic adhesive capsulitis for at least 3 months, but not longer than 12 months. Inclusion criteria stated that participants were in the frozen or adhesive stage of the condition, as determined by the investigator. The affected shoulder must have had a restricted active range of total active movement (AROM) of at least 60° compared to the contralateral shoulder. Deficits in AROM had to be present in at least one of the following planes of movement: forward flexion, abduction, external rotation, and/or internal rotation.

The main exclusion criteria were physical therapy or acupuncture within 2 weeks before the first injection of the study drug; intra-articular or intra-bursal injections of lidocaine or sodium hyaluronate, suprascapular nerve blocks or glenohumeral distention arthrography within 3 months before the screening visit. Participants were also excluded if they presented with active subacromial impingement, calcified tendonitis or glenohumeral joint arthritis in the affected shoulder.

Participation was voluntary, and an informed consent agreement, approved by the Independent Ethics Committee, was signed prior to participation.

Randomization

Following screening and conformation of eligibility to participate in the study, patients were randomised 3:1 to receive CCH 0.58 mg or placebo. A central randomisation scheme with an interactive web response system was used by the trial coordinator.

Interventions

Participants were injected with either the CCH injection or a placebo (saline solution) under ultrasound guidance. Participants received up to three injections of study drug on days 1, 22, and 43 of the study. Each injection was separated by a minimum of 21 days and followed by a specified home exercise program which was demonstrated to the participants. The components of the study drug were: 0.9mg of collagenase *Clostridium histolyticum*, 0.5 mg of hydrochloric acid, 18.5 mg of sucrose and 1.1 mg of tromethamine diluted with calcium and sodium chloride solution. 1 mL of the product was injected anteriorly under ultrasound guidance using a 22 g Sprotte needle.

Both groups were given the same unsupervised home exercise regime with directed activity modification post-treatment without physiotherapist consultation.

Outcomes

The primary outcome measure was a functional assessment of active range of movement (AROM) and passive range of movement (PROM). Movements assessed were shoulder flexion, extension, external rotation, and internal rotation. The AROM used as our primary outcome measure was assessed by the treating Physician at screening, day 1, day 8, day 22, day 29, day 43, day 50, day 64, and day 95 (end of study). Compliance with the home exercise regime was recorded.

Sample Size

This study looks at the data set from a single site involving 11 participants, as part of a larger, multi-centre trial of 321 participants.

Blinding

This was a double-blinded study in which the investigator, patient, and other study personnel involved in the evaluation were blinded. The trial drug and placebo were identical in appearance, labelling and colour.

Statistical Methods

Statistical analysis was conducted on an intention-to-treat basis (ITT) using STATA version 13 (Stata Corp. 2013 Stata Statistical Software: Release 13. College Station, TX: Stata Corp LP). Treatment comparisons were based on the change in AROM on day 95, with significance at $P < 0.05$. Standard t-tests with equal variance were performed on day 95.

Results

Patient Study and Follow-Up

During the recruitment period, a total of 37 patients were assessed. 26 subjects were excluded, leaving 11 subjects

who randomly assigned to the treatment group ($n=9$) or the control group ($n=2$) and analysed by intention to treat. Figure 1 shows the flow of patients in the trial, none lost to follow-up. Table 1 shows the demographic data of the patients. The groups showed similar demographics in relation to age, body mass index (BMI), height, and weight.

Primary Outcome

Table 2 shows the mean range of motion (ROM) in total active range of movement (AROM), active external rotation (AER), and active forward flexion (AFF) for both the treatment and control group at baseline (day 0), 43 days, and 95 days.

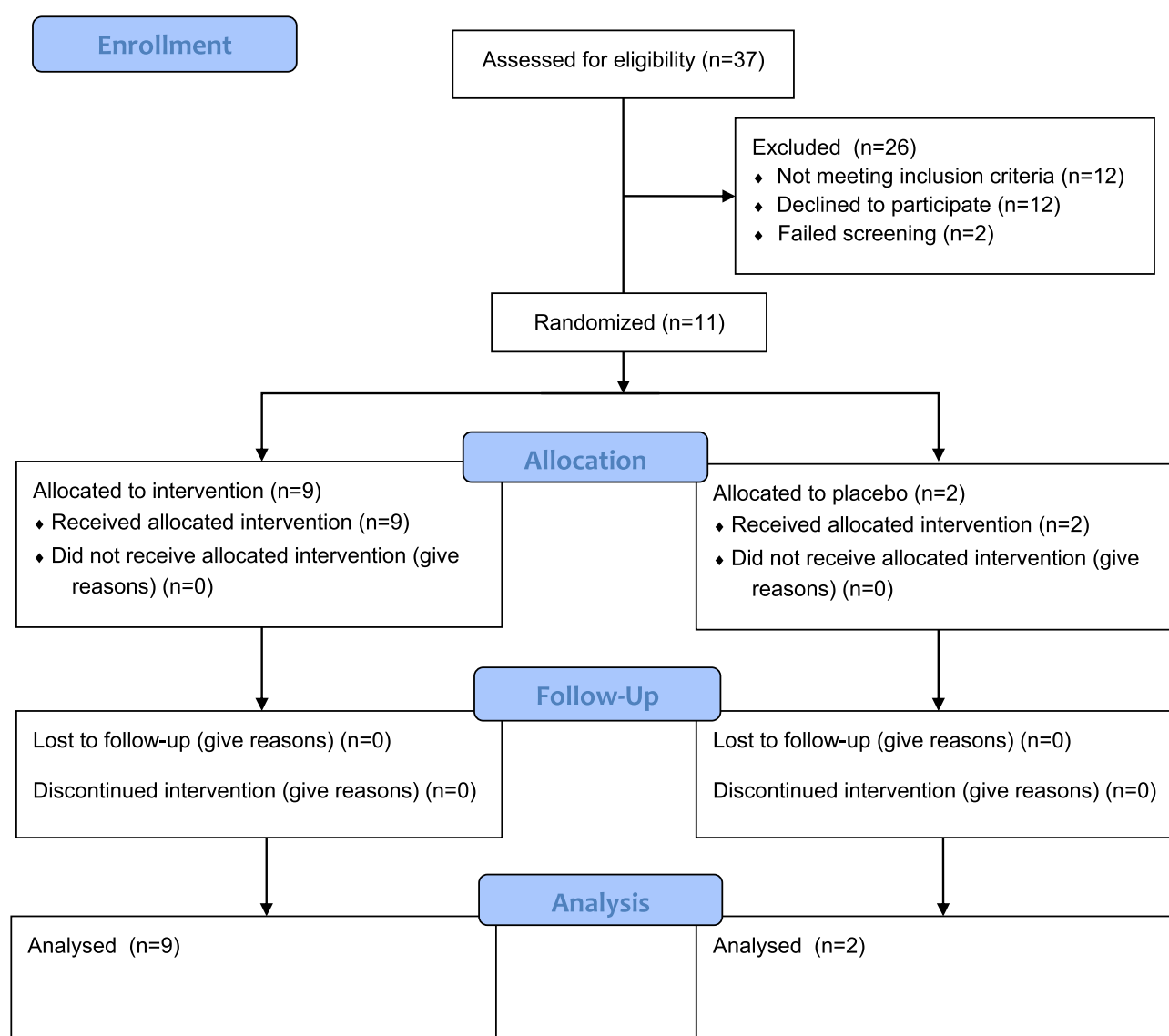


Figure 1 Consort flow diagram.

Abbreviation: n, number.

Table 1 Demographic Data of the Treatment and Control Groups

Characteristics	Treatment Group (n= 9)	Control Group (n=2)
Age , years mean, (range)	46.22 (32–55)	56 (49–63)
Sex n, (%)		
Male	1 (11.11)	0 (0)
Female	8 (88.89)	2 (100)
BMI , kg/m ² mean	25.71	25.29
Height, cm mean (SD)	170.19 (8.69)	165.3 (3.25)
Weight, kg mean (SD)	74.31 (9.62)	68.85 (1.20)

Abbreviations: n, number; SD, standard deviation; BMI, body mass index.

The mean AFF at baseline for the treatment group was 110.33° (SD 21.68), compared to the control group mean of 117.00° (SD 5). Both the control and treatment groups showed improvement in AFF over the course of the study. The means at day 43 for the treatment and control groups, respectively, were 161.33° (SD 20.83) and 154.00°. At day 95, the treatment group had a mean AFF of 167.33° (SD 21.12), while the control group had a mean of 173.50° (SD 1.50) $p=0.95$.

The mean AER at baseline for the treatment and control groups, respectively, were 43.56° (SD 25.62) and 26.00° (SD 1.41). At day 43, there was a difference in AER control 37° (SD-) and treated 77° (SD 26) $p=0.46$ but this was not sustained at day 95. The AER for the treatment group improved from 43.56° (SD 25.62) at baseline

to 84.78° (SD 24.85) at day 95 compared to the control group 26.00° (SD 1.41) at baseline and 86.50° (SD 6.36) at day 95.

The mean AROM at baseline for the treatment and control groups, respectively, were 272.89° (SD 86.25) and 246.00° (SD 5.66). At 43 days there was a difference in AROM with control group 300° (SD-) and treated group 430° (SD 94). This was not sustained at 95 days with treated group 462.11° (SD 96.89) and the control group 451.50° (SD 50.20) at 95 days, $p=0.78$.

Adverse Events

As previously reported¹ all participants who received CCH had treatment-related adverse events at the injection site, including haematoma (bruising) and localised pain and swelling. Table 3 shows the adverse events. Bruising was seen in 100% of the treated group and none of the control group. Of note was the extent of the bruising in 66% which extended from the sternum and involved the whole of the breast to the midline and the upper arm to the elbow. All participants had pain post-procedure – the difference was in the length of time analgesia was required with 88% of the treated group using analgesia including opioids beyond 24 hrs (Mean 78 hrs (24–288)) and none of the control group requiring analgesia beyond 12 hrs. There were no serious adverse events related to the study drug.

Table 2 Primary Outcome Measures at Baseline, 43 Days, and 95 Days

Time	Baseline	43 Days	95 Days
AROM , degrees mean (SD)			
Treatment group (n=9)	272.89 (86.25)	430.78 (94.04)	462.11 (96.89)
Control group (n=2)	246.00 (5.66)	300.00 (-)	451.50 (50.20)
AFF , degrees mean (SD)			
Treatment group	110.33 (21.68)	161.33 (20.83)	167.33 (21.15)
Control group	117.00 (5)	154.00 (-)	173.50 (1.50)
AER , degrees mean (SD)			
Treatment group	43.56 (25.62)	77.00 (26.09)	84.78 (24.85)
Control group	26.00 (1.41)	37.00 (-)	86.50 (6.36)

Abbreviations: AROM, total active range of movement; AFF, active forward flexion; AER, active external rotation; SD, standard deviation.

Table 3 Adverse Events

Description	Control Group N (%)	Treatment Group N (%)
Bruising		9 (100%)
Major to midline or elbow		6 (66%)
Minor localised		3 (33%)
Nil	2 (100%)	0 (0%)
Swelling localised	–	4 (44%)
Pins and needles or numbness	–	2 (22%)
Pain	2 (100%)	8 (88%)
Opioid analgesia	2 (100%)	8 (88%)
Other analgesia eg acetaminophen	–	5 (55%)
Duration of analgesia in hours	2 (100%)	8 (88%)
N (%) mean hours (Range in hours)	6 hours (4–8)	78 hours (24–288)

Abbreviations: N, number; %, percentage of total in group.

Discussion

This study compared the change in ROM in subjects with adhesive capsulitis of the shoulder treated with CCH compared to a placebo. The data showed no significant difference between the control and treatment groups. Of importance, the site data reflected the overall study data which also showed improvement in function but no statistical significance between the groups.¹¹ The function of both the control and treatment groups improved over the course of the study, suggesting that the home exercise program, completed by both groups, may improve functional outcomes in adhesive capsulitis of the shoulder. The natural history of the condition may have accounted for the improvement.⁸

The authors felt that it was important to report the findings of this study, even though there was a negative outcome. With any new treatment, it is important to assess effectiveness, but it is also important to consider whether there are potential harms associated with the new treatment. It is important to note that 100% of participants who received the CCH had substantial bruising at the injection site. This extended in some people from the sternum right across the chest wall and down the arm to the elbow. Whilst it is temporary, it is much more extensive than would have been expected from any other injection such as hyaluronic acid or glucocorticoid. This may be particularly important if the injections became more widely used particularly in a population who may be under anticoagulants and be expected to bruise more easily.

Many treatment strategies have been studied. Classical needle acupuncture has been shown to reduce shoulder pain scores, but only relieves the pain symptoms in the short term.¹⁴ Similarly, trigger point dry needling has demonstrated transitory improvements in range of motion and other functional outcomes, however, this requires multiple visits over a 6-week time-frame.³ Transcatheter arterial embolization has been trialled as a treatment after patients have shown resistance to other conservative treatments, and has been shown to reduce pain.⁹ Extracorporeal shockwave therapy has also been trialled as a treatment in diabetic patients with adhesive capsulitis of the shoulder, demonstrating an improvement in functional outcomes following treatment.¹³

A recent prospective randomized study compared the efficacy of 3 injection methods, intra-articular injection, subacromial injection, and hydrodilatation (HD), in the treatment of primary frozen shoulder.

The authors found benefit from the three with no difference at 6 months.¹⁶

The injection technique used required the use of a blunt needle (which could not penetrate the capsule of the glenohumeral joint) and the use of ultrasound guidance for accurate needle placement extra-articularly. Administering the intra-articular injection, there is a risk of damaging other structures within the joint, which may lead to other adverse events for the patient.

Taking into consideration these adverse events, and the lack of statistical significance in the benefit, we cannot recommend this treatment for patients with adhesive capsulitis of the shoulder.

The significant limitation of this study is the small sample size but this site report from the 321-patient study had similar results to that of the overall study.

Conclusion

Although the data in this study showed improvement in function over the course of the study, statistical significance was not reached in the site nor the overall study cohort. Given the adverse events and the potential risk in the procedure, we would not recommend this drug for the treatment of adhesive capsulitis of the shoulder unless further studies demonstrated more significant outcomes.

Data Sharing Statement

All data relating to this study site are presented in the manuscript. The full data for the study can be found in the [supplementary material](#).

Ethics

This study had site ethics approval from Bellberry 2013-10-535.

Author Contributions

CR wrote the first draft of this manuscript. JF, IK and MR were involved in the editing and final approval of the manuscript. All authors had unrestricted access to the data. JF, CR and MR were involved in the running of the trial site. All authors made substantial contributions to conception and design, acquisition of data, or analysis and interpretation of data; took part in drafting the article or revising it critically for important intellectual content; gave final approval of the version to be published; and agree to be accountable for all aspects of the work.

Funding

Funding was received for this study from Auxilium Pharmaceuticals USA.

Disclosure

JF, CR and MR were involved in the trial site and received payments for the running of the trial. IK did not receive funding. No authors declare any other conflict.

References

1. Badalamente MA, Wang ED. CORR((R)) ORS Richard A. Brand award: clinical trials of a new treatment method for adhesive capsulitis. *Clin Orthop Relat Res*. 2016;474(11):2327–2336. doi:10.1007/s11999-016-4862-8
2. Blanchard V, Barr S, Cerisola FL. The effectiveness of corticosteroid injections compared with physiotherapeutic interventions for adhesive capsulitis: a systematic review. *Physiotherapy*. 2010;96(2):95–107. doi:10.1016/j.physio.2009.09.003
3. Clewley D, Plyn TW, Koppenhaver S. Trigger point dry needling as an adjunct treatment for a patient with adhesive capsulitis of the shoulder. *J Orthop Sports Phys Ther*. 2014;44(2):92–101. doi:10.2519/jospt.2014.4915
4. Fernandes MR, Barbosa MA, Farla RM. Quality of life and functional capacity of patients with adhesive capsulitis: identifying risk factors associated to better outcomes after treatment with nerve blocking. *Braz J Rheumatol*. 2017;57(5):445–451
5. Kivimäki J, Pohjolainen T. Manipulation under anesthesia for frozen shoulder with and without steroid injection. *Arch Phys Med Rehabil*. 2001;82(9):1188–1190. doi:10.1053/apmr.2001.24169
6. Le HV, Lee SJ, Nazarian A, Rodriguez EK. Adhesive capsulitis of the shoulder: review of pathophysiology and current clinical treatments. *Shoulder Elbow*. 2017;9(2):75–84. doi:10.1177/1758573216676786
7. Lee DH, Yoon SH, Lee MY, Kwack KS, Rah UW. Capsule-preserving hydrodilatation with corticosteroid versus corticosteroid injection alone in refractory adhesive capsulitis of shoulder: a randomized controlled trial. *Arch Phys Med Rehabil*. 2016;97(12):e12.
8. Manske RC, Prohaska D. Diagnosis and management of adhesive capsulitis. *Curr Rev Musculoskelet Med*. 2008;1(3–4):180–189. doi:10.1007/s12178-008-9031-6
9. Okuno Y, Iwamoto W, Matsumura N, et al. Clinical outcomes of transcatheter arterial embolization for adhesive capsulitis resistant to conservative treatment. *J Vasc Interventional Radiol*. 2017;28(2):161–167. doi:10.1016/j.jvir.2016.09.028
10. Park S, Lee DH, Yoon SH, Lee HY, Kwack KS. Evaluation of adhesive capsulitis of the shoulder with fat-suppressed T2-weighted MRI: association between clinical features and MRI findings. *AJR Am J Roentgenol*. 2016;207(1):135–141. doi:10.2214/AJR.15.15200
11. Pharmaceuticals E Clinical study for the treatment of adhesive capsulitis of the shoulder (AC). October 5 2017. 2018. Available from: <https://clinicaltrials.gov/ct2/show/NCT02006719?type=Intr&cond=Adhesive+Capsulitis&intr=Collagenase&rank=1>. Accessed November 13, 2018.
12. Ryan V, Brown H, Minns Lowe CJ, Lewis JS. The pathophysiology associated with primary (idiopathic) frozen shoulder: a systematic review. *BMC Musculoskelet Disord*. 2016;17(1):340. doi:10.1186/s12891-016-1190-9
13. Santoboni F, Balducci S, D'Errico V, et al. Extracorporeal shockwave therapy improves functional outcomes of adhesive capsulitis of the shoulder in patients with diabetes. *Diabetes Care*. 2017;40(2):e12–e13. doi:10.2337/dc16-2063
14. Schröder S, Meyer-Hamme G, Friedemann T, et al. Immediate pain relief in adhesive capsulitis by acupuncture—a randomized controlled double-blinded study. *Pain Med*. 2017;1–13.
15. Vlad VB, Sakalkale D, Warren RF. The role of capsular distention in adhesive capsulitis. *Arch Phys Med Rehabil*. 2003;84(9):1290–1292. doi:10.1016/s0003-9993(03)00261-2
16. Yoon JP, Chung SW, Kim J, et al. Intra-articular injection, subacromial injection, and hydrodilatation for primary frozen shoulder: a randomized clinical trial. *J Shoulder Elbow Surg*. 2016;25(3):376–383. doi:10.1016/j.jse.2015.11.009

Drug Design, Development and Therapy

Dovepress

Publish your work in this journal

Drug Design, Development and Therapy is an international, peer-reviewed open-access journal that spans the spectrum of drug design and development through to clinical applications. Clinical outcomes, patient safety, and programs for the development and effective, safe, and sustained use of medicines are a feature of the journal, which has also

been accepted for indexing on PubMed Central. The manuscript management system is completely online and includes a very quick and fair peer-review system, which is all easy to use. Visit <http://www.dovepress.com/testimonials.php> to read real quotes from published authors.

Submit your manuscript here: <https://www.dovepress.com/drug-design-development-and-therapy-journal>