

Inhibition of angiogenesis as a new therapeutic target in the treatment of lepromatous leprosy

Mohamed El-Khalawany¹
Dalia Shaaban²
Maha Sultan¹
Fatma Abd AlSalam¹

¹Departments of Dermatology, Faculty of Medicine, Al-Azhar University, Cairo, ²Department of Dermatology, Faculty of Medicine, Tanta University, Gharbia, Egypt

Background: Angiogenesis was suggested to have a significant role in the pathogenesis of leprosy. However, the benefit of inhibiting angiogenesis in lepromatous leprosy patients has not previously been studied. The purpose of this study was to evaluate angiogenesis in leprosy patients before and after treatment with multidrug therapy (MDT) with and without minocycline.

Methods: A total of 40 patients with lepromatous leprosy were enrolled in this study. They were categorized into two equal groups (A and B), each formed of 20 patients. Group A received World Health Organization MDT, and Group B received MDT combined with minocycline, which has a known antiangiogenic effect. Microvascular density (MVD) in dermal granuloma was evaluated in both groups by immunostaining with CD31 and CD34 markers before and after 6 months of treatment.

Results: With CD31 immunostaining, the mean MVD in Group A significantly decreased from 39.1 ± 3.1 vessels (v)/high power field (HPF) to 16.5 ± 2.7 v/HPF, and in Group B it significantly decreased from 38.3 ± 2.5 v/HPF to 7.6 ± 1.9 v/HPF. CD34 immunostaining also showed a significant decrease of MVD from 42.2 ± 3.1 v/HPF to 18.8 ± 2.4 v/HPF in Group A, and in Group B it significantly decreased from 43.7 ± 2.3 v/HPF to 11.5 ± 1.6 v/HPF. The reduction of MVD was significantly higher in Group B compared with in Group A ($P < 0.0001$). Moreover, there was a significant reduction in bacterial density (assessed by bacterial index) in the cutaneous lesions of in Group B (decreased from 4.9 ± 0.3 to 1.4 ± 0.2) compared with in Group A (decreased from 5.1 ± 0.4 to 2.3 ± 0.4).

Conclusion: The synergistic effect of MDT and minocycline seems to be promising in the treatment of lepromatous leprosy. It significantly reduces angiogenesis and rapidly eliminates lepra bacilli from the skin that enables a rapid control and elimination of the disease.

Keywords: leprosy, angiogenesis, minocycline

Introduction

Leprosy is a well-known chronic infectious disease that is caused by *Mycobacterium leprae* (*M. leprae*). It has a spectrum of cutaneous responses ranging from tuberculoid to lepromatous poles. The incidence of leprosy has declined worldwide after the introduction of multidrug therapy (MDT) by the World Health Organization (WHO) in 1982;¹ however, it is still a public health problem in many countries, which have a high rate of endemic infection.² This was an indicator to modify or change WHO MDT, aiming at a more effective, safe, compliant, and shorter-duration regimen that is free from the fear of the emergence of resistant lepra bacilli.³

Advances in, and deep understanding of, immunology, pathogenesis, and genetics of leprosy could improve the ability to fight against this potentially devastating

Correspondence: Mohamed El-Khalawany
Department of Dermatology, Faculty of Medicine, Al-Azhar University, Cairo, Egypt
Tel +20 100 5405120
Fax +20 22 5128989
Email makhalawany@gmail.com

infectious disease and may lead to the development of better protocols for treatment and prevention of the disease.⁴ The status of dermal vasculature was considered an important underlying pathogenic factor in leprosy, and the study of dermal vascular changes in leprosy was a matter of interest in previous reports.⁵ It was observed that there is narrowing, tortuosity, dilatation, or occlusion of the skin's blood vessels of lepromatous leprosy patients, especially those located in the extremities.⁶

It was proposed that there are two microvascular architectural patterns observed in cutaneous lesions of leprosy: a dense and tortuous mesh of microvessels among the granulomatous infiltrate in lepromatous leprosy and a microvessel network restricted to the periphery of the granulomas in tuberculoid leprosy.⁷ Moreover, the proliferation and migration of endothelial cells result in the formation of new blood vessels from pre-existing vessels, a process that is known as angiogenesis, which has also been studied in leprosy. It was proposed that there is a significant correlation between angiogenesis and bacterial load in cutaneous lesions of lepromatous patients.⁸

In this study we assessed angiogenesis in lepromatous leprosy patients before and after treatment with MDT alone and in combination with minocycline, a drug known to have an antiangiogenic effect. Moreover, we correlated the changes in angiogenesis with the changes in bacterial density (BD) in the same cutaneous lesions.

Materials and methods

A multicenter study was carried out on 40 lepromatous leprosy patients recruited from the outpatient clinics of the Dermatology Departments in Al-Hussein, Tanta, and Al-Zahraa university hospitals, Egypt. The study was approved by the local ethical committee.

Patient selection and grouping

All the patients included were newly diagnosed, and none of them had received any treatment for leprosy prior to the commencement of the study. The diagnosis of leprosy was based on the clinical presentation of bilateral, symmetrical, nonscaly erythematous nodular skin lesions, which was confirmed by the detection of *M. leprae* in direct nasal or slit skin smear. Exclusion criteria included pregnancy, lactation, known hypersensitivity to any of the therapeutic drugs, and serious illness or bad general condition. Written consent was signed by each patient after full explanation of the nature of the study, expected benefits of treatment, and possible side effects.

Patients were categorized into two equal groups (A and B). Group A (n = 20) received WHO MDT in the form of monthly

observed doses of rifampicin (600 mg) and clofazimine (300 mg) and an unobserved daily dose of dapsone (100 mg) and clofazimine (50 mg). Group B (n = 20) received WHO MDT therapy in addition to a monthly observed dose of minocycline (100 mg). Treatment was continued for 6 months.

Skin biopsy and processing

A 4 mm punch biopsy was taken from each patient before treatment and 6 months after. The first biopsy was usually taken from the largest nodular lesion, and the second biopsy was taken from nearly the same site. From each specimen, four sections (4 μ m thick) were prepared – one for routine hematoxylin and eosin staining for diagnosis and evaluation of the granulomatous reaction, one for modified Ziehl-Neelsen stain (Wade-Fite method) to record the BD (assessed by bacterial index [BI]), and two for immunohistochemical staining with anti-CD31 and anti-CD34 monoclonal antibodies to assess microvascular density (MVD).

Immunohistochemical staining

Immunohistochemical staining was performed using an avidin-biotin peroxidase complex method on formalin-fixed, paraffin-embedded tissue sections,⁹ using a 1/50 dilution of monoclonal CD31 and CD34 antibodies (Dako, Glostrup, Denmark). Briefly, tissue sections were mounted on 3-aminopropyl-triethoxysilane-coated slides and dried overnight at room temperature. Subsequently, they were dewaxed in xylene and rehydrated in graded ethanol. After being rinsed with phosphate buffered saline, they were immersed in 0.01 mol/L citric acid titrated to pH 6.0 and heated twice for 10 minutes in a microwave oven. The primary antibodies were then incubated on the sections for 30 minutes. Diaminobenzidine was used as a chromagen, and the slides were counterstained with Mayer's hematoxylin.

Microvessel density was assessed by immunostaining for CD31 and CD34 according to Weidner.¹⁰ Areas with higher vascularity (so-called hot-spots) were located at low magnification ($\times 40$) and then were counted at $\times 400$ magnification. Each positive endothelial cell or group of cells in contact with a spot was counted as an individual vessel. The mean vessel count from three fields was used as CD34 microvessel density or CD31 microvessel density. The assessment of both BD and MVD was performed only in the dermal granuloma without assessment of the stromal changes.

Microscopic evaluation

BD in each Wade-Fite stained specimen was assessed by BI following Ridley's logarithmic scale (from 1 to 6).

The number of solid staining (viable) lepra bacilli was visually calculated in ten different high power fields (HPF), and the mean \pm standard deviation (SD) was recorded.

Statistical analysis

For quantitative data, the mean and SD were calculated. The difference between means was statistically analyzed using the Student's *t*-test. $P < 0.05$ was considered statistically significant.

Follow-up of the patients

Follow-up of the patients was done monthly for observation of the monthly doses of treatment and recording of any side effects, complications, or lepra reaction. We reported two patients in Group A who developed erythema nodosum leprosum during the first month of treatment (2 and 3 weeks, respectively). The treatment was continued in both patients with the addition of oral corticosteroids (40 mg daily for 15 days then gradually withdrawn). Both patients showed significant relief of symptoms within 3 weeks. In Group B, no significant side effects or complications were encountered during the treatment period.

Results

Clinical data and direct smear

Group A included 16 males and four females. Their ages ranged from 25 years to 53 years with a mean of 32 ± 4.5 years. Group B included 13 males and seven females. Their ages ranged from 28 years to 49 years with a mean of 34 ± 2.5 years. The duration of the disease ranged from 3 weeks to 11 months with a mean of 14 ± 3 weeks. In 29 patients (72.5%) skin lesions were located on the trunk and extremities, whereas in eleven patients (27.5%) the lesions were distributed mainly on the extremities. Facial involvement was reported in 13 patients (32.5%) and nerve thickening in 27 patients (67.5%). *M. leprae* were detected in 16 patients (40%) by nasal smear and in 24 patients (60%) by slit skin smears.

Microvascular density

CD31 immunohistochemistry

In Group A, the MVD (number of vessels [v]/HPF) ranged from 35 v/HPF to 43 v/HPF with a mean of 39.1 ± 3.1 before treatment, whereas after treatment the MVD decreased to 16.5 ± 2.7 (ranged from 13 v/HPF to 19 v/HPF). This reduction was statistically highly significant ($P < 0.001$) (Table 1). In Group B, the MVD ranged from 35 v/HPF to 46 v/HPF with a mean of 38.3 ± 2.5 before treatment,

Table 1 CD31 and CD34 immunostaining and BI before and after treatment in group A

Marker	Before treatment	After treatment	P-value
CD31 (v/HPF)			
Range	35–43	13–19	<0.001 ^a
M ± SD	39.1 ± 3.1	16.5 ± 2.7	
CD34 (v/HPF)			
Range	37–46	15–23	<0.001 ^a
M ± SD	42.2 ± 3.1	18.8 ± 2.4	
BI			
Range	4–6	1–2	<0.001 ^a
M ± SD	5.1 ± 0.4	2.3 ± 0.4	

Note: ^a*P* is significant at <0.05 .

Abbreviations: BI, bacterial index; M, mean; SD, standard deviation, v/HPF, vessel/high power field.

which decreased to 7.6 ± 1.9 after treatment (ranged from 5 v/HPF to 10 v/HPF). This reduction was statistically highly significant ($P < 0.001$) (Table 2).

CD34 immunohistochemistry

In Group A, the mean MVD significantly decreased from 42.2 ± 3.1 before treatment (Figure 1A) to 18.8 ± 2.4 after treatment (Figure 1B) (Table 1). In Group B, the mean MVD significantly decreased from 43.7 ± 2.3 before treatment (Figure 2A) to 11.5 ± 1.6 after treatment (Figure 2B) (Table 2). There was a statistically significant higher reduction ($P < 0.001$) in angiogenesis evaluated by both CD31 and CD34 markers in Group B compared with in Group A (Table 3).

Bacterial density

In Group A, BI ranged from 4 (10–100 bacilli/HPF) to 6 (>1000 bacilli/HPF) with a mean of 5.1 ± 0.4 before treatment, which was significantly decreased to 2.3 ± 0.4 after treatment (Table 1). In Group B, the mean BI significantly decreased from 4.9 ± 0.3 before treatment (Figure 3A) to

Table 2 CD31 and CD34 immunostaining and BI before and after treatment in Group B

	Before treatment	After treatment	P-value
CD31 (v/HPF)			
Range	35–46	5–10	<0.001 ^a
M ± SD	38.3 ± 2.5	7.6 ± 1.9	
CD34 (v/HPF)			
Range	40–48	8–13	<0.001 ^a
M ± SD	43.7 ± 2.3	11.5 ± 1.6	
BI			
Range	4–6	0–1	<0.001 ^a
M ± SD	4.9 ± 0.3	1.4 ± 0.2	

Note: ^a*P* is significant at <0.05 .

Abbreviations: BI, bacterial index; M, mean; SD, standard deviation, v/HPF, vessel/high power field.

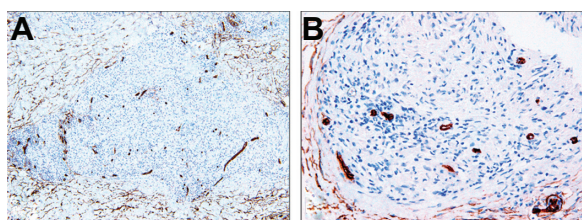


Figure 1 CD34 immunostaining (Group A) shows high microvessel density before treatment (A) that decreased after treatment (B) ($\times 100$ and $\times 400$).

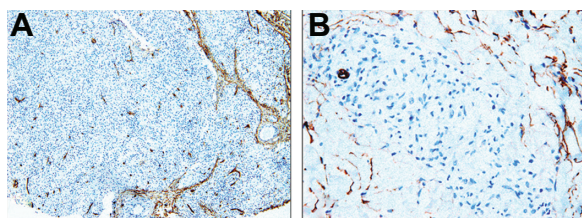


Figure 2 CD34 immunostaining (Group B) shows high microvessel density before treatment (A) that significantly decreased after treatment (B) ($\times 100$ and $\times 400$).

1.4 ± 0.2 after treatment (Figure 3B) (Table 2). There was a statistically significant higher reduction ($P < 0.001$) in BD in Group B compared with in Group A (Table 3).

Discussion

Angiogenesis is considered to be a fundamental event in many conditions. The major role of angiogenesis was reported in relation to neoplastic conditions and malignancies that need an ongoing blood supply to grow and expand.¹¹ Abnormal angiogenesis was also implicated in other conditions such as rheumatoid arthritis, inflammation, and degenerative eye conditions, in addition to many biological processes such as development, reproduction, and wound repair.¹² In dermatological disorders, angiogenesis

was implicated mainly in psoriasis,¹³ and to a lesser extent in skin aging and photoaging.¹⁴

Drugs that inhibit angiogenesis were used primarily in the treatment of malignancy. The role of these antiangiogenic or antivascular therapies in the treatment of cancer became important after the establishment of the relationship between angiogenesis and tumor growth.¹⁵ Inhibition of angiogenesis growth factors and transfer of antiangiogenesis genes were proposed as basic mechanisms of antiangiogenic drugs.¹⁶ The target receptors of antiangiogenic drugs include PtdIns-4,5-P2 that regulate vessel stability,¹⁷ vascular endothelial growth factor receptor key proteins,¹⁸ and Cap43 calcium-inducible genes.¹⁹

There are certain drugs which have an antiangiogenic effect and are used in the treatment of some skin diseases, such as chloroquine, which was suggested to have a beneficial effect in the treatment of discoid lupus erythematosus due to its antiangiogenic properties.²⁰ Thalidomide also has an antiangiogenic effect and is currently used in the treatment of different dermatological conditions including lepra reaction,²¹ sclerodermatous cutaneous reaction of graft versus host disease,²² and Jessner's lymphocytic infiltration of the skin.²³

Recently, rifampicin, which is a component of MDT for leprosy, was suggested to have promising antiangiogenic effects that may enable its use as an effective antitumor agent.²⁴ Minocycline was also reported as one of the drugs that inhibit angiogenesis,²⁵ and it is known to have an important role in the treatment of leprosy as a main component of rifampicin, ofloxacin, and minocycline (ROM) therapy.²⁶ However, the mechanism of action of both drugs in the treatment of leprosy remains unclear. Is it due to their antimicrobial effect only or due also to their antiangiogenic effect?

Table 3 CD31 and CD34 immunostaining and BI before and after treatment in both groups

	Group A (n = 20)	Group B (n = 20)	P-value
CD31 (v/HPF)			
Before treatment	39.1 ± 3.1	38.3 ± 2.5	0.37
After treatment	16.5 ± 2.7	7.6 ± 1.9	$<0.001^a$
CD34 (v/HPF)			
Before treatment	42.2 ± 3.1	43.7 ± 2.3	0.09
After treatment	18.8 ± 2.4	11.5 ± 1.6	$<0.001^a$
BI			
Before treatment	5.1 ± 0.4	4.9 ± 0.3	0.08
After treatment	2.3 ± 0.4	1.4 ± 0.2	$<0.001^a$

Note: ^aP is significant at <0.05 .

Abbreviations: BI, bacterial index; M, mean; SD, standard deviation, v/HPF, vessel/high power field.

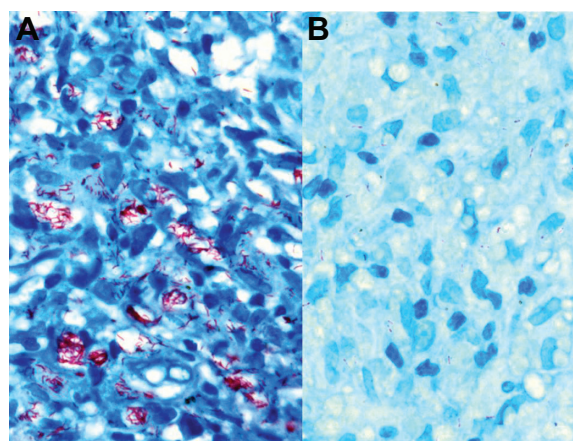


Figure 3 Fite stain (Group B) shows higher density of viable and intact *Mycobacterium leprae* before treatment (A) compared with a few and fragmented bacilli after treatment (B) ($\times 1000$).

To our knowledge, no previous studies have evaluated the efficacy of these antiangiogenic drugs on angiogenesis in cutaneous lesions of lepromatous leprosy patients, but a few studies monitor angiogenesis in the spectrum of leprosy. Bhandarkar et al⁸ studied angiogenesis in 32 leprosy patients using CD31 as a marker for microvessel density. The MVD of lepromatous leprosy lesions was (44.0 ± 9.8 v/HPF). We found a lower MVD value with a CD31 marker in lepromatous leprosy (39.1 ± 3.1 in Group A and 38.3 ± 2.5 in Group B), and with a CD34 marker we found a higher value (42.2 ± 3.1 in Group A and 43.7 ± 2.3 in Group B), which was close to that encountered by Bhandarkar et al. This may suggest the benefit of using more than one marker (CD31, CD34) in the assessment of angiogenesis.

Kim et al²⁷ also found a significant increase of MVD in lepromatous leprosy lesions compared with in normal skin, with an overall increase in the mean number of vessels from tuberculoid leprosy through borderline (tuberculoid and lepromatous) to lepromatous leprosy lesions. The MVD values in lepromatous leprosy were higher (104.40 ± 27.71) compared with our results. This can be explained by the use of a different vascular marker (Factor VIII-related antigen) or a different counting system.

These studies suggested that angiogenesis could be evaluated by using different vascular markers. In the current study we preferred to use two markers (CD31 and CD34) in the assessment of angiogenesis for proper evaluation of MVD and to minimize false positive results. Both CD31 and CD34 are known as effective markers in identifying blood vessels and were proposed also to be good prognostic markers of neoangiogenesis.^{28,29}

The significant reduction of MVD and BD in Group A, which was treated with MDT, may prove the possible antiangiogenic effect of rifampicin in addition to its antimicrobial effect. Rifampicin was suggested to exert its antiangiogenic effect through inhibition of the expression of angiogenesis-associated genes with downregulation of proangiogenic genes and inhibition of microvascular endothelial cell proliferation.²⁴ In a manner comparable with the action of endostatin, the endogenous angiogenesis inhibitor is known to downregulate a variety of growth and angiogenesis-related genes in a wide range of endothelial lineage cells.³⁰

In Group B, minocycline 100 mg, which is known to have antiangiogenic properties, was added to MDT as a monthly dose, aiming to potentiate the antiangiogenic efficacy of the classic MDT regimen. Although minocycline has different mechanisms of action from its antimicrobial

properties, such as inhibition of collagenase activity,³¹ and its anti-inflammatory effect through reduction of cytokines and pro-inflammatory protein expression,³² it also possesses inhibitory properties of angiogenesis.²⁵ This antiangiogenic effect of minocycline may contribute to the direct inhibition of matrix metalloproteinase activity and also to the inhibition of vascular endothelial growth factor-induced smooth muscle cell migration.³³

In the present work the reduction of MVD was significantly higher in Group B than in Group A using both markers. These results may suggest the presence of a synergistic effect of both minocycline and rifampicin as antiangiogenic drugs in addition to their antimicrobial effect. Moreover, the absence of any side effects or lepra reaction in Group B compared with in Group A may add a new benefit for the combination of MDT with minocycline.

Another important finding in this work is the significantly higher reduction in BI in Group B compared with in Group A. This may suggest that the addition of minocycline to the MDT can cause a more rapid elimination of lepra bacilli from cutaneous lesions of lepromatous leprosy patients. This rapid elimination of lepra bacilli from cutaneous lesions and also from mucous membranes is helpful in decreasing the transmission of the disease and maintaining the standard target of elimination of leprosy.

Conclusion

To our knowledge, this is the first work that assesses angiogenesis in leprosy patients after treatment with antiangiogenic drugs. The synergistic antiangiogenic effect of both minocycline and rifampicin was found to be promising and effective in the treatment of leprosy. Moreover, this combination showed an advantage of rapid elimination of *M. leprae* from the cutaneous lesions of lepromatous leprosy patients and decreased the possibility of the occurrence of lepra reaction. We hope that this regimen will be considered in wide-scale studies, especially in endemic areas of leprosy.

Disclosure

The authors report no conflicts of interest in this work.

References

1. Noordeen SK. Elimination of leprosy as a public health problem: progress and prospects. *Bull World Health Organ.* 1995;73:1–6.
2. Lockwood DN, Suneetha S. Leprosy: too complex a disease for a simple elimination paradigm. *Bull World Health Organ.* 2005;83:230–235.
3. Gautam VP. Treatment of leprosy in India. *J Postgrad Med.* 2009;55:220–224.
4. Gulia A, Fried I, Massone C. New insights in the pathogenesis and genetics of leprosy. *F1000 Med Rep.* 2010;2:30.

5. Chopra JS, Kaur S, Murthy JM, et al. Vascular changes in leprosy and its role in the pathogenesis of leprosy neuritis. *Lepr India*. 1981;53:443–453.
6. Yadav SS. Arteriographic evaluation of vascular changes in leprosy. *Angiology*. 1978;29:17–21.
7. Antunes SL, Motta E, de Almeida SM, Gallo ME, Nery JA, Lenzi HL. Distinct patterns of microvasculature in the cutaneous lesions of leprosy. *Int J Lepr Other Mycobact Dis*. 2000;68:143–151.
8. Bhandarkar SS, Cohen C, Kuruvila M, Rea TH, Mackelfresh JB, Lee DJ, et al. Angiogenesis in cutaneous lesions of leprosy: implications for treatment. *Arch Dermatol*. 2007;143:1527–1529.
9. Hsu SM, Raine L, Fanger H. Use of avidin-biotin-peroxidase complex (ABC) in immunoperoxidase techniques: a comparison between ABC and unlabeled antibody (PAP) procedures. *J Histochem Cytochem*. 1981;29:577–580.
10. Weidner N. Current pathologic methods for measuring intratumoral microvessel density within breast carcinoma and other solid tumors. *Breast Cancer Res Treat*. 1995;36:169–180.
11. Folkman J. Tumor angiogenesis: therapeutic implications. *N Engl J Med*. 1971;285:1182–1186.
12. Otrick ZK, Mahfouz RA, Makarem JA, Shamseddine AI. Understanding the biology of angiogenesis: review of the most important molecular mechanisms. *Blood Cells Mol Dis*. 2007;39:212–220.
13. Chua RA, Arbiser JL. The role of angiogenesis in the pathogenesis of psoriasis. *Autoimmunity*. 2009;42:574–579.
14. Chung JH, Eun HC. Angiogenesis in skin aging and photoaging. *J Dermatol*. 2007;34:593–600.
15. Stacker SA, Achen MG. From anti-angiogenesis to anti-lymphangiogenesis: emerging trends in cancer therapy. *Lymphat Res Biol*. 2008;6:165–172.
16. Liu CC, Shen Z, Kung HF, Lin MC. Cancer gene therapy targeting angiogenesis: an updated review. *World J Gastroenterol*. 2006;12:6941–6948.
17. Im E, Kazlauskas A. PtdIns-4,5-P2 as a potential therapeutic target for pathologic angiogenesis. *Expert Opin Ther Targets*. 2007;11:443–451.
18. Kiselyov A, Balakin KV, Tkachenko SE. VEGF/VEGFR signalling as a target for inhibiting angiogenesis. *Expert Opin Investig Drugs*. 2007;16:83–107.
19. Nishio S, Ushijima K, Tsuda N, Takemoto S, Kawano K, Yamaguchi T, et al. Cap43/NDRG1/Drg-1 is a molecular target for angiogenesis and a prognostic indicator in cervical adenocarcinoma. *Cancer Lett*. 2008;264:36–43.
20. Lesiak A, Narbutt J, Kobos J, et al. Systematic administration of chloroquine in discoid lupus erythematosus reduces skin lesions via inhibition of angiogenesis. *Clin Exp Dermatol*. 2009;34:570–575.
21. Jakeman P, Smith WC. Thalidomide in leprosy reaction. *Lancet*. 1994;343:432–433.
22. Pédaillès S, Troussard X, Launay V, Bazin A, Sentias C, Surbled M. Sclerodermatous cutaneous reaction of graft vs host disease treated with thalidomide. *Presse Med*. 1993;22:37.
23. Guillaume JC, Moulin G, Dieng MT, Poli F, Morel P, Souteyrand P, et al. Crossover study of thalidomide vs placebo in Jessner's lymphocytic infiltration of the skin. *Arch Dermatol*. 1995;131:1032–1035.
24. Shichiri M, Fukai N, Kono Y, Tanaka Y. Rifampicin as an oral angiogenesis inhibitor targeting hepatic cancers. *Cancer Res*. 2009;69:4760–4768.
25. Tamargo RJ, Bok RA, Brem H. Angiogenesis inhibition by minocycline. *Cancer Res*. 1991;51:672–675.
26. Suneetha S, Reddy R. Histological resolution and bacterial clearance with pulse ROM therapy in borderline lepromatous leprosy. *Int J Lepr Other Mycobact Dis*. 2001;69:53–54.
27. Kim BS, Park SD, Kim JP. Angiogenesis according to clinical forms in leprosy. *Korean J Dermatol*. 2010;48:278–282.
28. Tachezy M, Reichelt U, Melenberg T, Gebauer F, Izbickei JR, Kaifi JT. Angiogenesis index CD105 (endoglin)/CD31 (PECAM-1) as a predictive factor for invasion and proliferation in intraductal papillary mucinous neoplasm (IPMN) of the pancreas. *Histol Histopathol*. 2010;25:1239–1246.
29. Inda AM, Andrini LB, García MN, García AL, Fernández Blanco A, Furnus CC, et al. Evaluation of angiogenesis with the expression of VEGF and CD34 in human non-small cell lung cancer. *J Exp Clin Cancer Res*. 2007;26:375–378.
30. Abdollahi A, Hahnfeldt P, Maercker C, Gröne HJ, Debus J, Ansorge W, et al. Endostatin's antiangiogenic signaling network. *Mol Cell*. 2004;13:649–663.
31. Golub LM, McNamara TF, D'Angelo G, Greenwald RA, Ramamurthy NS. A non-antibacterial chemically-modified tetracycline inhibits mammalian collagenase activity. *J Dent Res*. 1987;66:1310–1314.
32. Dunston CR, Griffiths HR, Lambert PA, Staddon S, Vernallis AB. Proteomic analysis of the anti-inflammatory action of minocycline. *Proteomics*. 2011;11:42–51.
33. Yao JS, Chen Y, Zhai W, Xu K, Young WL, Yang GY. Minocycline exerts multiple inhibitory effects on vascular endothelial growth factor-induced smooth muscle cell migration: the role of ERK1/2, PI3K, and matrix metalloproteinases. *Circ Res*. 2004;95:364–371.

Clinical, Cosmetic and Investigational Dermatology

Publish your work in this journal

Clinical, Cosmetic and Investigational Dermatology is an international, peer-reviewed, open access, online journal that focuses on the latest clinical and experimental research in all aspects of skin disease and cosmetic interventions. All areas of dermatology will be covered; contributions will be welcomed from all clinicians and

basic science researchers globally. This journal is indexed on CAS. The manuscript management system is completely online and includes a very quick and fair peer-review system, which is all easy to use. Visit <http://www.dovepress.com/testimonials.php> to read real quotes from published authors.

Submit your manuscript here: <http://www.dovepress.com/clinical-cosmetic-and-investigational-dermatology-journal>