

# Virtual retinectomy: indocyanine green-assisted internal limiting membrane peeling as a surgical adjunct in repair of recurrent rhegmatogenous retinal detachment due to PVR

John R Minarcik  
Manfred A von Fricken

Ophthalmology, Georgetown/  
Washington Hospital Center, Retina  
Group of Washington, Fairfax, VA, USA

**Background:** The purpose of this study was to describe and evaluate a surgical approach, known as internal limiting membrane (ILM) peeling, as an adjunct to repair of recurrent retinal detachment due to proliferative vitreoretinopathy (PVR).

**Methods:** This was a retrospective case series. All eyes underwent repair of recurrent PVR-related rhegmatogenous retinal detachment incorporating macular indocyanine green-assisted ILM peeling. Patients with primary detachments, diabetes, staphyloma, or macular holes were excluded. The main outcome measure was the anatomic success of single surgery. The characteristics of the group were studied, including the number and types of previous detachment repair attempts, as well as the subsequent surgeries.

**Results:** Fourteen eyes from 14 patients were included. Anatomic success with single surgery was achieved in 11 of 14 (79%) of the operated eyes using this technique, and eventual success was achieved in all eyes (100%). Among the failed repairs prior to ILM peeling, 8/14 eyes had scleral buckles, 7/14 had silicone oil tamponade, and two had inferior retinectomies. There was no subsequent development of epiretinal membranes after ILM peeling.

**Conclusion:** ILM peeling in conjunction with vitrectomy and peeling of peripheral membranes is an effective technique with a high anatomic success rate in the challenging scenario of PVR-related recurrent detachments. We describe the technique as an alternative to the traditional retinectomy.

**Keywords:** internal limiting membrane, retinal detachment, proliferative vitreoretinopathy, retinectomy, surgical technique

## Introduction

Proliferative vitreoretinopathy (PVR) is the leading cause of failure of retinal detachment surgery.<sup>1-3</sup> Its recurrent nature can lead to redetachment, multiple surgeries, and even total loss of vision and phthisis.<sup>1</sup> Many approaches are employed as a means of reducing retinal traction caused by preretinal and subretinal proliferative membranes. The approaches range from membrane peeling to removal of tense retinal tissue.<sup>1,4</sup> In extreme situations, a retinectomy or circumferential excision of the retina is performed to allow reapposition of the neurosensory retina.<sup>5-11</sup> Recent studies report single surgery success rates ranging from 60% to 87% with traditional retinectomy and relaxing retinotomy in PVR cases.<sup>12-14</sup> Because of the sometimes problematic after effects associated with retinectomy, such as the frequent necessity for long-term silicone oil tamponade, recurrent PVR, hypotony,

Correspondence: JR Minarcik  
8505 Arlington Blvd,  
Suite 300 Fairfax, VA 22031-4621, USA  
Tel +1 703 698 9335  
Fax +1 703 207 0038  
Email minarcik@rocketmail.com

or corneal decompensation, this surgical strategy should be viewed as an option of last resort.<sup>5-11,15</sup>

Because of its rigidity, the internal limiting membrane (ILM) is considered a significant source of retinal stiffness, especially in posterior pole disease.<sup>16,17</sup> A minimally destructive form of retinal dissection, ILM peeling, is commonly and successfully employed for release of retinal tension in a variety of posterior pole diseases. Intraoperative tissue staining is widely used for optimum visualization in ILM peeling when complete and thorough posterior pole ILM removal is thought to be critical to the surgery's success.<sup>18-20</sup> Indocyanine green-assisted ILM peel has been described in many ocular disease states, including macular hole repair, repair of staphylomatous posterior pole retinal detachments, macular hole-related retinal detachments, myopic traction maculopathy, and epiretinal membrane prevention in retinal detachments.<sup>21-28</sup> Further, it is now frequently employed in diabetic macular edema which is recalcitrant to focal laser photocoagulation and intravitreal anti-vascular endothelial growth factor or anti-inflammatory therapy, and is thought to have a mechanical effect.<sup>29-32</sup> A recent study focusing on optical coherence tomography findings in patients who underwent ILM peeling in conjunction with PVR-retinal detachment repair demonstrates that the technique is now also being adapted for difficult retinal detachment cases.<sup>33</sup>

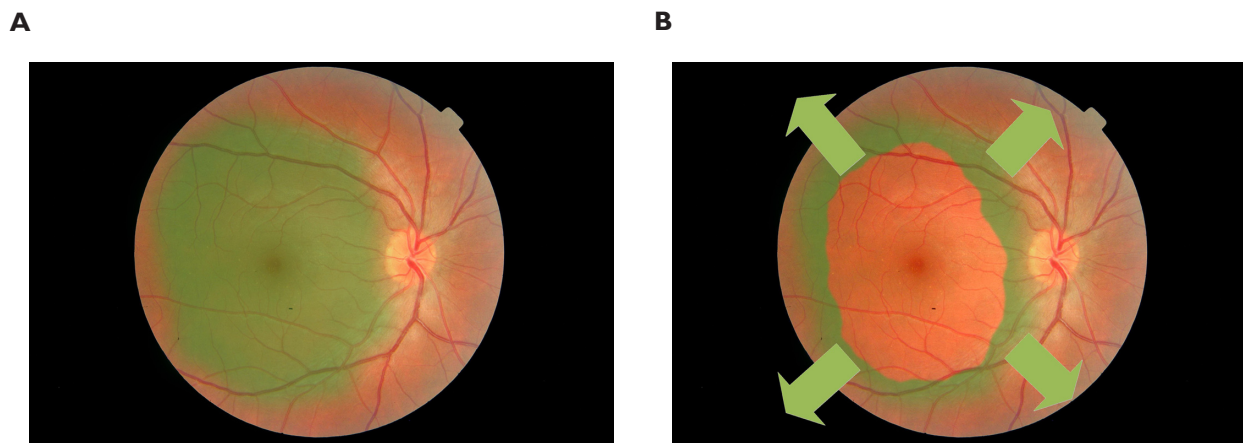
ILM peeling of the posterior pole is a non-standard approach to PVR detachments, and is not represented well in the literature. The rationale for its use is based on other well studied surgical applications in posterior pole diseases, such as macular pucker and macular hole. Theoretically, ILM peeling reduces retinal tension transmitted to the posterior pole. Removal of this tensile layer offers the mechanical

advantage of relaxing the surface tractional forces (Figure 1). It increases retinal compliance by the creation of a central "soft spot", which allows adjacent areas to relax better. ILM removal can also create a plane by which to undermine and dissect PVR,<sup>34</sup> especially if it is posteriorly located. Additionally, it reduces the likelihood of recurrence of posterior epiretinal membrane/PVR formation<sup>28</sup> and subsequent re-detachments, while maximizing macular visual function.

The primary objective of this study was to describe and evaluate a surgical approach using indocyanine green-assisted ILM peeling as an adjunct in vitrectomy for repair of recurrent retinal detachment due to PVR. The primary outcome measure was the anatomic success with single surgery. The utility of this technique as a means to relieve retinal tension is examined in terms of the surgical success of detachment repair. The authors hypothesize that posterior pole ILM removal in some cases helps counteract the pathologic tractional sequelae of PVR, and improves the chance of stable long-term retinal reattachment.

## Materials and methods

This is a retrospective case series examining 14 consecutive cases in which indocyanine green-assisted ILM peeling was used as an adjunct in pars plana vitrectomy for recurrent PVR-related rhegmatogenous retinal detachment. All cases were performed by a single surgeon (MAV) from April 2001 to November 2007. The main outcome measure was the anatomic success rate using single surgery. This was defined as stable total retinal reattachment for a minimum follow-up of 6 months after surgery. The characteristics of the group were studied, including the visual outcomes, the number of previous retinal detachment repair attempts, the use of scleral



**Figure 1** A schematic showing the theoretical mechanism of action. (A) posterior pole after staining, and (B) after ILM (internal limiting membrane)-rhesis, with vectors (arrows) of retinal relaxation after removal of ILM layer.

buckles, silicone oil, and traditional extensive peripheral retinectomies. The numbers and types of surgeries after the ILM peel, such as subsequent retinal detachments repair attempts, if applicable, were also studied. There was a minimum follow-up length of 6 months, and a mean follow-up of 37 (range 6–101) months.

### Inclusion/exclusion criteria

Only recurrent rhegmatogenous retinal detachments which were PVR-related were considered for the review. Primary retinal detachments, eyes with proliferative or tractional diabetic disease, staphylomatous detachments, and detachments due to macular holes were excluded from the series. While not an inclusion criterion, all of the patients had macula-off detachments. Fourteen eyes of 14 patients were identified that met the inclusion criteria. The group had an average number of prior surgical repair attempts of 2.5 (range 1–5) before the vitrectomy featuring indocyanine green-assisted ILM peeling. The overall surgical chronology was complex, indicating a problematic disease course in many of the patients (Table 1). Most of the cases (11/14) had advanced (grade C) PVR.<sup>35</sup> Also, the large majority (12/14) of the cases had at least some PVR located posterior to the equator. The classification of the PVR and the general location of the retinal detachments are given in Table 2.

### Surgical technique

Either 25-gauge (10/14) or 20-gauge (4/14) instrumentation was used. While all eyes had undergone previous vitrectomy,

**Table 1** Chronology of surgical procedures for each of the 14 cases

| Pt | Surgical sequences   |
|----|--|
| 1  | PPV, PPV, PPV/ILM-P  |
| 2  | PPV, PPV, PPV/PPL/MP/SO, SOR/PPV/ILM-P, PPV, PPV/SO, SOR/SB/cryotherapy, PPV/MP/retinectomy, PPV/MP/SO, PPV/evacuate subretinal heme/SO, SOR |
| 3  | PPV, PPV/SB/SO, PPV/SO, PPV/SOR, PPV, PPV/ILM-P  |
| 4  | SB/cryotherapy, external needle drainage/indirect laser, PPV, PPV/ILM-P  |
| 5  | Laser retinopexy, laser demarcation, PPV, PPV/ILM-P  |
| 6  | PPV, PPV, SB/PPV, PPV/ILM-P/SO   |
| 7  | PPV/vitreous biopsy (PCR), PEIOL, PPV/ILM-P  |
| 8  | SB/PPV, PPV/retinectomy/SO, SOR/PPV/ILM-P  |
| 9  | PPV, PEIOL/PPV/ILM-P/SO, SOR, PPV, PPV/SO, SOR   |
| 10 | SB, PPV, PEIOL, PPV/SO, SOR/PPV, laser demarcation, PPV/ILM-P  |
| 11 | Laser retinopexy, PPV, PPV/SB/retinectomy/SO, PPV/ILM-P/SO   |
| 12 | PPV/macular pucker, PPV, PPV/ILM-P   |
| 13 | SB, PPV/SO, PPV/SOR/MP, PPV/ILM-P  |
| 14 | PPV/evacuate subretinal heme, retinopexy, PPV/MP, PPV, SB/PPV/PPL/SO, SOR/PPV/ILM-P, PPV/SO, PPV/SOR   |

**Abbreviations:** ILM-P, internal limiting membrane peel; MP-PVR, membrane peel; PPV, pars plana vitrectomy; PPL, pars plana lensectomy; SB, scleral buckle; SO, silicone oil tamponade; SOR, silicone oil removal; PEIOL, phacoemulsification with intraocular lens implantation.

close vitreous base shaving with external scleral depression was again performed. Peeling and removal of any visible PVR membranes and bands was also performed in all cases prior to ILM removal. Indocyanine green staining of the posterior pole was accomplished with several brief directed pulses of dye around the macula with a soft tip catheter under balanced salt solution with avoidance of the fovea.

**Table 2** Features of retinal detachment at time of surgery with ILM-peeling

| Pt | Grade of PVR*   | Location RD    | Tamponade    | Gauge |
|----|---|----------------|--------------|-------|
| 1  | CP3, starfold   | Inferior       | C3F8, 12%    | 25    |
| 2  | CP3, diffuse  | Inferotemporal | SF6, 20%     | 25    |
| 3  | B, diffuse posterior stiffness                        | Inferior       | SF6, 20%     | 25    |
| 4  | CA2, subretinal bands                                 | Inferior       | SF6, 20%     | 25    |
| 5  | CP2, macular starfold                                 | Temporal       | SF6, 10%     | 20    |
| 6  | B, diffuse posterior stiffness                        | Total          | Silicone oil | 25    |
| 7  | CP3, diffuse stiffness and focal folds                | Superotemporal | C3F8, 12%    | 25    |
| 8  | CP4 diffuse folds, and CA3 anterior displacement      | Inferior       | C3F8, 12%    | 25    |
| 9  | CP2 focal folds                                       | Inferior       | Silicone oil | 25    |
| 10 | CA3 anterior fibrosis/membranes                       | Inferior       | C3F8, 12%    | 25    |
| 11 | CA2 focal folds and CP4 focal folds                   | Inferior       | Silicone oil | 20    |
| 12 | CP3 focal folds                                       | Superotemporal | C3F8, 10%    | 25    |
| 13 | CP3 subretinal fibrosis inferior, and CA3 focal folds | Superior       | SF6, 20%     | 20    |
| 14 | B, diffuse stiffness                                  | Temporal       | SF6, 20%     | 20    |

**Notes:** Description of PVR location of retinal detachment, tamponade agent, and instrumentation gauge used. \*Machamer classification system.<sup>35</sup>

**Abbreviations:** ILM, internal limiting membrane; PVR, proliferative vitreoretinopathy; RD, retinal detachment.

The staining was followed by prompt and complete removal of the dye with the cutter on aspiration mode. After effective staining, ILM dissection was initiated in the posterior pole under a wide-angle viewing system visualization with end-grasping forceps, and carried out as far as possible, to the arcades or beyond, if necessary (Figure 2). ILM peeling over the mobile detached retina offers uncertain countertraction compared with dissection in the attached retina, so good staining greatly facilitates the grasping and removal. In cases of posterior PVR, ILM removal was extended to the areas of PVR formation as a means to undermine the pathologic membranes. After subretinal fluid drainage was performed, tamponade was accomplished with either SF6, C3F8, or silicone oil (Table 2). Scleral buckling was not performed concurrently with this technique.

## Results

In our series using this ILM peeling technique, anatomic success using single surgery was achieved in 11 of 14 eyes (79%). Eventual success, if not achieved directly after the vitrectomy with ILM peel, was achieved in all eyes (100%). The group had an average number of prior surgical repair attempts of 2.5 (range 1–5) before indocyanine green-assisted ILM peeling. The group had an average number of subsequent reoperations for detachment repair of 0.7 (range 0–6). Among the failed detachment repairs prior to ILM peeling, all had at least one prior PPV, 8/14 eyes had prior scleral buckling procedures, 7/14 had prior silicone oil tamponade, and 2/14 had prior inferior retinectomies (Table 3). The mean final best-corrected visual acuity was logMAR 0.9206, or 20/167 (range 20/30 to hand motion). There was no subsequent

development of macular epiretinal membranes in any of the cases after ILM peeling within the duration of each patient follow-up.

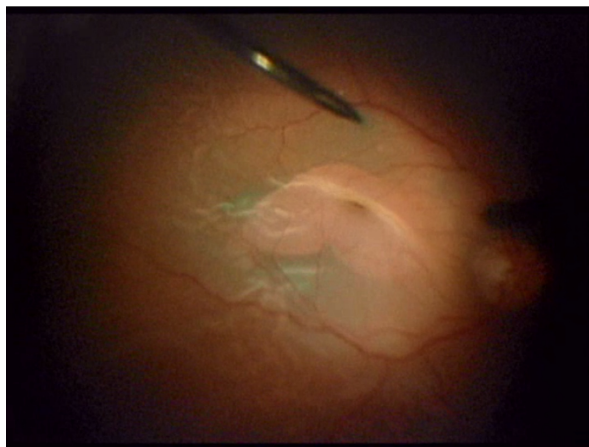
## Discussion

Using indocyanine green-assisted ILM peeling in conjunction with vitrectomy and peeling of peripheral membranes is an effective technique with a high anatomic success rate (79%) in the challenging scenario of PVR-related recurrent retinal detachments. We describe the technique as a surgeon's tool in PVR-related redetachments, and offer it as a tissue-sparing alternative to the more extensive traditional retinectomy in select cases. The anatomic success of single surgery using this technique was comparable with other studies in which relaxing retinotomies and traditional retinectomies were featured. In our data set, there are two examples of achieving anatomic success with ILM removal, even after traditional retinectomies done by different surgeons had failed.

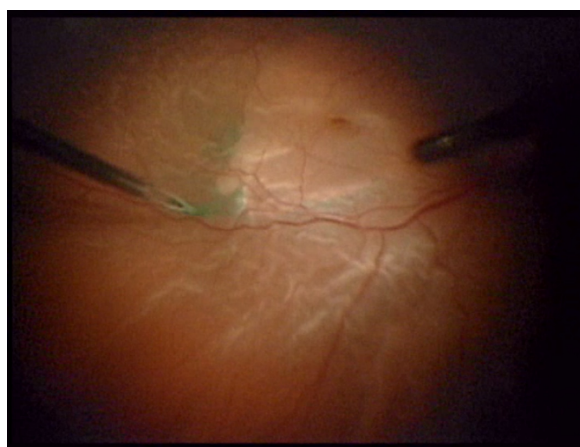
The authors acknowledge the limitations of a retrospective case series, in which certain cases with severe PVR may have been appropriately selected for more aggressive tissue removal, and therefore were not included in the study group. The process of selecting which cases are most appropriate for ILM peel is entirely based on the surgeon's experience and individual assessment of retinal compliance, and it is therefore difficult to compare this directly with other more aggressive surgical techniques. While a control group for the study would have been desirable, it is difficult to assign control cases in a retrospective case series without selection bias, especially given the diverse spectrum of PVR severity, and

Clinical Ophthalmology downloaded from <https://www.dovepress.com/> by 3.22.1.159.255 on 27-Jan-2021  
For personal use only.

**A**



**B**



**Figure 2** ILM peeling over detached macula using asymmetric 25-gauge end-grasping forceps. View the surgical video using this link: <http://youtu.be/7KWk2Jyngrs>.  
**Abbreviation:** ILM, internal limiting membrane.

**Table 3** Surgical features and clinical outcomes of study group

| Pt | RD repairs before ILM-P (n) | RD repairs after ILM-P (n) | Previous SB? | Previous Si oil? | Retinectomy?      | Postoperative VA | Factors affecting final VA                            |
|----|-----------------------------|----------------------------|--------------|------------------|-------------------|------------------|---|
| 1  | 2                           | 0                          | –            | –                | –                 | 20/50–           |   |
| 2  | 3                           | 6                          | –            | Yes              | Yes, after ILM-P  | HM               | Corneal opacification, s/p DSAEK                      |
| 3  | 5                           | 0                          | Yes          | Yes              | –                 | 20/200           | Aphakia   |
| 4  | 3                           | 0                          | Yes          | –                | –                 | 20/100+          |   |
| 5  | 1                           | 0                          | –            | –                | –                 | 20/30            | Post PEIOL endophthalmitis                            |
| 6  | 3                           | 0                          | Yes          | –                | –                 | 20/200           | Retained silicone oil                                 |
| 7  | 1                           | 0                          | –            | –                | –                 | 20/50            | Prior severe unknown posterior uveitis                |
| 8  | 2                           | 0                          | Yes          | Yes              | Yes, before ILM-P | 20/100           |   |
| 9  | 1                           | 2                          | –            | –                | –                 | 20/200           | Developed full thickness macular hole postoperatively |
| 10 | 4                           | 0                          | Yes          | Yes              | –                 | 20/60–           |   |
| 11 | 2                           | 0                          | Yes          | Yes              | Yes, before ILM-P | 20/400           |   |
| 12 | 1                           | 0                          | –            | –                | –                 | 20/80            |   |
| 13 | 3                           | 0                          | Yes          | Yes              | –                 | 20/200           | Fuchs'/corneal edema                                  |
| 14 | 4                           | 2                          | Yes          | Yes              | –                 | CF3'             | History of submacular hemorrhage                      |

**Abbreviations:** DSAEK, descemet's stripping automated endothelial keratoplasty; HM, hand motion; ILM-P, internal limiting membrane peel; PEIOL, phacoemulsification with intraocular lens implantation; RD, retinal detachment; SB, scleral buckle; SO, silicone oil tamponade; VA, visual acuity.

the uniqueness of the individual cases. Therefore, comparison of surgical success with other modern PVR studies featuring traditional methods is probably the best reference.<sup>12–14</sup> There is still clearly a role for traditional retinectomy in the most advanced cases, which the authors favor doing under silicone oil. Nevertheless, we believe the “virtual” retinectomy is an excellent conservative compromise in salvageable PVR cases, offering improved retinal compliance, prevention of epiretinal membrane and macular pucker formation, and subsequent posterior surface PVR. As such, we propose that it can be considered as an additional measure to minimize the chance of recurrent detachment.

The applicability of ILM peeling in detachment surgery may not be limited to PVR. Retinal detachment caused by other pathologies, such as diabetic tractional disease, staphyloma, or macular holes, were not included in this study. However, it is worth noting that the same technique has been employed in our clinical practice for these different varieties of rhegmatogenous retinal detachment with good effect.

The category of patients examined in this review represents one of the most challenging subsets of retinal pathology with which vitreoretinal surgeons are faced. This particular group of patients had somewhat limited visual outcomes, in general, logMAR 0.9206, or 20/167, on average, ranging from 20/30 to hand motion. However, if the cases with severe vision loss were excluded in this small retrospective study, the visual outcomes would be

skewed towards a much more satisfactory level. The visual acuity outcomes are influenced by multiple factors, such as numerous macular redetachments, corneal decompensation, other ocular disease, and post-surgical sequelae (Table 3). Despite the somewhat guarded visual prognosis in eyes with multiple detachments due to PVR, maintaining anatomic success long term is a tenable goal. Beyond the restoration and preservation of vision, postoperative stability and absence of phthisis is a major quality of life issue with patients. For these reasons, we describe our results using this alternative technique which frees the tangential traction from the posterior pole in the management of recurrent PVR rhegmatogenous retinal detachments.

## Disclosures

This work was presented at the American Society of Retina Specialists 28th annual meeting, August 28–September 1, 2010, Vancouver, Canada. The authors report no conflicts of interest in this work.

## References

1. Machemer R. Massive periretinal proliferation: a logical approach to therapy. *Trans Am Ophthalmol Soc.* 1977;75:556–586.
2. Lewis H, Aaberg TM, Abrams GW. Causes of failure after initial vitreoretinal surgery for severe proliferative vitreoretinopathy. *Am J Ophthalmol.* 1991;111(1):8–14.
3. Lewis H, Aaberg TM. Causes of failure after repeat vitreoretinal surgery for recurrent proliferative vitreoretinopathy. *Am J Ophthalmol.* 1991; 111(1):15–19.
4. Charles S. Vitrectomy for retinal detachment. *Trans Ophthalmol Soc UK.* 1980;100(4):542–549.

5. Federman JL, Eagle RC Jr. Extensive peripheral retinectomy combined with posterior 360 degrees retinotomy for retinal reattachment in advanced proliferative vitreoretinopathy cases. *Ophthalmology*. 1990;97(10):1305–1320.
6. Shalaby KA. Relaxing retinotomies and retinectomies in the management of retinal detachment with severe proliferative vitreoretinopathy (PVR). *Clin Ophthalmol*. 2010;4:1107–1114.
7. Han DP, Lewis MT, Kuhn EM, et al. Relaxing retinotomies and retinectomies. Surgical results and predictors of visual outcome. *Arch Ophthalmol*. 1990;108(5):694–697.
8. Morse LS, McCuen BW 2nd, Machemer R. Relaxing retinotomies. Analysis of anatomic and visual results. *Ophthalmology*. 1990;97(5):642–647.
9. Bovey EH, De Ancos E, Gonvers M. Retinotomies of 180 degrees or more. *Retina*. 1995;15(5):394–398.
10. Metge F, Massin P, Gaudric A. Retinectomies in the treatment of retinal detachments with vitreoretinal proliferation. *J Fr Ophthalmol*. 1997;20(5):345–349. French.
11. Iverson DA, Ward TG, Blumenkranz MS. Indications and results of relaxing retinotomy. *Ophthalmology*. 1990;97(10):1298–1304.
12. Tseng JJ, Barile GR, Schiff WM, et al. Influence of relaxing retinotomy on surgical outcomes in proliferative vitreoretinopathy. *Am J Ophthalmol*. 2005;140(4):628–636.
13. Quiram PA, Gonzales CR, Hu W, et al. Outcomes of vitrectomy with inferior retinectomy in patients with recurrent rhegmatogenous retinal detachments and proliferative vitreoretinopathy. *Ophthalmology*. 2006;113(11):2041–2047.
14. Tan HS, Mura M, Oberstein SY, de Smet MD. Primary retinectomy in proliferative vitreoretinopathy. *Am J Ophthalmol*. 2010;149(3):447–452.
15. Blumenkranz MS, Azen SP, Aaberg T, et al. Relaxing retinotomy with silicone oil or long-acting gas in eyes with severe proliferative vitreoretinopathy. Silicone Study Report 5. The Silicone Study Group. *Am J Ophthalmol*. 1993;116(5):557–564.
16. Kuhn F. Internal limiting membrane removal for macular detachment in highly myopic eyes. *Am J Ophthalmol*. 2003;135(4):547–549.
17. Sayanagi K, Ikuno Y, Tano Y. Tractional internal limiting membrane detachment in highly myopic eyes. *Am J Ophthalmol*. 2006;142(5):850–852.
18. Kadonosono K, Itoh N, Uchio E, Nakamura S, Ohno S. Staining of internal limiting membrane in macular hole surgery. *Arch Ophthalmol*. 2000;118(8):1116–1118.
19. Kwok AK, Yeung YS, Lee VY, Wong TH. Indocyanine green assisted peeling of the retinal ILM. *Ophthalmology*. 2002;109(6):1040.
20. Burk SE, Da Mata AP, Snyder ME, Rosa RH Jr, Foster RE. Indocyanine green-assisted peeling of the retinal internal limiting membrane. *Ophthalmology*. 2000;107(11):2010–2014.
21. Da Mata AP, Burk SE, Riemann CD, et al. Indocyanine green-assisted peeling of the retinal internal limiting membrane during vitrectomy surgery for macular hole repair. *Ophthalmology*. 2001;108(7):1187–1192.
22. Kwok AK, Lai TY, Man-Chan W, Woo DC. Indocyanine green assisted retinal internal limiting membrane removal in stage 3 or 4 macular hole surgery. *Br J Ophthalmol*. 2003;87(1):71–74.
23. Da Mata AP, Burk SE, Foster RE, et al. Long-term follow-up of indocyanine green-assisted peeling of the retinal internal limiting membrane during vitrectomy surgery for idiopathic macular hole repair. *Ophthalmology*. 2004;111(12):2246–2253.
24. Oie Y, Emi K, Takaoka G, Ikeda T. Effect of indocyanine green staining in peeling of internal limiting membrane for retinal detachment resulting from macular hole in myopic eyes. *Ophthalmology*. 2007;114(2):303–306.
25. Uemoto R, Yamamoto S, Tsukahara I, Takeuchi S. Efficacy of internal limiting membrane removal for retinal detachments resulting from a myopic macular hole. *Retina*. 2004;24(4):560–566.
26. Futagami S, Inoue M, Hirakata A. Removal of internal limiting membrane for recurrent myopic traction maculopathy. *Clin Experiment Ophthalmol*. 2008;36(8):782–785.
27. Kwok AK, Lai TY. Internal limiting membrane removal in macular hole surgery for severely myopic eyes: a case-control study. *Ophthalmology*. 2003;87(7):885–889.
28. Aras C, Arici C, Akar S, et al. Peeling of internal limiting membrane during vitrectomy for complicated retinal detachment prevents epimacular membrane formation. *Graefes Arch Clin Exp Ophthalmol*. 2009;247(5):619–623.
29. Hartley KL, Smiddy WE, Flynn HW Jr, Murray TG. Pars plana vitrectomy with internal limiting membrane peeling for diabetic macular edema. *Retina*. 2008;28(3):410–419.
30. Yanyali A, Horozoglu F, Celik E, Nohutcu AF. Long-term outcomes of pars plana vitrectomy with internal limiting membrane removal in diabetic macular edema. *Retina*. 2007;27(5):557–566.
31. Gandorfer A, Messmer EM, Ulbig MW, Kampik A. Resolution of diabetic macular edema after surgical removal of the posterior hyaloid and the inner limiting membrane. *Retina*. 2000;20(2):126–133.
32. Haller JA, Qin H, Apte RS, et al. Vitrectomy outcomes in eyes with diabetic macular edema and vitreomacular traction. Diabetic Retinopathy Clinical Research Network Writing Committee. *Ophthalmology*. 2010;117(6):1087–1093, e3.
33. Odrobina DC, Michalewska Z, Michalewski J, Nawrocki J. High-speed, high-resolution spectral optical coherence tomography in patients after vitrectomy with internal limiting membrane peeling for proliferative vitreoretinopathy retinal detachment. *Retina*. 2010;30(6):881–886.
34. Sakamoto H, Yamanaka I, Kubota T, Ishibashi T. Indocyanine green-assisted peeling of the epiretinal membrane in proliferative vitreoretinopathy. *Graefes Arch Clin Exp Ophthalmol*. 2003;241(3):204–207.
35. Machemer R, Aaberg TM, Freeman HM, Irvine AR, Lean JS, Michels RM. An updated classification of retinal detachment with proliferative vitreoretinopathy. *Am J Ophthalmol*. 1991;112(2):159–165.

## Clinical Ophthalmology

### Publish your work in this journal

Clinical Ophthalmology is an international, peer-reviewed journal covering all subspecialties within ophthalmology. Key topics include: Optometry; Visual science; Pharmacology and drug therapy in eye diseases; Basic Sciences; Primary and Secondary eye care; Patient Safety and Quality of Care Improvements. This journal is indexed on

Submit your manuscript here: <http://www.dovepress.com/clinical-ophthalmology-journal>

Dovepress

PubMed Central and CAS, and is the official journal of The Society of Clinical Ophthalmology (SCO). The manuscript management system is completely online and includes a very quick and fair peer-review system, which is all easy to use. Visit <http://www.dovepress.com/testimonials.php> to read real quotes from published authors.