

External squeeze test during pediatric laparoscopic hernia repair: a novel on-table assessment to ensure complete closure of patent processus vaginalis

Dayang Anita Abdul Aziz¹
Marjmin Osman¹
Felicia Lim²
Rufina Teo²
Zarina Abdul Latiff³
Rizal Abdul Manaf⁴

¹Department of Surgery, UKM Medical Centre, Kuala Lumpur, Malaysia;

²Department of Anaesthesia, UKM Medical Centre, Kuala Lumpur, Malaysia; ³Department of Paediatrics, UKM Medical Centre, Kuala Lumpur, Malaysia; ⁴Department of Public Health, UKM Medical Centre, Kuala Lumpur, Malaysia

Background: In pediatric patients, recurrent inguinal hernia (IH) after laparoscopic repair mostly occurs secondary to incomplete closure of the patent processus vaginalis (PPV). The “external squeeze test” (EST) is a simple on-table assessment tool to check completeness of closure of PPV during laparoscopic IH repair.

Patients and methods: A review of effectiveness of EST and recurrence of IH was carried out at our institution from December 2007 to December 2017. Closure of PPV was achieved with creation of purse string over pre-peritoneal fascia of the deep inguinal ring with avoidance of important structures; EST was then performed, that is, a gentle squeeze on the scrotum or labia majora while the telescope remains focused at the pursed area. If the closure was incomplete, EST would result in escape of CO₂ from within the scrotum or labia back into the peritoneal cavity, visualized as air bubbles internally and taken as a positive EST. A complete closure of PPV would not produce any bubbles internally upon external pressure; this would be taken as a negative EST. All patients had 1- to 12-month follow-up.

Results: A total of 874 PPVs were repaired. EST was performed in 870 PPVs (99.5%). There were five recurrences of PPVs consistent with recurrent IH (0.57%); one was in a patient with negative EST, attributed to a slipped ligature; the other four did not have EST performed ($p < 0.000000$). All the recurrences were re-repaired laparoscopically.

Conclusion: EST is a simple, useful on-table assessment tool which significantly detects completeness of closure of PPV which may prevent recurrence of IH. We highly recommend EST in pediatric laparoscopic hernia repair, especially in large PPV.

Keywords: pediatric, laparoscopy, inguinal hernia, recurrent

Introduction

Recurrent inguinal hernia (IH) after laparoscopic repair occurs most likely secondary to incomplete closure of the patent processus vaginalis (PPV). The “external squeeze test” (EST) was introduced by the author in 2007, which is a simple on-table assessment tool to test completeness of closure of the PPV using the port-free purse-string technique for laparoscopic inguinal hernia (LIH) repair.¹

Methodology

To look at the effectiveness of EST, a review of all cases from December 2007 to December 2017 with and without EST and the recurrence of IH were carried out. This review based on our existing audit is waived for ethical approval by UKM Medical

Correspondence: Dayang Anita Abdul Aziz
Department of Surgery, UKM Medical Centre, Bandar Tun Razak, 56000 Cheras, Kuala Lumpur, Malaysia
Fax +60 3 9145 6684
Email dayanganita@yahoo.co.uk

Centre Medical Research and Ethics Committee. At laparoscopy, during the CO₂ insufflation, the gas would also flow into the scrotum or labia majora through the PPV; squeezing the scrotum or labia externally would result in escape of gas from within the scrotum or labia back into the peritoneal cavity, visualized as air bubbles internally. Closure of PPV was achieved via creation of purse string over pre-peritoneal fascia of the deep inguinal ring with avoidance of important structures, that is, vas deferens and spermatic cords. A gentle squeeze on the scrotum or labia majora externally or EST was then performed, while the telescope remains focused at the pursed area (Figure 1). If the closure of PPV was incomplete, EST would result in escape of gas from within the scrotum or labia back into the peritoneal cavity, visualized as air bubbles internally and taken as a positive EST; therefore, the purse string needed to be redone. Absence of internal air bubbles upon EST means the closure of PPV is complete, and hence, a negative EST (Video 1). If there was any residual air in the inguinal-scrotal region, percutaneous aspiration using the smallest gauge needle would be carried out at the end of surgery.

Results

A total of 874 PPVs were repaired laparoscopically and evaluated. EST was performed in 870 PPVs (99.5%). All patients were followed up at 1 and 12 months post surgery. Five repaired PPVs had recurrence of the IH (0.57%): one recurrence happened in a patient who had negative EST which was attributed to a slipped ligature, confirmed during the second repair; the other 4 cases did not have EST per-

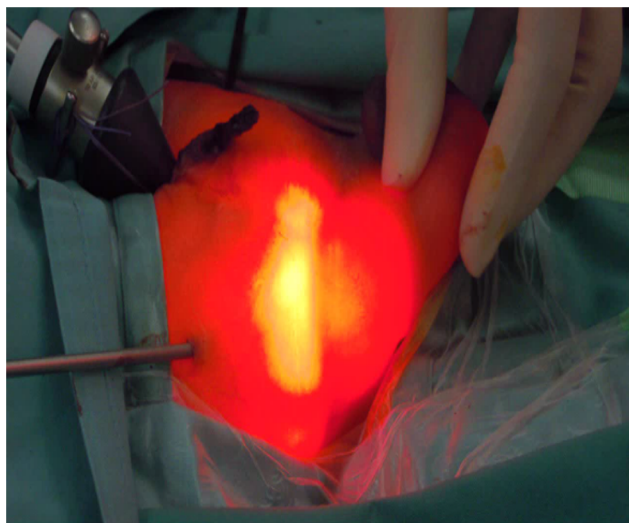


Figure 1 External squeeze test.

Table 1 Single-table analysis of EST and successful surgery

	Successful surgery (no recurrence)	Unsuccessful surgery (with recurrence)	Total surgery
EST performed	869	1	870
EST not performed	0	4	4
	869	5	874

Notes: At least one expected value (row total × column total/grand total) is <5; hence, Fisher's or mid-P exact test is recommended than chi-square test. Fisher's exact test results showed $p < 0.0000001$.

Abbreviation: EST, external squeeze test.

formed. All the recurrences were re-repaired laparoscopically. Single-table analysis was carried out with Fisher's exact test; the result showed $p < 0.0000001$ (Table 1).

Discussion

The results showed that EST performed at our institution ensured complete closure of PPV for LIH repair and correlated with successful surgery (no recurrence). Furthermore, 220 large PPVs (bowel seen in irreducible or obstructed IH or PPV of more than 2 cm diameter) with positive on-table EST benefitted from immediate re-purse string, resulting in no hernia recurrence. Our IH recurrence rate of 0.57% is comparable to the recurrence rate of 0.3% at a high-volume center in the People's Republic of China with a series of over 6,000 pediatric patients, and better than most other pediatric laparoscopic IH series (1.4%–3.1%).²⁻⁵

Conclusion

EST is a simple and useful on-table assessment tool. We recommend EST in LIH repair, especially when the patient has a large PPV.

Acknowledgments

The interim finding of this work was presented as a poster at the International Pediatric Endosurgery Group (IPEG) 2013 Conference in Beijing, People's Republic of China. Abstract of the poster (A52) was published in the supplement of *Journal of Laparoendoscopic & Advanced Surgical Techniques* (<https://doi.org/10.1089/lap.2013.9995>).

Disclosure

The authors report no conflicts of interest in this work.

References

1. Aziz DAA, Nor MM. External squeeze test (EST) during laparoscopic hernia repair; a novel on-table assessment technique to prevent recurrence of hernia. *J Laparoendosc Adv Surg Tech A*. 2013;23(12):A-52.

2. Chinnaswamy P, Malladi V, Jani KV, et al. Laparoscopic inguinal hernia repair in children. *JLS*. 2005;9(4):393–398.
3. Esposito C, St Peter SD, Escolino M, Juang D, Settini A, Holcomb GW 3rd. Laparoscopic versus open inguinal hernia repair in pediatric patients: a systematic review. *J Laparoendosc Adv Surg Tech A*. 2014;24(11):811–818.
4. Xiang B, Jin S, Zhong L, Li F, Jiang X, Xu Z. Reasons for recurrence after the laparoscopic repair of indirect inguinal hernia in children. *J Laparoendosc Adv Surg Tech A*. 2015;25(8):681–683.
5. Steven M, Carson P, Bell S, Ward R, McHoney M. Simple purse string laparoscopic versus open hernia repair. *J Laparoendosc Adv Surg Tech A*. 2016;26(2):144–147.

Open Access Surgery

Publish your work in this journal

Open Access Surgery is an international, peer-reviewed, open access journal that focuses on all aspects of surgical procedures and interventions. Patient care around the peri-operative period and patient outcomes post surgery are key topics for the journal. All grades of surgery from minor cosmetic interventions to major surgical procedures are covered. Novel techniques and the

utilization of new instruments and materials, including implants and prostheses that optimize outcomes constitute major areas of interest. The manuscript management system is completely online and includes a very quick and fair peer-review system, which is all easy to use. Visit <http://www.dovepress.com/testimonials.php> to read real quotes from published authors.

Submit your manuscript here: <https://www.dovepress.com/open-access-surgery-journal>

Dovepress