

# The King Vision™ video laryngoscope for awake intubation: series of cases and literature review

Ewelina Gaszynska  
Tomasz Gaszynski

Department of Emergency Medicine  
and Disaster Medicine, Medical  
University of Lodz, Lodz, Poland

**Abstract:** Intubation of patients with a supraglottic mass causing obstruction of the glottis remains a difficult problem for the experienced anesthesiologist. Awake fiberoptic endotracheal intubation is the recommended approach in such cases; however, use of a video laryngoscope for awake intubation can be an alternative to a fiberoptic. Here we present two cases of awake intubation using a King Vision™ video laryngoscope in patients with a supraglottic mass, and a literature review on use of video laryngoscopes for awake intubation. After topical anesthesia and sedation with opioids, the patients were successfully intubated.

**Keywords:** airway management, difficult airway, awake intubation, video laryngoscope

## Introduction

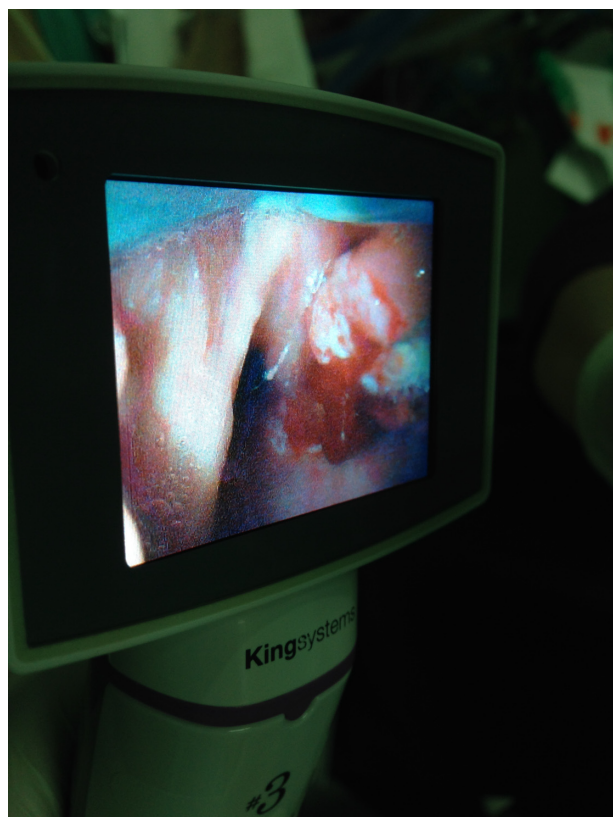The intubation of patients with a supraglottic mass causing obstruction of the glottis is a difficult problem for the experienced anesthesiologist. Awake fiberoptic endotracheal intubation is the recommended approach in such cases; however, use of a video laryngoscope can be an alternative to fiberoptic for awake intubation.<sup>1</sup> Here we report two cases in which the King Vision™ video laryngoscope (King Systems, Noblesville, IN, USA) was used rather than the flexible fiberoptic for awake intubation of patients with pharyngeal and laryngeal tumors. Written consent was obtained from the patients for publication of this paper.

## Case report I

A 56-year-old male was admitted to the department of laryngology at Barlicki University Hospital, Poland, for treatment of a pharyngeal tumor causing discomfort and dysphagia. Following a discussion with various specialists, it was decided to attempt intubation and perform a tracheostomy under general anesthesia. As an alternative method, a tracheostomy would be performed under local anesthesia, should intubation be unsuccessful.

After indirect examination of the larynx, it was found that the entrance was not visible and a tumor was covering the epiglottis and entrance to the larynx. Thus, it was decided to perform an awake intubation under local anesthesia. The patient was anesthetized with 4% lidocaine topical spray anesthesia using the typical method.<sup>2,3</sup> Fentanyl 0.1 mg and atropine 0.5 mg were administered intravenously. An anesthesiologist experienced in use of the King Vision video laryngoscope attempted intubation. While gently introducing the video laryngoscope, it was possible to elevate the tumor with the tip of the video laryngoscope blade and visualize the entrance to the larynx (Figure 1).

Correspondence: Tomasz Gaszynski  
Department of Emergency Medicine and  
Disaster Medicine, Barlicki University  
Hospital, ul Kopcinskiego 22,  
90-153 Lodz, Poland  
Tel +484 2678 3748  
Fax +484 2678 3748  
Email tomasz.gaszynski@umed.lodz.pl



**Figure 1** Picture of visualization of the tumor obscuring the entrance to the larynx using the KingVision™ video laryngoscope (King Systems, Noblesville, IN, USA).

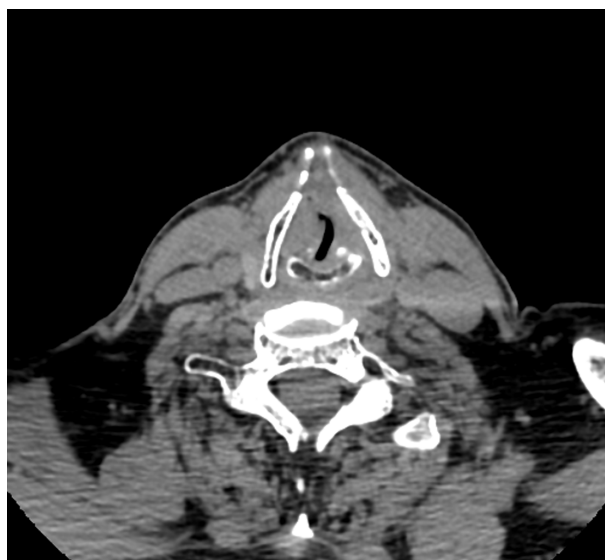
A size 7.0 endotracheal tube was then introduced into the trachea. General anesthesia was commenced with propofol infusion and maintained with sevoflurane and rocuronium. The surgery and perioperative period were uneventful.

## Case report 2

A 64-year-old male patient with a laryngeal tumor was admitted to the hospital for diagnosis. On admission, the patient suffered from sore throat, dysphagia, dysphasia, and sleep problems caused by respiratory disturbance. He was scheduled for an urgent tracheostomy. Computer tomography revealed a tumor affecting the entrance to the larynx (Figure 2). We opted to perform an awake intubation using the King Vision video laryngoscope. The patient was managed similar to patient in Case report 1. After visualizing the entrance to the larynx, a size 6.5 endotracheal tube was inserted and the procedure was continued.

## Discussion

To the best of our knowledge, this is the first report of application of the King Vision video laryngoscope for awake intubation in patients suspected of being difficult to



**Figure 2** Computed tomography scan at level of entrance to larynx showing tumor mass obscuring glottis.

intubate. Patients with tumors of the oral cavity, especially those operated due to recurrence of illness prior to final reconstructive surgery, may present a challenge with regard to the airways management necessary for safe anesthesia. As a standard approach, awake fiberoptic intubation is recommended in cases where intubation is anticipated to be difficult.<sup>2</sup> However, in unfavorable conditions, fiberoptic intubation requires extensive skill, experience, and specialized equipment to be performed safely and effectively. After adequate training, new devices such as video laryngoscopes are easy to use when dealing with difficult airways.<sup>1</sup> Anesthesiologists who do not perform fiberoptic intubation during routine practice may find the newer systems much easier to use.<sup>1</sup> These new video systems can be used for intubation not only under general anesthesia but also for awake intubation. Successful use of video laryngoscopes for awake intubation is described in several papers.

Tahan et al described use of the King Vision for patients with inspiratory stridor, orthopnea, and dyspnea as a result of critical tracheal stenosis.<sup>4</sup> They performed combined video laryngoscopy and fibroscopy under general anesthesia, and not under local anesthesia as we did. Other reports of application of video laryngoscopy for awake intubation have used other devices. The most similar to the King Vision are the Airtraq (Prodol Meditec SA, Vizcaya, Spain) and Pentax-AWS (Hoya Corporation, Tokyo, Japan) video laryngoscopes. The King Vision, Airtraq, and Pentax-AWS are from a group of airway devices with a specially incorporated channel for the endotracheal tube. Dimitriou et al reported on a series of cases using the Airtraq device for awake intubation in

suspected difficult intubation.<sup>5</sup> Xue et al used the Airtraq device for nasal awake intubation.<sup>6</sup> Dimitriou et al, in addition to topical anesthesia, used 10% lidocaine injected through the cricothyroid ligament. Asai used the Pentax-AWS in patients with neck instability in whom fiberoptic intubation failed.<sup>7</sup> Suzuki et al reported use of the Pentax-AWS in the case of a laryngeal tumor<sup>8</sup> and in morbidly obese patients as an alternative to awake fiberoptic intubation.<sup>9</sup> However, Sasano et al reported failure of the Pentax-AWS because the blade of the airway scope was too short to reach the epiglottis.<sup>10</sup> The advantage of using devices similar to the Pentax-AWS video laryngoscopes, eg, the King Vision or Airtraq devices, is that limited mouth opening is of little concern. A 25 mm mouth opening is sufficient to perform awake intubation using such video laryngoscopes.<sup>11</sup> We have used the Truview PCD (Truphatek International Ltd., Netanya, Israel) for awake intubation in patients with severely restricted mouth opening.<sup>12</sup> Uslu et al described use of the McGrath video laryngoscope for awake intubation,<sup>13</sup> which is very different in construction and operation to the King Vision and is similar to video laryngoscopes like the Pentax-AWS and Airtraq.

Very interesting is the combined use of video laryngoscopy and fibroscopy. Schoettker et al described use of the Airtraq combined with a flexible fiberoptic in very difficult cases.<sup>14</sup> We used typical methods for administration of local anesthesia in our patients with success. Adjunctive opioid administration is very effective in attenuating reflexes from the posterior wall of the pharynx and the entrance to the larynx during fibroscopy. Xue et al reported 13 cases of awake intubation using a combination of a GlideScope (Verathon Medical (Europe) BV, IJsselstein, the Netherlands) and fiberoptic.<sup>15</sup> As in the report by Xue et al, in our case we administered fentanyl with good effect. Choi et al reported awake combined GlideScope-flexible fiberoptic intubation in a patient with an elliptic tumor mass about 4 cm in diameter which was blocking nearly the entire superior aspect of the glottis.<sup>16</sup> They used a remifentanyl infusion as the opioid. Remifentanyl infusion for awake intubation is described by Rai et al as very effective and producing sedation without a need for additional sedative drugs.<sup>17</sup>

Video laryngoscopy can be a good alternative to fibroscopy for awake intubation,<sup>1</sup> especially in the event of failed fiberoptic intubation.<sup>7,18,19</sup> Video laryngoscopes are easier to use and more amenable to use by anesthesiologists inexperienced with fiberoptic awake intubation. However, unexpected complications, such as extensive bleeding, may occur when using the video laryngoscope for awake intubation.<sup>20</sup>

Alternative methods must always be planned and available. There is a wide range of video laryngoscopes and other airway devices currently available. Video laryngoscopes can be divided into subgroups, ie, Macintosh-like blades (eg, C-MAC [Karl Storz GmbH, Tuttlingen, Germany], McGrath MAC [Aircraft Medical, Edinburgh, UK]), and modified blades (eg, the McGrath Series 5 GlideScope). The TruView PCD, which we have used, is a laryngoscope with a modified blade. The view of the glottis is obtained through the optical view tube incorporated into the blade, and a video system can be connected. There are also devices with a special channel for the endotracheal tube, eg, the Airtraq, Pentax-AWS, and King Vision devices. The Airtraq nasotracheal intubation device that we used is modified, in that it has no channel for the endotracheal tube.

Each device has its advantages and disadvantages. Video laryngoscopes are advantageous in that they function in a manner very similar to that of standard laryngoscopes. As a result, anesthesiologists can rapidly master the skill needed to use this device effectively. A possible disadvantage to its use is fogging, which may be resolved in a variety of ways; for example, applying anti-fog solution in the case of the C-MAC, or the Airtraq device which should be turned on 30 seconds prior to use to warm up the lens. In the case of the TruView PCD, constant oxygen flow to the lens area prevents fogging and removes secretions from the view.

The general indication for all devices mentioned is in situations of both predicted and unexpected difficult intubation. Such devices are now being used more frequently in standard patients because they allow optimal prevention of possible intubation injuries in comparison with standard laryngoscopes. The fiberoptic is preferred in the event of predicted intubation difficulties (as in the case of our patient with a cancer of the oral cavity); however, modern airway devices can be a good alternative. For anesthesiologists using the new devices in their everyday practice, such devices create new opportunities to manage difficult patients in an effective way.

Video laryngoscopes are easier to use than fiberoptic and are a good alternative to fiberoptic intubation for anesthesiologists with limited experience in awake fiberoptic intubation. Video laryngoscopes are operated in a way similar to laryngoscopes, which are well known to anesthesiologists.

In the cases reported here, we opted to use the King Vision video laryngoscope because it is our personal experience that this is well tolerated by patients in awake intubation procedures; further, the device is plastic and has a small diameter. Our other goal was to provide a visible entrance to the larynx for the operating laryngologist. The monitor

is incorporated into the handle of the King Vision video laryngoscope, so was used to provide adequate visibility.

There are several limitations when using this technique. The first is that of the uncooperative patient. We have witnessed similar cases to those reported here, wherein the patient was too agitated even under sedation to continue with the awake intubation procedure. In the event of an agitated patient, video laryngoscopy has an important advantage over fibroscopy. Due to the structural composition, the video laryngoscope would not be destroyed should the patient bite it. However, use of fiberscopes during awake intubation necessitates a bite block to prevent damage. Second, awake intubation is not recommended for emergency intubation in a patient with a full stomach. We mention this because some clinicians claim that it may be better to have a conscious patient with protective reflexes present. In our opinion, this is too dangerous and rapid sequence induction is recommended in this situation. The third limitation of the awake technique using video laryngoscopy is a severely limited mouth opening. In such cases, nasal fiberoptic intubation remains the only possibility. Finally, lack of training in video laryngoscopy is a disadvantage. Awake intubation using video laryngoscopy requires skills and training; however, as stated earlier, it is easier than the awake fiberoptic intubation technique.

In conclusion, we regard the King Vision video laryngoscope as a favorable option for awake intubation in patients with suspected difficult intubation rather than the flexible fiberscope.

## Acknowledgment

We thank Corrine Fiddick (Canada) for revising the English language content of this manuscript.

## Disclosure

The authors report no conflicts of interest in this work.

## References

- Rosenstock CV, Thøgersen B, Afshari A, Christensen AL, Eriksen C, Gätke MR. Awake fiberoptic or awake video laryngoscopic tracheal intubation in patients with anticipated difficult airway management. *Anesthesiology*. 2012;116:1210–1216.
- Andruszkiewicz P, Dec M, Kanski A, Becler R. Awake fiberoptic intubation. *Anestezjol Intens Ter*. 2010;42:246–250.
- Wadelek J. Airway local anaesthesia for awake flexible fiberoptic endotracheal intubation. *Anesthesiol and Rescue*. 2010;4:99–110.
- El-Tahan MR, Doyle DJ, Khidr AM, Abdulshafi M, Regal MA, Othman MS. Use of the King Vision™ video laryngoscope to facilitate fiberoptic intubation in critical tracheal stenosis proves superior to the GlideScope. *Can J Anaesth*. 2014;61:213–214.
- Dimitriou VK, Zogogiannis ID, Liotiri DG. Awake tracheal intubation using the Airtraq laryngoscope: a case series. *Acta Anaesthesiol Scand*. 2009;53:964–967.
- Xue FS, Liao X, Yuan YJ, Liu JH, Wang Q. Nasotracheal intubation using the Airtraq® optical laryngoscope in patients with a difficult airway. *Can J Anaesth*. 2011;58:406–408.
- Asai T. Pentax-AWS video laryngoscope for awake nasal intubation in patients with unstable necks. *Br J Anaesth*. 2010;104:108–111.
- Suzuki A, Kunisawa T, Takahata O, Iwasaki H, Nozaki K, Henderson JJ. Pentax-AWS (Airway Scope) for awake tracheal intubation. *J Clin Anesth*. 2007;19:642–643.
- Suzuki A, Terao M, Aizawa K, Sasakawa T, Henderson JJ, Iwasaki H. Pentax-AWS Airway Scope as an alternative for awake flexible fiberoptic intubation of a morbidly obese patient in the semi-sitting position. *J Anesth*. 2009;23:162–163.
- Sasano N, Yamauchi H, Fujita Y. Failure of the Airway Scope to reach the larynx. *Can J Anaesth*. 2007;54:774–775.
- Jarvi K, Hillermann C, Danha R, Mendonca C. Awake intubation with the Pentax Airway Scope – initial experience on 17 patients: 19AP5-3. *Eur J Anaesth*. 2011;28:235.
- Gaszynska E, Wiczorek A, Gaszynski T. Awake non-fiberoptic endotracheal intubation in patients with severely restricted mouth opening – alternative devices: series of cases and literature review. *Cent Eur J Med*. 2014. In press.
- Uslu B, Damgaard Nielsen R, Kristensen BB, McGrath video laryngoscope for awake tracheal intubation in a patient with severe ankylosing spondylitis. *Br J Anaesth*. 2010;104:118–119.
- Schoettker P, Bathory I, Broome M. Use of the nasotracheal Airtraq® to assist difficult nasal fiberoptic intubation. *Can J Anaesth*. 2008;55:884.
- Xue FS, Li CW, Zhang GH, et al. GlideScope-assisted awake fiberoptic intubation: initial experience in 13 patients. *Anaesthesia*. 2006;61:1014–1015.
- Choi GS, Park SI, Lee EH, Yoon SH. Awake GlideScope® intubation in a patient with a huge and fixed supraglottic mass – a case report. *Korean J Anesthesiol*. 2010;59 Suppl:S26–S29.
- Rai MR, Parry TM, Dombrovskis A, Warner OJ. Remifentanyl target-controlled infusion vs propofol target-controlled infusion for conscious sedation for awake fiberoptic intubation: a double-blinded randomized controlled trial. *Br J Anaesth*. 2008;100:125–130.
- Sukhpragarn W, Churnchongkolkul W. Glidescope intubation after failed fiberoptic intubation. *Paediatr Anaesth*. 2010;20:901–902.
- Jeyadoss J, Nanjappa N, Nemeth D. Awake intubation using Pentax-AWS video laryngoscope after failed fiberoptic intubation in a morbidly obese patient with a massive thyroid tumour and tracheal compression. *Anaesth Intensive Care*. 2011;39:311–312.
- Lasinska-Kowara M, Karwacki Z, Lapinski M. Complications after using the Airtraq laryngoscope for predicted difficult intubation. *Anesthesiol Intensive Ther*. 2013;45:38–40.

### Therapeutics and Clinical Risk Management

### Publish your work in this journal

Therapeutics and Clinical Risk Management is an international, peer-reviewed journal of clinical therapeutics and risk management, focusing on concise rapid reporting of clinical studies in all therapeutic areas, outcomes, safety, and programs for the effective, safe, and sustained use of medicines. This journal is indexed on PubMed Central, CAS,

Submit your manuscript here: <http://www.dovepress.com/therapeutics-and-clinical-risk-management-journal>

EMBASE, Scopus and the Elsevier Bibliographic databases. The manuscript management system is completely online and includes a very quick and fair peer-review system, which is all easy to use. Visit <http://www.dovepress.com/testimonials.php> to read real quotes from published authors.

Dovepress