

# Sub-Clinical Regional Macular Changes in Self-Reported Diabetic Subjects: Vascular and Retinal Layer Analysis Using Swept-Source OCT

Naveen Kumar Challa, Waleed M Alghamdi , Muhammed S Alluwimi , Saleh Alshammeri

Department of Optometry, College of Applied Medical Sciences, Qassim University, Buraidah, AlQassim, Saudi Arabia

Correspondence: Naveen Kumar Challa, Department of Optometry, College of Applied Medical Sciences, Qassim University, Buraidah, AlQassim, Saudi Arabia, Tel +966531177518, Email N.challa@qu.edu.sa

**Aim:** To assess and compare subclinical alterations in superficial capillary plexus vessel density (SCPVD) and retinal layers thickness in the macular region between individuals with type 2 diabetes mellitus (DM) and healthy controls.

**Methods:** Swept-source OCT images were obtained from 29 control subjects and 24 diabetic subjects. Macular thickness (MT), retinal nerve fiber layer (RNFL) thickness, and ganglion cell layer (GCL) thickness were measured in the central macula and four quadrants of macular region using a 6.0 × 6.0 mm radial macular scan centered on the fovea. OCTA acquisition included a 3.0 × 3.0 mm macular scan for the foveal avascular zone (FAZ) and a 4.5 × 4.5 mm macular scan for SCPVD. The FAZ was manually mapped at the SCP on OCTA images.

**Results:** In diabetic subjects, the superficial capillary plexus vessel density (SCPVD) was significantly lower in both the central ( $P = 0.04$ ) and inferior ( $P = 0.01$ ) regions compared to the control group. Additionally, diabetic patients showed a significant reduction in temporal macular thickness (MT) and thinning of the ganglion cell layer (GCL) in all three quadrants except in the central and inferior macula ( $P < 0.05$ ). There was also significant thinning of the superior macular retinal nerve fiber layer (RNFL) in diabetics compared to controls ( $P = 0.02$ ). While the foveal avascular zone (FAZ) was larger in diabetic subjects, this difference was not statistically significant ( $P = 0.78$ ). Duration of diabetes has shown a significantly high positive correlation ( $r = 0.77$ ,  $P < 0.01$ ) with superior macular VD.

**Conclusion:** The findings of this study suggest that the diabetic macula experiences significant ganglion cell layer (GCL) thinning and reduced superficial capillary plexus (SCP) vascular density even before the onset of clinical retinopathy. Swept-source OCT proves to be an essential tool for detecting these early changes in diabetic patients.

**Keywords:** tomography, age, RNFL, SCPVD, FAZ, diabetes mellitus

## Introduction

Type 2 Diabetes Mellitus (DM) is a chronic disease characterized by impaired glucose metabolism due to reduced insulin production in the pancreas.<sup>1-3</sup> DM affects the vascular and neural systems that include eyes causing diabetic retinopathy (DR).<sup>4-7</sup> Prevalence of DR increases significantly every year, and it is one of the leading causes of blindness in the world.<sup>8,9</sup> Progression of the DR leads to blindness, and it can be prevented with early detection and intervention.<sup>10</sup> Advance imaging techniques such as OCT (Optical Coherence Tomography) and OCTA (Optical Coherence Tomography Angiography) are of current interest to detect the vascular and neural biomarkers in the retina for the early detection of DR.<sup>11</sup> Preclinical retinopathy can be detected by high resolution OCTA by, for example, detecting changes in the foveal avascular zone, changes in vessel density, and changes in retinal thickness.<sup>12,13</sup> Recent advancement in OCT technology such as swept source OCT has drawn a lot of attention due to its efficiency and scanning speed in achieving high resolution in retinal imaging using long wavelength light.<sup>14,15</sup>

Swept source OCT A parameters such as FAZ area<sup>16,17</sup> and Vessel density measurements across various DR stages have demonstrated their utility in characterizing DR progression.<sup>18-20</sup> Despite these advancements, there are limited



quantitative data comparing vessel density in healthy eyes versus eyes with diabetes but without clinical signs of DR using swept-source OCT-A.<sup>21–24</sup> Such comparisons are crucial for identifying preclinical vascular changes that could serve as early markers for DR diagnosis. Therefore, this study utilized swept-source OCT-A to evaluate vascular and retinal tissue alterations in individuals with diabetes but no DR, comparing them to healthy controls to explore potential early indicators of DR.

## Methods

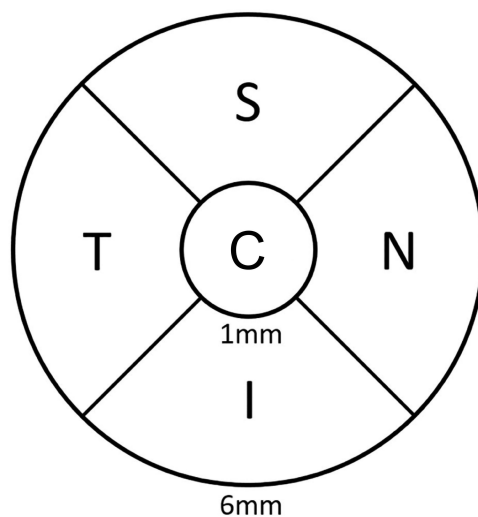
In the current cross-sectional study, healthy and diabetic subjects were recruited from Qassim University's medical clinics. The study's inclusion criteria were as follows: i) individuals over the age of eighteen who were diagnosed with type 2 diabetes mellitus (DM) by their physician and managing the condition with medication or insulin. ii) subjects that did not exhibit any signs of diabetic retinopathy (DR) after comprehensive eye examination conducted by an expert ophthalmologist; iii) healthy (control) subjects were those with no history of diabetes or any other systemic disease on annual routine checkup comprehensive eye examination showed no abnormalities.

Exclusion criteria of the Subjects are as follows: i) clinically evident diabetic retinopathy, ii) prior ocular surgery, iii) refractive error greater than  $\pm 3.00D$ , iv) history of any ocular disease such as glaucoma, hypertensive retinopathy or ocular hypertension, v) uncontrolled systemic blood pressure, vi) OCTA image of poor quality due to media opacity or poor cooperation.

All the study subjects underwent comprehensive eye examination that included objective and subjective refraction, IOP (intraocular pressure) evaluation, anterior segment evaluation, fundus examination using indirect ophthalmoscopy prior to OCT data collection.

This study followed the ethical guidelines and approved by the Institutional Review Board of Qassim University and adhered to the Declaration of Helsinki, 2013. Written informed consent was obtained from all participants. Demographic data was collected from all the study participants that included age, ocular history, recent fasting blood glucose levels if available.

A swept source OCT (DRI Triton, Topcon, Tokyo, Japan) that uses infrared light with a wavelength of 1050 nm and a scanning speed of 1,00,000 A-scans per second was used to acquire the OCT and OCTA imaging for every subject. Full retinal thickness, GCL thickness at the central, superior, inferior, temporal, and nasal quadrants of the macula were measured using an ETDRS grid using a  $6.0 \times 6.0$  mm radial scan that was centered on the fovea (Figure 1). RNFL thicknesses were measured automatically by the device using the same  $6.0 \times 6.0$  mm macular radial scan in superior, inferior, nasal and temporal quadrants of the macular region. The Topcon Advanced Boundary Software (TABSTM)



**Figure 1** ETDRS (early treatment diabetic retinopathy study) grid used to define five quadrants of the macula.  
**Abbreviations:** C, Central; S, Superior; N, Nasal; I, Inferior; T, Temporal.

automatically segments retinal tissue layers, allowing for the measurement of overall retinal thickness and its sub-layers. Full retina thickness is measured as the distance between Internal limiting membrane (ILM) to retinal pigment epithelium (RPE). GCL thickness is measured as the distance between the inner boundary of RNFL and outer boundary of GCL+IPL (inner plexiform layer) complex, and RNFL thickness is measured as the distance between ILM and the outer boundary of the RNFL.

The  $3.0 \times 3.0$  mm scan for FAZ measurement and the  $4.5 \times 4.5$  mm scan for superficial capillary plexus (SCP) vascular density (VD) were included in the OCTA acquisition. The extent of the Foveal Avascular Zone (FAZ) was manually outlined along the innermost capillaries on OCTA images at the SCP utilizing quantitative measurement of the FAZ area using the  $3 \times 3$  mm scan. In the  $4.5 \times 4.5$  mm scan, the apparatus quantitatively assessed the retinal vascular density map at the SCP automatically. The OCT device automatically recognizes and detects superficial plexus, which is located  $2.6 \mu\text{m}$  below the internal limiting membrane to  $15.6 \mu\text{m}$  below the junction between the inner plexiform and inner nuclear layers (IPL/INL). This is achieved by the inbuilt auto segmentation of the instrument.

## Statistical Analysis

Data was first entered into Excel, then transferred to SPSS (IBM, version 27.0) for additional analysis. The mean, standard deviation, and 95% confidence intervals were provided for descriptive data such as age, refractive error, and duration of diabetes. To examine the association between SCPVD, age, and the duration of diabetes, the Pearson correlation coefficient was employed.

For parameters that were normally distributed, an independent *t*-test was used to compare the mean values of variables between the control and diabetic group. For parameters that were not normally distributed non-parametric test ie, Mann–Whitney *U*-test was used to compare the variables between the two groups. P-values less than 0.05 were reported as statistically significant.

## Results

A total of 54 subjects were included in the study, of whom 29 subjects were controls and 24 subjects were having DM. Among the control group 26 subjects were males and 3 were females. Among the DM group 18 subjects were males and 6 were females. Descriptive data such as age, Refractive error and duration of DM were presented in Table 1. There was no significant difference ( $P = 0.78$ ) in the age groups of control and diabetic subjects.

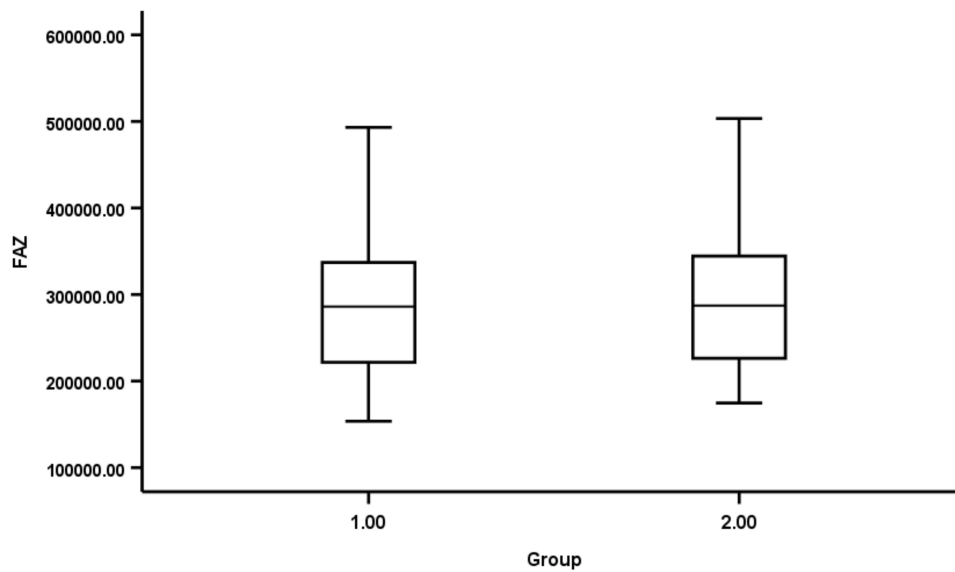
Mean FAZ values between control and diabetic subjects were shown as bar graphs (Figure 2). There was no significant difference ( $P = 0.78$ ) in mean FAZ between the two groups. Box plots illustrating the SCPVD in the central macula and across the four quadrants of macular region for both control and diabetic subjects were shown in Figure 3 with the corresponding mean values provided in Table 2. SCP VD was significantly lower in central ( $P = 0.04$ ) and Inferior ( $P = 0.01$ ) macular regions of diabetic subjects compared to controls.

Box plots illustrating the macular thickness in central region and across four quadrants of macular region for both control and diabetic subjects were shown in Figure 4 with the corresponding mean values provided in Table 3. There was a significant mean temporal macular thinning ( $P = 0.01$ ) among diabetic subjects compared to controls.

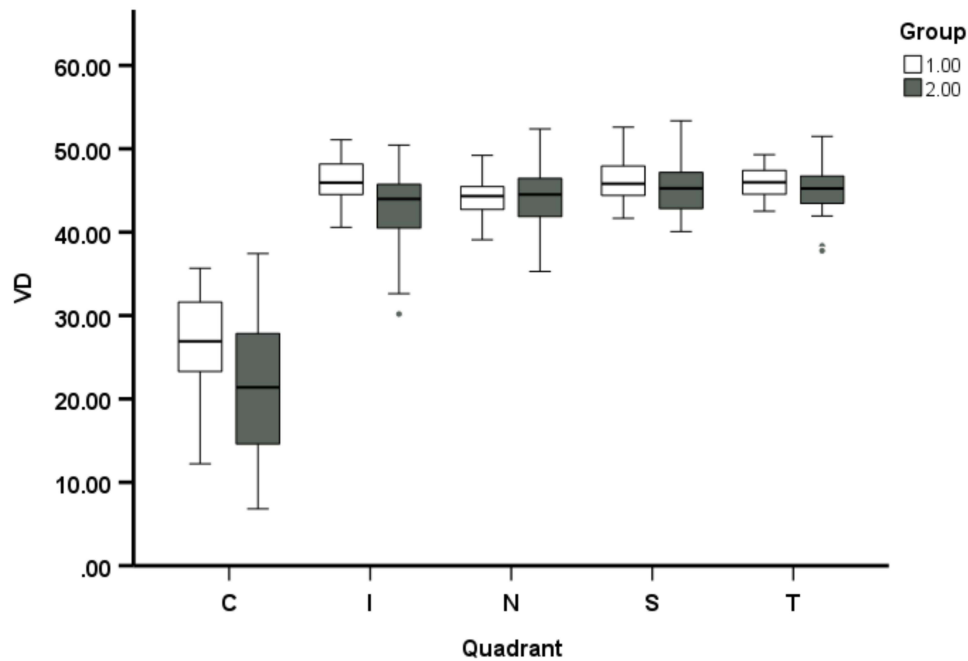
RNFL thickness across four quadrants of macula for both control and diabetic subjects were illustrated as box plots in Figure 5 with the corresponding mean values provided in Table 4. There was a significant mean superior macular RNFL thinning ( $P = 0.01$ ) among diabetic subjects compared to controls.

**Table 1** Descriptive Data of Healthy and Diabetic Subjects of the Study. SE- Spherical Equivalent, DM- Diabetes Meletus

Parameter	Healthy Subjects	DM Without DR	P value
Number of subjects	29	26	–
Age (years)	$43.97 \pm 6.67$	$47.48 \pm 7.75$	0.08
Refractive error (SE_diopters)	$-1.38 \pm 0.67$	$-0.70 \pm 1.04$	0.14
Duration of DM (years)	–	$5.56 \pm 5.75$	–



**Figure 2** Box plots show the FAZ area of control (Group 1) and diabetes (Group 2) subjects.



**Figure 3** Vessel density across the Quadrants in two groups of subjects. Error bar represents 95% confidence intervals. Thick line in the Box plots represent the mean value. Group 1 is control subjects. Group 2 is Diabetic subjects.

**Abbreviations:** VD, Vessel density; C, Central; S, Superior; N, Nasal; I, Inferior; T, Temporal.

GCL thickness in central macular region and across four quadrants of macula for both control and diabetic subjects were illustrated as box plots in [Figure 6](#) with the corresponding mean values provided in [Table 5](#). There was a significant GCL thinning across superior ( $P = 0.02$ ), nasal ( $P=0.04$ ) and temporal ( $P < 0.01$ ) quadrants of macular region among diabetic subjects compared to controls.

### Effect of DM Duration and Age on OCTA and OCT Parameters

There was high significant positive correlation between the duration of DM and superior macular VD ( $r = 0.77$ ,  $P < 0.01$ ). However, there was no significant correlation between the duration of DM and other parameters.

**Table 2** FAZ and SCPVD Mean Values Between the Two Groups

Parameter	Group 1 (Control)	Group 2 (Diabetic)	P value
FAZ ( $\mu$ meter)	290153.14 $\pm$ 77,380.89	301,032.32 $\pm$ 99,419.48	0.78
VD_Central	26.27 $\pm$ 6.60	21.69 $\pm$ 9.141	0.04*
VD_Superior	46.20 $\pm$ 2.61	45.17 $\pm$ 3.175	0.20
VD_Inferior	46.19 $\pm$ 3.08	42.78 $\pm$ 4.94	<0.01*
VD_Nasal	43.74 $\pm$ 3.03	43.91 $\pm$ 4.48	0.87
VD_Temporal	45.82 $\pm$ 2.28	45.22 $\pm$ 3.23	0.42

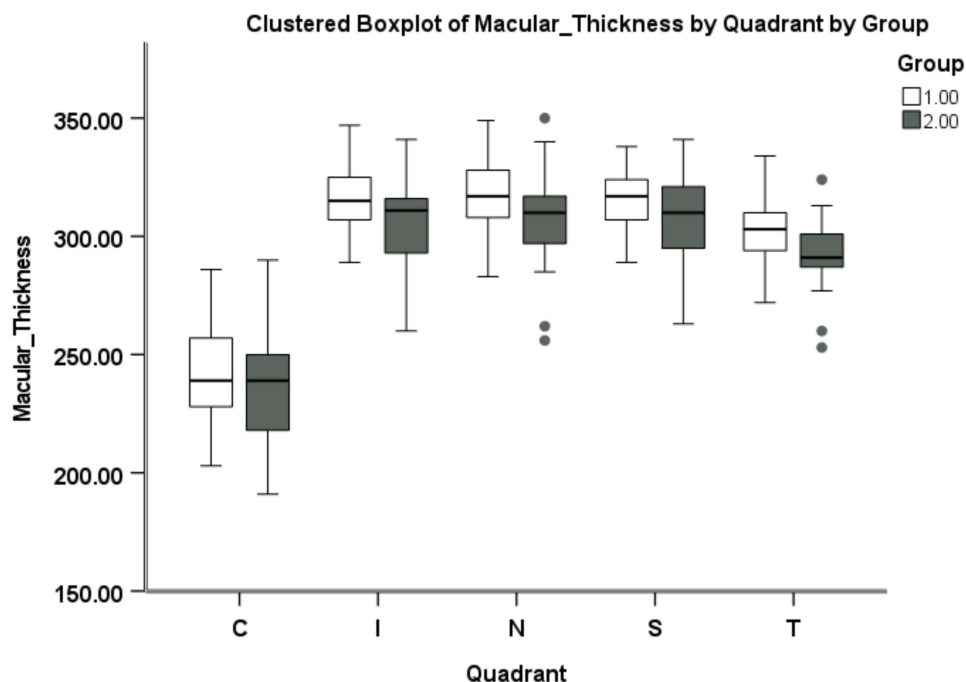
Note: \*Indicates P less than 0.05.

Age has shown significant moderate correlation with superior macular thickness ( $r = -0.33$ ,  $P = 0.01$ ), Inferior macular thickness ( $r = -0.31$ ,  $P = 0.02$ ), Nasal macular thickness ( $r = -0.28$ ,  $P = 0.04$ ), superior RNFL thickness ( $r = -0.30$ ,  $P = 0.02$ ), superior GCL thickness ( $r = -0.30$ ,  $P = 0.02$ ), and inferior GCL thickness ( $r = -0.27$ ,  $P = 0.04$ ) in the macular region.

## Discussion

The current study has shown changes in OCTA and OCT parameters in the macular region of diabetic subjects without clinical retinopathy in comparison to control subjects using swept source OCT. Results showed that the changes in localized SCPVD, MT, RNFL and GCL layers in diabetic subjects compared to controls.

Numerous studies<sup>12,14,15,22–30</sup> have examined changes in VD between healthy individuals and those with diabetes who did not exhibit clinical retinopathy, yielding inconsistent results. While some studies have identified that significant lower SCP VD in comparison to healthy individuals, other studies have shown that SCP VD does not change significantly in DM. Only a limited number of studies have directly compared local variations in SCPVD in the macular region between individuals with diabetes and healthy controls. Saif et al<sup>15</sup> found a significant decrease in vessel density in the superior, inferior, and nasal regions of the macula among diabetic subjects compared to controls. Likewise,



**Figure 4** Full retinal thickness at all macular regions in control (Group 1) and Diabetic (Group 2) subjects.

**Abbreviations:** VD, Vessel density; C, Central; S, Superior; N, Nasal; I, Inferior; T, Temporal.

**Table 3** Mean MT Values Between the Two Groups

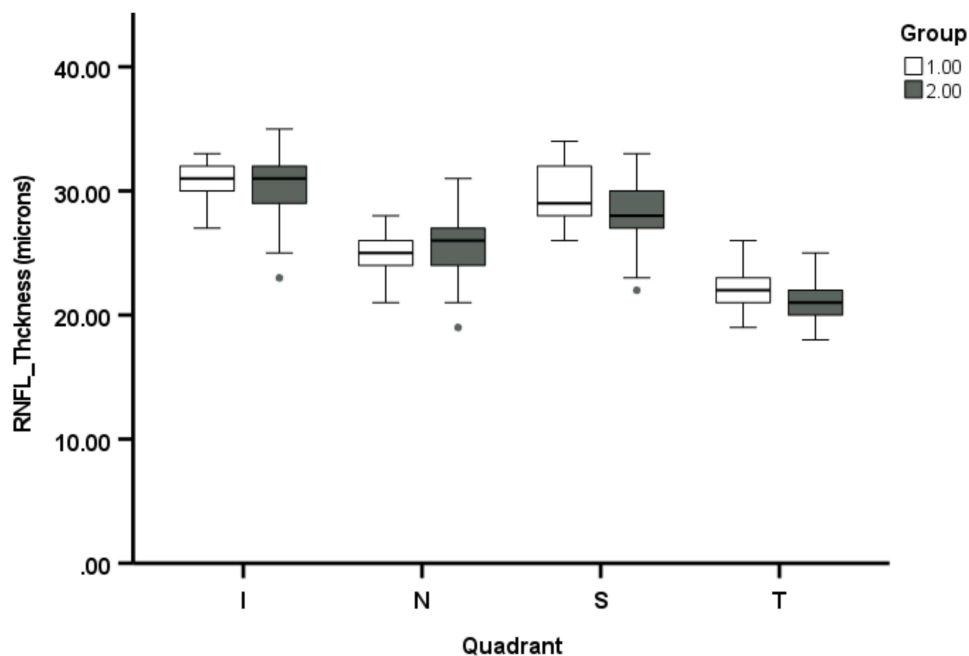
Parameter	Group 1 (Control)	Group 2 (Diabetic)	P value
MT_Central	242.96 ± 24.64	237.20 ± 23.59	0.39
MT_Superior	315.93 ± 17.05	306.96 ± 19.20	0.08
MT_Inferior	315.69 ± 14.76	306.24 ± 19.99	0.06
MT_Nasal	317.55 ± 15.20	307.56 ± 21.21	0.06
MT_Temporal	303.59 ± 13.75	292.80 ± 15.88	0.01*

Note: \*Indicates P less than 0.05.

Escobar-Villado et al<sup>26</sup> reported a significant reduction in vessel density in the superior and nasal quadrants. In our study, we discovered that SCPVD was significantly lower in the central ( $P = 0.04$ ) and inferior ( $P = 0.01$ ) regions of the macula in diabetic subjects compared to controls. Several factors could explain the variations in studies showing reduced vessel density in different regions of macula among individuals with DM compared to controls. Some possible reasons include i) Differences in the study populations, particularly in terms of ethnicity and geographic location. ii) Variations in the instruments and techniques used for measurement.

Studies on the foveal avascular zone (FAZ) in diabetic patients without retinopathy have produced inconsistent findings. Some research reports a significant increase in the FAZ area in diabetic individuals compared to controls,<sup>12,31–33</sup> while others find no notable difference between two groups.<sup>19,34,35</sup> Despite the statistical variation, DM subjects tend to exhibit a larger FAZ area than non-diabetics. In our study, we also observed an increase in the mean FAZ area in diabetic participants compared to controls, though this difference was not statistically significant. Additionally, our findings showed considerable heterogeneity in the FAZ area among healthy controls, consistent with previous studies,<sup>36–38</sup> with significant overlap between the diabetic and control groups.<sup>38,39</sup>

Recent studies have examined the differences in macular thickness between healthy individuals and diabetic patients without clinical retinopathy. Afarid et al<sup>40</sup> and Ferreira et al<sup>41</sup> found no significant differences in the thickness of the central or surrounding macular areas between diabetic patients and healthy controls. In contrast, Ezhilvendan et al<sup>42</sup> reported notable thinning of the macula in all quadrants for diabetic patients. Additionally, Chai et al<sup>25</sup> identified



**Figure 5** RNFL thickness at all macular regions in control (Group 1) and Diabetic (Group 2) subjects.

**Abbreviations:** VD, Vessel density; C, Central; S, Superior; N, Nasal; I, Inferior; T, Temporal.

**Table 4** Mean RNFL Values Between the Two Groups

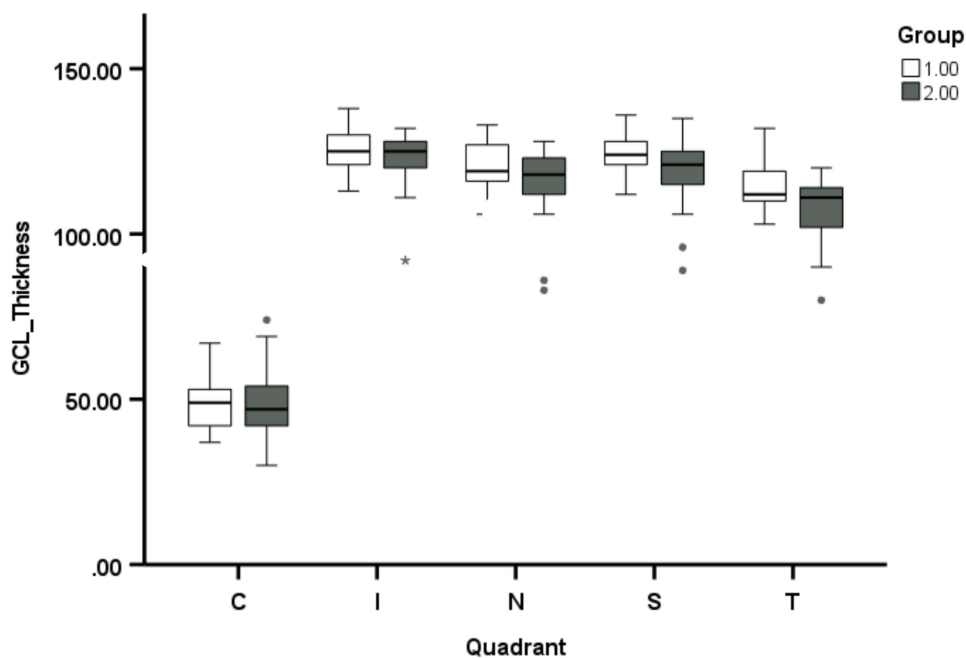
Parameter	Group 1 (Control)	Group 2 (Diabetic)	P value
RNFL_Superior	29.86 ± 2.40	28.04 ± 2.74	0.01*
RNFL_Inferior	30.62 ± 2.16	30.16 ± 2.93	0.51
RNFL_Nasal	25.27 ± 2.41	25.04 ± 2.79	0.88
RNFL_Temporal	21.90 ± 1.74	21.04 ± 1.59	0.10

Note: \*Indicates P less than 0.05.

a significant difference in the thickness of the nasal macula between diabetic subjects and controls. Current study found that diabetic patients had significant thinning in the temporal (outer side) area of the macula compared to healthy individuals. The differences in the studies do not highlight a specific region of macular thickness that would be helpful for the early detection of diabetic retinopathy.

The current study found a significant reduction in the superior RNFL thickness in diabetic subjects compared to healthy controls. This aligns with previous studies that have reported differences in RNFL thickness between healthy individuals and diabetic patients, with or without diabetic retinopathy (DR). Borooah et al<sup>43</sup> found significant differences in superior, inferior and temporal macular RNFL between diabetes and control subjects. Bhaskaran et al<sup>44</sup> observed notable differences in superior and inferior macular RNFL thickness between these groups, while Carpineto et al<sup>45</sup> and Mehboob et al<sup>46</sup> found significant differences in all quadrants. Shi et al<sup>47</sup> and Demir et al<sup>48</sup> specifically noted superior RNFL thinning, like our findings. However, Ambiya et al<sup>49</sup> and Chablani et al<sup>50</sup> reported no significant changes in RNFL thickness across all quadrants in diabetic patients without DR. Our study suggests that superior RNFL thinning could serve as an early marker for diabetic retinopathy, emphasizing the need for quadrant-specific RNFL assessments to improve early detection and monitoring of the diabetic retinopathy.

Recent research has explored how diabetes affects the thickness of the ganglion cell layer-inner plexiform layer (GCL-IPL), which may serve as an early sign of retinal damage in people with diabetes. These studies focus on comparing GCL-IPL thickness in diabetic individuals and healthy controls, aiming to better understand how diabetes contributes to changes in the retina. According to Borooah et al<sup>43</sup> diabetic patients and healthy controls differ



**Figure 6** GCL thickness at all macular regions in control (Group 1) and Diabetic (Group 2) subjects.

**Abbreviations:** VD, Vessel density; C, Central; S, Superior; N, Nasal; I, Inferior; T, Temporal.

**Table 5** Mean GCL Values in All Regions of Macula Between the Two Groups

Parameter	Group 1 (Control)	Group 2 (Diabetic)	P value
GCL_Central	50.28 ± 10.42	48.56 ± 10.99	0.56
GCL_Superior	124.28 ± 8.03	118.60 ± 10.02	0.02*
GCL_Inferior	125.17 ± 9.22	121.64 ± 10.70	0.88
GCL_Nasal	121.00 ± 7.21	115.76 ± 11.29	0.04*
GCL_Temporal	113.72 ± 6.64	107.56 ± 9.37	<0.01*

Note: \*Indicates P less than 0.05.

significantly in the thickness of the ganglion cell layer-inner plexiform layer (GCL-IPL), especially in the superior, inferior, and temporal quadrants. Similarly, Ezhilvendan et al<sup>42</sup> found that diabetes individuals and controls differed significantly in GCL thickness across all quadrants. However, according to Afef et al<sup>51</sup> and Somilleda-Ventura et al<sup>52</sup> there were no discernible variations in GCL thickness between the diabetic and control groups, and the present study has shown reduced GCL thickness in diabetic subjects compared to controls in agreement with the previous findings of GCL-IPL variance in certain locations among diabetic patients.

While current study offers useful insights into changes in vascular parameters and retinal thickness changes in the diabetic macula before signs of retinopathy appear, it has some limitations. First, we did not examine the relationship between blood glucose (HbA1c levels) and vascular changes, as participants were selected based on their self-reported diabetes status, and not everyone had recent diabetes reports. Second, there were significantly fewer female participants than male participants, so we could not analyze differences by gender, which might create a potential bias. Finally, we did not analyze the deep capillary plexus vessel density (DCPVD) an important early marker for diabetes because our equipment did not have this feature. Due to reduced vessel density in diabetic subjects, a corresponding decrease in vessel volume is expected, offering another perspective for evaluating changes in these individuals. However, the OCT instrument used in the current study lacks the capability to measure vessel volume, so this data was not reported. Few other limitations include that this is a single center study hence multi center trails are required to confirm the findings of the current study.

## Conclusion

The result from the current study in Saudi adults suggests that the diabetic macula experiences significant ganglion cell layer (GCL) thinning, Superior macular RNFL thinning, and reduced superficial capillary plexus (SCP) VD in central and inferior macular regions even before the onset of clinical retinopathy. Swept-source OCT proves to be very useful tool for detecting these early changes in diabetic patients. In the future, large cohort randomized control trails with diverse groups of people are needed to confirm these findings, as results can vary among different races.

## Disclosure

The authors report no conflicts of interest in this work.

## References

1. Stumvoll M, Goldstein BJ, Van Haefen TW. Type 2 diabetes: principles of pathogenesis and therapy. *Lancet*. 2005;365(9467):1333–1346. doi:10.1016/S0140-6736(05)61032-X
2. Weyer C, Bogardus C, Mott DM, Pratley RE. The natural history of insulin secretory dysfunction and insulin resistance in the pathogenesis of type 2 diabetes mellitus. *J Clin Invest*. 1999;104(6):787–794.
3. Galicia-Garcia U, Benito-Vicente A, Jebari S, et al. Pathophysiology of type 2 diabetes mellitus. *Int J mol Sci*. 2020;21(17):6275.
4. Nentwich MM, Ulbig MW. Diabetic retinopathy-ocular complications of diabetes mellitus. *World J Diabetes*. 2015;6(3):489. doi:10.4239/wjd.v6.i3.489
5. Badrah MH, Abdelaaty TA, Imbaby SA, Abdel-Fattah YH, Silim WM, El Feky AY. The relationship between vascular endothelial growth factor-a serum level and the severity of diabetic peripheral neuropathy. *Egypt Rheumatol Rehabil*. 2022;49(1):66.
6. Ozougwu JC, Obimba KC, Belonwu CD, Unakalamba CB. The pathogenesis and pathophysiology of type 1 and type 2 diabetes mellitus. *J Physiol Pathophysiol*. 2013;4(4):46–57. doi:10.5897/JPAP2013.0001

7. Li Y, Liu Y, Liu S, et al. Diabetic vascular diseases: molecular mechanisms and therapeutic strategies. *Signal Transduct Target Ther.* 2023;8(1):152.
8. Ting DS, Cheung GC, Wong TY. Diabetic retinopathy: global prevalence, major risk factors, screening practices and public health challenges: a review. *Clin Exp Ophthalmol.* 2016;44(4):260–277.
9. Bourne RR, Jonas JB, Bron AM, et al. Prevalence and causes of vision loss in high-income countries and in Eastern and Central Europe in 2015: magnitude, temporal trends and projections. *Br J Ophthalmol.* 2018;102(5):575–585. doi:10.1136/bjophthalmol-2017-311258
10. Hill L, Makaroff LE. Early detection and timely treatment can prevent or delay diabetic retinopathy. *Diabetes Res Clin Pract.* 2016;120:241–243. doi:10.1016/j.diabres.2016.09.004
11. Zhang Z, Deng C, Paulus YM. Advances in structural and functional retinal imaging and biomarkers for early detection of diabetic retinopathy. *Biomedicines.* 2024;12(7):1405. doi:10.3390/biomedicines12071405
12. de Carlo TE, Chin AT, Bonini Filho MA, et al. Detection of microvascular changes in eyes of patients with diabetes but not clinical diabetic retinopathy using optical coherence tomography angiography. *Retina.* 2015;35:2364–2370. doi:10.1097/IAE.0000000000000882
13. Srinivasan S, Sivaprasad S, Rajalakshmi R. Early retinal functional alteration in relation to diabetes duration in patients with type 2 diabetes without diabetic retinopathy. *Sci Rep.* 2022;12(1):11422. doi:10.1038/s41598-022-15425-x
14. Ghassemi F, Fadakar K, Berijani S, Babeli A, Gholizadeh A, Sabour S. Quantitative assessment of vascular density in diabetic retinopathy subtypes with optical coherence tomography angiography. *BMC Ophthalmol.* 2021;21(1):82. doi:10.1186/s12886-021-01831-8
15. Saif PS, Salman AEG, Omran NAH, Farweez YAT. Assessment of diabetic retinopathy vascular density maps. *Clin Ophthalmol.* 2020;14:3941–3953. doi:10.2147/OPHTH.S256963
16. Balaratnasingam C, Inoue M, Ahn S, et al. Visual acuity is correlated with the area of the foveal avascular zone in diabetic retinopathy and retinal vein occlusion. *Ophthalmology.* 2016;123(11):2352–2367. doi:10.1016/j.ophtha.2016.07.008
17. Sun Z, Tang F, Wong R. OCT angiography metrics predict progression of diabetic retinopathy and development of diabetic macular edema: a prospective study. *Ophthalmology.* 2019;126(12):1675–1684. doi:10.1016/j.ophtha.2019.06.016
18. Nesper PL, Roberts PK, Onishi AC. Quantifying microvascular abnormalities with increasing severity of diabetic retinopathy using optical coherence tomography angiography. *Invest Ophthalmol Visual Sci.* 2017;58(6):BIO307–15. doi:10.1167/iovs.17-21787
19. Ong JX, Fawzi AA. Perspectives on diabetic retinopathy from advanced retinal vascular imaging. *Eye.* 2022;36(2):319–327.
20. Waheed NK, Rosen RB, Jia Y, et al. Optical coherence tomography angiography in diabetic retinopathy. *Prog Retinal Eye Res.* 2023;97:101206.
21. Hirano T, Kitahara J, Toriyama Y, Kasamatsu H, Murata T, Sadda S. Quantifying vascular density and morphology using different swept-source optical coherence tomography angiographic scan patterns in diabetic retinopathy. *Br J Ophthalmol.* 2019;103(2):216–221.
22. Vujosevic S, Toma C, Villani E, et al. Early detection of microvascular changes in patients with diabetes mellitus without and with diabetic retinopathy: comparison between different swept-source oct-a instruments. *J Diabet Res.* 2019;2019:2547216.
23. Dai Y, Zhou H, Chu Z, et al. Microvascular changes in the choriocapillaris of diabetic patients without retinopathy investigated by swept-source OCT angiography. *Invest Ophthalmol Visual Sci.* 2020;61(3):50.
24. Carnevali A, Sacconi R, Corbelli E. Optical coherence tomography angiography analysis of retinal vascular plexuses and choriocapillaris in patients with type 1 diabetes without diabetic retinopathy. *Acta Diabetologica.* 2017;54:695–702. doi:10.1007/s00592-017-0996-8
25. Chai Q, Yao Y, Guo C, Lu H, Ma J. Structural and functional retinal changes in patients with type 2 diabetes without diabetic retinopathy. *Ann Med.* 2022;54(1):1816–1825. doi:10.1080/07853890.2022.2095010
26. Escobar-Villado SL, Lima-Gómez V. Regional parafoveal vessel density changes in diabetic patients without retinopathy. *Gaceta Médica de México.* 2021;157(4):338–342. doi:10.24875/GMM.M21000572
27. Al-Sheikh M, Akil H, Pfau M, Sadda SR. Swept-source OCT angiography imaging of the foveal avascular zone and macular capillary network density in diabetic retinopathy. *Invest Ophthalmol Visual Sci.* 2016;57(8):3907–3913.
28. Cao D, Yang D, Huang Z, et al. Optical coherence tomography angiography discerns preclinical diabetic retinopathy in eyes of patients with type 2 diabetes without clinical diabetic retinopathy. *Acta Diabetologica.* 2018;55(5):469–477.
29. Shin YI, Nam KY, Lee SE. Peripapillary microvasculature in patients with diabetes mellitus: an optical coherence tomography angiography study. *Sci Rep.* 2019;9(1):15814.
30. Wang X, Han Y, Sun G. Detection of the microvascular changes of diabetic retinopathy progression using optical coherence tomography angiography. *Trans Vision Sci Technol.* 2021;10(7):31. doi:10.1167/tvst.10.7.31
31. Di G, Weihong Y, Xiao Z. A morphological study of the foveal avascular zone in patients with diabetes mellitus using optical coherence tomography angiography. *Graefes Arch Clin Exp Ophthalmol.* 2016;254(5):873–879. doi:10.1007/s00417-015-3143-7
32. Lupidi M, Coscas G, Coscas F. Retinal microvasculature in nonproliferative diabetic retinopathy: automated quantitative optical coherence tomography angiography assessment. *Ophthalmic Res.* 2017;58(3):131–141. doi:10.1159/000471885
33. Kulikov AN, Maltsev DS, Burnasheva MA. Improved analysis of foveal avascular zone area with optical coherence tomography angiography. *Graefes Arch Clin Exp Ophthalmol.* 2018;256(12):2293–2299. doi:10.1007/s00417-018-4139-x
34. Lee H, Lee M, Chung H, Kim HC. Quantification of retinal vessel tortuosity in diabetic retinopathy using optical coherence tomography angiography. *Retina.* 2018;38(5):976–985. doi:10.1097/IAE.0000000000001618
35. Durbin MK, An L, Shemonski ND, et al. Quantification of retinal microvascular density in optical coherence tomographic angiography images in diabetic retinopathy. *JAMA Ophthalmol.* 2017;135(4):370–376. doi:10.1001/jamaophthalmol.2017.0080
36. Magrath GN, Say EA, Sioufi K, Ferenczy S, Samara WA, Shields CL. Variability in foveal avascular zone and capillary density using optical coherence tomography angiography machines in healthy eyes. *Retina.* 2017;37(11):2102–2111.
37. Chui TY, VanNasdale DA, Elsner AE, Burns SA. The association between the foveal avascular zone and retinal thickness. *Invest Ophthalmol Visual Sci.* 2014;55(10):6870–6877. doi:10.1167/iovs.14-15446
38. Lynch G, Romo JS, Linderman R, et al. Within-subject assessment of foveal avascular zone enlargement in different stages of diabetic retinopathy using en face OCT reflectance and OCT angiography. *Biomed Opt Express.* 2018;9(12):5982–5996. doi:10.1364/BOE.9.005982
39. Conrath J, Giorgi R, Raccach D, Ridings B. Foveal avascular zone in diabetic retinopathy: quantitative vs qualitative assessment. *Eye.* 2005;19(3):322–326. doi:10.1038/sj.eye.6701456
40. Afarid M, Mohsenipoor N, Parsaei H, et al. Assessment of macular findings by OCT angiography in patients without clinical signs of diabetic retinopathy: radiomics features for early screening of diabetic retinopathy. *BMC Ophthalmol.* 2022;22(1):281. doi:10.1186/s12886-022-02492-x

41. Ferreira JT, Alves M, Dias-Santos A, et al. Retinal neurodegeneration in diabetic patients without diabetic retinopathy. *Invest Ophthalmol Visual Sci.* 2016;57(14):6455–6460. doi:10.1167/iovs.16-20215
42. Ezhilvendhan K, Shenoy A, Rajeshkannan R, Balachandrachari S, Sathiyamoorthy A. Evaluation of macular thickness, retinal nerve fiber layer, and ganglion cell layer thickness in patients among type 2 diabetes mellitus using optical coherence tomography. *J Pharm Bioallied Sci.* 2021;13(S1):S1055–61. doi:10.4103/jpbs.jpbs\_165\_21
43. Borooah M, Nane YJ, Ekka J. Evaluation of thickness of retinal nerve fiber layer and ganglion cell layer with inner plexiform layer in patients without diabetic retinopathy and mild diabetic retinopathy in type 2 diabetes mellitus patients using spectral-domain optical coherence tomography. *Int J Res Med Sci.* 2018;6(7):2434–2439.
44. Bhaskaran A, Babu M, Sudhakar NA, Kudlu KP, Shashidhara BC. Study of retinal nerve fiber layer thickness in diabetic patients using optical coherence tomography. *Indian J Ophthalmol.* 2023;71(3):920–926. doi:10.4103/ijo.IJO\_1918\_22
45. Carpineto P, Toto L, Aloia R. Neuroretinal alterations in the early stages of diabetic retinopathy in patients with type 2 diabetes mellitus. *Eye.* 2016;30(5):673–679. doi:10.1038/eye.2016.13
46. Mehboob MA, Amin ZA, Islam QU. Comparison of retinal nerve fiber layer thickness between normal population and patients with diabetes mellitus using optical coherence tomography. *Pak J Med Sci.* 2019;35(1):29–33. doi:10.12669/pjms.35.1.65
47. Shi R, Guo Z, Wang F, Li R, Zhao L, Lin R. Alterations in retinal nerve fiber layer thickness in early stages of diabetic retinopathy and potential risk factors. *Curr Eye Res.* 2018;43(2):244–253. doi:10.1080/02713683.2017.1387669
48. Demir M, Oba E, Sensoz H, Ozdal E. Retinal nerve fiber layer and ganglion cell complex thickness in patients with type 2 diabetes mellitus. *Indian J Ophthalmol.* 2014;62(7):719–720. doi:10.4103/0301-4738.136234
49. Ambiya V, Kumar A, Bhavaraj VR, Sharma V, Sharma N. Study of inner retinal neurodegeneration in diabetes mellitus using spectral-domain optical coherence tomography. *Eur J Ophthalmol.* 2022;32(3):3074–3081. doi:10.1177/11206721211048793
50. Chhablani J, Sharma A, Goud A. Neurodegeneration in type 2 diabetes: evidence from spectral-domain optical coherence tomography. *Invest Ophthalmol Visual Sci.* 2015;56(11):6333–6338. doi:10.1167/iovs.15-17334
51. Afef M, Asma K, Chaker B, Faïda A, Riadh R. Retinal fiber layer and macular ganglion cell layer thickness in diabetic patients. *J Clin Exp Ophthalmol.* 2019;10(1):1–5.
52. Somilleda-Ventura SA, Blanco-Hernández DM, Ocampo-Moreno I, Lima-Gómez V. Ganglion cell layer thinning in diabetic patients without retinopathy: related or unrelated to total macular thickness? *Arquivos Brasileiros de Oftalmologia.* 2020;83(5):389–395. doi:10.5935/0004-2749.20200048

## Diabetes, Metabolic Syndrome and Obesity

### Publish your work in this journal

Diabetes, Metabolic Syndrome and Obesity is an international, peer-reviewed open-access journal committed to the rapid publication of the latest laboratory and clinical findings in the fields of diabetes, metabolic syndrome and obesity research. Original research, review, case reports, hypothesis formation, expert opinion and commentaries are all considered for publication. The manuscript management system is completely online and includes a very quick and fair peer-review system, which is all easy to use. Visit <http://www.dovepress.com/testimonials.php> to read real quotes from published authors.

Submit your manuscript here: <https://www.dovepress.com/diabetes-metabolic-syndrome-and-obesity-journal>

**Dovepress**  
Taylor & Francis Group