

# Viable Ileosigmoid Knotting, A Very Phenomenon Finding and Rare Cause of Intestinal Obstruction: A Case Report and Literature Review

Sintayehu Asrat Beyene<sup>1</sup>, Nahom Tadesse Bogale<sup>1</sup>, Mahad Mohammed Abdinasir<sup>1</sup>, Addisu Zegeye Desalegne<sup>2</sup>, Megdelawit Ayalew Wossen<sup>3</sup>

<sup>1</sup>General Surgery Unit, Department of Surgery, Jigjiga University Sheik Hassen Yabare Comprehensive Specialized Hospital, Jigjiga, Ethiopia;

<sup>2</sup>Department of Radiology, Jigjiga University Sheik Hassen Yabare Comprehensive Specialized Hospital, Jigjiga, Ethiopia; <sup>3</sup>School of Medicine and Health Sciences, Jigjiga University Sheik Hassen Yabare Comprehensive Specialized Hospital, Jigjiga, Ethiopia

Correspondence: Sintayehu Asrat Beyene; Nahom Tadesse Bogale, Email [sintayehubeyene54@gmail.com](mailto:sintayehubeyene54@gmail.com); [Tadnahi2@gmail.com](mailto:Tadnahi2@gmail.com)

**Introduction:** Ileosigmoid knotting is the wrapping of an active component of either the ileum or the sigmoid colon over each other. It is an unusual cause of intestinal obstruction, accounting for 1–2% of cases of all mechanical obstruction in the majority published literatures. A viable knot is a unique phenomenon of this seldom cause of bowel obstruction.

**Case Presentation:** A sixteen-year-old female patient presents with a complaint of central abdominal distension and obstipation of 12-hour duration. Later, she also developed abdominal cramps and vomiting of ingested matter. Her vital signs were all in the normal range, and the abdominal examination was positive for a grossly distended abdomen with mild upper and central abdominal tenderness. The ileosigmoid knotting was clearly visible on the computed tomography. Emergency exploratory laparotomy was performed, and a viable ileosigmoid knot was identified. Unknotting, derotation, and decompression of the sigmoid colon were performed. The postoperative course was uneventful.

**Discussion:** Ileosigmoid knotting is a rare, life-threatening cause of intestinal obstruction with rapid progression to intestinal vascular compromise and gangrene. It is a hyperactive segment of ileum that winds around the pedicle of the redundant sigmoid colon, resulting in a closed-loop obstruction. There are different classification schemes of ileosigmoid knotting depending on the active component of the knot and based on the viability of the bowel and physiology of the patient. Preoperative diagnosis of this condition is often challenging and usually confirmed intraoperative.

**Conclusion:** A high index of suspicion and prompt surgical exploration are crucial for the best outcome of the patient. Despite being a rare cause of intestinal obstruction, ileosigmoid knotting poses a significant morbidity and mortality to the patient. Management of a patient with viable ileosigmoid knotting is controversial, as some scholars suggest non-resective options and others recommend resective treatment as a recurrence preventive measure.

**Keywords:** ileosigmoid knotting, intestinal obstruction, acute abdomen, volvulus, unknotting, operative decompression, viable

## Introduction

Ileosigmoid knotting is wrapping a loop of ileum around the base of the redundant sigmoid colon and vice versa.<sup>1,2</sup> It was first described by Parker, entitled “Case of Intestinal Obstruction. Sigmoid Flexure strangulated by the Ileum”, and further elaborated by Shepherd.<sup>3</sup> The incidence is much lower in the western world but relatively higher in areas where sigmoid volvulus is common. It is also relatively more common in males than females, in younger age groups than the elderly, with an average peak incidence during the third to fifth decade of life.<sup>3–5</sup> Patients will present with the characteristic presentation of intestinal obstruction, abdominal cramp, distension, obstipation, and vomiting.<sup>3</sup>

Owing to the rarity of the condition, less defined clinical presentation, and inconsistent radiological signs, preoperative diagnosis is challenging.<sup>1,6</sup> The management involves adequate fluid resuscitation and expedite surgical exploration with undue delay. The surgical options depend on the status of the bowel and the general physiology of the patient.<sup>7</sup> The

primary goals of surgical management are unknotting the tie, if viable, resecting the gangrenous segment of the bowel, and maintaining the continuity of the intestine.<sup>8</sup>

Here, we will be presenting a case report of a sixteen-year-old female patient with a viable ileosigmoid knotting. We are reporting this case due to its unique nature, unfamiliarity with such a condition, and individual surgeons' experience is limited to only a few cases that have a disastrous effect on the patient outcome. This study is written in line with the Surgical CAse Report (SCARE) guidelines.<sup>9</sup>

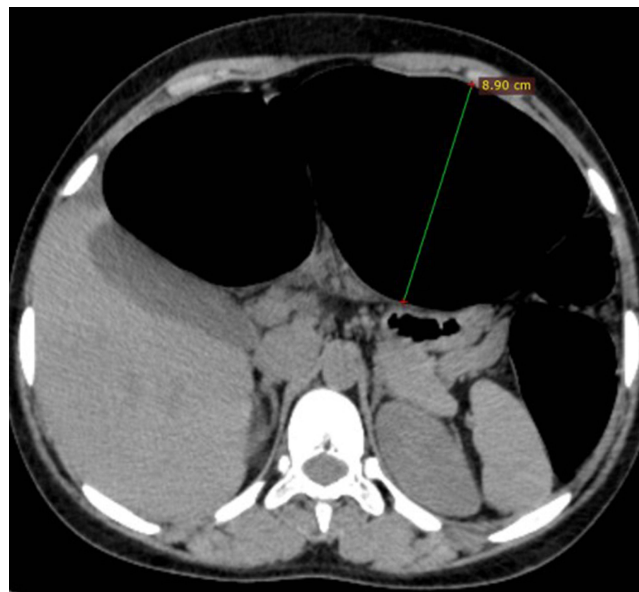
## Case Presentation

A sixteen-year-old female patient presented with a complaint of intermittent upper and central abdominal cramps associated with abdominal distension of 12-hour duration. She later developed vomiting of ingested matter and obstipation. The abdominal pain worsened later and became persistent and agonizing in type. She has no fever, chills, or rigor. She also had no vaginal discharge or bleeding; her last normal menstrual period was a week back from her presentation. Her past medical and surgical history was absent for previous abdominal surgery. She was neither an alcoholic nor a smoker.

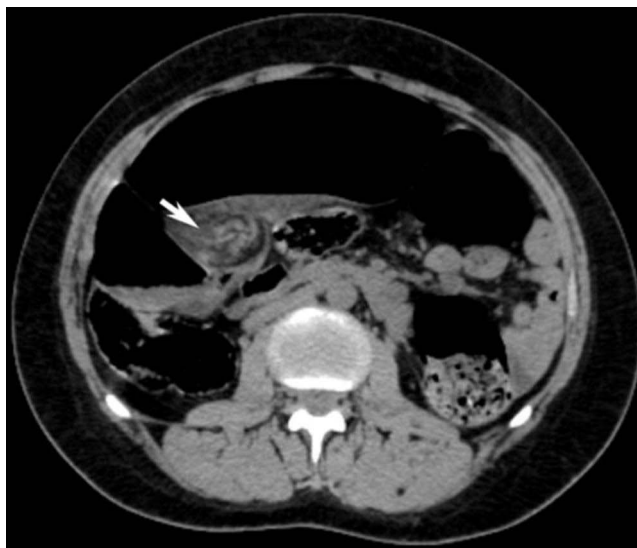Physical examination revealed an acutely sick-looking patient in pain. Her vital signs were a pulse rate of 110 beats per minute, blood pressure of 110/70 mmHg, respiratory rate of 22 breaths per minute, and temperature of 37.1°C. The pertinent physical findings were on abdominal examination, where a grossly distended central abdomen with hyperactive bowel sounds and mild upper abdominal tenderness were identified. A digital rectal examination revealed an empty rectum. As a result, possible differential diagnoses of intestinal obstruction, primary peritonitis, dyspepsia, cholecystitis, acute pancreatitis, pelvic inflammatory disease, and other gynecologic conditions were considered.

Baseline laboratory examinations showed a white cell count of  $11.9 \times 10^3/\mu\text{L}$ , hemoglobin of 12.2 g/dl, and platelet count of 248k. Urine B-HCG was negative and other blood chemistry results were unremarkable.

Imaging study with abdominal computed tomography (CT) was requested since the presentation was not typical and with myriads of differential diagnoses. Cross-sectional image indicates a significantly dilated sigmoid colon measuring 8.9 cm with air fluid levels seen in the sigmoid colon (Figure 1). It also depicts twisting and wrapping of the ileum along the base of the sigmoid colon and a characteristic whirlpool sign of mesenteric vessels (Figure 2). The diagnosis of intestinal obstruction secondary to ileosigmoid knotting was entertained, and the decision to emergency surgical exploration was made.



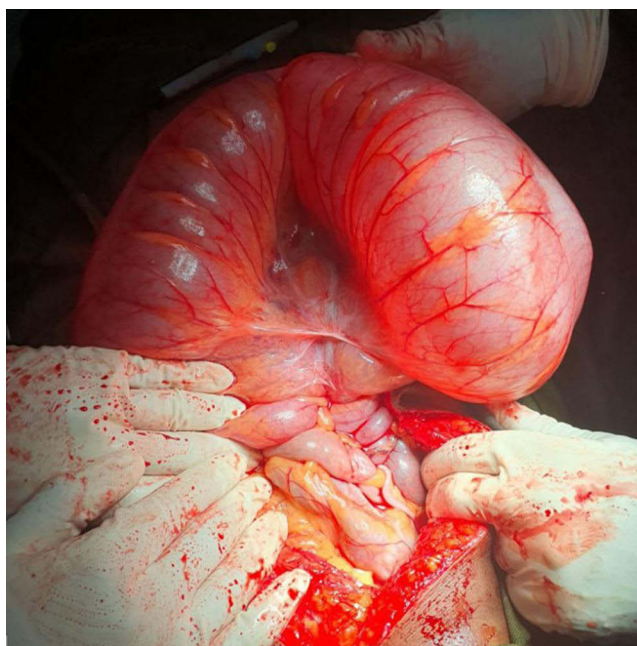
**Figure 1** Axial CT scan image at the level of T11 shows dilated sigmoid colon measuring 8.9 cm.



**Figure 2** Axial CT image, showing twisting of the ileum with wrapping of the ileum along the base of colon [arrow].

The patient was then kept nil by mouth and resuscitated with intravenous crystalloids; an NG tube was inserted; an indwelling Foley catheter was inserted; and the patient was prepared for surgical exploration after informed written consent was obtained.

We took the patient to the operating room, placing her in the supine position on the operating table. General anesthesia was given and the airway secured with an endotracheal tube. The surgical site was prepared and draped in a sterile manner. The abdomen was entered through a vertical midline abdominal incision, and the intraoperative findings were around 100 mL of serosanguinous reactive fluid, a significantly distended, elongated, and redundant sigmoid colon that has twisted 360° CCW (counter clockwise) along its mesentery and is wrapped by a loop of terminal ileum and cecum. Both the ileocecum and the sigmoid colon appear normal (Figure 3). The knot was untied, the rotated sigmoid colon was derotated CW (clockwise), and the distension was decompressed with rectal tube.



**Figure 3** Dilated, redundant sigmoid colon with winding of ileocecum.

The patient had an uneventful postoperative course, and oral feeding was resumed on the second postoperative day and discharged home on the fourth postoperative day. Subsequently, resection of the redundant sigmoid colon was performed as an elective procedure after adequate bowel preparation after two months of the initial emergency exploration. Currently, she is being followed in our outpatient department.

## Discussion

Ileosigmoid knotting is an infrequent surgical pathology that results in an immense abdominal catastrophe. It is ascribed to the enveloping of a part of the mobile ileum or sigmoid colon around the other segment. Its incidence is not well known, but the majority of the cases are described from the regions where sigmoid volvulus is common: Africa, South America, Eastern and Northern Europe, Northern and Southern Asia, and Middle Eastern countries.<sup>1,7,10,11</sup>

It demands a peculiar anatomic prerequisite of a redundant sigmoid colon with an elongated and narrow-based mesentery and a mobile small intestine with long mesentery for its pathogenesis.<sup>1,5,12</sup> The knot is initiated by a hyperactive ileum that encircles itself around the pedicle of the passive sigmoid loop. Other predisposing factors incriminated as triggering events are bulk feeding on an empty small intestine, which plays an important role in stimulating bowel activity, late pregnancy, intestinal malrotations, postoperative adhesion, internal herniation, and Meckel's diverticulum.<sup>2,4,13</sup> Several chemicals like 5-hydroxy tryptamine (rich in banana) leading to hypermotility of the ileum have also been incriminated.<sup>13</sup>

Earlier scholars tried to arbitrarily categorize the condition into four types based on the active component of the knot. Type I is when the ileum is the active segment, which wraps itself over the passive sigmoid colon in either the CW or CCW direction, whereas in type II the sigmoid colon becomes the active component in the CW or CCW direction. The third type of event is when the ileocecal segment is active and winds itself around the sigmoid colon. When it is impossible to determine what causes the knot with the other, it is called undetermined, or Type IV. The suffix A or B is added when the direction is CW or CCW, respectively. Type IA being the commonest one and Type III the most infrequent.<sup>1,5,11</sup>

The most recent and detailed classification scheme described by Atamanalp et al and categorized ileosigmoid knotting using age, American Society of Anesthesiologists physical status classification, bowel viability, and bowel anastomosis leak risk.<sup>7</sup> This updated algorithm also suggests the treatment armament and prognosticates the associated morbidity and mortality. Our patients' knotting type was Type III, which is the rarest, and Group IA, which has a favorable outcome.

Clinical features are characteristics of intestinal obstruction, which include abdominal pain, off-centre abdominal distension, nausea, vomiting, and obstipation. However, patients might have a bizarre presentation, and preoperative consideration might be divergent, similar to our case.

Preoperative diagnosis is often difficult on account of the unfamiliarity of the phenomenon and atypical radiologic findings. Laboratory studies are less sensitive and non-specific but serve as a tell-tale signal to its dire complications cascaded from the closed loop obstruction, such as sepsis and organ failure.

Plain abdominal film is the best initial imaging modality requested whenever intestinal obstruction is assumed in the differential diagnosis. It might show a dilated sigmoid colon on the right side of the abdomen and multiple small intestinal air fluid levels on the left side. Computed tomography is the best imaging modality for assisting in the diagnosis when a patient presents with vague abdominal complaints. It also has higher sensitivity and specificity.

We requested abdominal computed tomography (CT) since our patient's presentation was equivocal and the modality was available. Our patient's CT finding was similar to the text book description of ileosigmoid knotting. It reveals the findings of a sigmoid volvulus characteristically "whirl sign" generated by the twisted ileum and mesocolon. CT scan, in general, is an excellent imaging modality as it demarcates the transitional point and indicates features of bowel ischemia.<sup>13,14</sup>

The management involves judicious fluid and electrolyte resuscitation, initiation of broad-spectrum antibiotics, and emergency surgical exploration. It is crucial to differentiate it from sigmoid volvulus since rectal tube or endoscopic decompression is a contraindication for ileosigmoid knotting. Operative measures need to be carried out without inordinate delay. As time elapses, the two segments evolve to be irretrievably intertwined. The operative procedure is highly dependent on the intraoperative finding and the general physiology of the patient.<sup>8</sup>

Early vascular compromise with bowel necrosis and sepsis is the anticipated consequence of ileosigmoid knotting, which dictates damage control surgery. In the vicinity of bowel strangulation and necrosis of both segments, en-bloc resection of the involved segment is mandatory, and intestinal continuity is maintained with enteroenterostomy, preferably, and Hartmann's procedure.<sup>1,7,12</sup>

It is extremely unusual to find a viable ileosigmoid knot so that its operative management is debatable.<sup>15</sup> Certain scholars recommend untying the knot and decompression of the sigmoid colon, which will suffice without volvulus preventive measures as the recurrence rate is presumed to be low.<sup>3,7,15</sup> On the contrary, others also recommend sigmoid resection and primary anastomosis after undoing the knot in areas where sigmoid volvulus is common, provided that the patient is young, stable, and the surgeon is experienced.<sup>5–7,12</sup> Our approach was similar with the second option of management for viable knotting, but the difference is that we did the sigmoid resection as an elective procedure after optimal bowel preparation. The authors believe that it demands further study about the occurrence of ileosigmoid knotting in younger age group.

## Conclusion

Ileosigmoid knotting is a very rare etiology of intestinal obstruction with poor prognosis if confounded with bowel necrosis. It behests a high index of suspicion and consideration in every patient with acute abdomen. Core objectives of surgical management are aimed at operative undoing of the knot and decompression of the sigmoid colon, whenever viable, or resection of the necrotic segment of the bowel and maintaining intestinal continuity with primary anastomosis or Hartmann's procedure, if a non-viable intraoperative finding.

## Abbreviations

HCG, Human Chorionic Gonadotropin; CW, Clockwise; CCW, Counter Clockwise; CT, Computer Tomography; SCARE, Surgical Case Report.

## Ethical Approval

For publication of a case report at our institution, Jigjiga University, SheIk Hassen Yabare Referral Hospital, ethical approval is not necessary. This is because the patient is not involved directly in the study with interview or any other intervention. The identity of the patient is also protected and not mentioned in the case report.

## Informed Consent

Written informed consent was obtained from the patient for publication of this case report and accompanying images.

## Funding

The case report did not receive specific grant from funding agencies in the public, commercial or non-profit sectors.

## Disclosure

The authors have no conflicts of interest to declare for this work.

## References

1. Alver O, Oren D, Tireli M, Kayabaşı B, Akdemir D. Ileosigmoid knotting in turkey. review of 68 cases. *Dis Colon Rectum*. 1993;36(12):1139–1147. doi:10.1007/BF02052263
2. Kumar R, Kumar Shamanur Kenchappa P, Meena K, Singh BK. Ileosigmoid knotting: an unusual cause of acute intestinal obstruction with bowel gangrene. *BMJ Case Rep*. 2019;12(5):e226663. doi:10.1136/bcr-2018-226663
3. Shepherd JJ. Ninety-two cases of ileosigmoid knotting in Uganda. *Br J Surg*. 1967;54(6):561–566. doi:10.1002/bjs.1800540615
4. Alshaimi MA, Aljaysh MA, Alghamdi HS, Alotaibi MS, Alghamdi AA. A rare cause of acute intestinal obstruction: ileo-sigmoid knotting type IIA. *Ann Med Surg*. 2022;83:104532. doi:10.1016/j.amsu.2022.104532
5. Sseruwagi TM, Lewis C. Ileosigmoid knotting: a case series. *Cureus*. 2022;14(11):e32003. doi:10.7759/cureus.32003
6. Kotisso B, Bekele A. Ilio-sigmoid knotting in Addis Ababa: a three-year comprehensive retrospective analysis. *Ethiopian Med J*. 2006;44(4):377–383.

7. Atamanalp SS, Peksöz R, Dişçi E. Sigmoid volvulus and ileosigmoid knotting: an update. *Eurasian J Med.* 2022;54(Suppl1):91–96. doi:10.5152/eurasianjmed.2022.22310
8. Singh PK, Ali MS, Manohar DB Sr, Sethi M Jr. A challenging case of ileosigmoid knotting in an elderly. *Cureus.* 2020;12(8):e9624. doi:10.7759/cureus.9624
9. Agha RA, Franchi T, Sohrabi C, Mathew G, Kerwan A. The SCARE 2020 guideline: updating consensus surgical case report (SCARE) guidelines. *Int j Surg.* 2020;84:226–230. doi:10.1016/j.ijssu.2020.10.034
10. Atamanalp SS. Ileosigmoid knotting: an update for atamanalp classification. *Pak J Med Sci.* 2021;37(3):913–915. doi:10.12669/pjms.37.3.3179
11. Bawa D, Ikenna EC, Ugwu BT. Ileosigmoid knotting--a case for primary anastomosis. *Niger J Med.* 2008;17(1):115–117. doi:10.4314/njm.v17i1.37370
12. Abebe K, Sherefa K, Teshome H, Abebe E. Ileosigmoid knotting: analysis of patients clinical profiles and determinants of outcomes. *Surg Res Pract.* 2020;2020:3826138. doi:10.1155/2020/3826138
13. Banerjee C, Mukhopadhyay M, Roy A, Kumar J, Mukherjee S, Rahman QM. The unusual volvulus: a five year retrospective analysis of nine cases. *Indian J Surg.* 2014;76(2):100–103. doi:10.1007/s12262-012-0551-3
14. Tamura M, Shinagawa M, Funaki Y. Ileosigmoid knot: computed tomography findings and the mechanism of its formation. *ANZ J Surg.* 2004;74(3):184–186. doi:10.1046/j.1445-1433.2003.02793.x
15. Mungazi SG, Mutseyekwa B, Sachikonye M. A rare occurrence of viability of both small and large bowel in ileosigmoid knotting: a case report. *Int J Surg Case Rep.* 2018;49:1–3. doi:10.1016/j.ijscr.2018.05.024

### International Medical Case Reports Journal

### Publish your work in this journal

The International Medical Case Reports Journal is an international, peer-reviewed open-access journal publishing original case reports from all medical specialties. Previously unpublished medical posters are also accepted relating to any area of clinical or preclinical science. Submissions should not normally exceed 2,000 words or 4 published pages including figures, diagrams and references. The manuscript management system is completely online and includes a very quick and fair peer-review system, which is all easy to use. Visit <http://www.dovepress.com/testimonials.php> to read real quotes from published authors.

Submit your manuscript here: <https://www.dovepress.com/international-medical-case-reports-journal-journal>

**Dovepress**

Taylor & Francis Group