

Effect of Sub-Eyebrow Small Incision Dissection of the Corrugator Supercilii Muscle Combined with Autologous Block Fat Transplantation for the Treatment of Severe Frown Lines

Shenxing Tan^{1,*}, Changying Niu^{2,*}, Yiwu Zhang³, Zhe Cao⁴, Shan Zhang¹, Shanshan Ren¹, Xiaoshen Lu¹, Yuanyuan Liu¹

¹Department Plastic Surgery, Affiliated Hospital of Shandong second Medical University, Weifang, People's Republic of China; ²Department of Dermatology, Affiliated Hospital of Shandong second Medical University, Weifang, People's Republic of China; ³Department Plastic Surgery, Shandong second Medical University, Weifang, People's Republic of China; ⁴Department of Dermatology, Hospital of Weifang People, Weifang, People's Republic of China

*These authors contributed equally to this work

Correspondence: Yuanyuan Liu; Xiaoshen Lu, Email 898152261@qq.com; luxiaosheng2006@163.com

Objective: To explore the clinical efficacy of small sub-eyebrow incision in severing the corrugator supercilii muscle combined with autologous block fat transplantation for treating severe frown lines.

Methodology: Sixteen patients with severe frown lines admitted to our hospital who refused to receive repeated injections of botulinum toxin were selected for treatment through corrugator dissection combined with fat transplantation.

Results: No patients had difficulty raising their eyebrows after surgery. They all had a smooth eyebrow shape, no abnormal movement of the eyebrows, and no tissue depression during relaxation or frowning. At 12 months after surgery, the overall patient satisfaction with the treatment was 100%, indicating satisfactory results.

Conclusion: Treating severe frown lines with a small incision of corrugator combined with autologous block fat transplantation is more effective than traditional treatment, maintains stable and long-term satisfaction, and is associated with less postoperative complications; therefore, this technique should be promoted for treating severe frown lines.

Keywords: corrugator supercilii muscle, autologous lumpy fat, frown lines, plastic surgery

Introduction

Glabellar lines are common features of facial aging and are mainly caused by long-term excessive contraction of the frown muscle. With continuous aging of the skin, the elastic fibers of muscle tissue are weakened or broken, and their shape becomes gradually distorted, which may appear as a sad face in severe cases.¹ Injection drug therapy requires multiple repeated injections. What's more, the long-term reactions and effectiveness of the drug in the human body still require clinical verifications for patients with severe frown lines. Moreover, if intermittent treatment is not continued, there is still the possibility of worsening symptoms.² Scholars have suggested a surgical treatment plan to excise the corrugator, which aims to mimic the effect of wrinkle removal by inhibiting the contraction of the supercilii muscle, resulting in a long-term curative effect.³

Therefore, we opted for a small sub-eyebrow incision to dissect the corrugator combined with autologous block fat transplantation to fill the muscle space to obtain satisfactory results.

Methodology

Patients

We enrolled 16 female patients (average age, 45.1 years; range, 37–60 years) admitted to our hospital between January 2021 and April 2022. All patients had obvious glabellar lines and met the criteria for severe glabellar line (Fitzpatrick Wrinkle Assessment [FWA] score >3).^{4,5} The patients were unwilling to accept long-term botulinum toxin treatment and instead requested surgery. All patients have signed the informed consent form for surgery. The patients in [Figures 1](#) and [2](#) have signed a written consent form for publication. This study was approved by the Ethics Committee of the Affiliated Hospital of Shandong Second Medical University (IRB number: wyfy-2022-ky-002). All the patients signed the informed consent before the study. All the research procedures are conformed to the principle of the Declaration of Helsinki.

Surgical Schematic Diagram

Surgical Site Positioning Design

A vertical mark was made at the supraorbital foramen on the supraorbital margin (AB) and at the supratrochlear notch along the medial side of the supraorbital margin. If not reachable, the superior orbital margin, 2 cm from the midline of the plane, was selected as a vertical marker (CD). A 1-cm transverse incision marker line (BD) was drawn between the two lines close to the lower edge of the eyebrow, and a transverse marker line (AC) was drawn 1 cm from the upper edge of the eyebrow. The four lines continuously formed a rectangular frame area, which was regarded as the range of stripping of the supercillii muscle bundle and the distal height of the muscle. A vertical line (EF) was created at the midpoint of the lower incisal margin to dissect the frown muscles ([Figure 3i](#)).

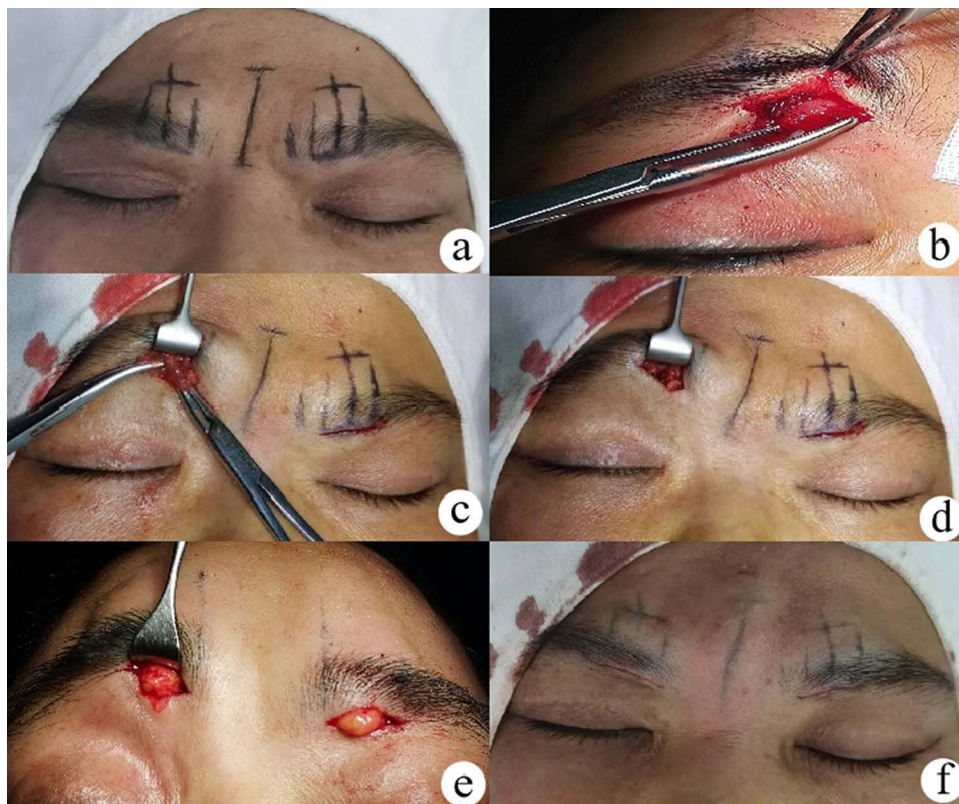


Figure 1 Surgical procedure. (a) Preoperative delineation of the surgical area. (b) The subcutaneous space and the suprapariosteal space expose the frown muscle; attention should be paid to the protection of neurovascular bundles. (c and d) The set position of the corrugator is dissected and muscle activity is viewed. (e) Autologous massive fat transplantation at the stump of muscle. (f) Immediately after surgery.

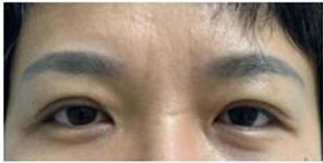

















		Pre-operatively	3-months postoperative	12-months postoperative
Case 1	Relaxed			
	FWA	score =2	score =0	score =1
	Dynamic			
	FWA	score =4	score =0	score =1
Case 2	Relaxed			
	FWA	score =3	score =0	score =1
	Dynamic			
	FWA	score =4	score =1	score =2
Case 3	Relaxed			
	FWA	score =3	score =0	score =1
	Dynamic			
	FWA	score =5	score =1	score =1

Figure 2 Case data. Static (relaxed) and dynamic (frowning) performance and corresponding Fitzpatrick Wrinkle Assessment scores before, three months after, and 12 months after surgery.

Frown Muscle Resection

After infiltrating local anesthesia, an incision was made in the skin and subcutaneous layer along the BD line, following the direction of the hair follicle growth, and the skin was separated from the subcutaneous and suprapariosteal spaces. The superficial and deep surfaces of the corrugator were exposed, and a corrugator bundle with a width of approximately 1 cm was separated with supraorbital and supratrochlear neurovascular bundles well-preserved. The muscle bundle was clamped

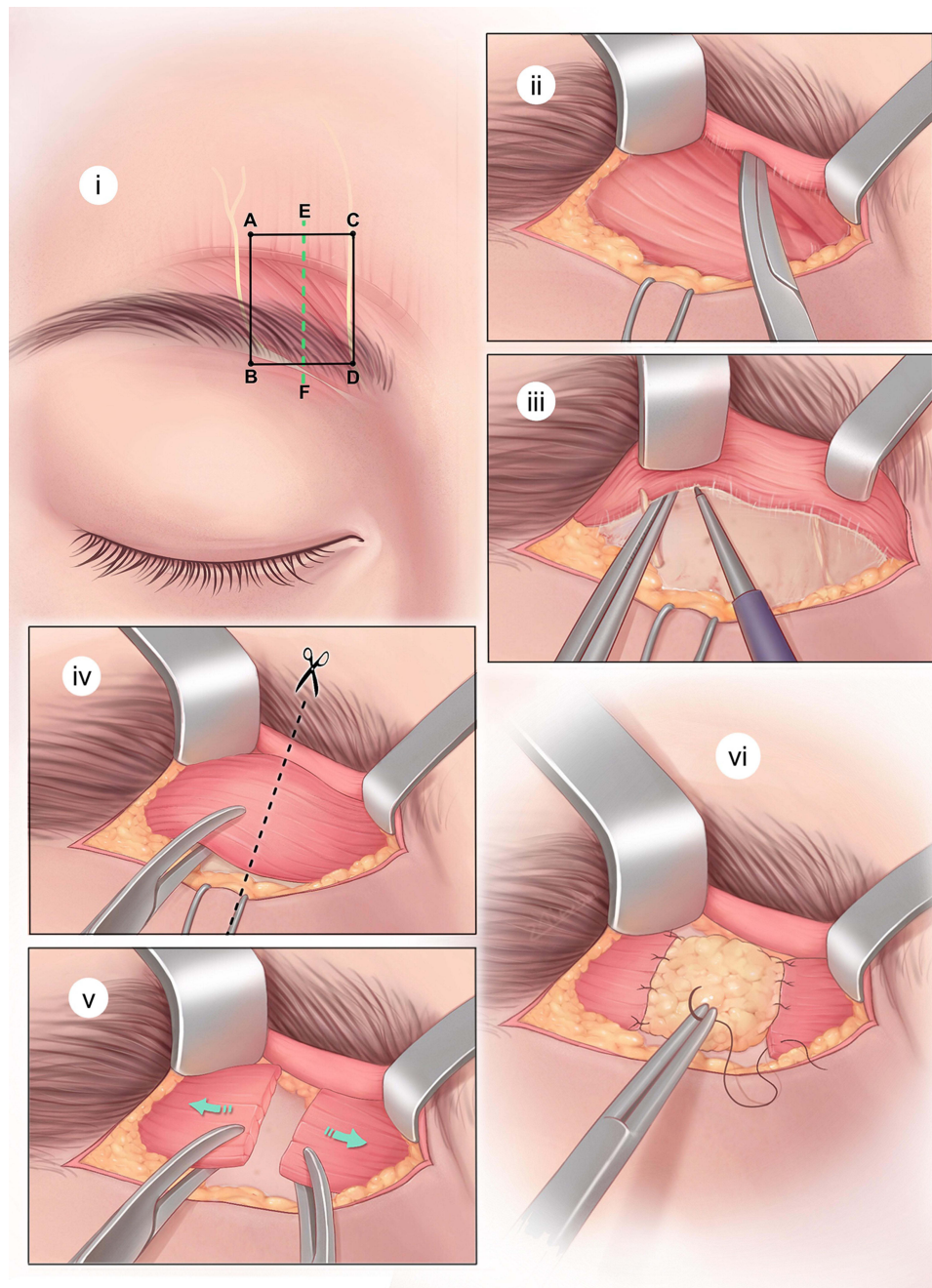


Figure 3 Surgical schematic diagram. (i) Preoperative delineation of the surgical area. (ii, iii) Dissection of subcutaneous and periosteal space. (iv, v) Resection of the corrugator muscle bundle and clamping of the retracted muscle stump. (vi) Transplantation and fixation of autologous bulk fat.

using two mosquito clamps and the corrugator was cut off along the EF line to the frontal side. Subsequently, sufficient hemostasis was achieved, and the severed ends of the corrugator were naturally retracted at both sides (Figure 3ii–v).

Massive Fat Transplantation

With the consideration of the cavity left after the corrugator resection, the resection range for fat transplantation was marked on the lower wall of the navel. A 0.5-cm incision was made at the lower edge of the umbilicus. After infiltration of local anesthesia, the skin was incised at the subcutaneous skin layer. Free bulk fat (approximately 1×1.5 cm) was cut, filled, and transplanted into the retracted gap of the severed corrugator. Simultaneously, the two ends of the bulk fat were

sutured and fixed to the severed end of the muscle with a 5–0 absorbable thread. Thereafter, the subcutaneous tissue and skin of the incision were closed layer by layer (Figure 3vi).

Surgical Procedure on Patient

The study group patients completed the surgery following the above-mentioned surgical technique principles. Additionally, fat particle transplantation was performed for filling in superficial wrinkles between the eyebrows. After tumescent anesthesia of the lower abdomen applied at the same incision as the umbilicus, the granular fat was aspirated using a 2.5-mm microporous needle. After standing and cleaning, the purified fat was obtained by centrifugation at 1000 rpm for 3 min. Chylous fat was prepared using a special A and B conversion valve, and around 1–2 mL of chylous fat was filled in the wrinkled depression between the brows. If deemed necessary, a long-term recovery period was complemented by a secondary fat filling procedure. In this group, three patients received secondary fat filling six months after the surgery. Finally, cosmetic suture the incision under the eyebrow (Figure 1a-f).

Postoperative Care

After surgery, erythromycin ointment was applied at the incision site and covered with gauze. Dressing was changed a day after the surgery, and the stitches were removed after seven days of the surgery. Patients were advised not to consume alcohol for one month.

Assessment of Patient Satisfaction

The postoperative satisfaction of the patients was assessed using the Facial Line Treatment Satisfaction (FTS) Questionnaire.

Results

For all 16 patients included in this study, the incisions were made such that the tissues are healed with primary intention, resulting in hidden scars without hyperplasia. The patients were followed up for 1–12 months postoperatively. One patient (6.3%) experienced unilateral lower one-third frontal numbness, which was resolved at one month after surgery without special treatment. None of the patients had an eyebrow lifting disorder; all had smooth eyebrow shape, and there were no instances of abnormal eyebrow movement or tissue depression upon relaxing or frowning (Figure 2).

The results of the FTS questionnaire showed that the overall satisfaction of patients with treatment at 12 months after surgery was 100% (16/16). All scoring indicators were greater than five points, indicating satisfactory results (Table 1).

In the early postoperative period, no cases of infection, hematoma, poor healing, or skin necrosis occurred. Within one month after surgery, only one case experienced mild numbness in one side of the forehead, with an incidence rate of 8.3%. But during the 3-month follow-up after surgery, the patient's frontal sensation returned to normal. After the follow-up of 12 months, all patients could raise their eyebrows normally, and the skin was smooth without depression, and the eyebrows were natural and smooth.

Table 1 Evaluation of Postoperative Satisfaction of the Study Patients (n=16)

	N (%)					
	Treatment Effect Satisfaction		Treatment Process Satisfaction		Total Satisfactory Degree	
	3 Months	12 Months	3 Months	12 Months	3 Months	12 Months
Dissatisfied	1 (6.3)	0 (0)	2 (12.5)	0 (0)	0 (0)	0 (0)
Satisfied	15 (93.7)	16 (100)	14 (87.5)	16 (100)	16 (100)	16 (100)

Discussion

Once a frowning eyebrow pattern occurs, it can provide an appearance of melancholy, aging, and sadness. It generally manifests earlier in individuals who habitually frown, presenting a crucial challenge in improving facial rejuvenation.⁶ Injection of botulinum toxin is a common treatment for patients with mild and moderate symptoms. Occasionally combined with a filler or laser treatment, botulinum injection can enhance the appearance of the patient; however, repeated treatment is needed to maintain its curative effect. Patients with severe frown lines can only improve their local symptoms by injecting botulinum toxin or fillers, and their own treatment demands are often unmet.^{7,8} Therefore, resection of the supercillii muscle has become a common surgical method for treating severe frown lines.⁹ This operate requires experienced plastic surgeons who familiarize with the facial anatomical structure, which could avoid vascular and nerve damage better; otherwise, temporary or permanent forehead sensory numbness is likely to occur.¹⁰

In the early stages of this study, we examined cadaver perfusion anatomy and reviewed the relevant literature. The position of the supraorbital nerve through the supraorbital foramen is relatively accurate and tangible and was set as the AB vertical line. However, the location of the supratrochlear nerve outside the orbital foramen is usually unclear hence, prone for inadvertent damage. To avoid damage to the neurovascular bundle, the CD vertical line was set to 2 cm from the median line, and the midpoint vertical line EF between the two vertical lines was considered as the supercillii muscle transection surgical path. Under direct vision, the supraorbital and supratrochlear nerves were identified to avoid secondary damage.^{11,12} According to the anatomical parameters of supercillii muscle, we adopted a small incision approach under the eyebrow. Only the horizontal transverse muscle bundle was resected, and the total muscle resection length was set to 2 cm. Considering that the average width of an Asian eyebrow is approximately 1 cm, the farthest cut-off distance was 1 cm above the eyebrow. In the long term, the frown lines improved satisfactorily, indicating that the resection position and width can sufficiently correct severe frown lines.

The severed end of the muscle bundle naturally retracts to both sides after the resected supercillii muscle, and the lack of muscle continuity leaves a concave tissue cavity. Residual muscle fibers may re-adhere and lead to relapse over time, or cause movement of abnormal muscle.¹³ To solve these problems, selecting a suitable filling material to repair the local depression and construct the continuity of bridge reconstruction tissue is necessary to ensure the success of the surgery and prevent complications. Commonly used filling materials include hyaluronic acid, collagen, and autologous granular fat; however, these are completely or partially absorbed and do not continue to act on the recipient area. The risk of displacement is not considered suitable for a depressed defect area.¹⁴ Based on the tissue morphology of autologous fat granules, we used autologous massive adipose tissue as a graft filler. Experimental studies have found that the survival volume of massive fat remains at approximately 50% after three months, and the morphological structure of fat cells is close to normal;¹⁵ that is, it can fill the volume to repair the depression and can also serve to bridge tissue continuity and prevent adhesion recurrence.

The patients were followed-up for 12 months. No local collapse or abnormal eyebrow movement was observed. The correction of frown lines was satisfactory, and no case of recurrence was noted. Due to the small sample size of our study, we will continue to apply this surgical treatment method in our future work, track and follow up the 95% CI of patients' wrinkle improvement postoperative scores, and further verify the safety and effectiveness of the surgery. Meanwhile, it is still necessary to observe the occurrence of complications, such as fat absorption and abnormal linkage.

In conclusion, for patients with severe frown lines, a small sub-eyebrow incision approach was adopted to sever the horizontal muscle bundle of the corrugator within the set range and, at the same time, autologous massive fat transplantation was performed to fill the defect area of the muscle stump. This approach results in less trauma, a definite curative effect, stable and lasting long-term satisfaction, and a low incidence of postoperative complications, making it a safe, effective, and valuable surgical method worthy of promotion and reference.

Funding

Weifang Youth Medical Talent Support Project Funding (42). Science and Technology Development Project of the Affiliated Hospital of Shandong Second Medical University (2024FYQ007, 2024FYM023).

Disclosure

Shenxing Tan and Changying Niu are co-first authors for this study. The authors report no conflicts of interest for this study.

References

1. de Maio M, Swift A, Signorini M, Fagien S. Aesthetic leaders in facial aesthetics consensus committee. Facial assessment and injection guide for botulinum toxin and injectable hyaluronic acid fillers: focus on the upper face. *Plast Reconstr Surg.* 2017;140(2):265e–276e. doi:10.1097/PRS.0000000000003544
2. Kaufman-Janette J, Cox SE, Dayan S, Joseph J. Botulinum toxin type A for glabellar frown lines: what impact of higher doses on outcomes? *Toxins.* 2021;13(7):494. doi:10.3390/toxins13070494
3. Guyuron B, Son JH. Transpalpebral corrugator resection: 25-year experience, refinements and additional indications. *Aesthetic Plast Surg.* 2017;41(2):339–345. doi:10.1007/s00266-017-0780-8
4. Honeck P, Weiss C, Sterry W, Rzany B, Study Group G. Reproducibility of a four-point clinical severity score for glabellar frown lines. *Br J Dermatol.* 2003;149(2):306–310. doi:10.1046/j.1365-2133.2003.05436.x
5. Cox SE, Finn JC, Stetler L, Mackowiak J, Kowalski JW. Development of the facial lines treatment satisfaction questionnaire and initial results for botulinum toxin type A-treated patients. *Dermatol Surg.* 2003;29(5):444–449. doi:10.1046/j.1524-4725.2003.29111.x
6. Zhang J, Hou W, Feng S, Chen X, Wang H. Classification of facial wrinkles among Chinese women. *J Biomed Res.* 2017;31(2):108–115. doi:10.7555/JBR.31.20150175
7. Kim JE, Song EJ, Choi GS, Lew BL, Sim WY, Kang H. The efficacy and safety of liquid-type botulinum toxin type A for the management of moderate to severe glabellar frown lines. *Plast Reconstr Surg.* 2015;135(3):732–741. doi:10.1097/PRS.0000000000001032
8. Frampton JE, Easthope SE. Botulinum toxin A (Botox Cosmetic): a review of its use in the treatment of glabellar frown lines. *Am J Clin Dermatol.* 2003;4(10):709–725. doi:10.2165/00128071-200304100-00005
9. Starkman SJ, Sherris DA. Association of corrugator supercilii and procerus myectomy with endoscopic browlift outcomes. *JAMA Facial Plast Surg.* 2019;21(5):375–380. doi:10.1001/jamafacial.2018.2084
10. Janis JE, Ghavami A, Lemmon JA, Leedy JE, Guyuron B. The anatomy of the corrugator supercilii muscle: part II. Supraorbital nerve branching patterns. *Plast Reconstr Surg.* 2008;121(1):233–240. doi:10.1097/01.prs.0000299260.04932.38
11. Konofaos P, Soto-Miranda MA, Ver Halen J, Fleming JC. Supratrochlear and supraorbital nerves: an anatomical study and applications in the head and neck area. *Ophthalmic Plast Reconstr Surg.* 2013;29(5):403–408. doi:10.1097/IOP.0b013e318295fa09
12. Nanayakkara D, Manawaratne R, Sampath H, Vadysinghe A, Peiris R. Supraorbital nerve exits: positional variations and localization relative to surgical landmarks. *Anat Cell Biol.* 2018;51(1):19–24. doi:10.5115/acb.2018.51.1.19
13. Lee EJ, Hwang K. Depressor muscle division through a subbrow excision for the improvement of brow ptosis. *J Craniofac Surg.* 2013;24(6):1987–1990. doi:10.1097/SCS.0b013e3182a28bc8
14. Ignaciuk A, Olszański R, Rybak Z, et al. Recommendations of the Polish society of aesthetic and anti-aging medicine concerning the application of fillers in difficult areas: eye, glabella and temple. *Wiad Lek.* 2019;72(12 cz 1):2383–2391. (). doi:10.36740/WLek201912121
15. Bai Y, He YJ, Zhang H, et al. Experimental study on autograft fat tissue in rabbit orbit. *Chin J Exp Ophthalmol.* 2006;24:70–73.

Clinical, Cosmetic and Investigational Dermatology

Publish your work in this journal

Clinical, Cosmetic and Investigational Dermatology is an international, peer-reviewed, open access, online journal that focuses on the latest clinical and experimental research in all aspects of skin disease and cosmetic interventions. This journal is indexed on CAS. The manuscript management system is completely online and includes a very quick and fair peer-review system, which is all easy to use. Visit <http://www.dovepress.com/testimonials.php> to read real quotes from published authors.

Submit your manuscript here: <https://www.dovepress.com/clinical-cosmetic-and-investigational-dermatology-journal>

Dovepress
Taylor & Francis Group