


Appendicitis After Initiation of Tirzepatide

Garrett Chan ¹, Mariam Ansar¹, Marlena Klein^{1,2}¹Department of Internal Medicine, Cooper University Hospital, Camden, New Jersey, USA; ²Cooper Medical School of Rowan University, Camden, New Jersey, USACorrespondence: Garrett Chan, Email chan-garrett@cooperhealth.edu

Abstract: Tirzepatide is a GLP1/GIP receptor agonist that is used to treat type 2 diabetes and promote weight loss. Common side effects of Tirzepatide include nausea, vomiting, and diarrhea. More severe side effects include pancreatitis, cholelithiasis, thyroid cancer, and cholecystitis. With the increased use of these medications, additional side effects are being discovered. Delayed gastric emptying associated with GLP1/GIP receptor agonists can increase the risk of developing appendicitis due to changes in gastrointestinal motility. There is minimal data on the risk of developing appendicitis with Tirzepatide. This novel case report presents a 73-year-old female patient, without typical risk factors or obvious triggers, who developed appendicitis one week following the initiation of Tirzepatide. Once Tirzepatide was stopped, the patient's symptoms dramatically improved and there was improvement also demonstrated on CT imaging. The patient eventually got an outpatient appendectomy. Appendicitis is not frequently reported as a GLP1/GIP receptor agonist side effect in clinical studies. There seems to be a temporal association between Tirzepatide and the onset of appendicitis. This case report highlights the importance of considering appendicitis as a potential adverse effect of Tirzepatide, a GLP1/GIP receptor agonist.

Keywords: GLP1 receptor agonists, GIP receptor agonists, Tirzepatide, appendicitis, diabetes, obesity

Introduction

GLP1/GIP receptor agonists have been effective medications to treat type 2 diabetes. These medications, such as Tirzepatide, stimulate the pancreas to produce insulin, delay gastric emptying, and reduce appetite cravings. With the increased use of these medications, additional side effects are being discovered. Delayed gastric emptying associated with GLP1/GIP receptor agonists may increase the risk of appendicitis due to changes in gastrointestinal motility. We present a novel case of a 73-year-old female who presented to the emergency department with acute appendicitis one week after being initiated on Tirzepatide. Based on clinical studies, appendicitis is not frequently reported as a side effect of GLP1/GIP receptor agonists.

Case Report

A 73-year-old female with type 2 diabetes, hyperlipidemia, depression, and obesity (BMI 38.5) presented with worsening abdominal pain for three days. The pain was located in the right lower quadrant, described as sharp, stabbing, and non-radiating, with a severity of 9/10. The associated symptoms included nausea, vomiting, and diarrhea. No aggravating or alleviating factors were identified. The medication list included Tirzepatide, metformin, atorvastatin, omeprazole, and bupropion. The patient was started on Tirzepatide one week prior for type 2 diabetes and weight loss. There were no other changes that the patient noted within the last month other than the initiation of Tirzepatide. Notably, the patient had a normal colonoscopy three years ago.

Vitals on admission were 126/60 mmHg, temp 97.5 F, HR 76/min, and SpO₂ 96%. On physical exam, pertinent findings included tenderness in the right lower quadrant on palpation without guarding or rebound. Laboratory results were significant for leukocytosis (WBC 14.7), hypokalemia, and hyponatremia. The CT Abdomen/ Pelvis imaging findings were consistent with acute appendicitis with rupture (Figures 1 and 2). The general surgery team decided that no urgent intervention was needed. The patient was started on Zosyn IV antibiotics, fluids, and pain medications. The

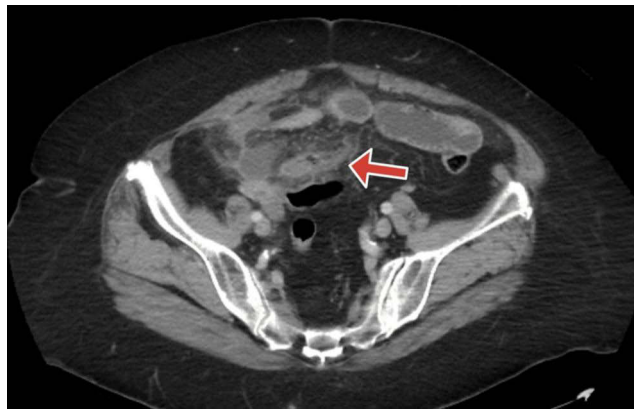


Figure 1 CTAP in axial view. The red arrow is showing acute appendicitis with rupture.

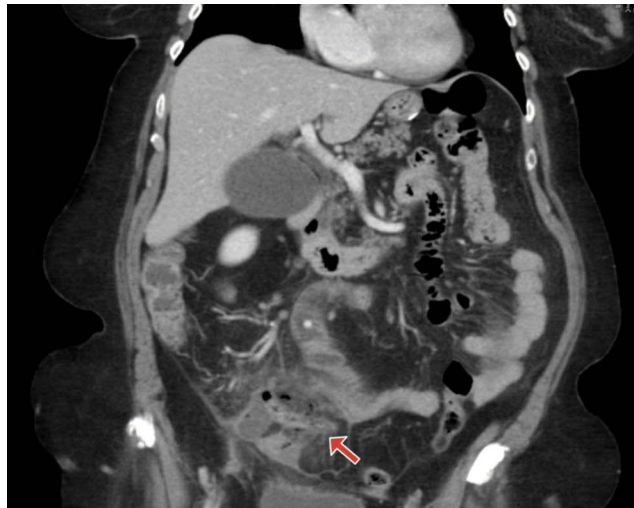


Figure 2 CTAP in coronal view. The red arrow is showing acute appendicitis with rupture.

patient's abdominal pain, electrolytes, and leukocytosis improved. She remained afebrile and was clinically stable. She was discharged on Augmentin antibiotics for 10 days. As part of conservative management, an outpatient appendectomy was scheduled.

Prior to the patient's planned appendectomy surgery date, the patient experienced increased right lower quadrant pain, prompting her to return to the emergency department. Vitals were stable and the exam remained unchanged from the prior admission. The CT Abdomen/Pelvis revealed unchanged inflammation of the appendix, along with a new enteroenteric fistula formation. The patient was advised to stop Tirzepatide, started on antibiotics, and administered intravenous fluids. The general surgery team placed the JP drain for the fistula and deemed that no urgent intervention was necessary. The patient was advised to have the outpatient appendectomy that was already scheduled. Her abdominal symptoms resolved drastically over the next week. A repeat CT Abdomen/Pelvis was obtained after symptom resolution, and it showed decreased inflammation of the appendix (Figures 3 and 4). During the following week, the patient was taken for an elective laparoscopic appendectomy as originally planned, after which her clinical course was unremarkable.

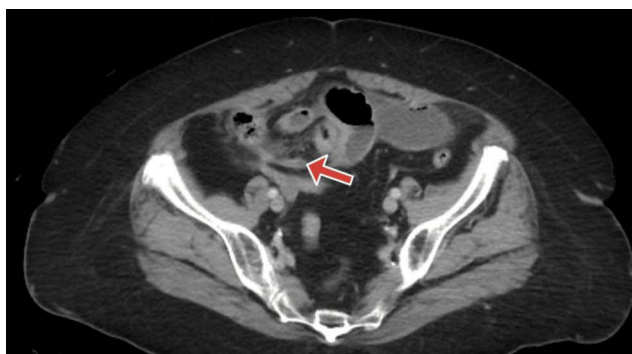


Figure 3 CTAP in axial view. The red arrow is showing decreased inflammation of the appendix after Tirzepatide cessation.

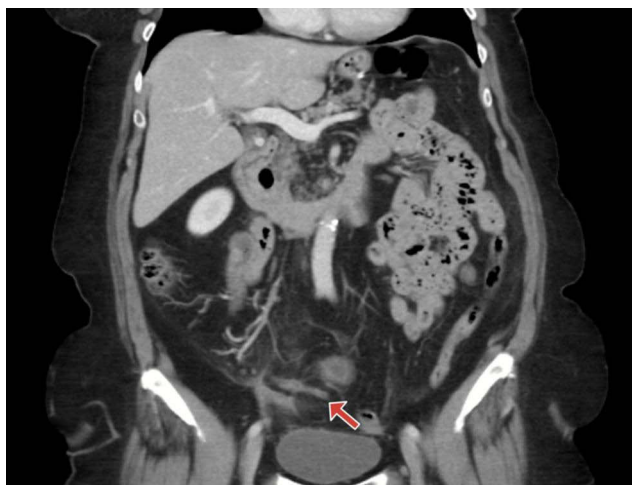

Figure 4 CTAP in coronal view. The red arrow is showing decreased inflammation of the appendix after Tirzepatide cessation.

Discussion

There is an increasing demand for medical providers to prescribe GLP1/GIP receptor agonists, as they improve type 2 diabetes and manage obesity by reducing baseline body weight by 10–20%.¹ GLP1/GIP receptor agonists such as Tirzepatide stimulate insulin and suppress glucagon release, thereby lowering blood sugar levels, delaying gastric emptying, reducing appetite cravings, and enhancing satiety. Contraindications for GLP1 receptor agonist use include pancreatitis and history of medullary thyroid cancer. The most common side effects of GIP/GLP1 receptor agonists include nausea, vomiting, constipation, dyspepsia, and diarrhea, as shown in the SURMOUNT 3 trial.² Adverse side effects of Tirzepatide are diverse, including acute pancreatitis, cholelithiasis, severe hypoglycemia, and cholecystitis which have been reported to be present in less than 1% of all doses of Tirzepatide, along with anaphylaxis in some patients.³

Appendicitis is the most common abdominal surgical emergency worldwide, with significant cost burden on healthcare, and can lead to serious complications, including ileus, peritonitis, abscess, and even death.⁴ There is minimal data to reflect the risk of appendicitis with Tirzepatide, but one clinical study depicted appendicitis several months after starting Semaglutide, a GLP-1 receptor agonist.⁵ Although Tirzepatide and Semaglutide are similar, they are slightly different. A more novel medication, Tirzepatide is a GLP1/GIP receptor agonist, whereas Semaglutide is only a GLP1 receptor agonist.⁶ Tirzepatide has an additional GIP receptor agonist function that can lead to a different side-effect profile. Severe adverse effects such as pancreatitis, transaminitis, cholelithiasis, COVID19 pneumonia, hypoglycemia, and injection site reactions, were more common in people taking Tirzepatide than in those taking Semaglutide.⁷

Angiotensin-converting enzyme (ACE) inhibitors and angiotensin receptor blockers (ARBs) have been shown to cause appendicitis.⁸ In an analysis of FAERS (FDA Adverse Event Reporting System), interferon beta, etanercept, and infliximab have been associated with appendicitis.⁹ Because of the delayed gastric emptying associated with GLP1/GIP receptor agonists, patients may be at a higher risk of developing appendicitis. GLP1/GIP receptor agonist medications such as Tirzepatide decrease gastric motility by suppressing peristalsis and increasing pyloric region contraction. As a result, fecaliths are formed, which cause blockage of the appendix. Obstruction of the appendix increases intraluminal pressure, which causes inflammation, bacterial overgrowth leading to infection, and appendiceal mucosal ischemia. If these complications are not treated, they can progress to gangrene and perforation of the appendix, which can be deadly.¹⁰

Major risk factors for appendicitis include family history and male sex category. Individuals between the ages of 5 and 45, with a mean age of 28 years, are more likely to have appendicitis.¹¹ Tirzepatide was continued despite having appendicitis when discharged with improvement after the first hospitalization. The medical team during the first hospitalization did not consider Tirzepatide to have played a role in causing appendicitis. It was not until the relapse of GI symptoms leading to the second hospitalization, while still on Tirzepatide and despite completing antibiotics, that the medical team started considering Tirzepatide as a potential cause of appendicitis. Our patient was a 73-year-old female with no family history and a recent normal colonoscopy. This may have been an atypical presentation of appendicitis. Our patient did not take any culprit medications that were previously reported to increase risk of appendicitis. Appendicitis occurred one week after the initiation of Tirzepatide, which demonstrates a temporal association between this medication and appendicitis. The fact that there was an improvement while stopping the offending drug supports this theory.

Conclusion

Tirzepatide is a safe and effective option for treating type 2 diabetes and promoting weight loss in patients with obesity. However, as with any medication, side effects must be fully considered as part of the decision making process to initiate a medication. This case report aims to increase awareness and consideration of appendicitis among medical providers as a potential side effect in patients taking Tirzepatide and GLP1/GIP receptor agonists. Further studies would be required to establish a causative relationship between Tirzepatide and appendicitis. The conclusions from this case report can influence clinical decision making and patient counseling regarding the risks and benefits of Tirzepatide.

Consent for Publication

A written consent was obtained from the participant. The participant agreed to have the case and images published. Institutional approval was not required for publication of this case report.

Disclosure

The authors report no conflicts of interest in this work.

References

1. Garvey WT, Batterham RL, Bhatta M, et al. Two-year effects of semaglutide in adults with overweight or obesity: the STEP 5 trial. *Nat med.* 2022;28(10):2083–2091. doi:10.1038/s41591-022-02026-4
2. Meng Z, Yang M, Wen H, Zhou S, Xiong C, Wang Y. A systematic review of the safety of tirzepatide—a new dual GLP1 and GIP agonist - is its safety profile acceptable? *Front Endocrinol.* 2023;14:1121387. doi:10.3389/fendo.2023.1121387 PMID: 37051199; PMCID: PMC10084319.
3. Mishra R, Raj R, Elshimy G, et al. Adverse Events Related to Tirzepatide. *J Endocr Soc.* 2023;7(4):bvad016. doi:10.1210/jendso/bvad016 PMID: 36789109; PMCID: PMC9915969.
4. D'Souza N, Nugent K. Appendicitis. *Am Fam Physician.* 2016;93(2):142–143.
5. Casella S, Galli K. Appendicitis: a hidden danger of GLP-1 receptor agonists? *J Pharm Technol.* 2024;40(2):108–111. doi:10.1177/87551225231216638
6. Andraos J, Muhar H, Smith S. Beyond glycemia: comparing tirzepatide to GLP-1 analogues. *Rev Endocr Metab Disord.* 2023;24(6):1089–1101. doi:10.1007/s11154-023-09825-1
7. Frias JP, Davies MJ, Rosenstock J, et al. Tirzepatide versus semaglutide once weekly in patients with type 2 diabetes. *N Engl J Med.* 2021;385(6):503–515. doi:10.1056/nejmoa2107519

8. Mukamal KJ, Ghimire S, Pandey R, Fiarman GS, Gautam S. Angiotensin-converting enzyme inhibitors, angiotensin-receptor blockers, and risk of appendicitis. *Ann Epidemiol.* 2012;22(10):747–750. doi:10.1016/j.annepidem.2012.07.001 Epub 2012 Aug 4. PMID: 22867943. Angiotensin-converting enzyme inhibitors, angiotensin-receptor blockers, and risk of appendicitis - PubMed (nih.gov).
9. Ramai D, Mozell D, Facciorusso A, et al. Medications and the risk of perforated appendicitis: an adverse event report system (FAERS) database analysis. *Expert Rev Gastroenterol Hepatol.* 2022;16(10):1011–1017. doi:10.1080/17474124.2022.2143346 Epub 2022 Nov 11. PMID: 36322707.
10. Nakatani Y, Maeda M, Matsumura M, et al. Effect of GLP-1 receptor agonist on gastrointestinal tract motility and residue rates as evaluated by capsule endoscopy. *Diab Metab.* 2017;43(5):430–437. doi:10.1016/j.diabet.2017.05.009
11. Jones MW, Lopez RA, Deppen JG. Appendicitis. National Library of Medicine. Available from: <https://www.ncbi.nlm.nih.gov/books/NBK493193/>. Accessed January 22, 2025.

Diabetes, Metabolic Syndrome and Obesity

Dovepress
Taylor & Francis Group

Publish your work in this journal

Diabetes, Metabolic Syndrome and Obesity is an international, peer-reviewed open-access journal committed to the rapid publication of the latest laboratory and clinical findings in the fields of diabetes, metabolic syndrome and obesity research. Original research, review, case reports, hypothesis formation, expert opinion and commentaries are all considered for publication. The manuscript management system is completely online and includes a very quick and fair peer-review system, which is all easy to use. Visit <http://www.dovepress.com/testimonials.php> to read real quotes from published authors.

Submit your manuscript here: <https://www.dovepress.com/diabetes-metabolic-syndrome-and-obesity-journal>