

Lesion Location and Possible Etiology of Acute Unilateral Vestibulopathy

Menglu Zhang^{1,2,*}, Jianrong Wang^{1,2,*}, Siru Xue¹, Shui Liu³, Kangzhi Li⁴, Tongtong Zhao^{1,2}, Yufei Feng^{1,2}, Rubo Sui², Bentao Yang⁵, Xu Yang¹

¹Department of Neurology, Aerospace Center Hospital, Peking University Aerospace School of Clinical Medicine, Beijing, 100049, People's Republic of China; ²Department of Neurology, The First Affiliated Hospital of Jinzhou Medical University, Jinzhou, 121001, People's Republic of China; ³Department of Radiology, Aerospace Center Hospital, Peking University Aerospace School of Clinical Medicine, Beijing, 100049, People's Republic of China; ⁴Department of Neurology, Peking University Shougang Hospital, Beijing, 100144, People's Republic of China; ⁵Department of Radiology, Beijing Tongren Hospital, Capital Medical University, Beijing, 100730, People's Republic of China

*These authors contributed equally to this work

Correspondence: Xu Yang, Department of Neurology, Aerospace Center Hospital, Peking University Aerospace School of Clinical Medicine, 15 Yuquan Road, Haidian District, Beijing, 100049, People's Republic of China, Tel +86010-59971978, Email yangxu2011@163.com; Bentao Yang, Department of Radiology, Beijing Tongren Hospital, Capital Medical University, No. 1, Dongjiaomin Lane, Dongcheng District, Beijing, 100730, People's Republic of China, Tel +86 13671281401, Email cjr.yangbentao@vip.163.com

Objective: Acute unilateral vestibulopathy (AUVP) is quite common in clinical practice, but lesion localization and etiological diagnosis of AUVP remain the current clinical challenges, and have always been the focus for researchers. The study aimed to explore the lesion site and possible etiology of AUVP.

Methods: This study is a retrospective study. Twenty-three AUVP patients who attended the neurology outpatient clinics of our hospital from January 2020 to March 2022 were included. Clinical data of patients including baseline data, cardiovascular risk factors, immunological test results and infection indicators were collected. Vestibular function tests, including video head impulse test (vHIT), caloric testing, vestibular evoked myogenic potentials (VEMPs) and post-contrast delayed 3D-FLAIR MRI, were performed.

Results: Among 32 AUVP patients included, there were 10 males and 13 females, with a male-to-female ratio of 1:1.3, and an average age of 42.13 ± 14.57 years (range 19–76 years old). Acute persistent vertigo and relapsing-remitting vertigo accounted for 39.1% (9/23) and 60.9% (14/23) of the patients, respectively. Possible etiologies included cardiovascular risk factors ($n = 11$), abnormal immunological indicators ($n = 8$), and evidence of infection ($n = 3$). About 57.1% (12/21) of the patients showed abnormal vHIT (including reduced gain in horizontal canal (HC) in 14.3%, anterior canal (AC) in 4.8%, both the AC and HC in 19%, both the HC and posterior canal (PC) in 14.3%, and all three canals in 9.5% of cases). Probable entire vestibular nerve damage was found in 38.1% of the patients, only 9.5% of the patients followed the innervation pattern of the entire vestibular nerve, these patients had abnormal vHIT and VEMP results, and were considered to have definite entire vestibular nerve damage. Probable superior vestibular nerve (SVN) damage was found in 47.6% of the patients, but only 4.8% (1/21) of the patients followed the innervation pattern of SVN, with reduced VOR gains for AC and HC and abnormal oVEMP results, and were considered to have definite SVN damage. 3D-FLAIR MRI revealed high signal intensity in the SVN and vestibule in 4.8% (1/21) and 19% (4/21) of the patients, respectively.

Conclusion: The majority of AUVP patients had a relapsing-remitting course and had vestibular function test results that did not follow the innervation pattern of the vestibular nerve. Post-contrast delayed 3D-FLAIR MRI revealed damage to the vestibule in some patients, suggesting that damage to the labyrinth itself in AUVP deserves clinical attention. The majority of the AUVP patients had cardiovascular risk factors and abnormal systemic immunological indicators, which might be the possible etiologies of AUVP.

Keywords: acute unilateral peripheral vestibular dysfunction, etiology, vestibule, labyrinth, vestibular nerve

Introduction

Acute unilateral vestibulopathy (AUVP) is a quite common peripheral vestibular disorder. The main clinical manifestations are acute persistent rotational or non-rotational spontaneous vertigo caused by acute unilateral loss of vestibular

function, accompanied by nausea/vomiting, vibrovision, and instability, without acute audiological symptoms and signs of acute central nervous system damage.^{1,2} The annual incidence of AUVP is reported to range from 3.5 to 15.5 cases/100,000 people,³ accounting for 7% of specialist clinics for vertigo, and is the third most common cause of external atrium disease (the most common is benign paroxysmal positional vertigo (BPPV), followed by Meniere's disease). The age of onset is usually between 30 and 60 years old, and the peak of onset is between 40 and 50 years old. There was no significant gender difference⁴ and no evidence of seasonal differences.⁵ About 50–70% of patients experience complete remission of subjective symptoms several months after onset.⁴ Patients with AUVP may develop secondary BPPV in the posterior semicircular canal (PC), the incidence of which is about 9.8% to 16.3%.^{6,7}

Clinically, precise localization of AUVP has always been the focus for researchers. As we all know, the vestibular nerve is the eighth cranial nerve (auditory nerve) issued by the branch, divided into upper and lower branches, and they innervate different vestibular organs. The superior vestibular nerve (SVN) controls the anterior semicircular canal (AC) and horizontal semicircular canal (HC) ampullae and utricle, while the inferior vestibular nerve (IVN) mainly controls the posterior semicircular canal (PC) ampullae and saccule. Although there are several clinical tools to assess vestibular function of the AUVP patients, such as caloric testing, video head impulse test (vHIT), and vestibular evoked myogenic potentials (VEMPs),⁸ but these tests are still unable to accurately determine whether the peripheral vestibular lesions are localized to the vestibular labyrinth (eg semicircular canals and vestibule) or the vestibular nerve and cannot provide a scientific basis for accurate localization of AUVP. In recent years, some scholars have attempted to precisely determine whether the labyrinth itself or the vestibular nerve is damaged in AUVP patients by using a combination of different tests, such as caloric testing + vHIT + VEMPs^{9,10} or using non-vestibular evaluation techniques such as post-contrast delayed 3D-FLAIR MRI. Rachael et al¹¹ conducted a study on 43 patients with AUVP and found that 55.8% (24/43) of the patients had vestibular nerve injury, while only 11.6% (5/43) of the patients met the principle of total nerve injury innervation, indicating that vestibular nerve injury in most AUVP patients did not meet the principle of innervation. It appears that not only the vestibular nerve but also the labyrinth itself can be damaged in AUVP patients.^{11,12} Kim et al¹³ performed 3D-FLAIR MRI on AUVP patients and also showed that damage to the labyrinth was more common and damage to the vestibular nerve was less common. The specific lesion site in AUVP patients is still controversial and deserves further in-depth investigation.

At present, few studies on the etiology and pathogenesis of AUVP are available. A genome-wide association study reported that AUVP, such as vestibular neuritis, was caused by the reactivation of latent herpes simplex virus type 1.¹⁴ Other etiologies have also been proposed, including cardiovascular risk factors and autoimmune responses. Oron et al¹⁵ found that the ratio of cardiovascular risk factors in AUVP patients was significantly higher than those of the general population and there was a significant correlation between patients' age and cardiovascular risk factors, suggesting that the occlusion of small blood vessels and labyrinthine ischemia may lead to the development of vestibular symptoms. Chung et al¹⁶ showed that arterial stiffness and high metabolic syndrome scores were correlated with the occurrence of AUVP. Furthermore, some scholars believe that the special interval between the onset of respiratory tract infection and the onset of vertigo in AUVP patients may suggest that the disease is caused by immune-mediated infectious complications rather than direct neuroviral infection.¹⁷

Given this background, this study aimed to explore the lesion site and possible etiology of AUVP by using vestibular function tests and post-contrast delayed 3D-FLAIR MRI.

Materials and Methods

Patients

This study is a retrospective study. Twenty-three AUVP patients who attended the neurology outpatient clinics of our hospital from January 2020 to March 2022 were included. The inclusion criteria are as follows: (1) patients who developed acute persistent rotatory or non-rotatory spontaneous vertigo (lasting \geq 24 hours); (2) videonystagmography revealed spontaneous horizontal nystagmus, which was direction-fixed and enhanced by removal of visual fixation; (3) impaired unilateral vestibulo-ocular reflex (VOR) gain on vHIT or a unilateral reduced vestibular response on caloric irrigation; (4) patients who had no obvious hearing loss and signs of central nervous system damage; (5) the symptoms

can be better explained by other diseases. The exclusion criteria are as follows: (1) accompanied by serious medical or mental illness; (2) there are serious intracranial space-occupying lesions and other serious neurological diseases in the head magnetic examination; (3) patients with severe renal impairment or hypersensitivity to contrast agents; (4) patients with claustrophobia who cannot tolerate MRI or have other contraindications for MRI; (5) patients who do not cooperate with the examination or do not sign the informed consent; (6) patients with incomplete baseline information.

This study was approved by the Ethics Committee of Aerospace Center Hospital, Peking University Aerospace School of Clinical Medicine (No. 2021-ASCH-010) and were conducted in accordance with the Declaration of Helsinki (as revised in 2013). Written informed consent was obtained from all patients.

Clinical Data Collection

Baseline data of all patients, including sex, age, current medical history (disease duration, history of cold and diarrhea before onset, symptoms during onset, onset duration, trigger factors, and accompanying symptoms), neurological examination, cardiovascular risk factors (such as hypertension, diabetes, hyperlipidemia), immunological tests (immunological abnormalities were considered if any of the following laboratory indicators were abnormal: anti-thyroglobulin antibody, anti-thyroid peroxidase antibody, rheumatoid factor, anti-nuclear antibody and anti-phospholipid antibody) and detection of infection indicators (screening for herpes virus infection).

Vestibular Function Tests

Video Head Impulse Test (vHIT)

vHIT (Interacoustics, Middelfart, Denmark) was used to evaluate the function of the three pairs of semicircular canals. Test was performed in a brightly lit room. Patients were in a sitting position and wore vHIT goggles. They were instructed to fix their eyes on a target at eye level and at a distance of 1.5m. The examiner stood behind the patient and held the patient's head between both palms, delivered 20 passive head impulses in a brief and rapid manner, the angular velocity was 150–250°/s for the horizontal canal impulses, 100–200°/s for the vertical canal impulses, and the amplitude was 10–20°. The vHIT software was used to record the average slow phase VOR gain values. VOR gain is defined as the ratio of eye velocity to head velocity at 60s. vHIT results were considered abnormal if the gain for the HC was less than 0.8 and the gain for the vertical semicircular canals was less than 0.7.¹⁸ All gain values were below the normal range and pathological saccades were recorded.

Caloric Testing

During the caloric testing, patients were positioned in the supine position in the semi-dark room, with their head tilted up about 30° and with goggles placed over their eyes. The airflow was 50°C hot air and 24°C cold air, respectively, and the external auditory canals were irrigated for 1 min. The caloric irrigation was performed in the following order: right ear warm (50°C, RW), left ear warm ((50°C, LW), right ear cold (24°C, RC), left ear cold (24°C, LC), Once the nystagmus had completely subsided, the next irrigation was performed. The sides of strong and weak caloric responses were determined by the maximum slow-phase velocity (SPV) values of the total responses from the left and right ears (ie absolute SPV values of RC+RW responses vs the absolute SPV values of LC+LW responses).¹⁹ CP was calculated according to the following formula: $CP = (RW+RC)-(LW+LC)/(RW+RC+LW+LC) \times 100$. Unilateral CP >25% was defined as unilateral HC dysfunction.²⁰

Vestibular Evoked Myogenic Potentials

The test was carried out using the Eclipse evoked potential system (Interacoustics, Middelfart, Denmark) in a sound-proofed examination room. Insert earphones were used. The stimuli were short 500 hz tone bursts at a stimulus intensity of 95 or 100 dB nHL and a repetition rate of 5.1 times/seconds. A total of 200 stimuli were performed. The analysis time window was 50 ms. The band-pass filter intensity was in the range of 10–1000 hz. There were 2 cycles rise and fall times and 1 cycle plateau.

Ocular VEMPs (oVEMPs) and cervical VEMPs (cVEMPs) were recorded. Normal bilateral amplitude asymmetry ratios were defined as cVEMPs ≤ 0.35 and oVEMP ≤ 0.33 . The normal VEMP latency values defined by our laboratory were N18 and P25 cVEMP latencies and N13 and P18 oVEMP latencies. The cVEMP latency range is P1 Mean 16.90 \pm

2 SD 20.27 and N1 Mean 25.24 ± 2 SD 29.31; oVEMP latency range is N1 Mean 12.8 ± 2.47 (± 2 SD) and P1 Mean 15.9 ± 3.02 (± 2 SD). No response, amplitude asymmetry ratio falling outside of the normal range, and latency prolongation were considered as abnormal VEMP results.

Post-Contrast Delayed 3D-FLAIR MRI

A 3.0T MR system (MAGNETOM Avanto, Germany) with 8-channel head coil was used. The whole temporal bones were scanned. Double-dose gadolinium contrast was administered intravenously. The second scan was performed at an interval of 4 hours. Images were standardized by a physician and transferred to a picture archiving and communication system (PACS). Images were then evaluated by an experienced radiologist and a neurologist. Imaging findings were assessed according to the criteria previously described by Bernaerts et al.²¹

The protocols used for scanning were as follows: plain T1WI, FSE T2WI and T2-DRIVE-HR in the transverse plane; enhanced T1WI in the transverse and coronal planes; and 4-h delayed post-gadolinium 3D-FLAIR in the transverse plane. The average time from the onset of acute persistent rotational or non-rotatory spontaneous vertigo to the time of patients receiving post-contrast delayed 3D-FLAIR MRI was recorded.

Statistical Analysis

All data were collected in an Excel data collection sheet. Descriptive statistics were performed for all variables, with continuous variables presented as mean \pm standard deviation (SD) and categorical variables as percentages (%). Due to the small sample size and low statistical power, the use of inferential statistics was not appropriate.

Results

Baseline Characteristics and Possible Etiology of AUVP Patients

Twenty-three AUVP patients were included, including 10 males and 13 females, with a male-to-female ratio of 1:1.3, and an average age of 42.13 ± 14.57 years (range 19–76 years old). In terms of disease course, acute persistent vertigo accounted for 39.1% (9/23) of all patients included in the study, and relapsing-remitting vertigo accounted for 60.9% (14/23) of all patients. In terms of possible etiology of AUVP, cardiovascular risk factors were observed in 47.8% (11/23) of the patients, abnormal immunological indicators were observed in 34.8% (8/23) of the patients, and evidence of herpes virus infection was noted in 13% (3/23) of the patients (Table 1).

Table 1 Baseline Characteristics and Possible Etiological Characteristics of Patients With AUVP

Number of Patients	Sex	Age	Vestibular Symptoms		Acute Hearing Loss	Cardiovascular Risk Factors	Immunological Indicators	Evidence of Infection
			Acute-persistent vertigo	Relapsing-remitting vertigo				
1	F	33	0	1	0	0	1	0
2	M	33	0	1	0	0	0	0
3	M	35	1	0	0	1	0	0
4	F	60	1	0	0	1	0	0
5	F	19	1	0	0	0	0	0
6	M	33	0	1	0	1	0	0
7	F	21	0	1	0	0	1	0
8	F	44	1	0	0	1	1	0
9	M	61	0	1	0	1	1	0
10	F	57	0	1	0	1	0	0
11	F	49	0	1	0	0	0	0

(Continued)

Table 1 (Continued).

Number of Patients	Sex	Age	Vestibular Symptoms		Acute Hearing Loss	Cardiovascular Risk Factors	Immunological Indicators	Evidence of Infection
			Acute-persistent vertigo	Relapsing-remitting vertigo				
12	M	46	1	0	0	0	0	1
13	F	42	0	1	0	1	1	0
14	F	33	0	1	0	0	1	0
15	F	28	1	0	0	0	1	1
16	F	53	0	1	0	0	1	0
17	M	64	0	1	0	0	0	0
18	M	38	1	0	0	1	0	0
19	M	46	1	0	0	1	0	0
20	M	26	0	1	0	0	0	0
21	F	76	0	1	0	0	0	0
22	M	40	0	1	0	1	0	1
23	F	32	1	0	0	1	0	0

Abbreviations: F, female; M, male; 0, no; 1, yes; AUVP, acute unilateral vestibulopathy.

Vestibular Function Test results in AUVP Patients

Twenty-one out of the 23 patients completed the vestibular function tests. In terms of vHIT results, 57.1% (12/21) of the patients showed reduced vHIT gains, including reduced vHIT gain in the HC in 14.3% (3/21) of the patients, in the AC in 4.8% (1/21) of the patients, in both the AC and HC in 19% (4/21) of the patients, in both the HC and PC in 14.3% (3/21) of the patients, and in all three semicircular canals in 9.5% (2/21) of the patients.

In terms of VEMP results, 23.8% (5/21) of the patients had abnormal cVEMP results, 61.9% (13/21) of the patients had abnormal oVEMP results (Table 2).

In terms of anatomical localization of AUVP based on the vestibular function test results, vestibular receptors innervated by superior (SVN) and inferior vestibular nerves (IVN) were found to be damaged in 38.1% (8/21) of the patients, probable damage to the entire vestibular nerve was considered, but only 9.5% (2/21) of the patients followed the innervation pattern of vestibular nerve; these patients had abnormal vHIT and VEMP results and were considered to have definite entire vestibular nerve damage. About 47.6% (10/21) of the patients had probable SVN damage, but only 4.8% (1/21) of the patients followed the innervation pattern of SVN, with reduced VOR gains for AC and HC and abnormal oVEMP results, and were considered to have definite SVN damage (Table 3 and Figure 1).

Delayed Post-Contrast Enhanced 3D-FLAIR MRI Findings

Twenty-one patients completed the examination. Time interval between AUVP onset and MRI average is 8.2 ± 4.2 days. About 4.8% (1/21) of the patients showed increased signal intensity in the SVN, clearly suggesting vestibular nerve damage. About 19% (4/21) of the patients showed abnormally increased signal intensity in the vestibule. Damage to the labyrinth was not observed in 81% (17/21) of the patients (Table 2 and Figure 2).

Discussion

The present study provides a more comprehensive multidimensional assessment of clinical course, vestibular function, post-contrast enhanced 3D-FLAIR MRI findings of the labyrinth, immunological indicators, and evidence of infection in AUVP patients without hearing loss. We not only used vestibular evaluation techniques such as caloric testing, vHIT, and VEMPs but also applied the non-vestibular evaluation technique delayed post-contrast enhanced 3D-FLAIR to intuitively evaluate whether the site of lesion in AUVP patients was localized to the labyrinth or vestibular nerve from an imaging

Table 2 Vestibular Function Test Results and Imaging Features in Patients With AUVP

Number of Patients	Sex	Age	Side of Lesion	Spontaneous nystagmus Direction	CP value	vHIT Gain on the Side of Lesion			cVEMP	oVEMP	3D-FLAIR MRI			Delay Between AUVP onset and MR Imaging (day)
						AC	HC	PC			Vestibular nerve	Vestibule	Cochlea	
1	F	33	L	R	100	1.53	0.69	0.64	0	0	0	0	0	9
2	M	33	R	L	100	0.18	0.38	0.88	0	I	I	I	0	3
3	M	35	L	R	96	1.10	0.99	1.26	0	I	0	0	0	15
4	F	60	L	R	100	0.81	0.56	0.69	0	I	0	I	0	16
5	F	19	L	R	88	1.24	0.86	1.23	0	0	0	0	0	10
6	M	33	R	L	100	0.42	0.52	0.41	I	I	0	0	0	10
7	F	21	L	R	55	1.09	1.12	1.33	0	0	0	0	0	5
8	F	44	R	L	74	0.85	0.83	0.93	0	I	0	0	0	8
9	M	61	L	R	77	0.85	0.36	0.70	0	I	0	0	0	13
10	F	57	L	R	35	—	—	—	—	—	0	0	0	7
11	F	49	L	R	100	0.56	0.37	0.70	I	I	0	0	0	5
12	M	46	L	R	42	0.38	0.31	1.46	I	I	0	0	0	2
13	F	42	R	L	75	1.17	0.54	0.64	0	0	0	0	0	14
14	F	33	R	L	76	0.97	0.55	1.08	0	0	0	0	0	7
15	F	28	R	L	67	1.22	0.90	1.13	0	0	—	—	—	—
16	F	53	L	R	27	1.12	0.81	1.05	0	I	0	0	0	6
17	M	64	R	L	31	1.08	0.94	1.22	0	I	0	0	0	3
18	M	38	L	R	79	0.42	0.35	0.87	0	0	0	I	0	12
19	M	46	R	L	100	0.39	0.50	0.55	I	I	0	0	0	5
20	M	26	L	R	94	0.91	1.23	1.28	0	I	0	0	0	8
21	F	76	L	R	26	—	—	—	—	—	—	—	—	—
22	M	40	L	R	60	0.60	0.89	1.23	I	0	0	0	0	3
23	F	32	R	L	140	0.71	0.57	1.14	0	I	0	I	0	12

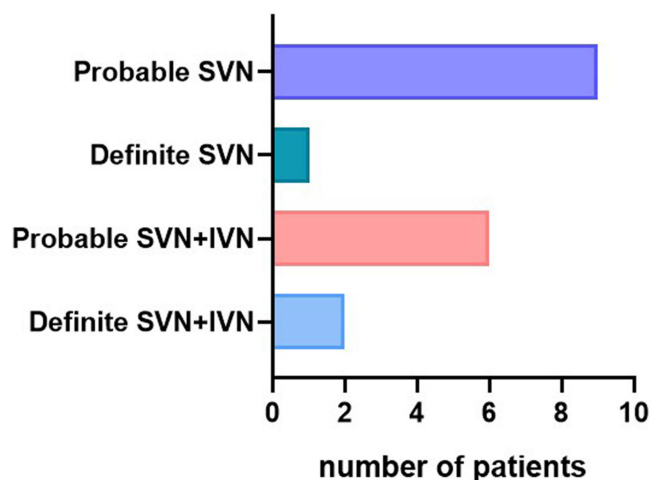
Abbreviations: F, female; M, male; R, right; L, left; AC, anterior canal; HC, horizontal canal; PC, posterior canal; CP, canal paresis; vHIT, video-head impulse test; oVEMP, ocular vestibular evoked myogenic potential; cVEMP, cervical vestibular evoked myogenic potential; 3D-FLAIR MRI, three-dimensional fluid-attenuated inversion recovery magnetic resonance imaging; 0, normal; I, abnormal; AUVP, acute unilateral vestibulopathy; —, not done.

Table 3 Anatomical Localization in AUVP Patients Based on the Results of Vestibular Function Tests (vHIT and VEMPs)

n	AC	HC	PC	Sacculle	Utricle	Classification
Definite SVN+IVN damage (n=2, 9.5%)						
2	1	1	1	1	1	SVN+IVN
Probable SVN+IVN damage (n=6, 28.6%)						
1	0	1	1	0	1	PC+SVN
2	1	1	0	1	1	SVN+ Sacculle
2	0	1	1	0	0	PC+HC
1	1	0	0	1	0	AC+ Sacculle
Definite SVN damage (n=1, 4.8%)						
1	1	1	0	0	1	SVN
Probable SVN damage (n=9, 42.9%)						
1	1	1	0	0	0	SVN
5	0	0	0	0	1	only Utricle
2	0	1	0	0	1	SVN
1	0	1	0	0	0	only HC

Abbreviations: 0, normal; 1, abnormal; AC, anterior canal; HC, horizontal canal; PC, posterior canal; SVN, superior vestibular nerve; IVN, inferior vestibular nerve; vHIT, video-head impulse test; VEMPs, vestibular evoked myogenic potentials; AUVP, acute unilateral vestibulopathy.

perspective. Additionally, we also further analyzed the patients' characteristics and disease course, cardiovascular risk factors and immune factors. We believe that the findings of this study will help us have a better understanding of the lesion location and possible etiology of AUVP.

**Figure 1** Distribution patterns for vestibular nerve damage in patients with acute unilateral vestibulopathy.

Abbreviations: SVN, superior vestibular nerve; IVN, inferior vestibular nerve.

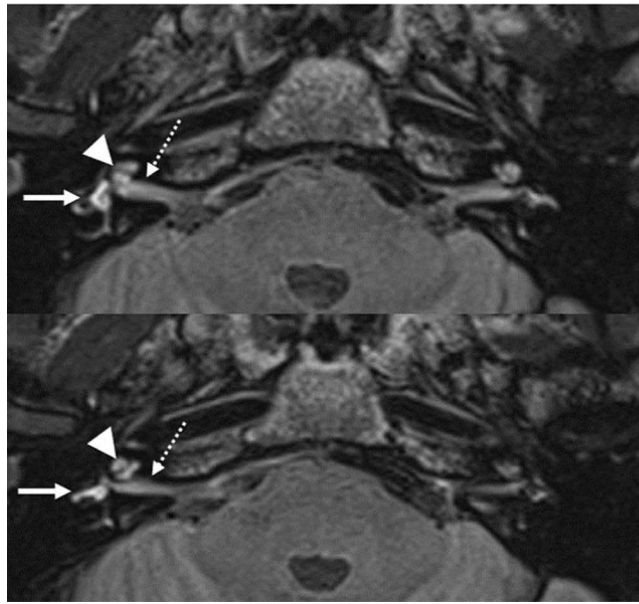


Figure 2 Delayed post-contrast enhanced 3D-FLAIR images of patients with acute unilateral vestibulopathy. Delayed post-contrast enhanced 3D-FLAIR MRI revealed abnormally increased signal intensity in the right vestibular nerve and right vestibule compared to the contralateral side. Dashed arrows: vestibular nerve; short arrows: cochlea; solid arrows: vestibule.

Lesion Site in AUVP Patients: Vestibular Nerve or Labyrinth?

The vestibular nerve is a branch from the eighth paired cranial nerve (auditory nerve).²² In this study, cases with decreased VOR gain in caloric tests were included, but nearly half of the cases had no abnormal semicircular canal vHIT. In response to this phenomenon, we believe that it may be related to the “dual-frequency mechanism”. Some scholars believe that ampullar is consists of both Type I and Type II hair cells as well as regularly and irregularly discharging afferent neurons. Type I hair cells populate the central part of the crista ampullaris. Irregular afferents primarily connect to Type I hair cells or a mixture of Type I and Type II hair cells. These hair cells encode high-frequency and high-acceleration head movements. Type II hair cells populate the periphery of the crista. Regular afferents carry the output of Type II hair cells or a mixture of Type I and Type II hair cells and likely encode low-frequency, low-acceleration movement.²³ Therefore, damage to different types of hair cells can result in selective abnormalities in vestibular function tests. Moreover, vHIT is a type of high-frequency stimulation, while the caloric testing involves low-frequency stimulation. People’s daily life activities are mostly high-frequency activities.²⁴ As a result, patients with low-frequency damage are more likely to be found by vestibular function tests. The SVN innervates the ampullae of the AC and HC and the utricle, the IVN mainly innervates the ampullae of the PC and saccule.²⁵ Some scholars believe that the lesion site in AUVP patients is mostly localized to the vestibular nerve, without damage to the labyrinth itself.²⁶ If this hypothesis is true, either damage to the SVN, IVN or entire vestibular nerve should follow the innervation pattern, ie if SVN is damaged, dysfunction of the AC, HC and utricle should be observed; if IVN is damaged, dysfunction of the PC and the saccule should be observed; if the entire vestibular nerve is damaged, dysfunction of all semicircular canals, utricle and saccule should be observed. However, our results showed that the damage to the vestibular receptors innervated by both SVN and IVN, ie, probable entire vestibular nerve damage was found in 38.1% of the patients; however, only 9.5% of the patients followed the innervation pattern of the entire vestibular nerve, and had damage to all vestibular receptors. Damage to the vestibular receptors innervated by the SVN, ie probable SVN damage was found in 47.6% of the patients; however, only 4.8% of the patients had damage to both the AC, HC, and utricle; IVN damage was never observed in the present study. The results are consistent with previously published findings showing that AUVP more commonly involves only the SVN,²⁷ and uncommonly affects only the IVN.^{28,29} In a study by Magliulo et al³⁰ vHIT and VEMPs results showed that about 55% of the patients developed mixed damage to the vestibular receptors innervated by both the SVN and IVN, however, only 25% of the patients had damage to all vestibular receptors.

Additionally, 40% of the patients developed damage to the vestibular receptors innervated by SVN, but only 20% of the patients had complete damage to the SVN. Only 5% of the patients developed damage to the vestibular receptors innervated by the IVN, and 2.5% of the patients had complete damage to the IVN. The same results were also reported by Rachael et al.³¹ Although these findings are similar to our results, but the authors suggest that AUVP is caused by damage or partial damage to the vestibular nerve, and do not mention the damage to the labyrinth itself. Findings from a study conducted by Hegemann et al¹¹ seem to support our results, the authors suggest that the lesion site in AUVP patients was more likely to be localized to the labyrinth itself, up to 76% of the 25 patients included did not follow the innervation pattern, and were considered to have damage to the labyrinth itself, while only 24% of the patients had vestibular nerve damage.

In the present study, we further used delayed post-contrast enhanced 3D-FLAIR MRI to determine the lesion site in AUVP patients. The findings obtained also supported the above-mentioned vestibular function test results. Among 21 patients who underwent delayed post-contrast enhanced 3D-FLAIR MRI, increased signal intensity in the SVN was observed in only 4.8% (1/21) of the patients, and abnormal increased signal intensity in the vestibule was seen in 19% (4/21) of the patients. Our results are similar to the findings of Eliezer et al¹² showing that abnormal signal in the vestibular nerve was not observed in these patients, but 86.6% of the patients showed increased signal in the affected semicircular canal, suggesting that the lesion site in AUVP patients was localized to the labyrinth itself, which was not localized to the vestibular nerve.

Our study showed that only 39.1% (9/23) of AUVP patients experienced a first-episode acute-persistent vertigo, while 60.9% (14/23) of AUVP patients had history of acute or subacute onset of sustained spinning or non-spinning vertigo lasting at least 24 hours. Bárány Society's International classification of vestibular disorders defines AUVP into "AUVP", "AUVP in evolution", "Probable AUVP", "History of AUVP". The diagnostic criteria of "History of AUVP" were discussed: A) History of acute or subacute 1 onset of sustained spinning or non-spinning vertigo lasting at least 24 hours (ie an acute vestibular syndrome) and slowly decreasing in intensity over days; B) No history for simultaneous acute central neurological or audiological symptoms such as hearing loss or tinnitus; C) Evidence of unilaterally reduced VOR function; D) No history of simultaneous acute central neurological or audiological signs; E) Not better accounted for by another disease or disorder. At the same time, the standard also considers that up to 25% of patients may experience an episode of vertigo or dizziness lasting for several hours within two days before the onset of the sustained vertigo, if episodic vertigo occurs many days before the onset of persistent vertigo, an alternative differential diagnosis should be considered, namely Meniere's disease, vestibular migraine or TIA.³ The patients included in this study are all patients with acute vertigo whose vertigo time is more than 24 hours, and the relapsing-remitting vertigo means that the patients have a history of vertigo, rather than having transient vertigo and experience many days before 24-hour persistent vertigo. Moreover, the patients included in this study do not have a history of migraine and have no history of hearing loss; therefore, they cannot define it as Meniere's disease, TIA or vestibular migraine, we prefer to define it as an acute onset unilateral peripheral vestibular dysfunction, namely AUVP. The clinical symptoms of these AUVP patients are fluctuating and the course of disease is relapse-remissive, which seems to be more consistent with the repeated fluctuating damage caused by the labyrinth itself.

According to the recurrent and fluctuating natures of the clinical symptoms and disease course of AUVP, as well as the aforementioned results from vestibular function tests and non-vestibular evaluation technique, we believe that there is insufficient evidence of vestibular nerve damage in AUVP patients, whereas damage to the labyrinth in AUVP deserves clinical attention.

Possible Etiology of AUVP Patients

In the present study, evidence of infection was found in 13% (3/23) of the patients, and 47.8% (11/23) of the patients were found to have cardiovascular risk factors. For example, in a patient with acute persistent vertigo and cardiovascular risk factors, reduced vHIT gain in the HC, obvious saccades in the AC, abnormal oVEMP results were noted, and SVN damage was considered. Delayed post-contrast enhanced 3D-FLAIR showed abnormally increased signal in the vestibule, the presence of blood-labyrinthine-barrier breakdown, and no vestibular nerve damage (Figure 3). The labyrinth is supplied by the labyrinthine artery (LA). The anterior vestibular artery supplies the utricle, the superior part of the

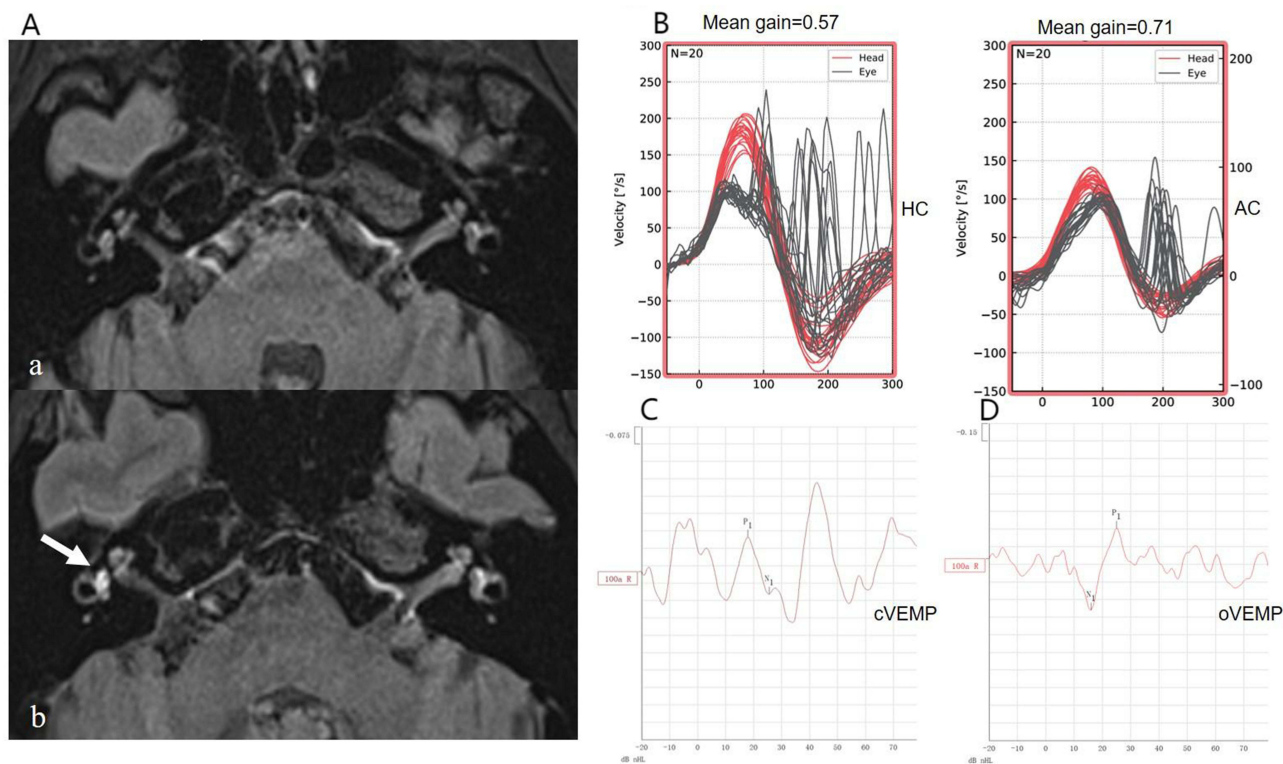


Figure 3 Delayed post-contrast enhanced 3D-FLAIR images and vestibular function test results of AUVP patients with definite SVN damage. **(A)** pre-contrast image showed no abnormally increased signal; **(B)** 4-hour-delayed post-contrast enhanced 3D-FLAIR image showed abnormally increased signal in the right vestibule compared to the contralateral side (white arrow), and no abnormally increased signal in the right vestibular nerve. **(C)** Reduced vHIT gain in the right HC and the presence of saccades in the AC were observed. **(D)** Prolonged latency of the oVEMP on the right side was noted.

Abbreviations: AUVP, acute unilateral vestibulopathy; SVN, superior vestibular nerve; vHIT, video-head impulse test; oVEMP, ocular vestibular evoked myogenic potential; cVEMP, cervical vestibular evoked myogenic potential; HC, horizontal canal; AC, anterior canal.

sacculae, and the ampulla of the AC and HC. The posterior vestibular artery supplies the inferior part of the sacculae and the ampulla of the PC.³² It is speculated that this patient may have transient ischemia or occlusion of the anterior vestibular artery, thereby presenting with similar symptoms to SVN damage. It can be seen that patients presenting with symptoms of AUVP and cardiovascular risk factors were more likely to develop stenosis or occlusion of the LA, thus leading to the occurrence of vestibular symptoms. The LA and its branches are very thin, and current imaging techniques cannot display the fine structure of LA.³³ Therefore, when damage to the labyrinth itself occurs in these terminal arterioles, precise lesion localization is difficult, which may be misdiagnosed as vestibular nerve lesions.

Some scholars also believe that autoimmune mechanisms can also cause the occurrence of AUVP. In recent years, many immunological studies of the labyrinth have been carried out. A study found pathological T-helper/suppressor lymphocyte ratio (CD4/CD8) quotient in 57% of patients with Meniere's disease, 48% of patients with vestibular neuritis, and 39% patients with Bell's palsy.³⁴ Additionally, there is only an imbalance in the CD4/CD8 quotient in inner ear diseases of unknown cause, which favors a causative immunological origin.³⁵ Furthermore, the labyrinth is also a direct target of immune responses, which may be damaged by a deposition of circulating immune complexes or by systemic immune-mediated diseases.³⁶ In the present study, 34.8% (8/23) of the patients had abnormal immunological indicators, indicating that immunological mechanisms may also be the possible causes of AUVP.

Limitations

This study was a single-center study, the sample size was small. We have present descriptive statistics of the data, but we have refrained from any inferential statistics due to the small sample size. With regard to the possible etiology, we only analyzed the prevalence of cardiovascular risk factors, autoimmune markers and viral infection indicators in patients and did not explore how these etiologies affect the development of AUVP. In addition, the vHIT and VEMP tests may have

errors due to the matching degree of the operator and patients, as well as the sensitivity of the tests. Furthermore, the percentage of abnormal signal intensity of MRI found in the present study was relatively low, which may be due to the long time interval between diagnosis of AUVP and MRI examination (mean 8.2 ± 4.2 days). Further large-sample studies are needed to explore the influence of etiology on AUVP by including a control group and improve the positive rate of MRI diagnosis by shortening the time interval between disease onset and examination, thus confirming our findings.

Conclusions

The majority of the AUVP patients had a relapsing-remitting course and had vestibular function test results that did not follow the innervation pattern of the vestibular nerve. Post-contrast delayed 3D-FLAIR revealed damage to the vestibule in some patients, suggesting that damage to the labyrinth itself in AUVP patients deserves clinical attention. The majority of the AUVP patients had cardiovascular risk factors and abnormal systemic immunological indicators. It is worthwhile to further investigate how cardiovascular risk factors and systemic immune abnormalities are involved in the development of AUVP.

Data Sharing Statement

The data that support the findings of this study are available from the corresponding author upon reasonable request.

Ethics Statement

The studies involving human participants were conducted in accordance with the Declaration of Helsinki (as revised in 2013) and approved by the Ethics Committee of Aerospace Center Hospital, Peking University Aerospace School of Clinical Medicine (No. 2021-ASCH-010). The participants provided their written informed consent to participate in this study. Written informed consent was obtained from the participants for the publication of any potentially identifiable images or data included in this article.

Funding

This study was supported by Aerospace Center Hospital (Grant no. YN202106).

Disclosure

Menglu Zhang and Jianrong Wan are co-first authors for this study. The authors declare that the research was conducted in the absence of any commercial or financial relationships that could be construed as a potential conflict of interest.

References

1. Strupp M, Magnusson M. Acute Unilateral Vestibulopathy. *Neurol Clin.* 2015;33(3):669–685,x. doi:10.1016/j.ncl.2015.04.012
2. Jeong SH, Kim HJ, Kim JS. Vestibular neuritis. *Semin Neurol.* 2013;33(03):185–194. doi:10.1055/s-0033-1354598
3. Strupp M, Bisdorff A, Furman J, et al. Acute unilateral vestibulopathy/vestibular neuritis: diagnostic criteria. *J Vestib Res.* 2022;32(5):389–406. doi:10.3233/VES-220201
4. Strupp M, Brandt T. Vestibular neuritis. *Semin Neurol.* 2009;29(5):509–519. doi:10.1055/s-0029-1241040
5. Adamec I, Krbot Skorić M, Handžić J, Habek M. Incidence, seasonality and comorbidity in vestibular neuritis. *Neurol Sci.* 2015;36(1):91–95. doi:10.1007/s10072-014-1912-4
6. Mandalà M, Santoro GP, Awrey J, Nuti D. Vestibular neuritis: recurrence and incidence of secondary benign paroxysmal positional vertigo. *Acta Otolaryngol.* 2010;130(5):565–567. doi:10.3109/00016480903311278
7. Pardal Refoyo JL, Pérez Plasencia D, Beltrán Mateos LD. Isquemia de la arteria vestibular anterior (síndrome de Lindsay-Hemenway). Revisión y comentarios [Ischemia of the anterior vestibular artery (Lindsay-Hemenway syndrome). Review and comments]. *Acta Otorrinolaringol Esp.* 1998;49(8):599–602. Spanish.
8. Lee JY, Park JS, Kim MB. Clinical characteristics of acute vestibular neuritis according to involvement site. *Otol Neurotol.* 2019;40(6):797–805. doi:10.1097/MAO.0000000000002226
9. Halmagyi GM, Chen L, MacDougall HG, Weber KP, McGarvie LA, Curthoys IS. The video head impulse test. *Front Neurol.* 2017;8:258. doi:10.3389/fneur.2017.00258
10. Rosengren SM, Colebatch JG, Young AS, et al. Vestibular evoked myogenic potentials in practice: methods, pitfalls and clinical applications. *Clin Neurophysiol Pract.* 2019;4:47–68. doi:10.1016/j.cnp.2019.01.005
11. Uffer DS, Hegemann SC. About the pathophysiology of acute unilateral vestibular deficit - vestibular neuritis (VN) or peripheral vestibulopathy (PVP)? *J Vestib Res.* 2016;26(3):311–317. doi:10.3233/VES-160581

12. Eliezer M, Maquet C, Horion J, et al. Detection of intralabyrinthine abnormalities using post-contrast delayed 3D-FLAIR MRI sequences in patients with acute vestibular syndrome. *Eur Radiol.* 2019;29(6):2760–2769. doi:10.1007/s00330-018-5825-0
13. Kim KT, Park S, Lee SU, et al. Four-hour-delayed 3D-FLAIR MRIs in patients with acute unilateral peripheral vestibulopathy. *Ann Clin Transl Neurol.* 2024;11(8):2030–2039. doi:10.1002/acn3.52123
14. Rujescu D, Hartmann AM, Giegling I, et al. Genome-wide association study in vestibular neuritis: involvement of the host factor for HSV-1 replication. *Front Neurol.* 2018;9:591. doi:10.3389/fneur.2018.00591
15. Oron Y, Shemesh S, Shushan S, et al. Cardiovascular risk factors among patients with vestibular neuritis. *Ann Otol Rhinol Laryngol.* 2017;126(8):597–601. doi:10.1177/0003489417718846
16. Chung JH, Lee SH, Park CW, et al. Clinical significance of arterial stiffness and metabolic syndrome scores in vestibular neuritis. *Otol Neurotol.* 2017;38(5):737–741. doi:10.1097/MAO.0000000000001352
17. Greco A, Macri GF, Gallo A, et al. Is vestibular neuritis an immune related vestibular neuropathy inducing vertigo? *J Immunol Res.* 2014;2014:459048. doi:10.1155/2014/459048
18. McGarvie LA, MacDougall HG, Halmagyi GM, et al. The Video Head Impulse Test (vHIT) of semicircular canal function - age-dependent normative values of VOR gain in healthy subjects. *Front Neurol.* 2015;6:154. doi:10.3389/fneur.2015.00154
19. Yoo MH, Kim SH, Lee JY, et al. Results of video head impulse and caloric tests in 36 patients with vestibular migraine and 23 patients with vestibular neuritis: a preliminary report. *Clin Otolaryngol.* 2016;41(6):813–817. doi:10.1111/coa.12556
20. Halmagyi GM, Yavor RA, McGarvie LA. Testing the vestibulo-ocular reflex. *Adv Otorhinolaryngol.* 1997;53:132–154. doi:10.1159/000059042
21. Bernaerts A, Vanspauwen R, Blaivie C, et al. The value of four stage vestibular hydrops grading and asymmetric perilymphatic enhancement in the diagnosis of Ménière's disease on MRI. *Neuroradiology.* 2019;61(4):421–429. doi:10.1007/s00234-019-02155-7
22. Zhong YQ, Luo B, Guan RR, et al. The vestibular function in patients with vestibular neuritis. *Ting Li Xue Ji Yu Yan Ji Bing Za Zhi.* 2019;27:358–363. doi:10.3969/j.issn.1006-7299.2019.04.004
23. McCaslin DL, Rivas A, Jacobson GP, Bennett ML. The dissociation of video head impulse test (vHIT) and bithermal caloric test results provide topological localization of vestibular system impairment in patients with “definite” Ménière's disease. *Am J Audiol.* 2015;24(1):1–10. doi:10.1044/2014_AJA-14-0040
24. Tsuji K, Velázquez-Villaseñor L, Rauch SD, Glynn RJ, Wall C, Merchant SN. Temporal bone studies of the human peripheral vestibular system. Aminoglycoside ototoxicity. *Ann Otol Rhinol Laryngol Suppl.* 2000;181(5_suppl):20–25. doi:10.1177/00034894001090s504
25. Himmelein S, Lindemann A, Sinicina I, et al. Differential involvement during latent herpes simplex virus 1 infection of the superior and inferior divisions of the vestibular ganglia: implications for vestibular neuritis. *J Virol.* 2017;91(14):e00331–17. doi:10.1128/JVI.00331-17
26. Bronstein AM, Dieterich M. Long-term clinical outcome in vestibular neuritis. *Curr Opin Neurol.* 2019;32(1):174–180. doi:10.1097/WCO.0000000000000652
27. Taylor RL, McGarvie LA, Reid N, Young AS, Halmagyi GM, Welgampola MS. Vestibular neuritis affects both superior and inferior vestibular nerves. *Neurology.* 2016;87(16):1704–1712. doi:10.1212/WNL.0000000000003223
28. Halmagyi GM, Aw ST, Karlberg M, Curthoys IS, Todd MJ. Inferior vestibular neuritis. *Ann N Y Acad Sci.* 2002;956(1):306–313. doi:10.1111/j.1749-6632.2002.tb02829.x
29. Kim JS, Kim HJ. Inferior vestibular neuritis. *J Neurol.* 2012;259(8):1553–1560. doi:10.1007/s00415-011-6375-4
30. Magliulo G, Gagliardi S, Ciniglio Appiani M, et al. Vestibular neurolabyrinthitis: a follow-up study with cervical and ocular vestibular evoked myogenic potentials and the video head impulse test. *Ann Otol Rhinol Laryngol.* 2014;123(3):162–173. doi:10.1177/0003489414522974
31. Nham B, Akdal G, Young AS, et al. Capturing nystagmus in the emergency room: posterior circulation stroke versus acute vestibular neuritis. *J Neurol.* 2023;270(2):632–641. doi:10.1007/s00415-022-11202-y
32. Kim JS, Lee H. Inner ear dysfunction due to vertebrobasilar ischemic stroke. *Semin Neurol.* 2009;29(05):534–540. doi:10.1055/s-0029-1241037
33. Liqun Z, Park KH, Kim HJ, et al. Acute unilateral audiovestibulopathy due to embolic labyrinthine infarction. *Front Neurol.* 2018;9:311. doi:10.3389/fneur.2018.00311
34. Bumm P, Schlimok G. T-lymphocyte subpopulations and HLA-DR antigens in patients with Bell's palsy, hearing loss, neuronitis vestibularis, and Ménière's disease. *Eur Arch Otorhinolaryngol.* 1994;S4478. doi:10.1007/978-3-642-85090-5_178
35. Bumm P, Müller EC, Grimm-Müller U, et al. T-Lymphozytensubpopulationen und HLA-DR-Antigene beim Hörsturz, der Neuropathia vestibularis, dem Morbus Ménière und der Bellschen Parese [T-lymphocyte subpopulation and HLA-DR antigens in hearing loss of vestibular neuropathy, Ménière's diseases and Bell's palsy]. *Laryngorhinootologie.* 1991;70(5):260–266. German. doi:10.1055/s-2007-998033
36. Ciorba A, Corazzi V, Bianchini C, et al. Autoimmune inner ear disease (AIED): a diagnostic challenge. *Int J Immunopathol Pharmacol.* 2018;32:2058738418808680. doi:10.1177/2058738418808680