

# Unusual Cutaneous Manifestations in a Patient with a History of Hepatitis B: A Case of Scleromyxedema and Literature Review

Aili Gao, Xin Tian, Dexiu Lang, Yue Chen 

Department of Dermatology, Guangzhou Dermatology Hospital, Guangzhou, Guangdong, People's Republic of China

Correspondence: Yue Chen, Department of Dermatology, Guangzhou Dermatology Hospital, Guangzhou, People's Republic of China, Tel/Fax +86-020-83593472, Email chen767@mail3.sysu.edu.cn

**Abstract:** Scleromyxedema (SM) is a rare primary cutaneous mucinosis characterized by systemic papules and scleroderma-like manifestations, often associated with monoclonal gammopathy. We present the case of a 37-year-old male with SM who developed yellowish plaques on the neck and back over three years. Histopathological examination revealed mucin deposition, fibroblast proliferation, and fibrosis, supporting the diagnosis. Serum protein electrophoresis identified IgG- $\lambda$  type paraproteinemia. Notably, the patient had a history of hepatitis B virus (HBV) infection, suggesting a potential association. Following eight weeks of oral triamcinolone acetonide therapy, the skin lesions improved significantly. Despite established diagnostic criteria for SM, its pathogenesis remains poorly understood. Chronic antigenic stimulation from circulating cytokines and viral infections, such as HBV, may contribute to disease development. This case highlights the potential link between chronic HBV infection and SM, emphasizing the need for further investigation into viral etiologies. SM differs clinically, histologically, and systemically from related disorders such as scleroderma and scleroedema, necessitating careful differentiation for appropriate management. The scarcity of epidemiological data and lack of standardized treatment guidelines for SM in China underscore the challenges clinicians face in diagnosing and managing this rare disease. This case reinforces the importance of multidisciplinary collaboration, particularly when co-infections such as HBV are present. Given the chronic, unpredictable course of SM and its potential systemic involvement, continuous follow-up and vigilant monitoring are essential to optimize patient outcomes.

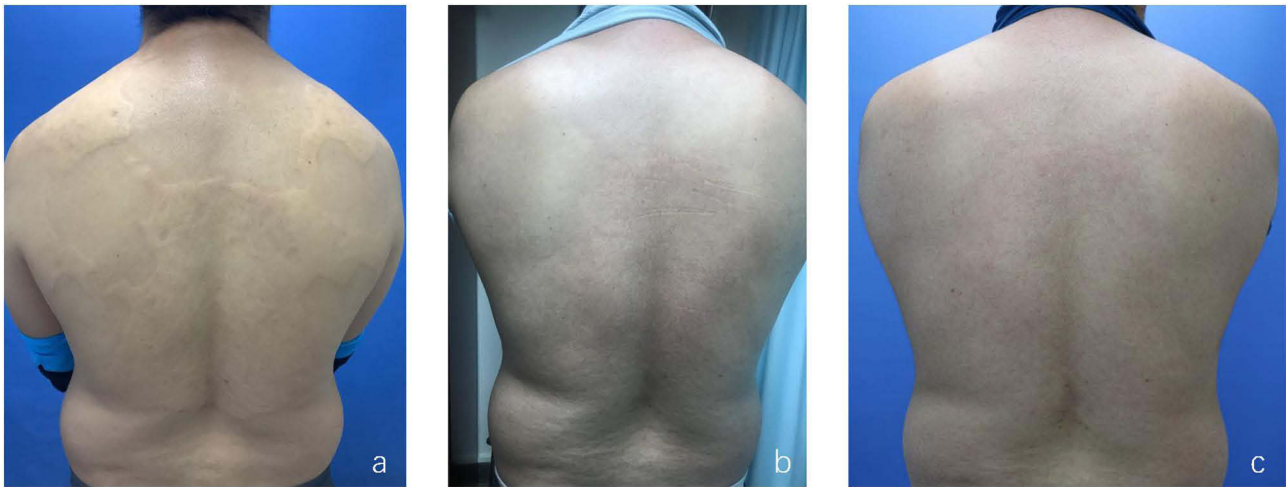
**Keywords:** scleromyxedema, mucin, paraglobulin, hepatitis B virus

## Introduction

Scleromyxedema (SM), also known as diffuse/generalized and sclerodermoid lichen myxedematosus or Arndt-Gottron disease, is a rare primary cutaneous mucinosis. It is characterized by a papular rash with a panulectatic distribution and a scleroderma-like appearance, often accompanied by monoclonal gammopathy.<sup>1</sup> Patients typically present with numerous waxy, hard papules and plaques. Histological examination reveals mucin deposition, fibroblast proliferation, and fibrosis. Lesions are usually confined to the upper back, shoulders, and dorsum of the neck. Involvement of the face and tongue can lead to difficulties in opening the mouth or eyes, dysarthria, or chewing problems. The hands and feet are generally unaffected. In recent years, an increasing number of reports have linked SM to viral infections.<sup>2</sup> Here, we describe the case of a 37-year-old Chinese male patient who presented with persistent yellowish plaques on his back for 3 years, along with skin tightening. The patient was diagnosed with SM and exhibited IgG- $\lambda$  type paraproteinemia, which was found to be associated with hepatitis B virus (HBV) infection.

## Case Report

A 37-year-old Chinese male presented to our hospital with yellowish plaques on the neck and back for 3 years. The patient had a skin-colored fingernail-sized plaque on the right side of the neck 3 years ago without any obvious triggers,

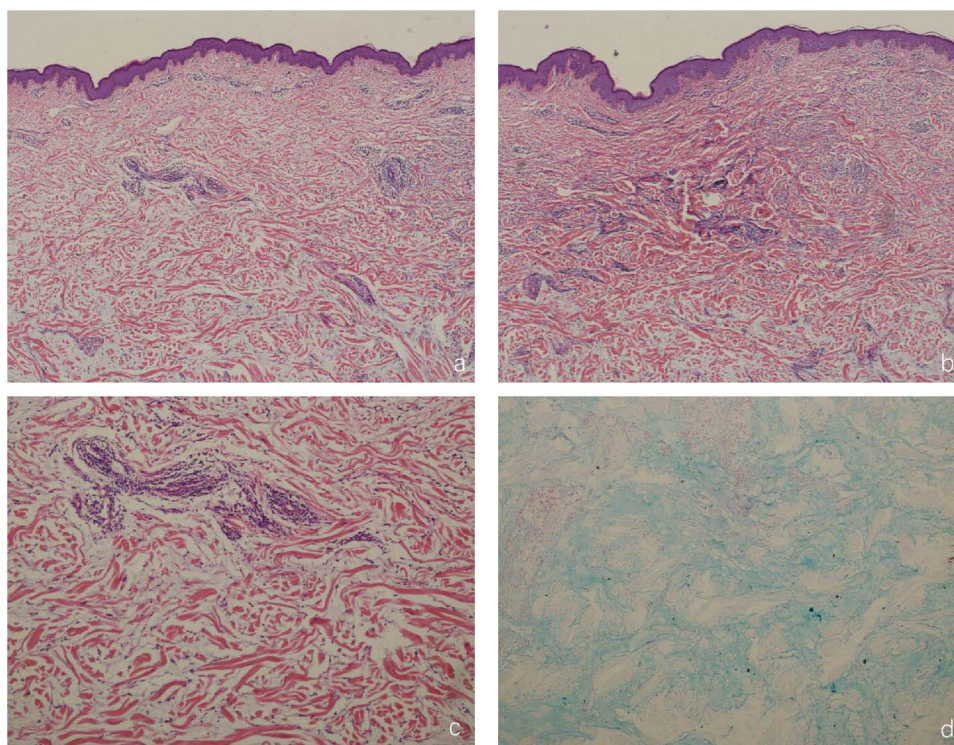


**Figure 1** Clinical photographs illustrating the patient's condition. (a) Initial presentation showing diffuse yellowish plaques on the nape of the neck, shoulders, back, and waist. The plaques had clear boundaries and formed a map-like appearance. The skin texture and hair appeared normal, with a slightly firm consistency that could be palpated without pain or sensory disturbances. (b) Significant improvement of the lesions observed after 8 weeks of treatment. (c) Absence of lesion recurrence during a follow-up visit 4 months after treatment.

with no pain or itching, which did not subside and gradually increased in size and expansion, spreading to the left side of the neck, back, and lumbar area, with a yellowish, well-defined, map-like appearance, and the lesions did not have any breakage, vesiculation, or exudation (Figure 1a). Denied recent history of medications, vaccinations, insect bites, photosensitivity, alopecia, oral ulcers, and musculoarticular pain. He had been seen in an outside hospital and was considered to have leprosy bacillus infection, which led to his referral to our hospital for further management. It is noteworthy that 15 years ago, he was diagnosed with hepatitis B virus infection at another hospital, with HBsAg (+), HBeAg (+), and HBcAb (+). He received hepatitis B treatment for six years (specific medications unknown) and then discontinued the medication. He has since undergone regular follow-ups, including biannual B-ultrasound examinations and liver function tests every six months to a year. He reported that the B-ultrasound indicated splenomegaly. There was no history of blood transfusion or trauma. Although there is no family history of similar diseases, it is notable that her grandfather, father, and brother all had hepatitis B. However, the patient was unaware of the cause of this familial clustering. The patient's systemic examination was unremarkable, and no enlarged lymph nodes were palpated. Dermatologic examination showed diffuse plaques on the posterior neck, bilateral scapulae, back, and lumbar region, which were yellowish in color, with clear boundaries, fused to form a map-like appearance, on which the skin pattern and hair were normal, with a slightly hard texture that could be pinched up, no pressure pain, no superficial sensory disturbances, and no Raynaud phenomenon.

Laboratory tests revealed that serum immunofixation electrophoresis identified the monoclonal protein as IgG- $\lambda$  type. IgA: 4.52 g/L (normal range: 0.7–3.5 g/L), urinary occult blood: 1+, urinary bilirubin: 1+, total bilirubin: 51.47  $\mu$ mol/L (normal range: less than 34  $\mu$ mol/L), direct bilirubin: 16.10  $\mu$ mol/L (normal range: 1.71–7  $\mu$ mol/L), uric acid: 519  $\mu$ mol/L. Other blood tests, liver enzymes, thyroid antibodies, thyroid function, antinuclear antibodies, TPPA, TRUST, HCV, HIV, and additional tests did not show significant abnormalities. Fungal direct smear and tissue fluid acid-fast bacillus smear were negative. Bone marrow examination, bone marrow biopsy, bone marrow flow cytometry, and bone marrow karyotype analysis showed no abnormalities. Histopathological examination of the skin lesions revealed a mostly normal epidermis, liquefied degeneration of the basal layer, extensive mucin deposition between dermal collagen, sparse inflammatory cell infiltration around dermal blood vessels (predominantly lymphocytes and a few fibroblasts), and positive Alcian blue staining. PAS staining did not reveal any spores or mycelium (Figure 2a–d).

The patient was diagnosed with SM based on clinical presentation, laboratory tests, and histological findings. Oral triamcinolone acetonide 12 mg once daily was prescribed. After 4 weeks, the patient developed dome-shaped inflammatory papules on the trunk, which improved after applying topical calamine lotion. By the sixth week of treatment, the lesions had flattened, and the rash was slightly raised above the skin surface. After 8 weeks, the patient's cutaneous



**Figure 2** Histopathological features of skin lesions. (a) The epidermis appears mostly normal, with liquefied degeneration of the basal lamina and extensive mucin deposition between the dermal collagen fibers (H&E, magnification  $\times 50$ ). (b) Focal fibrosis is observed in the dermis (H&E, magnification  $\times 50$ ). (c) Sparse infiltration of inflammatory cells, predominantly lymphocytes and a few fibroblasts is observed around the dermal blood vessels (H&E, magnification  $\times 100$ ). (d) Positive staining for Assyntolan is observed (H&E, magnification  $\times 200$ ).

sclerosis on the back showed marked improvement, with flattening and regression of plaques (Figure 1b). At the time of consultation, the patient reported facial swelling and toe spasms, which improved after reducing the methylprednisolone dose to 8 mg daily and supplementing with calcium. No recurrence has been observed during the follow-up period (Figure 1c). The patient provided written informed consent for treatment and publication of this report. The reporting of this study conforms to the CARE guidelines.<sup>3</sup>

## Discussion

SM is a rare disease that primarily affects middle-aged adults between the ages of 30 and 80 years, with infants and young children being rarely affected. There is no racial or gender predisposition.<sup>1</sup> The disease was originally proposed by Montgomery & Underwood in 1953 and later revised by Rongioletti and Reboria in 2001.<sup>4,5</sup> Due to its rarity, the current knowledge of SM is primarily derived from case reports and a limited number of retrospective studies.

The characteristic cutaneous manifestation of SM is the presence of widely distributed firm, waxy, slightly reddish or skin-colored dome-shaped or flattened papules measuring 2–3 mm in diameter. The most commonly affected areas include the face, neck, distal forearms, and hands, while the palms of the hands, scalp, and mucous membranes are typically unaffected. These papules often exhibit a distinct linear arrangement, and the surrounding skin appears shiny and firm. In rare cases, nontender subcutaneous nodules may be present. The presence of deep longitudinal furrow lines between the eyebrows gives rise to a characteristic lion-like appearance. Thickening of the proximal interphalangeal joints, along with central depression and deep furrow lines on the back or extremities, are common signs of SM. These signs are referred to as the “circle sign” and the “sandpaper sign”, respectively.<sup>6</sup> The diagnosis of SM is established based on the identification of the following clinicopathologic criteria: (i) presence of a generalized papular and scleroderma-like rash; (ii) microscopic triad consisting of mucin deposition, fibrosis, and fibroblast proliferation, and in rare cases, interstitial granulomatous-like lesions; (iii) presence of monoclonal gammopathy; and (iv) absence of thyroid disease.<sup>7</sup> The clinical manifestations of SM are diverse and can involve generalized skin lesions or multiple

organs. The most common associated condition is hyperimmunoglobulinemia with monoclonal immunoglobulinopathies, typically involving IgG- $\lambda$  with light chains. However, biclonal and polyclonal cases have also been reported. Other associated comorbidities encompass hematologic malignancies (eg, Hodgkin's lymphoma, non-Hodgkin's lymphoma, and leukemia), proximal muscle weakness, central and peripheral neuropathy, arthropathy, and potential involvement of the cardiopulmonary, gastrointestinal, and renal systems.<sup>8</sup> Although SM, scleredema, and scleroderma are distinct connective tissue disorders characterized by skin thickening, they differ in their causes, clinical features, and systemic involvement. Scleredema typically affects the upper back, shoulders, and neck and is often linked to metabolic conditions like diabetes or obesity; it is usually non-systemic and does not involve internal organs. Scleroderma (systemic sclerosis), a chronic autoimmune disease, causes fibrosis of both the skin and internal organs, frequently accompanied by systemic manifestations such as Raynaud's phenomenon, and involvement of the lungs, heart, and kidneys, as well as the presence of specific autoantibodies. While all three conditions involve skin hardening, scleroderma is the most systemic, scleromyxedema is associated with gammopathy, and scleredema is typically metabolic in origin and non-systemic.<sup>9</sup>

However, the precise etiology of SM remains unknown. The prevailing hypothesis suggests that circulating cytokines, including IL-1, TNF- $\alpha$ , and TGF- $\beta$ , which are known to stimulate glycosaminoglycan synthesis and fibroblast proliferation in the skin, may contribute to the pathogenesis of SM.<sup>1,10</sup> Clinical observations indicate that viral infections, such as HIV infection, may stimulate the production of mucin and collagen, thereby contributing to the development of SM.<sup>11,12</sup> Furthermore, SM has been reported to be associated with chronic hepatitis resulting from HCV infection.<sup>13,14</sup> Kim et al<sup>15</sup> presented a case report demonstrating that a 59-year-old woman with a 5-year history of hepatitis B developed cutaneous mucinopathy following the resolution of the herpes zoster rash. Taiwanese scholars conducted a systematic review of SM/Lichen Myxedematosus (LM) cases and found that 17.9% of SM patients were infected with HBV.<sup>16</sup> This indicates a potential association between viral hepatitis and SM, with the pathogenic mechanism likely involving chronic antigenic stimulation triggered by viral hepatitis. This stimulation leads to a cascade of dermal fibroblasts and the excessive production of mucin.<sup>10</sup> Moreover, the association of monoclonal gammopathy in SM suggests a role for plasma cell dysregulation in its pathogenesis. Chronic HBV infection, particularly in the chronic phase, has been implicated in the development of paraproteinemia and monoclonal gammopathies, potentially via immune activation and increased plasma cell production. Some studies have suggested that chronic viral infections, including hepatitis viruses, can provoke plasma cell expansion and the secretion of immunoglobulins, contributing to conditions like scleromyxedema.<sup>17</sup>

The current treatment options for SM comprise glucocorticoids, intravenous gamma globulin, melphalan, bortezomib, cyclophosphamide, methotrexate, cyclosporine, thalidomide, chloroquine, acitretin or isotretinoin, plasma exchange, PUVA, and ex vivo photochemotherapy.<sup>18,19</sup> However, due to the limited number of high-quality studies investigating the effects of SM treatment and the incomplete understanding of its pathogenesis, developing definitive guidelines for optimal treatment is challenging. The patient had a history of hepatitis B but declined testing for the virus during hospitalization, which prevented further consultation with the multidisciplinary team regarding hepatitis B virus control drugs. Subsequently, the patient received oral triamcinolone at a daily dosage of 12 mg. After 8 weeks of treatment, the skin lesions significantly improved, and the glucocorticoid dosage was reduced to 8 mg daily, with no recurrence of the lesions. Follow-up is currently ongoing. The patient responded well to glucocorticoid therapy but developed glucocorticoid-related adverse reactions, including folliculitis, facial edema, and toe spasms, which improved with symptomatic treatment. Furthermore, it is important to note that when a diagnosis of SM is confirmed and viral infection is suspected, timely multidisciplinary consultation should be organized to develop a treatment plan. Due to the lack of reports on HBV infection and SM in China, and considering the chronic and unpredictable progression of SM, clinicians should diligently monitor such cases. Additionally, given the potential association between HBV infection and SM, clinicians should maintain regular follow-up with these patients to prevent recurrence.

## Data Sharing Statement

This study does not include a dataset, so a data availability statement is not applicable.

## Ethics Statement

The reporting of this study conforms to the CARE guidelines. Ethical review and approval was not required to publish the case details in accordance with the local legislation and institutional requirements. Written informed consent was obtained from the patient for publication of this case report and any accompanying images as per our standard institutional rules.

## Author Contributions

All authors made a significant contribution to the work reported, whether that is in the conception, study design, execution, acquisition of data, analysis and interpretation, or in all these areas; took part in drafting, revising or critically reviewing the article; gave final approval of the version to be published; have agreed on the journal to which the article has been submitted; and agree to be accountable for all aspects of the work.

## Funding

This study was supported by the Science and Technology Program of Guangzhou (Grant No. 2024A03J0480).

## Disclosure

The authors declare no conflicts of interest in this work.

## References

- Rongioletti F, Merlo G, Cinotti E, et al. Scleromyxedema: a multicenter study of characteristics, comorbidities, course, and therapy in 30 patients. *J Am Acad Dermatol.* 2013;69(1):66–72. doi:10.1016/j.jaad.2013.01.007
- Patel DR, Vora N, Chaudhary R, Sharma V, Dadhaniya NV. Scleredema adultorum of buschke associated with diffuse eosinophilia and Hepatitis B virus infection. *Cureus.* 2023;15(4):e38300. doi:10.7759/cureus.38300
- Gagnier JJ, Kienle G, Altman DG, Moher D, Sox H, Riley D. The CARE guidelines: consensus-based clinical case reporting guideline development. *Headache.* 2013;53(10):1541–1547. doi:10.1111/head.12246
- Montgomery H, Underwood LJ. Lichen myxedematosus; differentiation from cutaneous myxedemas or mucoid states. *J Invest Dermatol.* 1953;20(3):213–236. doi:10.1038/jid.1953.25
- Rongioletti F, Rebora A. Updated classification of papular mucinosis, lichen myxedematosus, and scleromyxedema. *J Am Acad Dermatol.* 2001;44(2):273–281. doi:10.1067/mjd.2001.111630
- Ferrelli C, Gasparini G, Parodi A, Cozzani E, Rongioletti F, Atzori L. Cutaneous manifestations of scleroderma and scleroderma-like disorders: a comprehensive review. *Clin Rev Allergy Immunol.* 2017;53(3):306–336. doi:10.1007/s12016-017-8625-4
- Huang H, Qian SX. Lichen myxedematosus associated with monoclonal gammopathy of undetermined significance: a case report and literature review. *Front Med.* 2023;10:1118555. doi:10.3389/fmed.2023.1118555
- Wang SS, Chen QY, Xiang LH. Case report: scleromyxedema associated with a monoclonal gammopathy: successful treatment with intravenous immunoglobulins. *Front Immunol.* 2022;13:1099918. doi:10.3389/fimmu.2022.1099918
- Sreenivasan P, Nair S. Hepatitis B associated monoclonal gammopathy that resolved after successful liver transplant. *J Transplant.* 2009;2009:103784. doi:10.1155/2009/103784
- Mahévas T, Arnulf B, Bouaziz JD, et al. Plasma cell-directed therapies in monoclonal gammopathy-associated scleromyxedema. *Blood.* 2020;135(14):1101–1110. doi:10.1182/blood.2019002300
- Mohseni AZ, Goodarzi A, Emadi SN, et al. A comprehensive review on HIV-associated dermatologic manifestations: from epidemiology to clinical management. *Int J Microbiol.* 2023;2023:6203193. doi:10.1155/2023/6203193
- Concheiro J, Pérez-Pérez L, Peteiro C, Labandeira J, Toribio J. Discrete papular lichen myxoedematosus: a rare subtype of cutaneous mucinosis. *Clin Exp Dermatol.* 2009;34(8):e608–10. doi:10.1111/j.1365-2230.2009.03294.x
- Guarda NH, Bonamigo RR, Heck R. Case for diagnosis. Multiple infiltrated plaques in a patient with human immunodeficiency virus and hepatitis C co-infection: lichen myxedematosus. *An Bras Dermatol.* 2023;98(3):398–400. doi:10.1016/j.abd.2021.10.017
- Cárdenas-Gonzalez RE, Ruelas M, Candiani JO. Lichen myxedematosus: a rare group of cutaneous mucinosis. *An Bras Dermatol.* 2019;94(4):462–469. doi:10.1590/abd1806-4841.20198478
- Kim MB, Jwa SW, Ko HC, Kim SJ, Kwon KS, Oh CK. A case of secondary cutaneous mucinosis following herpes zoster: Wolf's isotopic response. *Int J Dermatol.* 2009;48(2):212–214. doi:10.1111/j.1365-4632.2009.03581.x
- Chen KY, Tzeng IS, Lee YY, Ting SW, Chang YY, Ng CY. Scleromyxedema and lichen myxedematosus: is it associated with viral hepatitis? *J Dermatol.* 2019;46(10):879–885. doi:10.1111/1346-8138.15039
- Visentini A, Rocchi M, Salvadori AG, Del Bravo P, Righi E. Infections and Paraproteinemia. In: Ragab G, Quartuccio L, Goubran H, editors. *Paraproteinemia and Related Disorders.* Cham: Springer International Publishing; 2022:277–304.
- Knobler R, Moinzadeh P, Hunzelmann N, et al. European dermatology forum S1-guideline on the diagnosis and treatment of sclerosing diseases of the skin, Part 2: Scleromyxedema, scleredema and nephrogenic systemic fibrosis. *J Eur Acad Dermatol Venereol.* 2017;31(10):1581–1594. doi:10.1111/jdv.14466
- Efthimiou P, Blanco M. Intravenous gammaglobulin and thalidomide may be an effective therapeutic combination in refractory scleromyxedema: case report and discussion of the literature. *Semin Arthritis Rheum.* 2008;38(3):188–194. doi:10.1016/j.semarthrit.2007.10.015

**Clinical, Cosmetic and Investigational Dermatology**

**Publish your work in this journal**

Clinical, Cosmetic and Investigational Dermatology is an international, peer-reviewed, open access, online journal that focuses on the latest clinical and experimental research in all aspects of skin disease and cosmetic interventions. This journal is indexed on CAS. The manuscript management system is completely online and includes a very quick and fair peer-review system, which is all easy to use. Visit <http://www.dovepress.com/testimonials.php> to read real quotes from published authors.

Submit your manuscript here: <https://www.dovepress.com/clinical-cosmetic-and-investigational-dermatology-journal>

**Dovepress**  
Taylor & Francis Group