


Visual Outcomes and Quality of Vision After Bilateral Implantation of a Hydrophobic Acrylic Trifocal Intraocular Lens

T Hunter Newsom¹, Brian Szabo¹, Kayla Unsell¹, Chase Newsom¹, Brooke Ayers Newsom¹, Brad Hall² 

¹Newsom Eye, Sebring, FL, USA; ²Sengi, Penniac, NB, Canada

Correspondence: T Hunter Newsom, Newsom Eye, 4211 US Hwy 27 N, Sebring, FL, 33870, USA, Tel +1-813-908-2020, Email hunter@newsomeye.net

Purpose: To evaluate visual outcomes and quality of vision following bilateral implantation of a hydrophobic acrylic intraocular lens (IOL) in eyes targeted for emmetropia.

Methods: This was a prospective, single arm study. Subjects were bilaterally implanted with the Clareon PanOptix IOL and evaluated at 1 and 3 months postoperatively. Endpoints included binocular uncorrected and distance-corrected visual acuities at distance (UDVA, CDVA), intermediate (UIVA, DCIVA; 60 cm), and near (UNVA, DCNVA; 40 cm, 33 cm), defocus curve, manifest refraction, and administration of a visual disturbance questionnaire (QUVID) and a satisfaction questionnaire (IOLSAT).

Results: A total of 24 subjects (48 eyes) completed the study. Mean postoperative binocular CDVA, DCIVA (60 cm), DCNVA (40 cm), and DCNVA (33 cm) were -0.04 ± 0.08 logMAR, -0.08 ± 0.10 logMAR, 0.01 ± 0.10 logMAR, and 0.04 ± 0.11 logMAR, respectively. Mean postoperative binocular UDVA, UIVA (60 cm), UNVA (40 cm), and UNVA (33 cm) were 0.02 ± 0.19 logMAR, -0.08 ± 0.09 logMAR, 0.04 ± 0.12 logMAR, and 0.08 ± 0.15 logMAR, respectively. Overall, postoperative spectacle independence at distance, intermediate, and near were 100%, 93%, and 73%, respectively. A total of 9%, 12%, and 0% of subjects were bothered “quite a bit” or “very much” by halos, starburst, and glare, respectively.

Conclusion: The results of this study suggest that bilateral implantation with the Clareon PanOptix can achieve excellent visual outcomes, high spectacle independence, and low reports of bothersome dysphotopsia.

Plain Language Summary: The natural lens inside the eye may eventually become opaque (develop a cataract). When that happens, it can be removed and replaced with an artificial intraocular lens (IOL). There are a variety of IOLs to choose from. For patients desiring spectacle independence, trifocal IOLs may be good option as this type of IOL is designed to provide clear vision to see far, arm’s length, and up close objects. The purpose of this study was to evaluate the visual outcomes and quality of vision following bilateral implantation of a new hydrophobic acrylic IOL (Clareon PanOptix). The results of this study suggest that bilateral implantation with the Clareon PanOptix can achieve excellent visual outcomes, high spectacle independence, and low reports of bothersome dysphotopsia.

Keywords: PanOptix, Clareon, cataract surgery

Introduction

There are many different types of intraocular lenses (IOLs) for patients to select. Monofocal IOLs allow for clear vision at distance and are the most popular implant. However, there are other options for patients that desire spectacle independence at intermediate and near distances. Extended depth of focus (EDOF) IOLs are designed to create one continuous focal point for decreased spectacle dependence at distance and intermediate.^{1,2} In contrast, trifocal IOLs split incoming light into 3 distinct focal points for decreased spectacle dependence at distance, intermediate, and near.³

The first trifocal IOL approved by the US Food and Drug Administration (FDA) was the AcrySof PanOptix. It is a diffractive trifocal IOL, distributing 50% of the incoming light for distance vision, 25% for intermediate vision, and 25% for near vision.³ Good clinical outcomes have been reported with the AcrySof PanOptix,^{4–6} however, as with any diffractive IOL, visual disturbances have been observed.^{7–10} A new version of the PanOptix IOL is available in a hydrophobic acrylic material (Clareon, Alcon Vision, LLC). The main difference between the AcrySof and Clareon materials is that the AcrySof material incorporates phenylethyl methacrylate (PEMA), while the Clareon material incorporates hydroxyethyl methacrylate (HEMA) to ensure an even distribution of water.¹¹ The water content of the Clareon material is also higher than that of the AcrySof material (1.5% versus 0.4% at 35°C).¹¹ In addition, the Clareon material has fewer microvacuoles and an improved manufacturing process, which may improve optical clarity.¹² Other published studies of the Clareon PanOptix to date are from South Korea or Japan or focused solely on toric IOLs.^{13–16} The purpose of this study was to evaluate visual outcomes and quality of vision following bilateral implantation of the Clareon PanOptix (both toric and non-toric) from patients in the United States.

Methods

This was a prospective, single-arm, observational study of visual outcomes and quality of vision following bilateral implantation of the Clareon PanOptix IOL. The study was reviewed and approved by an independent institutional review board (Salus IRB; approval THN-22-001). The study was reviewed by an independent IRB as the study was conducted in a private practice that does not have an IRB. All subjects gave written informed consent before participation. The tenets of the Declaration of Helsinki, Health Insurance Portability and Accountability Act (HIPAA), Good Clinical Practice, and International Harmonization (ICH) guidelines were followed. The study was registered on clinicaltrials.gov (NCT05518539). Data are not available for sharing.

The study was conducted from September 2022 to June 2024. Subjects were included that were adults (> 40 years), candidates for uncomplicated bilateral cataract surgery with trifocal IOL implantation, in good ocular health with no pathology that compromised visual acuity (outside of residual refractive error and cataract), and had expected visual potential of 20/25 Snellen (0.10 logMAR) or better in each eye. Subjects were excluded if they had corneal pathology, previous refractive surgery, pre-existing ocular pathology, including maculopathy, or glaucoma limiting or affecting visual potential.

Preoperative biometry was performed using the IOLMaster 500 (Carl Zeiss Meditec AG). To determine IOL power, the Barrett Universal II and Alcon Toric formulas were used, targeting emmetropia in each eye. The Clareon PanOptix toric and non-toric IOLs were bilaterally implanted (CNWTT0, CNW0T3, CNW0T4, CNW0T5, CNW0T6). For cylinder below the toric IOL indication (T3), limbal relaxing incisions were used during surgery.

Binocular uncorrected and distance corrected visual acuities were collected at 1 and 3 months postoperatively at distance (UDVA, CDVA), intermediate (UIVA, DCIVA; 60 cm), and near (UNVA, DCNVA; 40 cm, 33 cm). Visual acuities were collected using standard early treatment diabetic retinopathy (ETDRS) charts in logMAR. Questionnaires about quality of vision (QUVID) and IOL satisfaction (IOLSAT) were administered preoperatively and 3 months postoperatively. Both the QUVID and IOLSAT are validated and proprietary Alcon questionnaires. On the QUVID, subjects were asked to rate the frequency, severity, and bothersomeness of dysphotopsias using reference images. On the IOLSAT, subjects were asked to rate their spectacle independence and visual performance at distance, intermediate, and near. Refractive outcomes were also collected at 1 and 3 months postoperatively. A binocular defocus curve was performed at 3 months postoperatively. Areas under the curve were calculated using the trapezoidal numerical integration method, normalizing the 0.5 D defocus steps. The total defocus range was +1.00 D to –3.00 D, including +0.50 D to –0.50 D for far, –0.50 D to –2.00 D for intermediate, and –2.00 D to –3.00 D for near.

The primary endpoint was binocular DCNVA at 40cm. Secondary endpoints were binocular UDVA, CDVA, UIVA, DCIVA, UNVA (40 cm), and refractive outcomes. An exploratory endpoint was binocular DCNVA and UNVA at 33 cm. We anticipated that enrolling 30 patients would provide sufficient data (accounting for dropout) to characterize the visual outcomes and quality of vision with the Clareon PanOptix. All statistical analysis were performed using R (version 4.4.0; The R Foundation for Statistical Computing, Vienna, Austria).

Results

A total of 30 subjects (60 eyes) were enrolled. Three (3) subjects were lost to follow up before the 1 month visit. Another three (3) were lost to follow up between the 1 month and 3 month postoperative visits. There were no adverse events related to the IOL or surgery. Demographics and preoperative data are summarized in Table 1. Limbal relaxing incisions were performed in all 47 eyes that received a non-toric IOL.

The 3 month postoperative visual outcomes are summarized in Figure 1 and Table 2. Generally, the uncorrected visual acuities at distance, intermediate, and near were good with 79% of patients 20/25 or better at all distances. Likewise, distance corrected visual acuities at distance, intermediate, and near were also good with 92% of patients 20/25 or better at all distances. At extreme near (33 cm) the percentages of patients 20/25 or better for UNVA and DCNVA were 67% and 79%, respectively. Refractive outcomes at 3 month postoperative are also summarized in Figure 1. The percentages of eyes with MRSE and residual astigmatism ≤ 0.5 D were 96% and 96%, respectively.

A binocular defocus curve is summarized in Figure 2. Note that the total range is +1.00 D to -3.00 D. Areas under the curve were 2.02 total, 0.56 for far, 0.80 for intermediate, and 0.44 for near.

The IOLSAT questionnaire asked subjects to describe their spectacle use and visual performance, under different lighting conditions, at distance, intermediate and near. The results are summarized in Table 3. Spectacle independence was defined as answering “Never” or “Rarely”, while good visual performance was defined as answering “Very Good” or “Good”. Generally, spectacle independence and visual performance were higher postoperatively compared to preoperatively. Also, on the IOLSAT, 67% of patients reported their postoperative satisfaction as “Satisfied” or “Very Satisfied” compared to 4% preoperatively.

The QUID questionnaire asked subjects to rate the frequency, severity, and bothersomeness of seven different visual disturbances. The results are summarized in Table 4. Generally, visual disturbances were higher preoperatively compared to postoperatively. The visual disturbances that were rated “Moderate” or “Severe” by the largest percent of subjects were halos, starburst, and glare at 41%, 36%, and 9%, respectively. However, 9%, 12%, and 0% of subjects were bothered “quite a bit” or “very much” by halos, starburst, and glare, respectively.

Table 1 Demographics and Preoperative Data

Parameter	Outcomes*
Number of eyes (patients)	60 (30)
Sex	
Female (n)	20
Male (n)	10
Age	65.0 \pm 7.7 (49 to 83)
Sphere (D)	-0.63 \pm 3.50 (-10.75 to 3.50)
Cylinder (D)	0.86 \pm 0.85 (0.00 to 3.75)
MRSE (D)	-0.20 \pm 3.30 (-9.00 to 3.50)
Lens Model (n)	
CNWTT0	47
CNW0T3	7
CNW0T4	1
CNW0T5	3
CNW0T6	2

Note: *Presented as Mean \pm SD (Range) or n (%).

Abbreviation: CDVA, corrected distance visual acuity; D, diopters; SD, standard deviation.

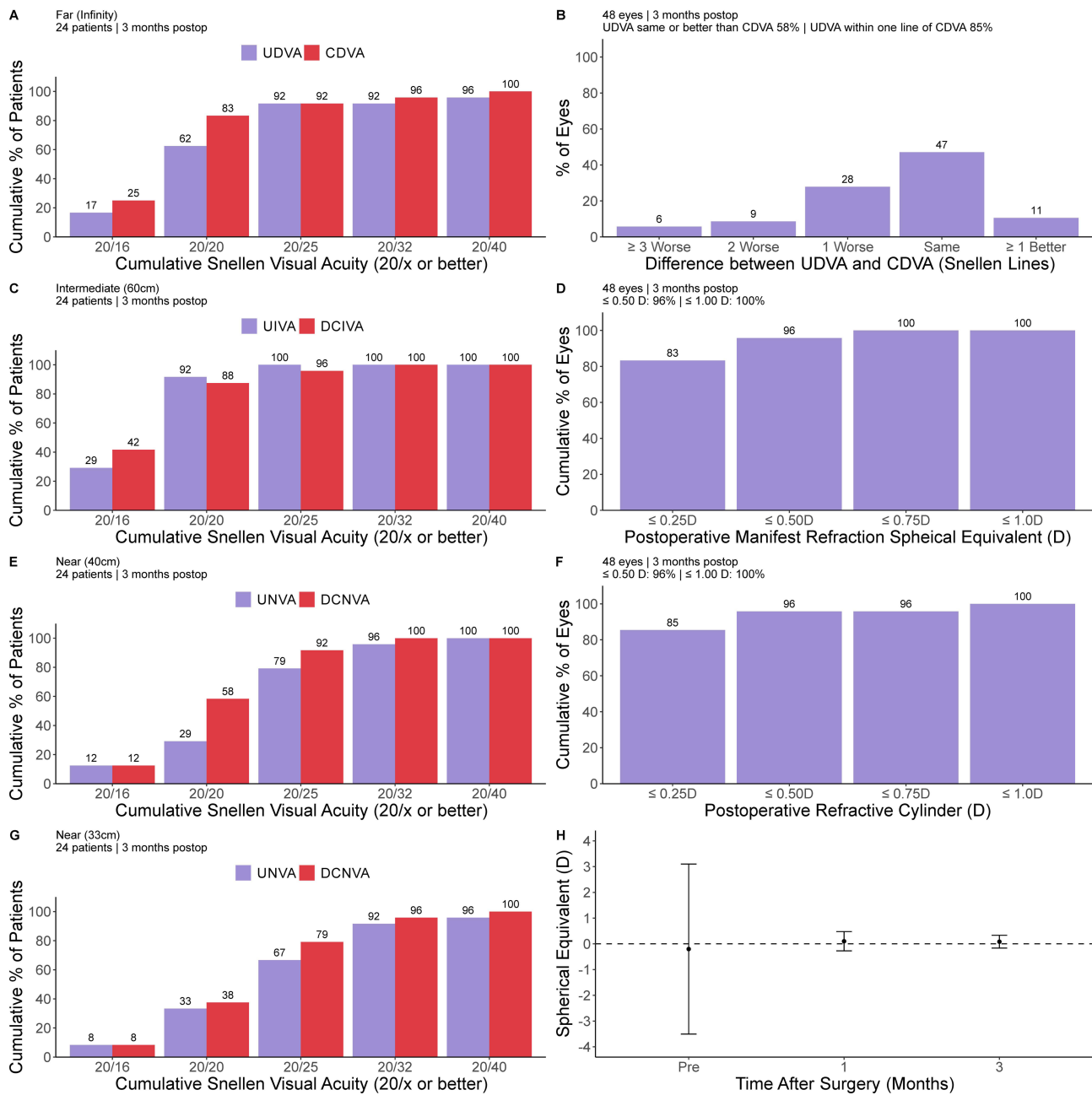


Figure 1 Standard efficacy plots for presbyopia correcting intraocular lenses. Cumulative percentage of patients achieving binocular uncorrected and distance corrected visual acuities at (A) far, (C) intermediate, (E) near, and (G) extreme near distances. (B) Difference in lines between postoperative UDVA and CDVA. (D) Postoperative manifest refraction spherical equivalent distribution, (F) postoperative refractive cylinder distribution and (H) spherical equivalent stability.

Discussion

We evaluated the clinical outcomes following bilateral implantation of the Clareon PanOptix toric and non-toric IOLs. Mean postoperative binocular CDVA, DCIVA, DCNVA (40 cm), and DCNVA (33 cm) were -0.04 logMAR, -0.08 logMAR, 0.01 logMAR, and 0.04 logMAR, respectively. These results are better than the monocular CDVA, DCIVA (70 cm), DCNVA (40 cm), and DCNVA (30 cm) outcomes reported by Yamashita et al¹³ of -0.05 logMAR, 0.12 logMAR, 0.11 logMAR, and 0.22 logMAR, respectively. However, we would expect binocular outcomes to be superior compared to monocular outcomes. Our results are also similar to the US FDA clinical trial of the AcrySof PanOptix (non-toric only), where binocular CDVA, DCIVA, and DCNVA were -0.06 logMAR, -0.01 logMAR, and 0.05 logMAR respectively.⁴ In addition, our results are similar to other reports of outcomes with the AcrySof PanOptix IOL.^{5,17-19}

Table 2 Postoperative Binocular Visual Acuities (logMAR)

Visual Acuity	1 Month	3 Months
UDVA	0.00 ± 0.08 (−0.10 to 0.24)	0.02 ± 0.19 (−0.20 to 0.82)
UIVA 60 cm	−0.04 ± 0.08 (−0.20 to 0.16)	−0.08 ± 0.09 (−0.24 to 0.10)
UNVA 40cm	0.04 ± 0.09 (−0.08 to 0.30)	0.04 ± 0.12 (−0.24 to 0.22)
UNVA 33cm	0.03 ± 0.10 (−0.16 to 0.32)	0.08 ± 0.15 (−0.16 to 0.60)
CDVA	−0.02 ± 0.07 (−0.14 to 0.22)	−0.04 ± 0.08 (−0.16 to 0.22)
DCIVA 60 cm	−0.04 ± 0.08 (−0.20 to 0.10)	−0.08 ± 0.10 (−0.20 to 0.12)
DCNVA 40cm	0.00 ± 0.06 (−0.18 to 0.10)	0.01 ± 0.10 (−0.26 to 0.20)
DCNVA 33cm	0.04 ± 0.08 (−0.14 to 0.18)	0.04 ± 0.11 (−0.18 to 0.28)

Note: Data presented as Mean ± SD (Range).

Abbreviations: CDVA, corrected distance visual acuity; DCIVA, distance corrected intermediate visual acuity; DCNVA, distance corrected near visual acuity; SD, standard deviation; UDVA, uncorrected distance visual acuity; UIVA, uncorrected intermediate visual acuity, UNVA, uncorrected near visual acuity.

Mean postoperative binocular UDVA, UIVA, UNVA (40 cm), and UNVA (33 cm) were 0.02 logMAR, −0.08 logMAR, 0.04 logMAR, and 0.08 logMAR, respectively, with the Clareon PanOptix. These results are similar to that reported by Jo et al,¹⁴ where binocular UDVA, UIVA, UNVA (40 cm) and UNVA (33 cm) were 0.04 logMAR, 0.04 logMAR, 0.03 logMAR, and 0.04 logMAR, respectively. Our results are also slightly higher than those reported by Melendez et al¹⁵ in toric IOLs only, where monocular UDVA, UIVA, and UNVA (40 cm) were 0.10 logMAR, 0.18 logMAR, and 0.07 logMAR, respectively. However, we again would expect binocular outcomes to be superior compared to monocular outcomes. Our binocular defocus curve is similar to that reported by Lee et al,¹⁶ however they measured defocus from 0.00 D to −4.00 D, compared to +1.00 D to −3.00 D in our study.

The uncorrected visual acuities in our study translated into high spectacle independence. Patient reported spectacle independence with the Clareon PanOptix overall at distance, intermediate, and near was 100%, 93%, and 73%, respectively, using the IOLSAT questionnaire. Using a different questionnaire, Jo et al¹⁴ observed patients reported spectacle independence of 98%, 100%, and 95% at distance, intermediate, and near, respectively. Studies of the AcrySof PanOptix have also reported high spectacle independence and satisfaction using a variety of questionnaires.^{4,7,8,20,21}

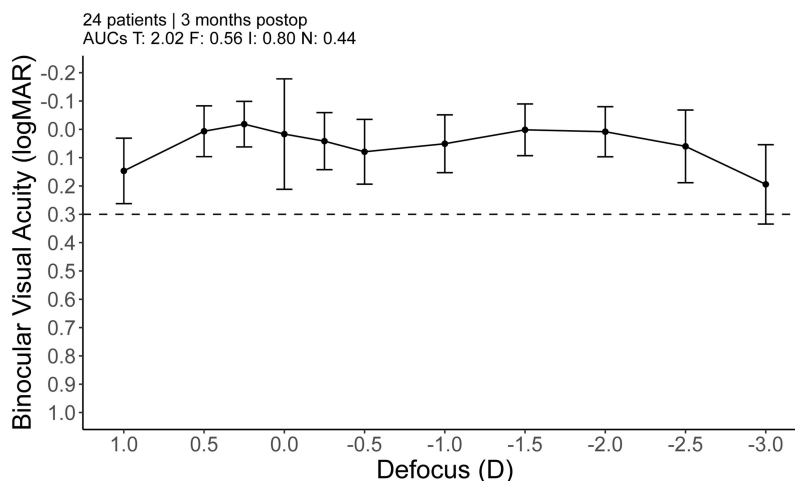


Figure 2 Binocular defocus curve including areas under the curve for (T) total, (F) far, (I) intermediate, and (N) near. Error bars represent the standard deviation.

Table 3 IOLSAT Questionnaire About Spectacle Independence and Visual Performance

Spectacle Independence	Preoperative (%)	3 Months Postoperative (%)
Distance (Overall)	14	100
Distance (Bright Light)	14	100
Distance (Dim Light)	10	100
Intermediate (Overall)	14	93
Intermediate (Bright Light)	10	93
Intermediate (Dim Light)	7	93
Near (Overall)	3	73
Near (Bright Light)	3	93
Near (Dim Light)	3	80
Visual Performance	Preoperative (%)	3 Months Postoperative (%)
Distance (Bright Light)	0	87
Distance (Dim Light)	0	67
Intermediate (Bright Light)	0	80
Intermediate (Dim Light)	0	80
Near (Bright Light)	0	80
Near (Dim Light)	0	67

A report by Lee et al¹⁶ suggested that the visual disturbances with the Clareon PanOptix may be lower than with the AcrySof PanOptix. On the QUID questionnaire, the percentages of subjects that were bothered “quite a bit” or “very much” by starbursts, halos, and glare, were 12%, 9%, and 0%, respectively. This is similar to the results of US FDA trial

Table 4 Summary of QUID Questionnaire Responses

	Frequency		Severity		Bothersomeness	
	(%) “Most of the time” or “Always”		(%) “Moderate” or “Severe”		(%) “Bothered quite a bit” or “Bothered very much”	
	Preop	3 Months	Preop	3 Months	Preop	3 Months
Starbursts	31	24	52	36	38	12
Halos	30	27	33	41	30	9
Glare	52	0	62	9	48	0
Haze	64	4	57	4	54	0
Blurred Vision	50	0	46	0	61	0
Double Vision	12	0	8	0	12	0
Dark Area	0	0	0	0	0	0

of the AcrySof PanOptix using the QUID questionnaire.⁴ Using a different questionnaire, Jo et al¹⁴ observed that moderate to severe visual disturbances were reported by 38% of patients with the Clareon PanOptix.

The primary limitation of this study was the high drop-out rate. A total of 30 subjects were enrolled, but 6 were lost to follow up. These 6 subjects were only present in Florida for the winter and returned to their primary residences before completing all visits. The relatively small sample size was also a limitation of this study. However, the sample should be sufficient to describe the performance of the Clareon PanOptix. Another limitation was the single-arm nature of the study. We have compared our results to other published studies, however having a direct comparison between the Clareon PanOptix and AcrySof PanOptix would have allowed for more definitive conclusions to be drawn.

In conclusion, the results of this study suggest that bilateral implantation with the Clareon PanOptix can achieve excellent visual outcomes and high spectacle independence.

Acknowledgments

This paper was presented at the 2023 and 2024 American Society of Cataract and Refractive Surgery (ASCRS) Annual Meetings as a conference talk with interim findings.

Funding

This study was supported with an investigator-initiated study grant (72606713) from Alcon Vision, LLC, Fort Worth, TX, USA.

Disclosure

The authors report no conflicts of interest for this work.

References

- Ozulken K, Kiziltoprak H, Yuksel E, Mumcuoglu T. A Comparative Evaluation of Diffractive Trifocal and New Refractive/Extended Depth of Focus Intraocular Lenses for Refractive Lens Exchange. *Curr Eye Res*. 2021;46:811–817. doi:10.1080/02713683.2020.1833347
- Hovanesian JA, Jones M, Allen Q. The Vivity extended range of vision IOL vs the PanOptix trifocal, ReSTOR 2.5 active focus and ReSTOR 3.0 multifocal lenses: a comparison of patient satisfaction, visual disturbances, and spectacle Independence. *Clin Ophthalmol*. 2022;16:145–152. doi:10.2147/OPHTH.S347382
- Garcia-Perez JL, Gros-Otero J, Sanchez-Ramos C, Blazquez V, Contreras I. Short term visual outcomes of a new trifocal intraocular lens. *BMC Ophthalmol*. 2017;17:72. doi:10.1186/s12886-017-0462-y
- Modi S, Lehmann R, Maxwell A, et al. Visual and patient-reported outcomes of a diffractive trifocal intraocular lens compared with those of a monofocal intraocular lens. *Ophthalmology*. 2021;128:197–207. doi:10.1016/j.ophtha.2020.07.015
- Lapid-Gortzak R, Bhatt U, Sanchez JG, et al. Multicenter visual outcomes comparison of 2 trifocal presbyopia-correcting IOLs: 6-month postoperative results. *J Cataract Refract Surg*. 2020;46:1534–1542. doi:10.1097/j.jcrs.0000000000000274
- Kohnen T, Marchini G, Alfonso JF, et al. Innovative trifocal (quadrifocal) presbyopia-correcting IOLs: 1-year outcomes from an international multicenter study. *J Cataract Refract Surg*. 2020;46:1142–1148. doi:10.1097/j.jcrs.0000000000000232
- Schallhorn JM. Multifocal and extended depth of focus intraocular lenses: a comparison of data from the United States food and drug administration premarket approval trials. *J Refract Surg*. 2021;37:98–104. doi:10.3928/1081597X-20201111-02
- Hovanesian JA, Jones M, Allen Q. The PanOptix trifocal IOL vs the ReSTOR 2.5 active focus and ReSTOR 3.0-add multifocal lenses: a study of patient satisfaction, visual disturbances, and uncorrected visual performance. *Clin Ophthalmol*. 2021;15:983–990. doi:10.2147/OPHTH.S285628
- Cao K, Friedman DS, Jin S, et al. Multifocal versus monofocal intraocular lenses for age-related cataract patients: a system review and meta-analysis based on randomized controlled trials. *Surv Ophthalmol*. 2019;64:647–658. doi:10.1016/j.survophthal.2019.02.012
- Pedrotti E, Carones F, Talli P, et al. Comparative analysis of objective and subjective outcomes of two different intraocular lenses: trifocal and extended range of vision. *BMJ Open Ophthalmol*. 2020;5:e000497. doi:10.1136/bmjophth-2020-000497
- Maxwell A, Suryakumar R. Long-term effectiveness and safety of a three-piece acrylic hydrophobic intraocular lens modified with hydroxyethyl-methacrylate: an open-label, 3-year follow-up study. *Clin Ophthalmol*. 2018;12:2031–2037. doi:10.2147/OPHTH.S175060
- Wang Q, Yildirim TM, Schickhardt SK, et al. Quantification of the In Vitro Predisposition to Glistening Formation in One Manufacturer's Acrylic Intraocular Lenses Made in Different Decades. *Ophthalmol Ther*. 2021;10:165–174. doi:10.1007/s40123-020-00329-8
- Yamashita K, Hayashi K, Hata S. Clinical performance and shape analysis of trifocal intraocular lenses via scanning electron microscopy. *BMC Ophthalmol*. 2024;24:86. doi:10.1186/s12886-024-03355-3
- Jo E, Kim B, Kim TI, Kim MK, Choi CY. Clinical outcomes of a new hydrophobic trifocal intraocular lens with hydroxyethyl methacrylate in cataract surgery: a prospective multicenter study. *Korean J Ophthalmol*. 2024;38:212–220. doi:10.3341/kjo.2023.0140
- Melendez R, Nguyen T, Solis A, Ortiz D, Moezzi C, Hall B. Outcomes after implantation of a trifocal toric intraocular lens using intraoperative aberrometry, digital image tracking, and femtosecond laser. *Clin Ophthalmol*. 2024;18:2033–2039. doi:10.2147/OPHTH.S460060
- Lee YW, Choi CY, Moon K, et al. Clinical outcomes of new multifocal intraocular lenses with hydroxyethyl methacrylate and comparative results of contrast sensitivity, objective scatter, and subjective photic phenomena. *BMC Ophthalmol*. 2022;22:379. doi:10.1186/s12886-022-02600-x

17. Kim TI, Chung TY, Kim MJ, Lee K, Hyon JY. Visual outcomes and safety after bilateral implantation of a trifocal presbyopia correcting intraocular lens in a Korean population: a prospective single-arm study. *BMC Ophthalmol.* 2020;20:288. doi:10.1186/s12886-020-01549-z
18. Kohnen T, Lapid-Gortzak R, Ramamurthy D, et al. Clinical Outcomes After Bilateral Implantation of a Diffractive Trifocal Intraocular Lens: a Worldwide Pooled Analysis of Prospective Clinical Investigations. *Clin Ophthalmol.* 2023;17:155–163. doi:10.2147/OPTH.S377234
19. Ramamurthy D, Vasavada A, Padmanabhan P, et al. Clinical Outcomes After Bilateral Implantation of a Trifocal Presbyopia-Correcting Intraocular Lens in an Indian Population. *Clin Ophthalmol.* 2021;15:213–225. doi:10.2147/OPTH.S279001
20. Blehm C, Potvin R. Reported Patient Satisfaction and Spectacle Independence Following Bilateral Implantation of the PanOptix(R) Trifocal Intraocular Lens. *Clin Ophthalmol.* 2021;15:2907–2912. doi:10.2147/OPTH.S323337
21. Ribeiro FJ, Ferreira TB. Comparison of visual and refractive outcomes of 2 trifocal intraocular lenses. *J Cataract Refract Surg.* 2020;46:694–699. doi:10.1097/j.jcrs.000000000000118

Clinical Ophthalmology

Publish your work in this journal

Clinical Ophthalmology is an international, peer-reviewed journal covering all subspecialties within ophthalmology. Key topics include: Optometry; Visual science; Pharmacology and drug therapy in eye diseases; Basic Sciences; Primary and Secondary eye care; Patient Safety and Quality of Care Improvements. This journal is indexed on PubMed Central and CAS, and is the official journal of The Society of Clinical Ophthalmology (SCO). The manuscript management system is completely online and includes a very quick and fair peer-review system, which is all easy to use. Visit <http://www.dovepress.com/testimonials.php> to read real quotes from published authors.

Submit your manuscript here: <https://www.dovepress.com/clinical-ophthalmology-journal>

Dovepress

Taylor & Francis Group