

Predictive Value of Netrin-1 Expression and Ultrasonic Blood Flow in Cervical Intraepithelial Neoplasia Severity

Bo Liu, Ling Wei, Lirui Wu, Huiying Wang, Hongli Wang, Qian Yu

Department of Gynecology, Hebei Petro China Center Hospital, Langfang, People's Republic of China

Correspondence: Ling Wei, Email 74037604@qq.com

Objective: To analyze the relationship and predictive value of Netrin-1 expression and ultrasonic blood flow parameters with the severity of cervical intraepithelial neoplasia (CIN).

Methods: A retrospective analysis was performed on 115 patients diagnosed with CIN and 37 patients with chronic cervicitis, all of whom underwent surgical intervention. The expression levels of Netrin-1 were evaluated through immunohistochemical staining and quantitative fluorescence PCR. Doppler ultrasound was employed to quantify flow index (FI), vascularization index (VI), and vascularization flow index (VFI) using VOCAL software. Statistical analyses, including correlation analysis, logistic regression, and receiver operating characteristic (ROC) curve analysis, were conducted to assess the predictive value of Netrin-1 expression and ultrasound-derived blood flow parameters.

Results: FI, VI, and VFI increased with CIN grade, showing significant differences between CIN II, CIN III, and the control group ($P < 0.05$). Netrin-1 levels were negatively correlated with FI, VI, and VFI (correlation coefficients of -0.287 , -0.309 , and -0.298 ; $P < 0.05$). Logistic regression indicated that Netrin-1 positivity was a protective factor against CIN III, while FI, VI, and VFI were risk factors. The AUC for Netrin-1 was 0.712, with sensitivity and specificity of 76.4% and 79.5% ($P < 0.05$).

Conclusion: Netrin-1 expression is significantly reduced in CIN patients, whereas Doppler ultrasound-derived blood flow parameters—FI, VI, and VFI—are markedly elevated. Both Netrin-1 levels and these ultrasound parameters exhibit a strong correlation with the severity of cervical lesions. Notably, Netrin-1 is negatively correlated with FI, VI, and VFI. Furthermore, Netrin-1 positivity serves as a protective factor against CIN III lesions, while elevated levels of FI, VI, and VFI are associated with increased risk for these lesions. The expression levels of both Netrin-1 and ultrasound parameters provide valuable predictive insights for the early screening, diagnosis, and prevention of cervical cancer.

Keywords: Netrin-1, ultrasonic blood flow parameters, cervical intraepithelial neoplasia, severity, predictive value

Introduction

Cervical intraepithelial neoplasia (CIN) is a precancerous lesion of cervical cancer, classified into three grades. CIN I is considered a low-grade precancerous lesion with a relatively low risk of malignancy, while CIN II and III have a higher risk of cancer progression. With environmental changes and advancements in medical technology, the detection rate of CIN has increased.

Studies indicate that over two-thirds of CIN III cases can progress to carcinoma in situ, with severe cases potentially advancing to invasive cervical cancer, posing a significant threat to patient health.¹ Surgical intervention remains the primary treatment for cervical cancer and high-grade CIN. For women seeking to preserve fertility, cervical conization is frequently performed; however, the high recurrence rate post-surgery adversely affects clinical outcomes and prognosis. Clinically, CIN often presents without obvious symptoms, leading most patients to remain asymptomatic. Consequently, early diagnosis and detection are critical in reducing the incidence of cervical cancer. Currently, CIN detection primarily

relies on invasive examinations that are complex and time-consuming.² Thus, the identification of more precise biomarkers to predict the occurrence and progression of CIN is of paramount importance.

Netrin-1, the first axon guidance factor identified within the netrin family, is recognized for its dual role in axonal guidance, where it can exert both attractive and repulsive effects. Additionally, it is involved in various physiological processes, including neuronal migration, angiogenesis, and anti-apoptotic activities.³ Domestic studies have demonstrated that Netrin-1 is expressed in proliferative fibrous tissue and vascular endothelial cells at the junction between the endometrium and myometrium in adenomyosis, suggesting its potential role in the development of adenomyosis through the promotion of angiogenesis and neural fiber proliferation.⁴

Currently, the relationship between neural and vascular factors and adenomyosis has become a research focus. However, the expression of Netrin-1 in cervical diseases and its relationship with disease severity have not been fully elucidated. Additionally, ultrasound-derived blood flow parameters play a crucial role in assessing tumor vascularity.⁵ Utilizing Doppler ultrasound and associated software analysis, parameters such as flow index (FI), vascularization index (VI), and vascularization flow index (VFI) can be obtained, allowing for an objective evaluation of tumor blood supply.⁶ This study aims to explore the expression of Netrin-1 in CIN patients and analyze its correlation with ultrasonic blood flow parameters in disease severity assessment. Through retrospective analysis of clinical data of CIN patients and patients with chronic cervicitis, we attempt to validate whether Netrin-1 and ultrasonic blood flow parameters can serve as potential biomarkers and auxiliary diagnostic methods for early screening, diagnosis, and prevention of cervical cancer transformation.

Materials and Methods

Clinical Data

A retrospective analysis was conducted on the clinical data of 115 patients with CIN admitted to our hospital from January 2022 to January 2024, and they were included in the observation group (pathological examination showed 42 cases of CIN I, 39 cases of CIN II, and 34 cases of CIN III). Additionally, 37 patients with chronic cervicitis during the same period were selected as the control group.

Inclusion and Exclusion Criteria

Inclusion Criteria

Participants were included if they were clinically diagnosed with CIN or chronic cervicitis based on relevant diagnostic tests;^{7,8} were females aged 18 to 70 years; had undergone surgical treatment at our institution; had lesion tissues collected during surgery that were confirmed by immunohistochemical staining pathology; had no prior history of radiotherapy or chemotherapy before surgery, and no hormonal treatment within the six months preceding surgery; and had complete and reliable clinical data available for analysis.

Exclusion Criteria

Patients were excluded if they exhibited severe dysfunction of vital organs; had abnormalities in immune function, coagulation function, or hematopoietic function; had a history of malignant tumors; presented with cognitive impairment or consciousness disorders; or had undergone previous cervical surgery.

The baseline data, including age, body mass index (BMI), and disease duration, were comparable between the two groups ($P > 0.05$). All patients underwent a preoperative three-dimensional energy Doppler ultrasound examination due to abnormal findings in cervical cytology. This examination was conducted prior to surgical intervention to acquire detailed vascular parameters and lesion characteristics.

In this study, the decision to perform surgical intervention for CIN I was based on individualized clinical assessments, taking into account factors such as the persistence of lesions, patient age, immune status, and risk of progression. Surgical treatment was deemed necessary in cases where CIN I lesions recurred or presented potential risk factors for progression. This approach adhered to ethical guidelines, ensuring that treatment decisions prioritized patient safety and minimized the risk of disease progression. All procedures received approval from the Ethics Committee, and informed consent was obtained from all participants.

Methods

This study protocol was approved by the ethics committee of Hebei Petro China Center Hospital, No.2975913. Informed consent was obtained from all study participants. All the methods were carried out in accordance with the Declaration of Helsinki.

Immunohistochemical Staining

Paraffin tissue sections were prepared at a thickness of 4 μm , and staining was conducted according to the kit instructions. During the staining process, the working concentration of the Netrin-1 monoclonal antibody was diluted to 1:100. Pathological tissue sections served as positive controls, while phosphate-buffered saline (PBS) was used as a negative control in place of the primary antibody. Positive cells were identified by their distinct cell structure and brown or tan staining.

To semi-quantitatively evaluate Netrin-1 positivity, the staining intensity of the cells was classified into grades: 0 for no staining, 1 for pale yellow, 2 for tan, and 3 for brown. Additionally, the percentage of positive cells within the sample was assessed, categorized as follows: 0 for no positive cells, 1 for less than 25% positive cells, 2 for 25% to 50% positive cells, and 3 for more than 50% positive cells.

The final score was calculated by multiplying the staining intensity by the percentage of positive cells. A score of 2 points or higher was considered immunohistochemically positive (+), while a score below 2 was deemed negative (-).

Netrin-1 mRNA Expression Level in Pathological Tissues

Fluorescence quantitative PCR technology was used to detect the expression level of Netrin-1 mRNA in pathological tissues. Total RNA was extracted from tissue samples using Trizol (Sigma, USA). Reverse transcription reaction was performed, followed by PCR amplification, with β -actin as an internal reference. The PCR amplification conditions were set as follows: pre-denaturation at 95°C for 30 seconds, followed by 40 cycles of denaturation at 95°C for 5 seconds, and extension at 60°C for 35 seconds. The specific primer sequences are shown in Table 1 below. Finally, the expression level of Netrin-1 mRNA was calculated using the $2^{-\Delta\Delta C_t}$ method.

Ultrasonography

A GE E8 hitachi ultrasound diagnostic instrument was used for transvaginal cervical ultrasound examination in non-menstruating patients, with a probe frequency set between 5 to 10 MHz. Prior to the examination, patients were instructed to empty their bladders and assume the lithotomy position. The ultrasound examination commenced with routine disinfection of the external genitalia, after which the probe was covered with a condom and a coupling agent was applied. The probe was then gently inserted into the vagina until it reached the vaginal fornix.

During the examination, the size, echogenicity, continuity of the cervical endometrial line, and any thickening of the cervix were recorded and evaluated. If a mass was detected, its size, internal echogenicity, and hemodynamic characteristics were further assessed.

The blood FI, VI, and VFI were calculated using VOCAL software at the site of strongest blood flow signal. All ultrasound examinations and blood flow data measurements were performed by the same professional physician. The cervix was scanned three times at the lesion site for each patient, and the average value was statistically analyzed.

Statistical Analysis

Data were processed using the SPSS 20.0 software package. Numerical data were presented as means (\pm standard deviation) and analyzed using one-way ANOVA for comparisons among multiple groups. When ANOVA indicated significant differences, post-hoc analyses were conducted for pairwise comparisons. Categorical data were expressed as n (%) and

Table 1 Primer Sequences

-	-	Primer Sequences
Netrin-1	Upstream	5'-AAGCCTATCACCCACCGGAAG-3'
	Downstream	5'-GCGCCACAGGAATCTTGATGG
β -actin	Upstream	5'-AGAGGGAAATCGTGCGTGAC
	Downstream	5'-CAATCGTGACCTGGCCGT-3'

analyzed using the chi-square test. Pearson correlation was used to assess the relationship between Netrin-1 expression and ultrasound blood flow parameters (FI, VI, and VFI). Multivariate logistic regression was conducted to identify factors associated with CIN severity. Receiver operating characteristic (ROC) curves were used to evaluate the predictive value of Netrin-1 and ultrasound blood flow parameters. A P-value < 0.05 was considered statistically significant.

Results

Netrin-1 Fluorescence Quantitative PCR Expression Level and Immunohistochemical Staining Results

The expression level of Netrin-1 mRNA in the observation group was significantly lower than in the control group ($P < 0.05$). Additionally, mRNA expression levels of Netrin-1 decreased progressively across CIN I, II, and III, with significant differences observed compared to the control group ($P < 0.05$). Microscopic analysis showed that the positive expression rate of Netrin-1 protein in the observation group was also lower than that in the control group ($P < 0.05$). Moreover, there were statistically significant differences in the positive expression rates of Netrin-1 protein among the pathological tissues of patients with CIN I, II, and III ($P < 0.05$), as presented in Table 2.

Comparison of Ultrasound Blood Flow Parameters Levels in Patients with Different Degrees of Lesions

The ultrasound blood flow parameters FI, VI, and VFI were all significantly higher in the observation group compared to the control group ($P < 0.05$). Additionally, in the observation group, the levels of FI, VI, and VFI increased progressively from CIN I to CIN III, with statistically significant differences noted between patients with CIN II and III and the control group ($P < 0.05$), as detailed in Table 3.

Correlation Between Netrin-1 and Ultrasound Blood Flow Parameters FI, VI, and VFI

Netrin-1 showed a negative correlation with ultrasound blood flow parameters FI, VI, and VFI ($r = -0.287, -0.309, -0.298, P < 0.05$), as shown in Figure 1.

Table 2 Netrin-1 Fluorescence Quantitative PCR Expression Level and Immunohistochemical Staining Results [$\bar{x} \pm s, n (\%)$]

Group	n	Netrin-1 mRNA	Netrin-1 Protein Expression	
			+	-
Control	37	0.62±0.25	29 (78.38)	8 (21.62)
Observation	115	0.38±0.14 ^a	32 (27.83) ^a	83 (72.17)
I	42	0.47±0.13 ^a	18 (42.86) ^a	24 (57.14)
II	39	0.34±0.13 ^{a,b}	10 (25.64) ^a	29 (74.36)
III	34	0.29±0.10 ^{a,b}	4 (11.76) ^{a,b}	30 (88.24)

Notes: Compared with the control group, ^a $P < 0.05$; compared with the I group, ^b $P < 0.05$.

Table 3 Comparison of Ultrasound Blood Flow Parameters Levels in Patients with Different Degrees of Lesions ($\bar{x} \pm s$)

Group	n	FI (dB)	VI (%)	VFI (dB)
Control	37	33.51±3.13	0.81±0.13	0.64±0.28
Observation	115	38.65±4.24 ^a	1.85±0.77 ^a	1.27±0.53 ^a
I	42	34.49±3.28	0.87±0.14	0.81±0.32
II	39	39.07±4.13 ^{a,b}	1.73±0.65 ^{a,b}	1.32±0.55 ^{a,b}
III	34	43.59±5.22 ^{a,b,c}	3.18±1.14 ^{a,b,c}	1.78±0.60 ^{a,b,c}

Notes: Compared with the control group, ^a $P < 0.05$; compared with the I group, ^b $P < 0.05$; compared with the II group, ^c $P < 0.05$.

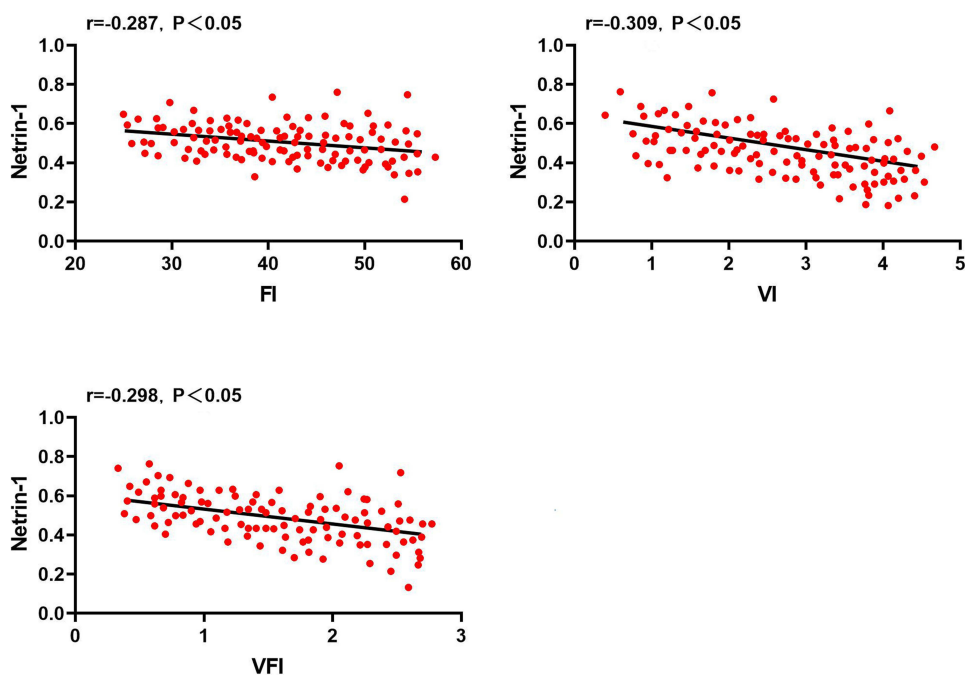


Figure 1 Correlation between Netrin-1 and Ultrasound Blood Flow Parameters FI, VI, and VFI.

Analysis of Factors Affecting the Severity of CIN

Using the occurrence of Grade III lesions in CIN patients as the dependent variable and Netrin-1 expression level, ultrasound blood flow parameters FI, VI, and VFI as independent variables, multiple logistic regression analysis was conducted. The results showed that Netrin-1 positivity was a protective factor for Grade III CIN lesions, while FI, VI, and VFI were risk factors for Grade III CIN lesions, as shown in [Table 4](#).

Predictive Value of Different Indicators for CIN Grade III Lesions

The AUC area for Netrin-1 was 0.732, with sensitivity and specificity of 76.4% and 79.5% respectively, which were higher than other indicators ($P < 0.05$), as shown in [Table 5](#) and [Figure 2](#).

Table 4 Analysis of Factors Affecting the Severity of CIN

Factor	β	S.E.	Wald X^2	P	OR (95% CI)
Netrin-1	0.301	0.129	5.526	0.020	0.745 (0.574~0.957)
FI	0.363	0.167	4.879	0.031	1.441 (1.038~1.976)
VI	0.254	0.121	4.517	0.035	1.287 (1.023~1.625)
VFI	0.356	0.133	12.569	0.011	1.423 (1.091~1.844)

Table 5 Predictive Value of Different Indicators for CIN Grade III Lesions

Indicator	AUC	95% CI	Sensitivity (%)	Specificity (%)
Netrin-1	0.732	0.318~0.826	76.4	79.5
FI	0.676	0.549~0.931	70.9	74.5
VI	0.631	0.439~0.816	72.4	73.8
VFI	0.704	0.523~0.767	72.6	76.6

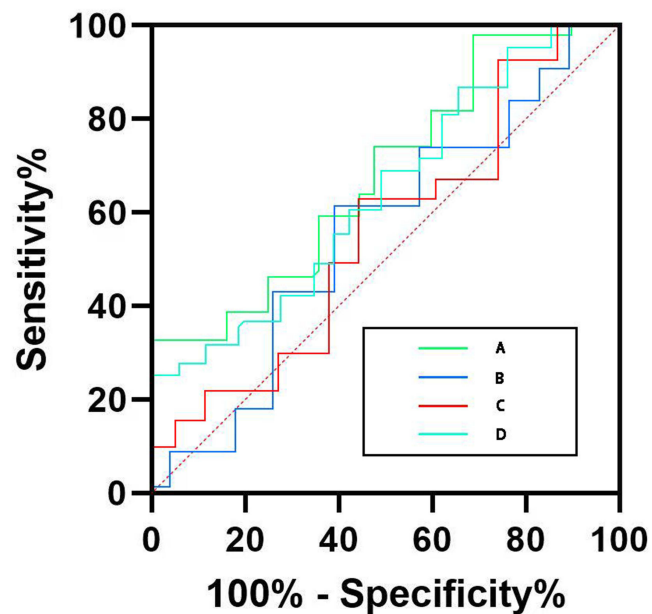


Figure 2 ROC curves for predicting CIN Grade III lesions using different indicators.
Notes: A (Netrin-1); B (Fl); C (Vl); D (VFl).

Discussion

Research indicates that in endometrial diseases, endometrial invasion, neovascularization, and neural fiber proliferation all play important roles.^{9–11} Netrin-1 is a secreted protein with a molecular weight of 80 kD, its main function is to guide the growth and development of neuronal axons in specific directions through regulation by its receptors.¹² However, due to the diversity of its receptors, the action of Netrin-1 can be either attractive or repulsive.¹³ Vascular and neural structures have anatomical similarities, and research¹⁴ suggests that fluoxetine can upregulate the expression of HIF-1 α -Netrin/VEGF cascade proteins, thereby promoting angiogenesis and improving long-term functional recovery after ischemic stroke. Furthermore, research¹⁵ indicates that Netrin-1 can induce angiogenesis of endometrial lesions by interacting with CD146 in vascular endothelial cells, playing an important role in neurovascularization of endometriosis. Therefore, Netrin-1 not only promotes the proliferation of vascular endothelial cells but also promotes their migration and adhesion. In this study, we found that the expression of Netrin-1 was significantly increased in the cell membrane, cytoplasm, and cell-cell junctions of fibrous proliferative tissues. Compared to the control group, the positive expression rate of Netrin-1 protein in CIN patients from the observation group was significantly lower, with a decreasing trend observed as the lesions progressed. This indicates that Netrin-1 may have an important protective role in the development of CIN, although its specific mechanism of action remains unclear and warrants further investigation. Additionally, neurovascularization is essential for the survival of metastatic tissues and tumors. A prior research indicates that interleukin-1 (IL-1), a pro-inflammatory cytokine secreted by macrophages, may regulate the generation of neural cells by stimulating ectopic endometrial stromal cells.¹⁶ Recent studies have also found that Netrin-1 can inhibit cell apoptosis by increasing the proportion of regulatory T cells and reducing the infiltration of T cells and macrophages, thereby reducing lung ischemia-reperfusion injury in mice.¹⁷ Therefore, we speculate that Netrin-1 may be involved in the physiological and pathological processes of vascular genesis and inflammatory response in CIN patients through different pathways. In conclusion, the treatment of CIN still faces challenges, and Netrin-1, as an important regulatory factor, may play a crucial protective role in the development of CIN. However, its specific mechanism is unclear and further research is needed for in-depth exploration.

In recent years, with the widespread application and development of Doppler ultrasound technology, its importance in the diagnosis and treatment of cervical lesions has gradually become prominent.¹⁸ Compared to traditional two-

dimensional imaging, Doppler ultrasound offers a visual representation of abnormal blood flow signals within lesion or cancerous tissues, facilitating accurate differentiation of blood flow patterns in lesions, cancerous tissues, and surrounding areas.¹⁹ By employing computer software for combined analysis, hemodynamic parameters such as FI, VI, and VFI can be directly obtained, enhancing clinical treatment and analysis. FI reflects the total number of blood cells detected during three-dimensional scanning, VI indicates the number of vessels identified at the lesion site, and VFI represents the cumulative vascular information and blood cell counts detected in the affected area.²⁰ In the early diagnosis of cervical dysplasia and carcinoma, vaginal ultrasound, as an intracavitary ultrasound technique, has a high image resolution and can accurately detect abnormal blood flow signals within lesion foci, possessing high clinical utility. Several studies have shown that in early cervical dysplasia and carcinoma, vaginal ultrasound can clearly display cervical layer structures, accurately analyze the infiltration of lesions or carcinomas and surrounding tissue conditions, and has high sensitivity.^{21,22}

The results of this study showed that the Doppler ultrasound blood flow parameters FI, VI, and VFI values in the observation group were significantly elevated in the observation group compared to the control group. As the severity of the lesions increased, the values of FI, VI, and VFI showed a corresponding rise, indicating the presence of neoangiogenesis at the lesion sites of CIN patients. This enhancement in blood flow perfusion correlates with the worsening of the lesions, consistent with findings from previous related studies.^{23–25} Pearson correlation analysis results showed that Netrin-1 was negatively correlated with FI, VI, and VFI values. Logistic multivariate analysis showed that Netrin-1 positivity was a protective factor for CIN grade III lesions, while FI, VI, and VFI were risk factors for CIN grade III lesions.

Moreover, this study preliminarily investigated the predictive value of Netrin-1 expression and Doppler ultrasound blood flow parameters for the severity of CIN. According to the results of clinical ROC curve analysis, an AUC greater than 0.7 indicates a certain predictive value, while an AUC greater than 0.85 suggests a higher predictive value. The findings revealed that the AUC for Netrin-1 was 0.732, with a sensitivity of 76.4% and a specificity of 79.5%, surpassing those of other indicators. This indicates that Netrin-1 expression possesses a significant predictive value for assessing the severity of CIN. Therefore, closely monitoring the dynamic changes in this marker is crucial for predicting and guiding timely clinical interventions.

It is important to acknowledge that, despite the positive findings regarding the relationship and predictive value of Netrin-1 expression and Doppler ultrasound blood flow parameters in assessing the severity of cervical intraepithelial neoplasia (CIN), this study has several limitations: 1) Small sample size: The relatively small sample size may restrict the reliability and generalizability of the findings. 2) Retrospective study design: The retrospective nature of this analysis may introduce information bias and issues related to incomplete data, making it difficult to rule out the influence of other potential confounding factors. 3) Failure to consider other relevant factors: Beyond Netrin-1 and Doppler ultrasound parameters, there are likely other factors that could impact CIN, such as viral infections (eg, high-risk HPV), genetic predispositions, and lifestyle factors (eg, smoking, sexual activity), all of which are known to influence the development and progression of CIN. Viral infections may interact with Netrin-1 expression, potentially modulating its role in disease progression. Genetic factors could predispose individuals to variations in Netrin-1 expression or alter vascular responses that can be measured by Doppler ultrasound. Additionally, lifestyle factors may affect blood flow parameters or influence the body's response to CIN, thereby indirectly impacting the outcomes measured in this study.

Although this study did not account for these variables, their potential impact on the results should be acknowledged. Future studies that include these factors could provide a more comprehensive understanding and strengthen the clinical applicability of Netrin-1 and Doppler ultrasound as predictive markers.

Conclusion

In summary, patients with CIN display low expression of Netrin-1 and high expression of Doppler ultrasound blood flow parameters FI, VI, and VFI—which are closely associated with the severity of the patient's condition. There is a negative correlation between Netrin-1 expression and the Doppler ultrasound parameters FI, VI, and VFI. Netrin-1 positivity serves as a protective factor for CIN grade III lesions, whereas elevated FI, VI, and VFI are considered risk factors for

these lesions. The expression levels of both Netrin-1 and the ultrasound parameters provide valuable predictive insights and guidance for early screening, diagnosis, treatment, and prevention of cervical cancer.

Funding

This study was supported by Research on the efficacy and optimal treatment parameters of ALA-PDT in the treatment of CINI associated with HPV infection, No. 2021013146.

Disclosure

The authors declare that they have no competing interests. This paper has been uploaded to Preprints as a preprint: <https://www.preprints.org/manuscript/202410.0907/v1>.

References

- Bowden SJ, Doulgeraki T, Bouras E, et al. Risk factors for human papillomavirus infection, cervical intraepithelial neoplasia and cervical cancer: an umbrella review and follow-up Mendelian randomisation studies. *BMC Med.* 2023;21(1):274. doi:10.1186/s12916-023-02965-w
- Chen Y, Qiu X, Wang W, et al. Human papillomavirus infection and cervical intraepithelial neoplasia progression are associated with increased vaginal microbiome diversity in a Chinese cohort. *BMC Infect Dis.* 2020;20(1):629. doi:10.1186/s12879-020-05324-9
- Cassier PA, Navaridas R, Bellina M, et al. Netrin-1 blockade inhibits tumour growth and EMT features in endometrial cancer. *Nature.* 2023;620(7973):409–416. doi:10.1038/s41586-023-06367-z
- Gao R, Peng X, Perry C, et al. Macrophage-derived netrin-1 drives adrenergic nerve-associated lung fibrosis. *J Clin Invest.* 2021;131(1). doi:10.1172/JCI136542
- Panova IE, Samkovich EV, Nechiporenko PA. [Doppler ultrasound in the assessment of blood supply to choroidal melanoma: parallels with contrast angiography and histography]. *Vestn Oftalmol.* 2023;139(1):27–34. Norwegian. doi:10.17116/ofitalma202313901127
- Sakuragi T, Shibata E, Kondo E, et al. Relationship between placental hemodynamics and placental histological analysis in third trimester. *J Obstet Gynaecol Res.* 2023;49(2):560–567. doi:10.1111/jog.15491
- Burness JV, Schroeder JM, Warren JB. Cervical colposcopy: indications and risk assessment. *Am Fam Physician.* 2020;102(1):39–48.
- Shroff S. Infectious vaginitis, cervicitis, and pelvic inflammatory disease. *Med Clin North Am.* 2023;107(2):299–315. doi:10.1016/j.mcna.2022.10.009
- Kalliala I, Athanasiou A, Veroniki AA, et al. Incidence and mortality from cervical cancer and other malignancies after treatment of cervical intraepithelial neoplasia: a systematic review and meta-analysis of the literature. *Ann Oncol.* 2020;31(2):213–227. doi:10.1016/j.annonc.2019.11.004
- Loopik DL, Bentley HA, Eijgenraam MN, et al. The natural history of cervical intraepithelial neoplasia grades 1, 2, and 3: a systematic review and meta-analysis. *J Low Genit Tract Dis.* 2021;25(3):221–231. doi:10.1097/LGT.0000000000000604
- Soler M, Masch R, Saidu R, Cremer M. Thermal ablation treatment for cervical precancer (Cervical intraepithelial neoplasia grade 2 or higher [CIN2+]). *Methods Mol Biol.* 2022;2394:867–882.
- Luo Y, Liao S, Yu J. Netrin-1 in post-stroke neuroprotection: beyond axon guidance cue. *Curr Neuropharmacol.* 2022;20(10):1879–1887. doi:10.2174/1570159X20666220302150723
- Ziegon L, Schlegel M. Netrin-1: a modulator of macrophage driven acute and chronic inflammation. *Int J Mol Sci.* 2021;23(1):275. doi:10.3390/ijms23010275
- Claro V, Ferro A. Netrin-1: focus on its role in cardiovascular physiology and atherosclerosis. *JRSM Cardiovasc Dis.* 2020;9:2048004020959574. doi:10.1177/2048004020959574
- Vásquez X, Sánchez-Gómez P, Palma V. Netrin-1 in glioblastoma neovascularization: the new partner in crime? *Int J Mol Sci.* 2021;22(15):8248. doi:10.3390/ijms22158248
- Bellina M, Bernet A. [Netrin-1, a novel antitumoral target]. *Med Sci.* 2022;38(4):351–358. Norwegian
- Lu X, Xu G, Lin Z, et al. Engineered exosomes enriched in netrin-1 modRNA promote axonal growth in spinal cord injury by attenuating inflammation and pyroptosis. *Biomater Res.* 2023;27(1):3. doi:10.1186/s40824-023-00339-0
- Li J, Gu C, Zheng H, et al. Ultrasonographic diagnosis in rare primary cervical cancer. *Int J Gynecol Cancer.* 2021;31(12):1535–1540. doi:10.1136/ijgc-2021-002860
- Zhang P, Zhou Q, Zeng Z. Combination of serum FOXR2 and transvaginal three-dimensional power Doppler ultrasonography in the diagnosis of uterine lesions. *Adv Clin Exp Med.* 2023.
- Wang Y, Liang L, Liu Y, et al. The application value of three-dimensional power Doppler ultrasound in fetal growth restriction. *Evid Based Complement Alternat Med.* 2022;2022:4087406. doi:10.1155/2022/4087406
- Saidman JM, Bertoni V, Demeco CM, et al. Importance of Doppler ultrasound in vaginal foreign body: case report and review of the literature. *J Ultrasound.* 2022;25(2):409–412. doi:10.1007/s40477-021-00596-6
- Pozzati F, Moro F, Leombroni M, et al. Clinical and ultrasound characteristics of vaginal lesions. *Int J Gynecol Cancer.* 2021;31(1):45–51. doi:10.1136/ijgc-2020-001651
- Nam M, Seo S-S, Jung S, et al. Comparable plasma lipid changes in patients with high-grade cervical intraepithelial neoplasia and patients with cervical cancer. *J Proteome Res.* 2021;20(1):740–750. doi:10.1021/acs.jproteome.0c00640
- Quirke T, Sleator RD. A beginner's guide to genomics in complex neurological disorders. *Innov Discov.* 2024;1(4):29. doi:10.53964/id.2024029
- Zortul S, Cayir Y. Receiving preconception care status of pregnant women and related factors. *J Mod Nurs Pract Res.* 2023;3(2):6. doi:10.53964/jmnp.2023006

International Journal of Women's Health

Publish your work in this journal

The International Journal of Women's Health is an international, peer-reviewed open-access journal publishing original research, reports, editorials, reviews and commentaries on all aspects of women's healthcare including gynecology, obstetrics, and breast cancer. The manuscript management system is completely online and includes a very quick and fair peer-review system, which is all easy to use. Visit <http://www.dovepress.com/testimonials.php> to read real quotes from published authors.

Submit your manuscript here: <https://www.dovepress.com/international-journal-of-womens-health-journal>

Dovepress
Taylor & Francis Group