


Bilateral Reversible Corneal Edema as a Novel Side-Effect of Levetiracetam – A Case Report

Kimberly Caruana ^{*}, Matthew Ellul^{*}, Andre Grixti^{*}

Department of Ophthalmology, Mater Dei Hospital, Imsida, MSD, 2090, Malta

^{*}These authors contributed equally to this work

Correspondence: Kimberly Caruana, Ophthalmology Outpatients, Mater Dei Hospital, Imsida, MSD, 2090, Malta, Email kimberly.caruana27@gmail.com

Purpose: We present a case of levetiracetam-induced corneal edema. To the best of our knowledge, this is the first documented case of bilateral reversible corneal edema secondary to levetiracetam use.

Patients and Methods: A 59-year-old woman was referred to the ophthalmology department with a few weeks' history of bilateral blurring of vision. She is a known case of secondary progressive multiple sclerosis, and she was started on levetiracetam by her neurologist a few weeks prior to referral in view of new seizure activity. Examination revealed bilateral clinically evident corneal edema, which was documented on corneal topography.

Results: Upon levetiracetam dose reduction, symptoms started to improve and eventually the medication was stopped altogether. The patient's vision and corneal edema normalized on follow-up.

Conclusion: This novel side effect should be kept in mind when a patient who is on levetiracetam presents with corneal edema as this can avoid misdiagnosis and unnecessary interventions.

Keywords: blurred vision, corneal thickening, multiple sclerosis

Introduction

We present a case of levetiracetam-induced corneal edema. To the best of our knowledge, this is the first documented case of this medication side-effect. Levetiracetam is an anti-epileptic medication that is used both as monotherapy in the treatment of focal epilepsy and as an add-on agent for complex or generalised epilepsy. Its mechanism of action is still not completely understood. One of its modes of action is mediated via adherence to synaptic vesicle 2A. This mediates calcium-dependent neurotransmitter release.^{1,2}

Case Report/Case Presentation

We present a case of a 59-year-old lady with a twelve-year history of secondary progressive multiple sclerosis who was referred to ophthalmology with a few weeks' history of bilateral blurring of vision.

The patient had no past ophthalmic history and no drug history other than the anti-epileptic medications related to her multiple sclerosis. Previously documented ophthalmic examinations did not reveal any signs of Fuchs' endothelial corneal dystrophy, and the patient has no family history of corneal pathology.

The patient had been on amantadine therapy at a dose of 100mg twice daily for the past 7 years and was started on levetiracetam 250mg twice daily as an add-on agent. Visual deterioration was experienced shortly after commencement of levetiracetam therapy for a breakthrough seizure.

On examination, the patient's best corrected visual acuity was 0.5 logMAR right eye and 0.5 logMAR left eye. Slit-lamp examination revealed corneal edema (shown in [Figure 1](#)) involving both eyes and absence of uveitis. Corrected intraocular pressures were 16mmHg right eye and 18mmHg left eye. Corneal topography was performed which

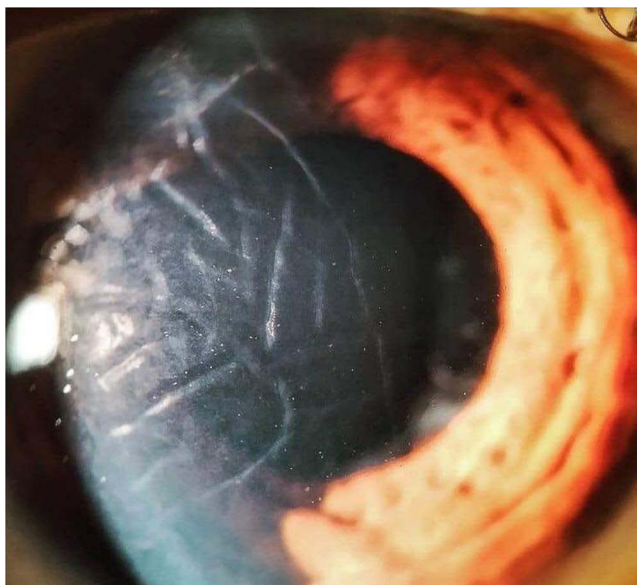


Figure 1 Right corneal picture showing corneal oedema with descemet membrane folds. Patient on levetiracetam.

confirmed bilateral significant corneal thickening with a right central corneal thickness of $936\mu\text{m}$ and left central corneal thickness of $1134\mu\text{m}$ (shown in [Figure 2](#)). The rest of the eye examination was normal.

Since amantadine is a known cause of corneal edema,^{3,4} it was agreed with the patient and her caring neurologist to switch from amantadine to lamotrigine. Levetiracetam therapy was continued at this stage. No improvement in vision was noted two months after this change in treatment. The patient expressed the wish to temporarily stop levetiracetam on a trial basis in view of the direct temporal association between the onset of symptoms and the commencement of the medication.

Amantadine was re-introduced, while levetiracetam dose was tapered. Improvement in vision was noted a few days after levetiracetam dose reduction. Levetiracetam was stopped altogether, and the patient remained on amantadine and lamotrigine. A provisional diagnosis of levetiracetam-induced corneal edema was made at this stage. Her vision normalized and repeat corneal topography six months after stopping the levetiracetam showed a right central corneal thickness of $567\mu\text{m}$ and a left central corneal thickness of $573\mu\text{m}$, (shown in [Figure 3](#)) and a visual acuity of 0.2 logMAR both eyes. Slit-lamp examination confirmed clear cornea and the absence of corneal guttata in either eye (shown in [Figure 4](#)).

The patient was examined again thirteen months after the first presentation. No further changes in her medications were made, and her vision had remained stable at 0.2 logMAR in both eyes. Repeat corneal topography showed no further changes.

Discussion

The primary function of corneal endothelium (CEN) is maintenance of constant corneal thickness and transparency. This is achieved via tight junctions that form a barrier to diffusion of electrolytes and water from the anterior chamber across the CEN to the corneal stroma, and via active transport of electrolytes (and passive flow of water) from the corneal stroma to the anterior chamber.⁵

It has been shown in different corneal models (bovine, rabbit and human) that calcium is involved in endothelial regulation of ion and fluid transport.⁶ Exposure to a hypotonic environment triggers cells to perform a regulatory volume decrease, which is mediated via calcium release from intracellular stores. On the other hand, perfusion with a calcium-free medium results in disruption of endothelial tight junctions, resulting in loss of barrier function with consequent corneal edema.⁵

Since some calcium channel blockers influence corneal endothelial calcium levels, these agents have been used experimentally to elucidate corneal function. While some agents clearly diminish corneal endothelial function and may

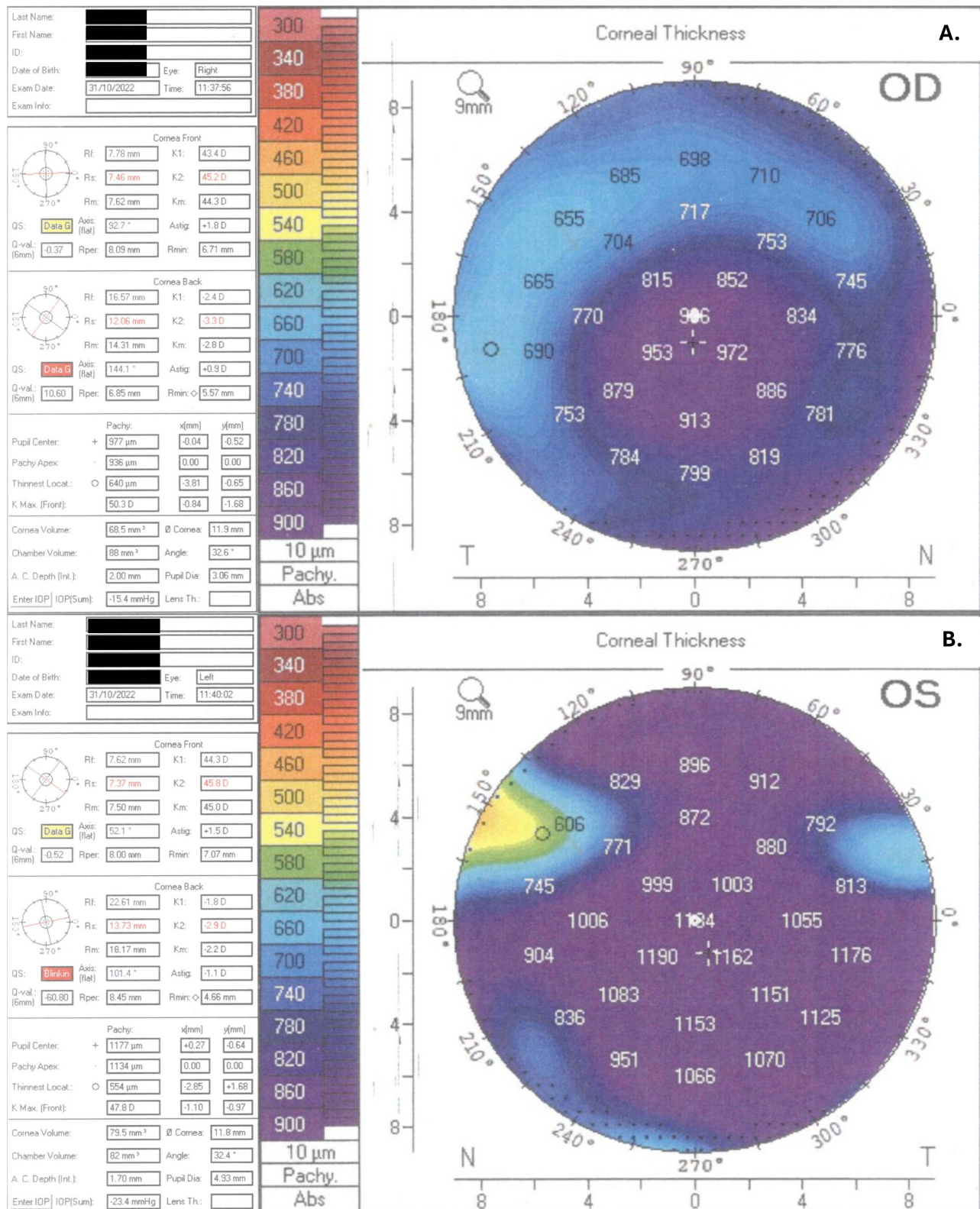


Figure 2 Corneal topography of the patient on levetiracetam treatment showing generalised increased corneal thickness. **(A)** Corneal topography right eye showing right apical thickness of 936µm **(B)** Corneal topography left eye showing left apical thickness of 1134µm.

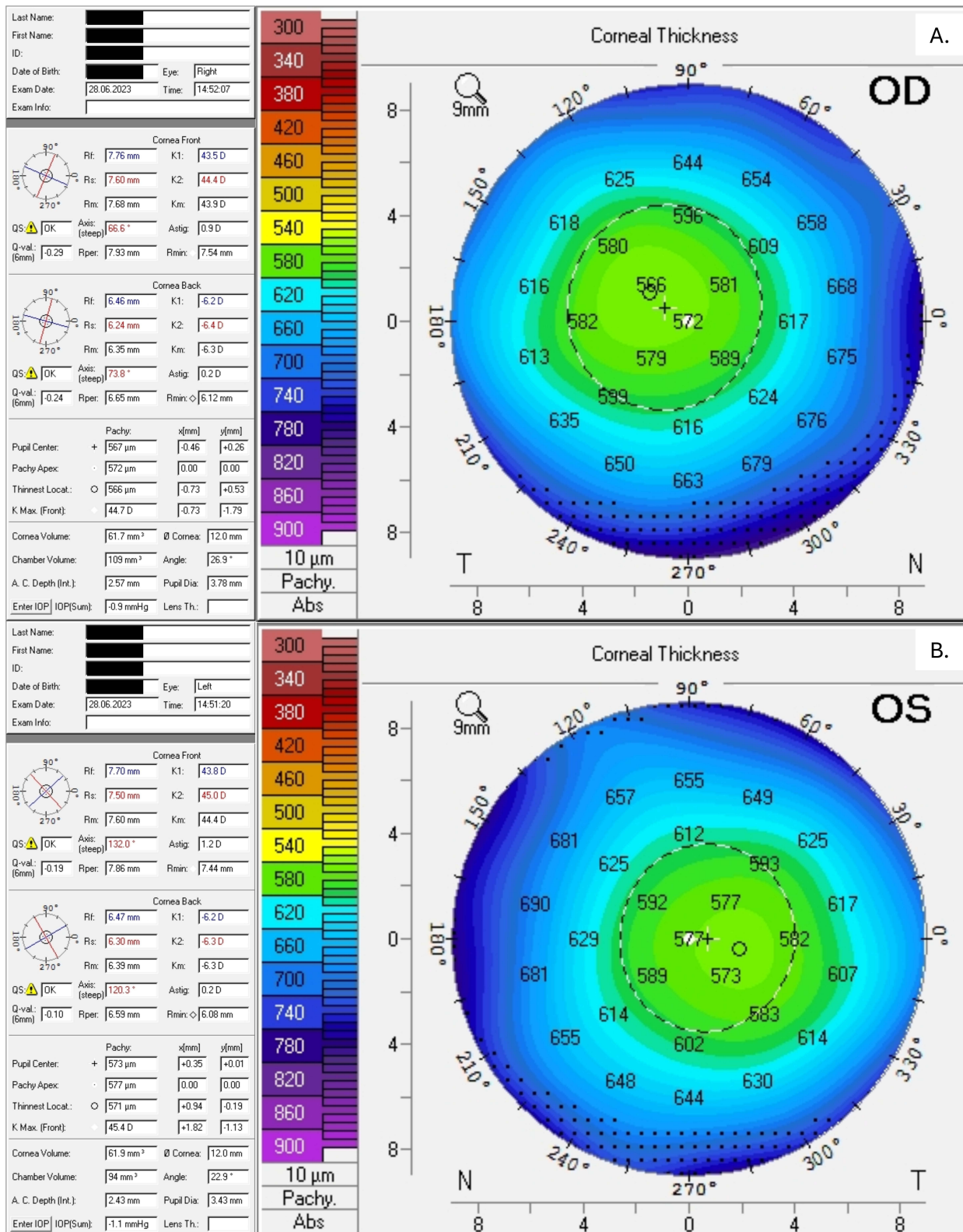


Figure 3 Corneal Topography of patient off levetiracetam treatment showing normal corneal thickness. (A) Corneal topography right eye showing right apical corneal thickness of 572µ (B) Corneal topography left eye showing left apical corneal thickness of 577µ.

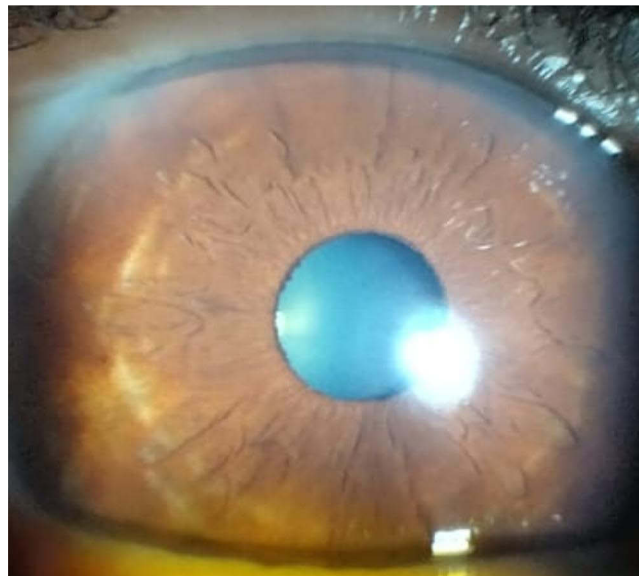


Figure 4 Right corneal picture showing clear cornea. Patient off levetiracetam.

consequently cause corneal edema (for example, nifedipine and diltiazem), other calcium channel blockers have no effect on the corneal endothelium. These results suggest that L-type calcium channels are the type predominantly expressed in corneal endothelial cells.⁵

In this case, the two drugs of interest were amantadine and levetiracetam. There are documented cases of amantadine-associated corneal endothelial cell dysfunction with resultant cornea edema^{3,4} in the literature and, therefore, amantadine was stopped first. The patient's symptoms did not improve after stopping this medication. Since the patient started experiencing blurred vision shortly after starting levetiracetam, amantadine was re-started and she underwent a levetiracetam cessation trial, which resulted in resolution of her symptoms and reversal of her corneal edema. The exact time interval between the initiation of levetiracetam and the development of corneal oedema cannot be accurately ascertained since the patient presented for an ophthalmic consultation after having been symptomatic for a few weeks. However, her symptoms improved within days of stopping the levetiracetam.

The temporal correlation between the initiation and cessation of levetiracetam treatment, the onset and resolution of symptoms, and the clinical and topographic corneal findings points towards a direct association between corneal edema and levetiracetam use.

Levetiracetam is a newer generation anti-epileptic agent with high bioavailability. It is excreted unchanged in the kidneys with no effect on the cytochrome P450 enzyme system and therefore has very low interaction with other medications.^{7,8} For these reasons, its use in seizure control is increasing, both as a sole agent and as an add-on medication.⁷

While the mechanisms of action of levetiracetam are incompletely understood, it has been shown that one mechanism of action of levetiracetam is inhibition of N, P and L-type calcium channels in the brain, which results in reduced calcium release from intracellular stores and consequently reduced intracellular calcium levels.⁷ Given the key roles played by calcium in corneal endothelial physiology, this mechanism of action of levetiracetam is a plausible mechanism, which can explain the corneal side-effect experienced by our patient when the medication was used. Specular microscopy of the patient, performed after resolution of her corneal edema showed a right corneal endothelial cell count of 1357 cells/mm² and a left corneal endothelial cell count of 1299 cells/mm² (endothelial cell count normal range: 1500–3500 cells/mm²). Taking into consideration the low corneal endothelial cell count, our patient may have been at higher predisposition to medication-induced corneal edema than patients with normal endothelial cell counts. Moreover, other factors, such as genetic variables cannot be excluded in this case.

Conclusion

This case is of value as it is the first documented case of corneal edema that was associated with levetiracetam use. Awareness of this side-effect is vital to avoid misdiagnosis and unnecessary interventions. Corneal transplant surgery, with all its associated risks, was being considered in this case since primary corneal failure was the main differential diagnosis.

Abbreviations

CEN, corneal endothelium.

Ethical Statement

Institutional ethical approval was not required for publication.

Informed consent

Patient's verbal and written consent was obtained to publish this data. Any person identifying information was not included.

Funding

This study was not supported by any sponsor or funder.

Disclosure

The authors declare no conflict of interest or financial support.

References

1. Hakami T. Neuropharmacology of Antiseizure Drugs. *Neuropsychopharm Rep.* 2021;41(3):336–351. doi:10.1002/npr2.12196
2. Hilgers A, Schaefer M. Systematic Adverse Drug Reaction Monitoring of Patients Under Newer Antiepileptic Drugs Using Routine Clinical Data of Inpatients. *Drug Real World Outco.* 2016;3(2):209–221. doi:10.1007/s40801-016-0077-2
3. Cennamo M, Dragotto F, Favuzza E, Morelli A, Mencucci R. Amantadine therapy for Parkinson's Disease: in Vivo Confocal Microscopy corneal findings, case report and revision of literature. *BMC Ophthalmol.* 2022;22(1):10.1186/s12886-022-02410-1. doi:10.1186/s12886-022-02410-1
4. Ching Lin C, Yin Cheng C, Pei Shin H, Ching Lin C, Liang Hsu S. Amantadine-related corneal edema and endothelial cell loss: four case reports. *Taiwan J Ophthalmol.* 2014;4(3):137–140. doi:10.1016/j.tjo.2014.04.003
5. Kraus D, Kaiserman I, Frucht-Pery J, Rahamimoff R. Calcium—an “all- round player” in the cornea. *Israel Med Ass J.* 3(4):269–274.
6. Green K, Cheeks L, David SH. Effects of calcium channel blockers on rabbit corneal endothelial function. *Current Eye Res.* 13(6):401–408. doi:10.3109/02713689408999867
7. Contreras-García IJ, Cárdenas-Rodríguez N, Romo-Mancillas A, et al. Levetiracetam Mechanisms of Action: from Molecules to Systems. *Pharmaceutica.* 2022;15(4):475. doi:10.3390/ph15040475
8. Wright C, Downing J, Mungall D, et al. Clinical pharmacology and pharmacokinetics of levetiracetam. *Front Neurol.* 2013;4:192. PMID: 24363651. doi:10.3389/fneur.2013.00192

International Medical Case Reports Journal

Dovepress

Publish your work in this journal

The International Medical Case Reports Journal is an international, peer-reviewed open-access journal publishing original case reports from all medical specialties. Previously unpublished medical posters are also accepted relating to any area of clinical or preclinical science. Submissions should not normally exceed 2,000 words or 4 published pages including figures, diagrams and references. The manuscript management system is completely online and includes a very quick and fair peer-review system, which is all easy to use. Visit <http://www.dovepress.com/testimonials.php> to read real quotes from published authors.

Submit your manuscript here: <https://www.dovepress.com/international-medical-case-reports-journal-journal>