

Combination Therapy with Baricitinib and Narrowband Ultraviolet B for Active Non-Segmental Vitiligo: A Retrospective Controlled Study

Bin Zhou^{1,2}, Jiachen Gui^{2,3}, Tao Wang^{2,4}, Zhimin Li², Wenzhi Hu⁵, Yue Zhang², Qiang Li²

¹Graduate School, Hebei North University, Zhangjiakou, People's Republic of China; ²Department of Dermatology, Air Force Medical Center, PLA, Beijing, People's Republic of China; ³Air Force Medical University, Xi'an, Shaanxi, People's Republic of China; ⁴Department of Dermatology, West China Hospital, Sichuan University, Chengdu, People's Republic of China; ⁵Department of Burn and Plastic Surgery, the Air Force Medical Center of Air, Force Military Medical University of Chinese PLA, Beijing, People's Republic of China

Correspondence: Qiang Li, Department of Dermatology, Air Force Medical Center, PLA, Beijing, 100142, People's Republic of China, Email 16585260@qq.com

Background: Vitiligo is a chronic autoimmune disease manifested by depigmented patches of skin devoid of melanocytes. Baricitinib, a JAK inhibitor selectively targeting JAK1/2, has shown preliminary efficacy for vitiligo. We aimed to assess the efficacy and tolerability of combination therapy with baricitinib and narrowband UV-B (NB-UVB) to treat active nonsegmental vitiligo (NSV).

Methods: We formed a combination group of 52 patients with NSV receiving baricitinib and NB-UVB irradiation, and a control group of 49 patients with NSV receiving oral mini-pulse (OMP) methylprednisolone and NB-UVB irradiation. Efficacy analysis was conducted for the 6-month period. Six months after the last treatment, the recurrence rates were investigated through follow-up.

Results: From the first month, the mean total vitiligo area scoring index (VASI) score was significantly reduced in the combination group when compared to that in the control group. Starting on the fourth month, the overall response rates (ORRs) were significantly higher in the combination group than in the control group ($P=0.034$). By the sixth month, the ORRs reached 86.5% in the combination group, whereas they reached 67.3% in the control group ($P=0.022$). The serum levels of IFN- γ and CXCL10 in the combination group decreased from 38.52 ± 5.98 pg/mL and 976.67 ± 150.57 pg/mL at baseline to 26.46 ± 5.93 pg/mL and 704.14 ± 103.38 pg/mL at the 6-month juncture, respectively ($P<0.001$). Moreover, we found that there was no significant difference in recurrence rates within 6 months after stopping treatment in both groups. Three patients (5.8%) in the combination group reported developing itchy skin during the first month of treatment period, and one patient (1.9%) developed erythema; no other serious adverse events occurred.

Conclusion: Our observations suggest that the combination therapy with baricitinib and NB-UVB is a promising strategy against NSV. Patients tolerated the treatment well without serious AEs, these results expand treatment options for vitiligo patients, warranting larger clinical trials.

Keywords: autoimmune disease, re-pigmentation, efficacy, assessment, safety

Introduction

Vitiligo is an acquired, chronic autoimmune disease manifested by depigmented patches of skin and hair due to the loss of melanocytes, the condition affects 0.5–2% of the global population.^{1–3} However, vitiligo is more than a cosmetic problem, the disease can be mentally distressing and significantly impact daily life.^{4,5} The main goals of medical management are to halt the disease activity through immunomodulation and to achieve re-pigmentation by stimulating the proliferation and migration of follicular reservoir melanocytes, as well as epidermal melanocytes from nearby healthy skin.⁶

The pathogenesis of vitiligo involves the infiltration of affected areas by activated melanocyte antigen-specific CD8⁺ T cells that drive cytotoxicity and disease progression.¹ CD8⁺ T cell-produced interferon- γ (IFN- γ) can activate the Janus kinase (JAK) pathway by binding to a cell surface receptor composed of two subunits (IFNGR1 and IFNGR2), which are linked to JAK1 and JAK2, respectively. IFN- γ mediates the recruitment of autoimmune CD8⁺ T cells to melanocytes via

the IFN γ -induced C-X-C motif chemokines, CXCL9 and CXCL10, which are regulated by the JAK 1 and JAK 2 signaling pathways, respectively.⁷ Therefore, IFN- γ , CXCL9, and CXCL10 are considered biomarkers of vitiligo activity, clinical research have reported that patients with vitiligo present higher levels of them than healthy individuals.^{8,9}

JAK inhibitors (JAKi) block IFN- γ signaling and suppress the release of inflammatory cytokines, they are treatment options for multiple dermatological diseases such as atopic dermatitis, alopecia areata, psoriasis, and vitiligo.^{10–13} Baricitinib is an inhibitor targeting JAK1 and JAK2, it induces melanocyte regeneration by blocking IFN- γ signaling and reducing T-cell numbers in skin lesions, preliminary studies have demonstrated the drug's efficacy against vitiligo.^{14,15} The combination of narrowband ultraviolet B (NB-UVB) irradiation and JAKi, both of which suppress inflammatory responses and stimulate melanocyte regeneration, has been reported to be more effective than NB-UVB therapy alone for treating vitiligo.¹⁶ UV irradiation may actually enhance the efficacy of JAKi against vitiligo without increasing the cancer risk, therefore, the administration of such a combination therapy may diminish inflammation and facilitate endogenous repigmentation.¹⁶

The studies on combination therapy with baricitinib and NB-UVB for vitiligo remain scarce. We conducted this retrospective study to evaluate the efficacy and tolerability of combining baricitinib with NB-UVB therapy in patients with active non-segmental vitiligo (NSV) over a six-month period.

Materials and Methods

Patients

We conducted this study by reviewing the clinical records of patients with vitiligo treated at the Dermatology department of our hospital between February 2020 and December 2022. The vitiligo diagnosis criteria for this study were based on the standard guidelines of the British Association of Dermatologists.¹⁷ According to the guideline, examining physicians should note whether the white macules or patches have blurred boundaries to assess disease progression.

Figure 1 shows the study's flow-chart. We screened the records of 620 patients with vitiligo, 459 patients were diagnosed as having active NSV. Unfortunately, the coronavirus (COVID-19) pandemic started during the treatment period and disrupted the follow-ups due to China's strict epidemic control policies. We finally found data for 52 patients

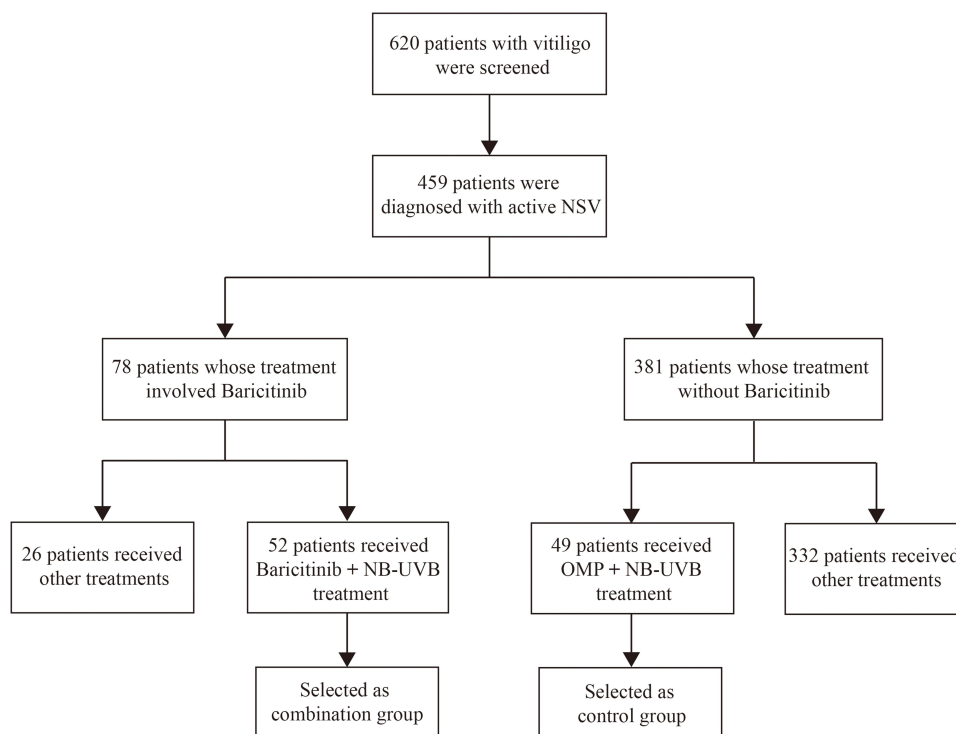


Figure 1 Patients inclusion flow-chart.

who received combination therapy with baricitinib and NB-UVB for six consecutive months. These patients had received at least another treatment including phototherapy, Chinese herbs, or systemic or topical drugs, but they were not satisfied with the results of those treatments. Additionally, we selected data from 49 patients with active NSV treated with methylprednisolone oral mini-pulse (OMP) therapy combined with NB-UVB as the control group. In addition, due to the Covid pandemic restrictions were eased we were able to assess the recurrence rate among these patients 6 months after the last treatment, we defined recurrence as the reappearance or expansion of white patches after the end of the last treatment. We solicited participants or their guardians for consent to utilize their clinical data for research prior to beginning the study, guaranteeing confidentiality of the clinical data and non-disclosure of personal information. All participants or their guardians signed informed consent forms.

Inclusion criteria:

1. Patients diagnosed as having active NSV before the treatment, NSV was identified in individuals with new skin lesions or enlargement of original lesions within the previous six months.
2. Individuals of any gender, skin type, duration of disease, and VASI scores.
3. Individuals older than 18 years.

Exclusion criteria:

1. Use of any therapy for vitiligo within the four weeks prior to the baseline data collection.
2. Patients with infectious or liver diseases, malignancy, hematological abnormalities, or other autoimmune diseases, as well as pregnant or lactating women, and anticoagulant users.

Therapeutic Protocol

Patients in the combination group received oral baricitinib tablets (2 mg twice a day; LillydelCaribe, United States) with NB-UVB light therapy (Shanghai SIGMA Hi-tech). Patients in the control group were administered oral methylprednisolone tablets (0.5 mg/kg per week on two consecutive days; Medrol[®], Pfizer Pharmaceuticals, Localita Marino del Tronto, Italy) combined with NB-UVB therapy.¹⁸

The phototherapy protocols were identical in both groups. NB-UVB was administered three times per week according to the recommendation of the Vitiligo Working Group consensus guidelines.¹⁹ The initial dose of NB-UVB was 200 mJ/cm², with subsequent adjustment increases by 10% to 20%, the maximum dose did not exceed a ceiling of 3000 mJ/cm². During the course of treatment, NB-UVB was paused whenever symptomatic erythema appeared and resumed once the erythema subsided, with the dose adjusted to a tolerable level for patients.

Treatment Assessment

We obtained patient baseline data from clinical records. The severity of vitiligo was assessed using vitiligo area scoring index (VASI) scores calculated by multiplying the depigmentation area in hand units (set at 1% per unit) by the extent of depigmentation within each hand unit-measured patch, the sum of the VASI scores of all regions determined the overall VASI score.²⁰ The improvement of lesions was graded as mild (<25%), moderate (25%–50%), good (51%–75%), or excellent (76%–100%). We defined overall response rates (ORRs) as the total percentage of patients who achieved good and excellent level responses. We conducted efficacy analyses monthly during the 6-month treatment period.

Laboratory testing included complete blood counts, serum levels of IFN- γ and CXCL10, liver and kidney function tests, blood glucose and lipid measurements were taken prior to initiating treatments and during each follow-up. Adverse events (AEs) were reported by patients throughout the treatment.

Statistical Analysis

Data analysis was performed using IBM SPSS software version 26 (SPSS Inc, Chicago, IL, USA). Graphs were made using GraphPad Prism 9.5 (GraphPad Software, San Diego, CA). According to the characteristics of research samples, classified variables are expressed as quantity and percentage, and numerical variables are expressed as mean \pm standard

deviation. The chi-square test was used for qualitative variables. Mann–Whitney *U*-test was used for quantitative variables. Spearman correlation is used to test the correlation between the degree of improvement and the baseline data. We considered *P* values lower than 0.05 as representing statistically significant differences.

Results

Table 1 shows the baseline characteristics of the patients in the two groups. All patients had active NSV with skin types III–IV, the mean ages were 25.23 years (SD 7.95, ranging from 18 to 59 years) in the combination group and 26.78 years (SD 9.01, 18 to 61 years) in the control group. The mean disease durations were 2.94 years (SD 3.55, 0.1 to 15 years) in the combination group and 2.58 years (SD 3.08, 0.2 to 12 years) in the control group. The baseline data on gender, age, disease durations, skin types, and VASI scores were no significant differences between the two groups.

Table 2 shows the improvement in total VASI scores in both groups, we found significant differences at the first ($P=0.024$), second ($P=0.006$), third ($P<0.001$), fourth ($P=0.003$), fifth ($P=0.021$), and sixth ($P=0.042$) months. **Table 3** further shows the VASI score improvements at each location, no significant differences were observed on the trunk, face and neck at month 1 and 2 between the two groups, however, the improvement in VASI was significantly better in the combination group starting on the third month of treatment. The VASI improvement on extremities' lesions was significantly better at the 4th ($P=0.049$), 5th ($P=0.027$), and 6th ($P=0.033$) months in the combination group than in the control group. In addition, no significant differences were observed in VASI on the acral lesions in the two groups throughout the six-month treatment. **Figure 2** depicts the dynamic VASI score changes throughout the 6-month period.

The number of patients with different degree of improvement between the two groups is shown in **Table 4**, during the 6-month period of treatment, there were no statistical significance was observed in both groups, **Figure 3** visually illustrates the proportion of improvement between the two groups. We further analyzed the ORRs variations between the two groups (**Figure 4**), the outcome between the two groups were similar during the first ($P=0.166$), second ($P=0.912$) and third ($P=0.638$) months. However, by the fourth month, the ORRs were significantly higher in the combination group (29 patients, 55.8%) than in the control group (17 patients, 34.7%). In the fifth month, the ORRs were 69.3% in the combination group

Table 1 Baseline Characteristics of Individuals Between the NB-Baricitinib and NB-OMP Groups

Characteristic	Group		P
	Combination (n=52)	Control (n=49)	
Gender, n (%)			
Male	23 (44.2)	18 (36.7)	0.443
Female	29 (55.8)	31 (63.3)	
Age, mean ± SD (years)	25.23 ± 7.95	26.78 ± 9.01	0.183
Disease duration, mean ± SD (years)	2.94 ± 3.55	2.58 ± 3.08	0.989
Skin type [#] , n (%)			
III	44 (84.6)	40 (81.6)	0.689
IV	8 (15.4)	9 (18.4)	
VASI, mean ± SD	2.67 ± 3.04	2.89 ± 2.24	0.069
Historical therapy, n (%)			
Phototherapy	28 (53.8)	17 (34.7)	
Chinese herbs	19 (36.5)	22 (44.9)	
Topical corticosteroids	21 (40.4)	16 (32.7)	
Calcineurin inhibitors	15 (28.8)	8 (16.3)	

Note: *P*-values <0.05 considered as statistically significant.

Abbreviations: VASI, Vitiligo area scoring index; SD, standard deviation. #: Fitzpatrick's skin photo-type.

Table 2 Changes in Total VASI Scores Between the Two Groups

Group	Month, mean \pm SD					
	1	2	3	4	5	6
Control	2.62 \pm 2.04	2.34 \pm 1.87	2.11 \pm 1.76	1.86 \pm 1.57	1.45 \pm 1.29	1.31 \pm 1.25
Combination	2.37 \pm 3.03	1.93 \pm 2.44	1.47 \pm 1.97	1.35 \pm 1.68	1.20 \pm 1.56	1.11 \pm 1.47
P	0.024*	0.006*	<0.001*	0.003*	0.021*	0.042*

Note: P-values <0.05 considered as statistically significant. *P < 0.05.

Abbreviations: VASI, Vitiligo area scoring index; SD, standard deviation.

Table 3 Changes in VASI Scores at Each Lesion Site in the Two Groups

Month	Group	Face and Neck, Mean \pm SD	P	Trunk, Mean \pm SD	P	Extremities, Mean \pm SD	P	Acral, Mean \pm SD	P
Prior to treatment	Control	1.33 \pm 0.49	0.224	1.91 \pm 1.05	0.613	1.89 \pm 1.63	0.423	1.15 \pm 0.48	0.913
	Combination	1.27 \pm 0.90		1.82 \pm 1.18		1.61 \pm 1.55			
1	Control	1.08 \pm 0.45	0.160	1.66 \pm 0.96	0.631	1.68 \pm 1.51	0.315	1.12 \pm 0.47	0.896
	Combination	1.03 \pm 0.94		1.61 \pm 1.20		1.45 \pm 1.58			
2	Control	0.93 \pm 0.40	0.059	1.49 \pm 0.92	0.220	1.48 \pm 1.38	0.213	1.04 \pm 0.45	0.793
	Combination	0.81 \pm 0.78		1.24 \pm 0.98		1.15 \pm 1.25			
3	Control	0.82 \pm 0.36	0.001*	1.35 \pm 0.85	0.037*	1.28 \pm 1.25	0.073	0.95 \pm 0.42	0.930
	Combination	0.55 \pm 0.61		0.92 \pm 0.82		0.87 \pm 1.04			
4	Control	0.67 \pm 0.32	0.034*	1.30 \pm 0.77	0.030*	1.26 \pm 1.19	0.049*	1.00 \pm 0.46	0.640
	Combination	0.54 \pm 0.53		0.83 \pm 0.61		0.69 \pm 0.64			
5	Control	0.60 \pm 0.27	0.024*	1.16 \pm 0.70	0.020*	1.17 \pm 1.12	0.027*	0.97 \pm 0.45	0.351
	Combination	0.46 \pm 0.47		0.71 \pm 0.51		0.61 \pm 0.56			
6	Control	0.50 \pm 0.22	0.010*	1.04 \pm 0.65	0.016*	1.07 \pm 1.04	0.033*	0.92 \pm 0.45	0.203
	Combination	0.38 \pm 0.44		0.60 \pm 0.40		0.56 \pm 0.55			

Note: P-values <0.05 considered as statistically significant. *P < 0.05.

Abbreviations: VASI, Vitiligo area scoring index; SD, standard deviation.

and 47.0% in the control group ($P=0.023$). By the sixth month, the ORRs increased to 86.5% in the combination group and 67.3% in the control group ($P=0.022$). In terms of the correlation between the degree of improvement and demographic characteristics, we found no significant associations for gender, age, disease duration, skin types, or VASI scores (Table 5). Moreover, six months after the last treatment, all patients were accepted for evaluation of vitiligo recurrences, the results revealed that there was no significant difference in recurrence rates in both groups (Table 6).

We compared the changes in serum levels of IFN- γ and CXCL10 before and after treatment, the results shows that the levels of IFN- γ and CXCL10 in the combination group decreased from 38.52 \pm 5.98 pg/mL and 976.67 \pm 150.57 pg/mL at baseline to 26.46 \pm 5.93 pg/mL and 704.14 \pm 103.38 pg/mL at the 6-month juncture ($P<0.001$), respectively (Table 7). In contrast, no significant decrease in serum levels of IFN- γ and CXCL10 were observed in the control group.

In the context of the occurrence of treatment-emergent AEs, three patients (5.8%) in the combination group and two (4.1%) in the control group reported the development of itchy skin during the first month of treatment, another patient (1.9%) in the combination group developed erythema, and one patient (2.0%) in the control group reported development of burning pain in the skin intervened by phototherapy after the first treatment. Notably, all these reported symptoms were mild and they disappeared spontaneously after 2 to 5 days. Thus, all the patients completed their treatments. Moreover, we found no clinically significant changes in laboratory values including complete blood counts, liver and kidney function tests, or blood glucose and blood lipid measurements before and after treatment in either group.

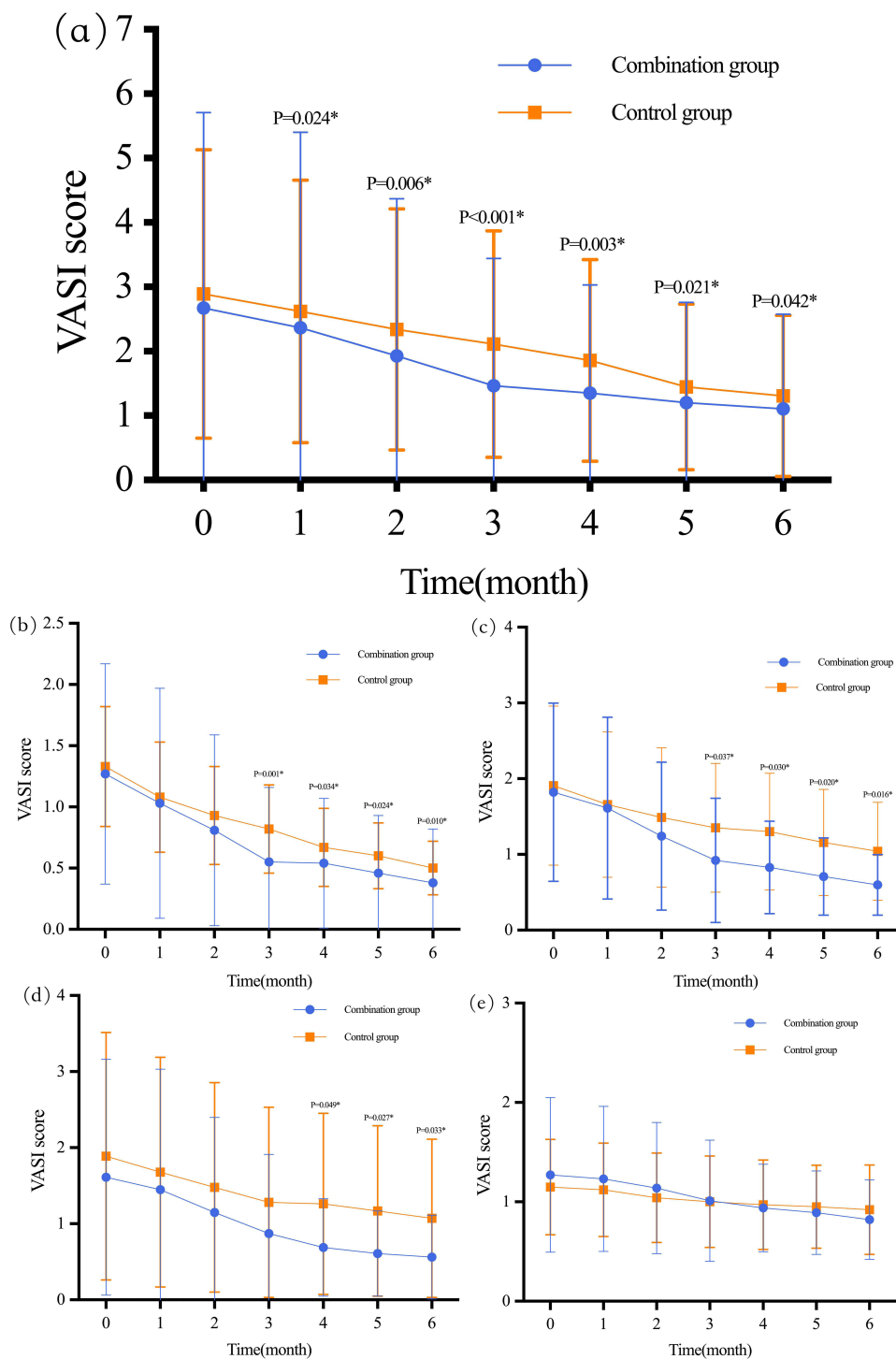


Figure 2 VASI score variations in the two groups. **(a)** Changes in total VASI score; **(b)** Changes in VASI scores of face and neck lesions; **(c)** Changes in VASI scores on trunk lesions; **(d)** Changes in VASI scores on extremities lesions; **(e)** Changes in VASI scores on acral lesions. VASI, Vitiligo area scoring index. *P*-values <0.05 considered as statistically significant. **P* < 0.05.

Discussion

Given that vitiligo is an autoimmune disease, oral mini-pulse steroids (OMP) have been explored as a promising treatment strategy due to their safety and efficacy, with the aim of halting the disease progression via therapeutic immunosuppression.²¹ Studies have shown the enhanced effects of combining OMP with NB-UVB therapy to facilitate

Table 4 Numbers of Patients with Different Degrees of Lesion Improvement in the Two Groups

Month	Group	Degree (%)					P
		None	Mild	Moderate	Good	Excellent	
1	Control	21 (42.9)	24 (49.0)	4 (8.1)	0	0	0.129
	Combination	15 (28.8)	29 (55.8)	6 (11.5)	2 (3.8)	0	
2	Control	4 (8.2)	22 (44.9)	15 (30.6)	7 (14.3)	2 (4.1)	0.588
	Combination	1 (1.9)	23 (44.2)	18 (34.6)	6 (11.5)	4 (7.7)	
3	Control	0	14 (28.6)	25 (51.0)	9 (18.4)	4 (8.2)	0.455
	Combination	0	9 (17.3)	27 (51.9)	10 (19.2)	6 (11.5)	
4	control	0	8 (16.3)	24 (48.9)	12 (24.5)	5 (10.2)	0.077
	Combination	0	2 (3.8)	21 (40.4)	20 (38.5)	9 (17.3)	
5	Control	0	4 (8.2)	19 (38.8)	16 (32.7)	7 (14.3)	0.052
	Combination	0	0	16 (30.8)	25 (48.1)	11 (21.2)	
6	Control	0	0	16 (32.7)	22 (44.9)	11 (22.4)	0.071
	Combination	0	0	7 (13.5)	30 (57.7)	15 (28.8)	

Note: P-values <0.05 considered as statistically significant.

significant re-pigmentation of vitiligo lesions.²² In this study, we evaluated the therapeutic efficacy of combining baricitinib with NB-UVB therapy for active NSV by comparing it to the efficacy of combination therapy with OMP and NB-UVB. Our results showed that the combination therapy with baricitinib and NB-UVB significantly promoted re-pigmentation in vitiligo patients (Figure 5).

JAKi treatments, specifically tofacitinib, ruxolitinib, and baricitinib have resulted in successful re-pigmentation of vitiligo lesions. However, the efficacy of JAKi monotherapy may be limited.²³ The combination therapy of a JAKi with phototherapy enhances the therapeutic efficacy against vitiligo. Liu et al used tofacitinib to treat 10 patients with vitiligo,²⁴ although markers of autoimmune response suppression were detected in both sun-exposed and non-light exposed skin lesions, only 5 patients acquired re-pigmentation at light exposure sites or after low-dose NB-UVB irradiation, indicating that light is necessary for melanocyte regeneration. Another study showed that JAK1 levels are downregulated in vitiligo after NB-UVB phototherapy,²⁵ this finding highlights the advantage of the combination therapy of a JAKi with phototherapy. Baricitinib is a relatively new JAKi, initially approved for treating rheumatoid arthritis. Mumford et al reported the successful treatment of a patient with vitiligo, who achieved complete re-pigmentation after

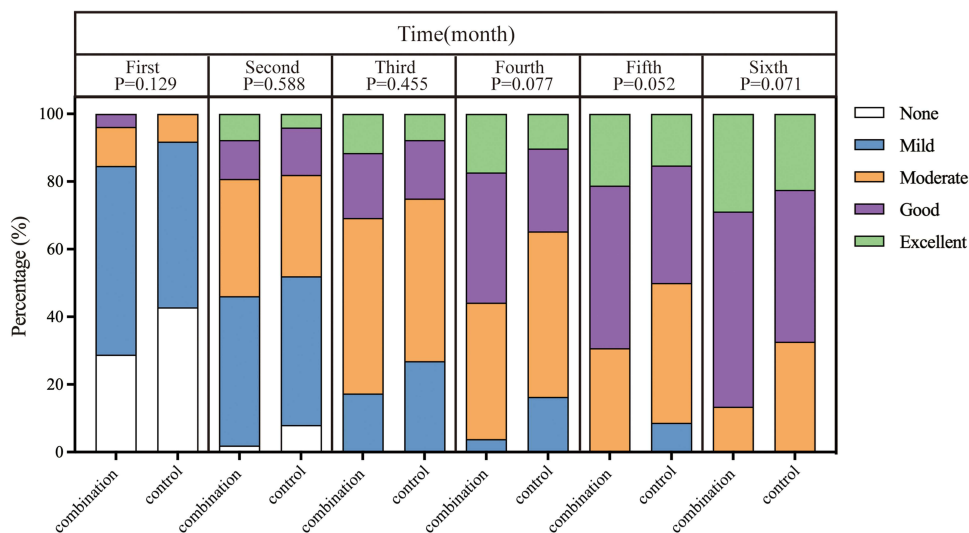


Figure 3 Proportion of different degrees of lesion improvement between the two groups. P-values <0.05 considered as statistically significant.

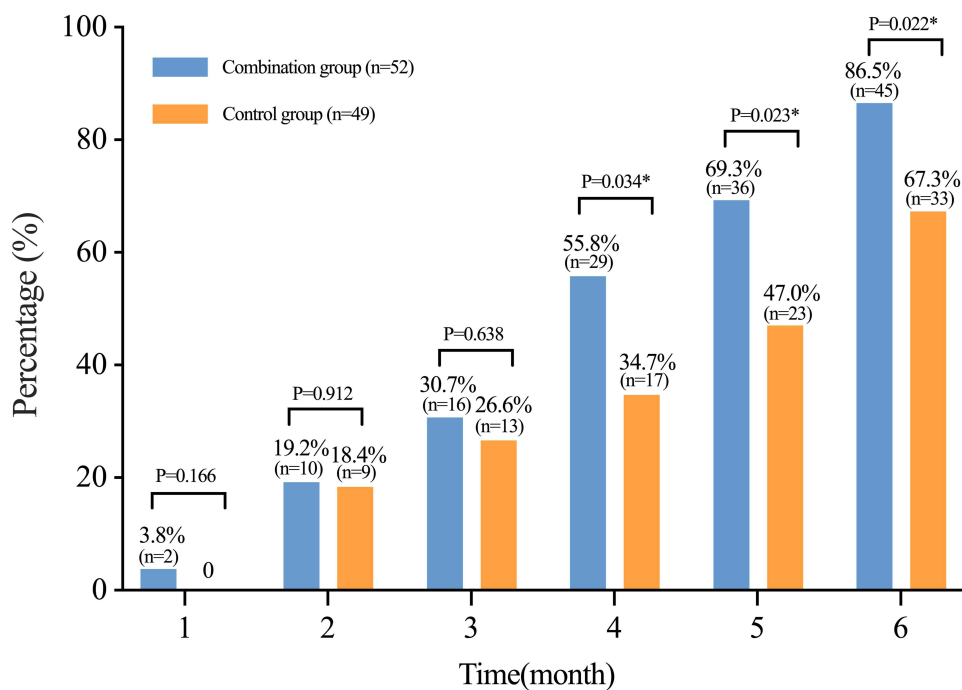


Figure 4 Comparison of overall response rates (ORRs) between the two groups. P-values <0.05 considered as statistically significant. *P < 0.05.

an 8-month treatment with baricitinib (as an alternative to tofacitinib).¹⁵ Inhibitors that selectively target JAK1/2 may be more effective than other inhibitors against vitiligo, given that IFN- γ is mediated by JAK 1/2. Dong et al found that baricitinib promotes tyrosinase activity and increases the melanin content in damaged melanocyte models, TYR and TRP-1 are upregulated in the process; thus, baricitinib may restore the tyrosinase activity and melanin synthesis ability of melanocytes.²⁶ Li et al reported on 2 patients with vitiligo treated with baricitinib and NB-UVB therapy, who achieved more than 75% repigmentation.¹⁴ These findings highlight the promising prospect of this combination therapy for the treatment of vitiligo.

Table 5 Correlation Between the Baseline Characteristics and the Degree of Lesion Improvement in the Two Groups

Group	Month		Gender	Age	Duration of disease	Skin type	VASI
Combination	1	r	-0.128	-0.169	-0.037	-0.063	0.056
		P	0.365	0.232	0.794	0.655	0.693
	2	r	-0.129	-0.205	-0.049	-0.099	-0.067
		P	0.364	0.146	0.731	0.485	0.636
	3	r	-0.105	-0.248	-0.102	0.035	0.067
		P	0.458	0.076	0.474	0.807	0.636
	4	r	-0.039	-0.245	0.031	-0.21	-0.010
		P	0.785	0.080	0.825	0.883	0.943
	5	r	-0.018	-0.089	0.095	-0.160	0.004
		P	0.898	0.531	0.502	0.258	0.980
	6	r	-0.029	-0.064	0.085	-0.112	0.102
		P	0.837	0.653	0.548	0.427	0.473

(Continued)

Table 5 (Continued).

Group	Month		Gender	Age	Duration of disease	Skin type	VASI
Control	1	<i>r</i>	0.150	0.087	-0.078	-0.187	-0.051
		<i>P</i>	0.303	0.553	0.593	0.198	0.730
	2	<i>r</i>	0.259	0.033	0.064	-0.247	-0.031
		<i>P</i>	0.073	0.821	0.664	0.087	0.834
	3	<i>r</i>	0.170	-0.042	0.055	-0.093	-0.011
		<i>P</i>	0.243	0.773	0.709	0.525	0.941
	4	<i>r</i>	0.150	-0.086	0.039	0.024	-0.032
		<i>P</i>	0.304	0.558	0.791	0.870	0.825
	5	<i>r</i>	0.168	-0.048	0.087	-0.120	-0.028
		<i>P</i>	0.248	0.744	0.553	0.412	0.847
	6	<i>r</i>	0.055	-0.086	0.076	-0.072	-0.148
		<i>P</i>	0.709	0.557	0.605	0.622	0.310

Note: *P*-values <0.05 considered as statistically significant. *r*: correlation coefficient.

Abbreviation: VASI, Vitiligo area scoring index.

Table 6 Comparison of Recurrence Rates Between the Two Groups

Group	Recurrence (%)		<i>P</i>
	Yes	No	
Combination	6 (11.5)	46 (88.5)	0.486
Control	8 (16.3)	41 (83.7)	

Note: *P*-values <0.05 considered as statistically significant.

Table 7 Changes in Serum Levels of IFN- γ and CXCL10 Before and After Six Months of Treatment

	Combination group, mean \pm SD		<i>P</i>
	Before	After	
IFN- γ , pg/mL	38.52 \pm 5.98	26.46 \pm 5.93	<0.001*
CXCL10, pg/mL	976.67 \pm 150.57	704.14 \pm 103.38	<0.001*
	Control group, mean \pm SD		<i>P</i>
	Before	After	
IFN- γ , pg/mL	36.93 \pm 6.25	36.11 \pm 6.21	0.485
CXCL10, pg/mL	907.89 \pm 111.67	773.53 \pm 108.33	0.743

Note: *P*-values <0.05 considered as statistically significant. **P* < 0.05.

Abbreviations: SD, standard deviation, IFN- γ , interferon- γ . CXCL10, CXCL chemokine ligand 10.

Although we observed a significant reduction in total VASI scores in the baricitinib combination group starting on the first month of treatment, in contrast, there was no statistically significant difference in degree of improvement between the two groups. However, From the 4th month, the ORRs were significantly higher in the combination group than in the control group, and the tendency remained existing for the next 2 months of treatment. These findings demonstrate that the

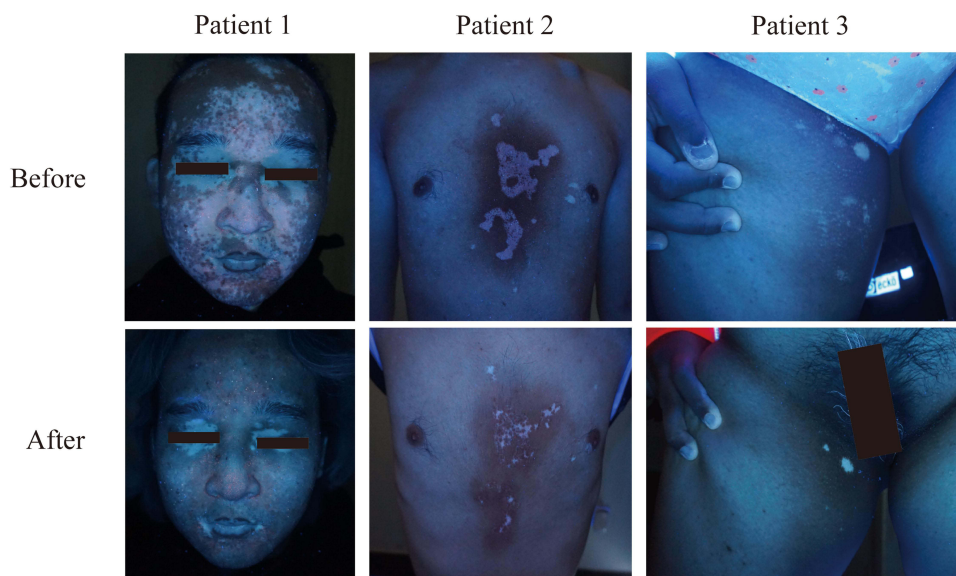


Figure 5 Clinical Improvement in vitiligo lesions after 6-month combination therapy with baricitinib and NB-UVB, Wood lamps highlight the improvement.

application of Baricitinib gained more potency over time. According to our results, combination therapy with baricitinib and NB-UVB yields gradual but continuous enhancements, rather than immediate benefits.

Previous researches have shown that the vitiligo lesions on the face, neck, trunk, and extremities exhibit the most favorable response to treatment.^{27,28} The baricitinib combination group in our study exhibited markedly enhanced improvements on the trunk, extremities, face, and neck lesions compared to the control group, which are in line with the previous results. Conversely, there was no significant differences of improvements on the acral lesions in both groups throughout the 6-month trial period. A lower level of melanocyte stem cells or baseline epidermal stem cell factors result in acral lesions such as those in hands and feet being difficult to treat.²⁹

Inhibition of JAK-mediated IFN- γ signaling is a rational strategy for vitiligo treatment. A previous study concluded that IFN- γ exerts the highest predictive value in the therapeutic response against vitiligo, followed by CXCL10.⁸ Our findings are consistent with those on earlier work demonstrating that baricitinib combination therapy for vitiligo decreases the serum levels of CXCL10 and IFN- γ in patients.^{8,30} Recently, Zhu et al found that serum levels of CXCL10 was decreased in patients with systemic steroid-resistant progressive vitiligo who receive baricitinib as a monotherapy for six-month.³¹ Given that the regulation of JAK-STAT signaling cascades by IFN- γ and CXCL10 is integral to the pathogenesis of vitiligo, a combination therapy with baricitinib and NB-UVB could accelerate the repigmentation response via reducing the serum levels of IFN- γ and CXCL10, followed by decreasing skin-associated inflammatory mediators in vitiligo lesions.

Furthermore, the similar recurrence rates between the two groups in our study suggest that the combination therapy with baricitinib and NB-UVB offers no advantages over the OMP and NB-UVB combination therapy on NSV recurrence prevention. However, given the noteworthy re-pigmentation response and relatively short duration of treatment, prolonging the administration of the baricitinib and NB-UVB may reveal advantages for stabilizing vitiligo.

Baricitinib has been used in various clinical settings, its most common adverse effects include headache, nausea, high cholesterol levels, and infections.³² In this study, only mild itchy skin and erythema were reported as AEs. Laboratory testing in both groups yielded normal results, and none of the patients discontinued the treatment, demonstrating the remarkable tolerability to baricitinib in the treatment for vitiligo. These results are consistent with others.^{14,15,26,31} However, phototherapy side effects may still affect patient compliance. A large-scale study with long-term follow-ups is needed to further assess the systemic safety of the combination therapy with baricitinib and UB-UVB.

There are some limitations in this study. First, the relatively small sample size and the brief 6-month treatment period may not completely reflect the therapeutic potential of the combination therapy with baricitinib and UB-UVB. Second,

our study was retrospective, randomized controlled double-blind trials (RCT) should be conducted to enhance the validity of future studies. Third, our study was confined to patients with active NSV, the therapeutic response of combination therapy with baricitinib and UB-UVB in other types of vitiligo remains to be determined.

Conclusion

Overall, our results provide preliminary data suggesting that the combination therapy with baricitinib is effective for active NSV, particularly in lesions of the trunk, extremities, face, and neck. Additionally, our findings also indicate a notable reduction in serum levels of IFN- γ and CXCL10 after combination therapy with baricitinib and UB-UVB. Patients tolerated the treatment well without serious AEs, demonstrating the safety of the strategy and expanding the treatment options against vitiligo. In addition, our results provide valuable preliminary data useful for planning future large-scale RCT studies to further assess the efficacy and safety profiles of the baricitinib combined with NB-UVB against vitiligo.

Abbreviations

AE, Adverse events; NSV, Non-segmental vitiligo; OMP, Oral mini-pulse; ORRs, Overall response rates; RCT, Randomized controlled double-blind trials; VASI, Vitiligo area scoring index.

Data Sharing Statement

The data that support the findings of the study are available on request from the corresponding author.

Ethics Approval and Informed Consent

The study was approved by the ethics committee of the Air Force Medical Center, PLA, Beijing, People's Republic of China. The study complies with the Declaration of Helsinki. We confirmed that the patients or patient guardians provided written informed consents to any accompanying images published.

Acknowledgments

The authors would like to thank Aniu Jin and Yunting Qian for their assistance in this study. The manuscript has undergone professional English language editing by Charlesworth, thanks to them.

Funding

There is no funding for this study.

Disclosure

The authors declare no conflicts of interest in this work.

References

1. van den Boorn JG, Konijnenberg D, DelleMijn TAM. et al. Autoimmune destruction of skin melanocytes by perilesional T cells from vitiligo patients. *J Invest Dermatol.* 2009;129(9):2220–2232. doi:10.1038/jid.2009.32
2. LeWitt TM, Kundu RV. Vitiligo. *JAMA Dermatol.* 2021;157(9):1136. doi:10.1001/jamadermatol.2021.1688
3. Bergqvist C, Ezzedine K. Vitiligo: a review. *Dermatol Basel Switz.* 2020;236(6):571–592. doi:10.1159/000506103
4. Morrison B, Burden-Teh E, Batchelor JM, Mead E, Grindlay D, Ratib S. Quality of life in people with vitiligo: a systematic review and meta-analysis. *Br J Dermatol.* 2017;177(6):e338–9. doi:10.1111/bjd.15933
5. Patel KR, Singam V, Rastogi S, Lee HH, Silverberg NB, Silverberg JL. Association of vitiligo with hospitalization for mental health disorders in US adults. *J Eur Acad Dermatol Venereol JEADV.* 2019;33(1):191–197. doi:10.1111/jdv.15255
6. Felsten LM, Alikhan A, Petronic-Rosic V. Vitiligo: a comprehensive overview Part II: treatment options and approach to treatment. *J Am Acad Dermatol.* 2011;65(3):493–514. doi:10.1016/j.jaad.2010.10.043
7. Harris JE, Harris TH, Weninger W, Wherry EJ, Hunter CA, Turka LA. A mouse model of vitiligo with focused epidermal depigmentation requires IFN- γ for autoreactive CD8⁺ T-cell accumulation in the skin. *J Invest Dermatol.* 2012;132(7):1869–1876. doi:10.1038/jid.2011.463
8. Ng CY, Chiu YC, Chan YP, et al. Skin interstitial fluid and plasma multiplex cytokine analysis reveals ifn- γ signatures and granzyme b as useful biomarker for activity, severity and prognosis assessment in vitiligo. *Front Immunol.* 2022;13:872458. doi:10.3389/fimmu.2022.872458
9. Zhang L, Chen S, Kang Y, et al. Association of clinical markers with disease progression in patients with vitiligo from china. *JAMA Dermatol.* 2020;156(3):288–295. doi:10.1001/jamadermatol.2019.4483

10. Chapman S, Gold LS, Lim HW. Janus kinase inhibitors in dermatology: part II. A comprehensive review. *J Am Acad Dermatol.* 2022;86(2):414–422. doi:10.1016/j.jaad.2021.06.873
11. Damsky W, King BA. JAK inhibitors in dermatology: the promise of a new drug class. *J Am Acad Dermatol.* 2017;76(4):736–744. doi:10.1016/j.jaad.2016.12.005
12. McLornan DP, Pope JE, Gotlib J, Harrison CN. Current and future status of JAK inhibitors. *Lancet Lond Engl.* 2021;398(10302):803–816. doi:10.1016/S0140-6736(21)00438-4
13. Qi F, Liu F, Gao L. Janus kinase inhibitors in the treatment of vitiligo: a review. *Front Immunol.* 2021;12:790125. doi:10.3389/fimmu.2021.790125
14. Li X, Sun Y, Du J, Wang F, Ding X. Excellent repigmentation of generalized vitiligo with oral baricitinib combined with NB-UVB phototherapy. *Clin Cosmet Invest Dermatol.* 2023;16:635–638. doi:10.2147/CCID.S396430
15. Mumford BP, Gibson A, Chong AH. Repigmentation of vitiligo with oral baricitinib. *Australas J Dermatol.* 2020;61(4):374–376. doi:10.1111/ajd.13348
16. Joshipura D, Plotnikova N, Goldminz A, et al. Importance of light in the treatment of vitiligo with JAK-inhibitors. *J Dermatol Treat.* 2018;29(1):98–99. doi:10.1080/09546634.2017.1339013
17. Cox NH. The expanding role of nurses in surgery and prescribing in British departments of dermatology. therapy guidelines and audit subcommittee of the British association of dermatologists. *Br J Dermatol.* 1999;140(4):681–684. doi:10.1046/j.1365-2133.1999.02770.x
18. Gui J, Li Z, Zhou B, et al. Combination of total glucosides of paeony, narrow-band ultraviolet B, and oral corticosteroid mini-pulse therapy for nonsegmental vitiligo: a retrospective study. *Skin Res Technol.* 2024;30(6):e13769. doi:10.1111/srt.13769
19. Mohammad TF, Al-Jamal M, Hamzavi IH, et al. The Vitiligo Working Group recommendations for narrowband ultraviolet B light phototherapy treatment of vitiligo. *J Am Acad Dermatol.* 2017;76(5):879–888. doi:10.1016/j.jaad.2016.12.041
20. Komen L, da Graça V, Wolkerstorfer A, de Rie MA, Terwee CB, van der Veen JPW. Vitiligo area scoring index and vitiligo European task force assessment: reliable and responsive instruments to measure the degree of depigmentation in vitiligo. *Br J Dermatol.* 2015;172(2):437–443. doi:10.1111/bjd.13432
21. Kim SM, Lee HS, Hann SK. The efficacy of low-dose oral corticosteroids in the treatment of vitiligo patients. *Int J Dermatol.* 1999;38(7):546–550. doi:10.1046/j.1365-4362.1999.00623.x
22. Esmat SM, El-Mofty M, Rasheed H, et al. Efficacy of narrow band UVB with or without OMP in stabilization of vitiligo activity in skin photo-types (III-V): a double-blind, randomized, placebo-controlled, prospective, multicenter study. *Photodermatol Photoimmunol Photomed.* 2022;38(3):277–287. doi:10.1111/phpp.12749
23. Kim SR, Heaton H, Liu LY, King BA. Rapid repigmentation of vitiligo using tofacitinib plus low-dose, narrowband UV-B phototherapy. *JAMA Dermatol.* 2018;154(3):370–371. doi:10.1001/jamadermatol.2017.5778
24. Liu LY, Strassner JP, Refat MA, Harris JE, King BA. Repigmentation in vitiligo. using the Janus kinase inhibitor tofacitinib may require concomitant light exposure. *J Am Acad Dermatol.* 2017;77(4):675–682.e1. doi:10.1016/j.jaad.2017.05.043
25. Nada HR, El Sharkawy DA, Elmasry MF, Rashed LA, Mamdouh S. Expression of Janus Kinase 1 in vitiligo & psoriasis before and after narrow band UVB: a case-control study. *Arch Dermatol Res.* 2018;310(1):39–46. doi:10.1007/s00403-017-1792-6
26. Dong J, Huang X, Ma LP, et al. Baricitinib is effective in treating progressing vitiligo in vivo and in vitro. *Dose-Response Publ Int Hormesis Soc.* 2022;20(2):15593258221105370. doi:10.1177/15593258221105370
27. Brazzelli V, Antoninetti M, Palazzini S, Barbagallo T, De Silvestri A, Borroni G. Critical evaluation of the variants influencing the clinical response of vitiligo: study of 60 cases treated with ultraviolet B narrow-band phototherapy. *J Eur Acad Dermatol Venereol JEADV.* 2007;21(10):1369–1374. doi:10.1111/j.1468-3083.2007.02278.x
28. Holla AP, Sahni K, Kumar R, Parsad D, Kanwar A, Mehta SD. Acral vitiligo and lesions over joints treated with non-cultured epidermal cell suspension transplantation. *Clin Exp Dermatol.* 2013;38(4):332–337. doi:10.1111/ced.12040
29. Esmat SM, El-Tawdy AM, Hafez GA, et al. Acral lesions of vitiligo: why are they resistant to photochemotherapy? *J Eur Acad Dermatol Venereol JEADV.* 2012;26(9):1097–1104. doi:10.1111/j.1468-3083.2011.04215.x
30. Rosmarin D, Pandya AG, Lebwohl M, et al. Ruxolitinib cream for treatment of vitiligo: a randomised, controlled, Phase 2 trial. *Lancet Lond Engl.* 2020;396(10244):110–120. doi:10.1016/S0140-6736(20)30609-7
31. Zhu Y, Shi Z, Xu Z, et al. Oral tofacitinib, baricitinib and upadacitinib monotherapy for steroid-resistant vitiligo: a prospective case series. *J Eur Acad Dermatol Venereol JEADV.* 2024. doi:10.1111/jdv.20109
32. Antonelli F, Malvaso D, Caldarola G, Simone CD, Peris K, Chiricozzi A. Infectious adverse events in patients with atopic dermatitis treated with baricitinib. *Immunotherapy.* 2023;15(18):1521–1529. doi:10.2217/imt-2023-0078

Clinical, Cosmetic and Investigational Dermatology

Dovepress

Publish your work in this journal

Clinical, Cosmetic and Investigational Dermatology is an international, peer-reviewed, open access, online journal that focuses on the latest clinical and experimental research in all aspects of skin disease and cosmetic interventions. This journal is indexed on CAS. The manuscript management system is completely online and includes a very quick and fair peer-review system, which is all easy to use. Visit <http://www.dovepress.com/testimonials.php> to read real quotes from published authors.

Submit your manuscript here: <https://www.dovepress.com/clinical-cosmetic-and-investigational-dermatology-journal>