

# The Clinical Study of Intratumoral and Peritumoral Radiomics Based on DCE-MRI for HER-2 Positive and Low Expression Prediction in Breast Cancer

Yiyan Shang<sup>1,2,\*</sup>, Yunxia Wang<sup>1,2,\*</sup>, Yaxin Guo<sup>2,3</sup>, Shunian Li<sup>2,3</sup>, Jun Liao<sup>2,3</sup>, Menglu Hai<sup>4</sup>,  
Meiyun Wang<sup>2,3</sup>, Hongna Tan<sup>1,2</sup>

<sup>1</sup>Department of Radiology, People's Hospital of Henan University, Zhengzhou, Henan, People's Republic of China; <sup>2</sup>Department of Radiology, Henan Provincial People's Hospital, Zhengzhou, Henan, People's Republic of China; <sup>3</sup>Department of Radiology, People's Hospital of Zhengzhou University, Zhengzhou, Henan, People's Republic of China; <sup>4</sup>Department of Radiology, Affiliated Cancer Hospital of Zhengzhou University & Henan Provincial Cancer Hospital, Zhengzhou, Henan, People's Republic of China

\*These authors contributed equally to this work

Correspondence: Hongna Tan, Department of Radiology, People's Hospital of Henan University & Henan Provincial People's Hospital, Zhengzhou, Henan, People's Republic of China, Tel +86 13526766042, Email natan2000@126.com

**Background:** Core biopsy sampling may not fully capture tumor heterogeneity. Radiomics provides a non-invasive method to assess tumor characteristics, including both the core and surrounding tissue, with the potential to improve the accuracy of HER-2 status prediction.

**Objective:** To explore the clinical value of intratumoral and peritumoral radiomics features from dynamic contrast enhanced magnetic resonance imaging (DCE-MRI) for preoperative prediction of human epidermal growth factor receptor-2 (HER-2) expression status in breast cancer.

**Methods:** Two tasks were designed, including Task1-distinguished HER-2 positive and HER-2 negative from 382 breast cancer patients and Task2-distinguished HER-2 low and HER-2 zero expression from 249 patients with HER-2 negative. Three radiomics models (intratumoral, peritumoral 5 mm, intratumoral+peritumoral 5 mm) were constructed based on decision tree, and clinical combined radiomics models were constructed with logistic regression based on clinicopathological features and radscore. The area under the curve (AUC), sensitivity, specificity, accuracy and decision curve analysis (DCA) were used to evaluate the predictive performance of models.

**Results:** Estrogen receptor (ER), progesterone receptor (PR) and Ki67 showed statistically significant in the different groups of HER-2 expression. Additionally, magnetic resonance imaging-reported axillary lymph nodes (MRI-reported ALN) in the positive and negative groups and histological grade in the low and zero expression groups showed significant differences (all  $P < 0.05$ ). For task 1, the peritumoral radiomics model outperformed the other two radiomics models, with AUC values of 0.774 and 0.727 in the training and testing sets, respectively. For task 2, intratumoral + peritumoral radiomics model in the testing set showed the best predictive performance among the three radiomics models, and the AUC values were 0.777. The addition of clinicopathological features slightly altered the AUC values in both tasks.

**Conclusion:** Both radiomics methods based on DCE-MRI and the nomogram are helpful for preoperative prediction of HER-2 expression status.

**Keywords:** breast cancer, human epidermal growth factor receptor-2, dynamic contrast enhanced magnetic resonance imaging, radiomics, intratumoral and peritumoral, nomogram

## Background

Breast cancer is one of the most common cancers in women worldwide and the leading cause of cancer-related death.<sup>1,2</sup> Human epidermal growth factor receptor-2 (HER-2) is a tyrosine kinase receptor, which is usually considered as an

important prognostic and predictive molecular marker for breast cancer. HER-2 expression status included positive and negative, and the HER-2 negative expression was further divided into low expression and zero expression by American Society of Clinical Oncology/College of American Pathologists (ASCO/CAP) HER-2 test guidelines.<sup>3,4</sup> HER-2 positive breast cancer patients were often treated with anti-HER-2 receptor targeted therapy. The successful trial of a new drug Trastuzumab deruxtecan (T-DXd) has changed the evaluation of HER-2 status, further distinguishing between low and zero expression in HER-2 negative expression. The T-DXd provides a new treatment strategy for breast cancer patients with HER-2 low expression,<sup>5</sup> which makes it possible for breast cancer with HER-2 low expression to become a new breast cancer type. Studies have shown that the clinicopathological characteristics, response to neoadjuvant chemotherapy and prognosis of breast cancer patients with HER-2 low expression are different from those with HER-2 zero expression and HER-2 positive breast cancer.<sup>6,7</sup> Hence, the accurate assessment of HER-2 expression status is crucial for prognostic assessment and individualized treatment options for breast cancer patients.

At present, postoperative immunohistochemistry (IHC) and fluorescence in situ hybridization (FISH) examination are still the gold standards of HER-2 expression status evaluation. However, these methods are invasive and hysteretic, and the information obtained from pathological specimens is limited, which may not fully reflect the entire heterogeneity of the lesion. Therefore, preoperative noninvasive prediction of HER-2 expression status is very important. Intratumoral features can provide detailed information about the interior of the tumor, thereby revealing the internal structural characteristics and potential biological behavior of the tumor. Peritumor features can capture the heterogeneity of the tumor microenvironment. Tumor microenvironment plays an important role during breast cancer development, progression and in determining the therapeutic response.<sup>8</sup> Intratumoral features and peritumoral features can complement each other, addressing the information gaps that may arise when using a single type of feature alone. Magnetic resonance imaging (MRI) is one of the most commonly used imaging methods to monitor the response of tumor treatment because of its high soft tissue resolution and quantitative imaging technology, which can be used to reflect the changes of tumor parenchyma and its microenvironment. Radiomics methods can further reveal the heterogeneity of lesions through quantitative analysis of high-throughput image data information.<sup>9</sup> This method has the potential to improve the accuracy of HER-2 status prediction, thereby better guiding treatment decisions and personalized therapy. Previous studies have shown that combined intratumoral and peritumoral radiomics can predict HER-2 positive and HER-2 negative status;<sup>10</sup> however, these studies did not consider HER-2 low expression breast cancer.

In this study, we aimed to explore the clinical value of combining intratumoral and peritumoral radiomic features based on Dynamic contrast enhanced magnetic resonance imaging (DCE-MRI) with clinicopathological characteristics for the preoperative prediction of HER-2 expression status in breast cancer, providing a reference for the treatment decision selection of different HER-2 expression status breast cancer patients.

## Materials and Methods

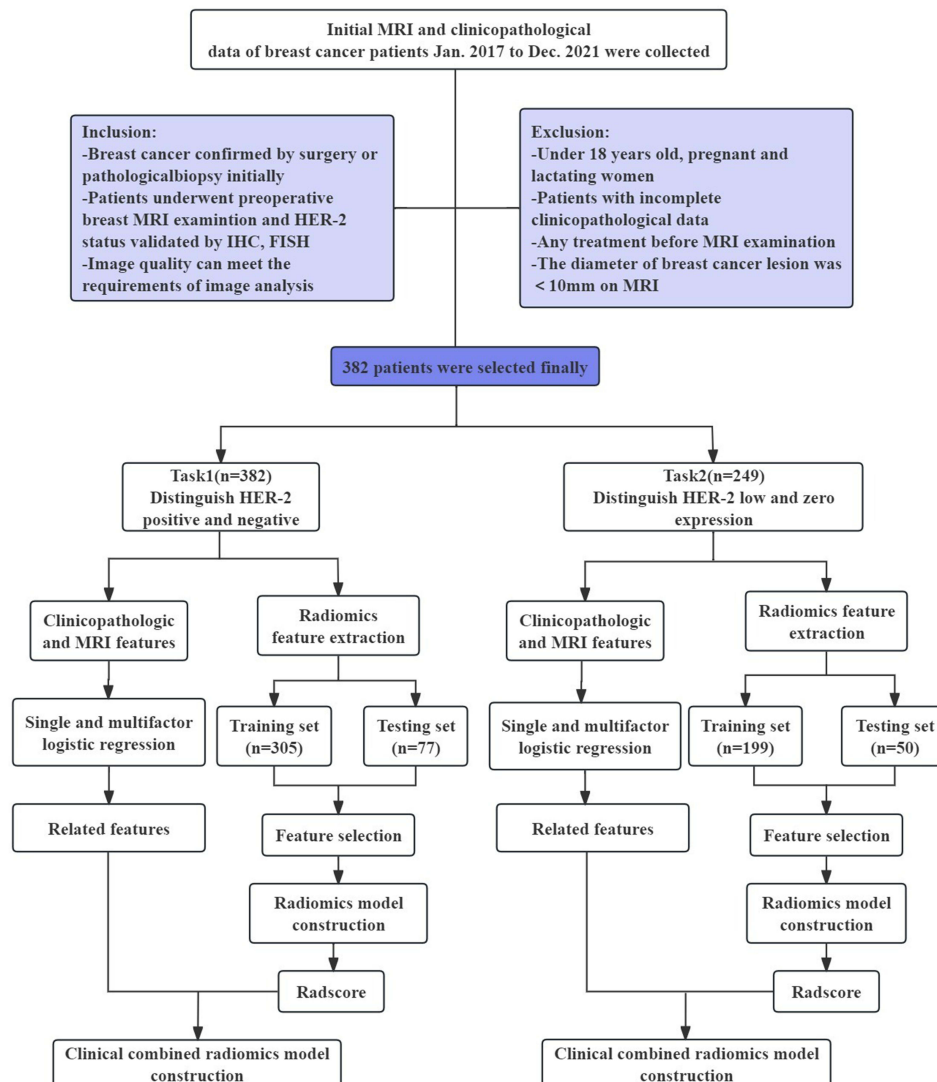
### Patient Population

This study complied with the Declaration of Helsinki and was approved by the Medical Ethics Committee of Henan Provincial People's Hospital (NO. 2022-124). This study was retrospective and the data was anonymous, so patient informed consent was waived. The initial MRI and clinicopathological data of breast cancer patients confirmed by pathology in our hospital from Jan. 2017 to Dec. 2021 were retrospectively collected. The inclusion criteria were as follows: (1) breast cancer confirmed by surgery or pathological biopsy initially; (2) patients underwent initial preoperative breast MRI examination and had a confirmed HER-2 status (with IHC results; if IHC was 2+, FISH testing was required for confirmation); (3) image quality can meet the requirements of image analysis. The exclusion criteria were as follows: (1) patients with age no more than 18 years old, pregnant or lactating woman; (2) patients with incomplete clinicopathological data; (3) patients who have undergone biopsy, radiotherapy, chemotherapy and other treatments before MRI examination; (4) patients who has the diameter of breast cancer lesion were <10 mm on MRI. A total of 382 breast cancer patients were finally included in this study according to the inclusion and exclusion criteria. In this study, we designed two tasks, including Task1: distinguishing HER-2 positive (n = 133) and HER-2 negative expression status

(n = 249) from 382 breast cancer patients; Task2: distinguishing HER-2 low (n = 170) and HER-2 zero expression (n = 79) from 249 patients with HER-2 negative expression. The flow chart of this study is shown in Figure 1.

## Clinicopathological and MRI Data

The clinicopathological data of patients were collected by the electronic medical record system of our hospital, including patient age, lesion position, lesion number, bilateral breast cancer or not, family history of breast cancer, menopausal status, pathological type, histological grade, estrogen receptor (ER) status, progesterone receptor (PR) status, Ki67, axillary lymph nodes (ALN), IHC, FISH results. If the patient had bilateral breast cancer, information about both primary tumors were collected. Based on the breast MRI-BIRADS classification evaluation system (2013 fifth version),<sup>11</sup> the MRI features of patients were collected on MRI images, including gland type, background parenchymal enhancement (BPE), lesion size, MRI associated ALN status and time-intensity curve (TIC). Lesion size was the maximum axial diameter measured by two radiologists on DCE-MRI, and its average value was taken. According to the ASCO/CAP HER-2 testing guidelines,<sup>3,4</sup> HER-2 expression status was classified as HER-2 positive (IHC score of 3+ or 2+ with positive FISH results), HER-2 negative (IHC score of 0, 1+ or 2+ with negative FISH results), and HER-2 negative



**Figure 1** Patient flow chart of the study. There were four models to preoperative evaluate HER-2 expression status for breast cancer, including three radiomics models (intratumoral, peritumoral, intratumoral + peritumoral) and clinical combined radiomics model.

**Abbreviations:** MRI, magnetic resonance imaging; HER-2, human epidermal growth factor receptor-2; IHC, immunohistochemistry; FISH, fluorescence in situ hybridization.

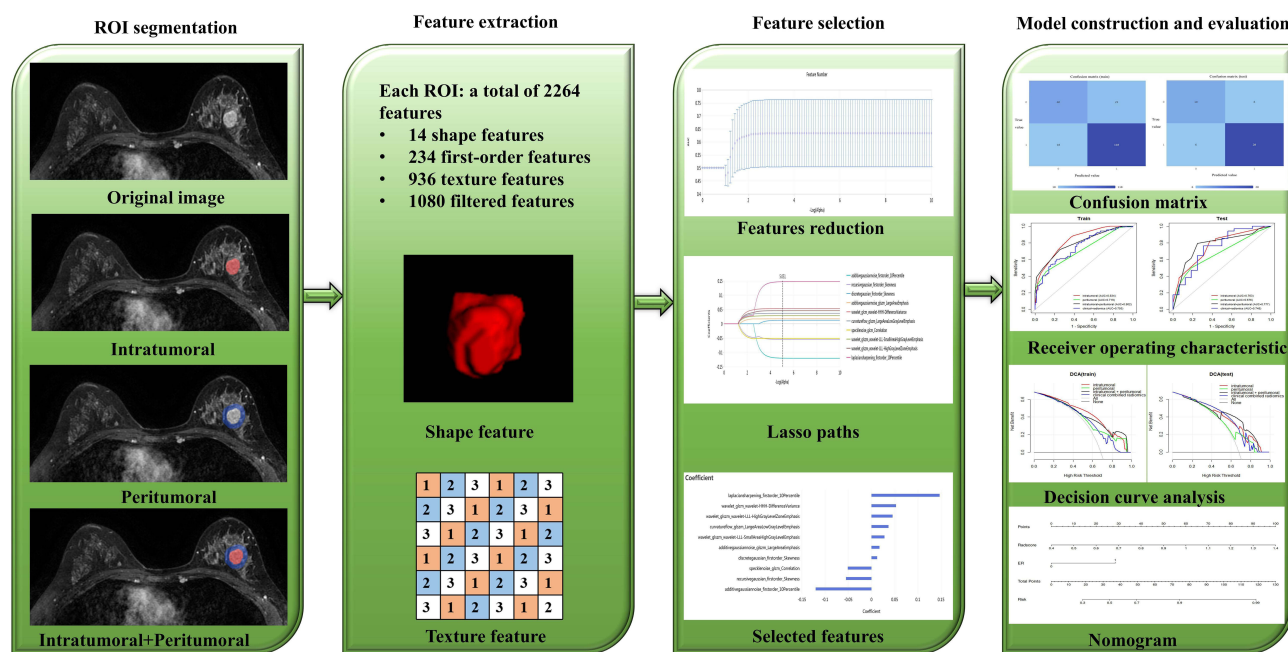
expression was further divided into HER-2-low expression (IHC score of 1+ or 2+ with negative FISH results) and HER-2-zero expression (IHC score of 0). ER and PR were classified as positive ( $\geq 1\%$ ) or negative ( $< 1\%$ ) according to the ASCO/CAP ER and PR testing guidelines.<sup>12</sup> The cut-off point for Ki-67 index evaluation was 20%.<sup>13</sup>

### MRI Examination

Breast MRI examinations were performed using 3.0T MR imaging devices and dedicated breast phased-array surface coils (GE Medical Systems, Discovery MR750, Milwaukee, USA). During the examination, the patient lay prone on the coil with both hands raised in front of them. The breast MRI examination consisted of T1/T2-weighted imaging (T1/T2WI) and dynamic contrast-enhanced T1-weighted (DCE-T1) sequences. The scanning parameters for each sequence were as follows: T1-weighted axial sequences (TR/TE, 704/10 ms; slice thickness, 5 mm; number of slices, 24). T2-weighted axial sequences (TR/TE, 3451/68 ms; slice thickness, 5 mm; number of slices, 24). DCE-T1 was performed using the volume imaging for breast assessment (VIBRANT) technique (TR/TE, 4/2.2 ms; slice thickness, 1.1 mm; number of slices, 136; and phase, 8). The contrast agent was Gd-DTPA at a dose of 0.2 mmol/kg. The first phase was the mask scanning without contrast agent injection. After the Phase 1 scanning, the contrast agent was rapidly injected in 10s with a high-pressure syringe at a rate of 2.0 mL/s. Next, the tube was flushed with 20 mL saline injected at the same rate. Seven phases were obtained in turn and each phase took about 51s.

### Image Processing and Segmentation

The flow chart of radiomics is shown in Figure 2. Breast DCE-T1WI sequence Phase 3 images were exported from the picture archiving and communication systems (PACS) and stored in digital imaging and communication in medicine (DICOM) format. To reduce bias, radiologists delineated the ROI in a blinded fashion, without knowing the patient’s clinical information, such as IHC and FISH results. The images were analyzed using ITK-SNAP software (Version 3.8.0, <http://www.itk-snap.org>), developed by the Penn Image Computing and Science Laboratory (PICSL) at the University of Pennsylvania. Radiologists used ITK-SNAP software to manually delineate a three-dimensional region of interest (ROI) of the lesion on phase 3 images of the DCE-T1WI sequence. If there were multiple lesions on MRI, the ROI of the largest lesion was delineated. The intratumoral region (ITR) was manually delineated slice by slice by a breast radiologist with more than 7 years of experience while avoiding the areas of cystic necrosis or hemorrhage. Validation of the delineated ITRs



**Figure 2** Flow chart of radiomics, including ROI segmentation, features extraction and selection, and models construction and evaluation. **Abbreviation:** ROI, region of interest.

was performed by an associate chief physician with more than 10 years of experience in breast radiology. If there was a difference between the ROI delineated by two radiologists, the final ROI was determined by a third radiologist with 20 years of experience. The peritumoral region (PTR) was obtained by morphologically dilating the ITR outward by 5 mm using the uAI Research Portal (United Imaging Intelligence, China), a clinical research platform incorporating AI module algorithms. Any portions of the PTR beyond the breast parenchyma were manually removed. Each lesion obtained 2 ROIs, including an ITR and a 5 mm PTR.

## Feature Extraction and Selection

The uAI Research Portal (<https://www.uui-ai.com/en/uai/scientific-research>) was used to extract radiomics features from ROI of the intratumoral and peritumoral 5 mm. In our study, we applied image normalization during radiomics feature extraction. This improves the consistency of image data in terms of intensity, contrast, and other aspects, thereby enhancing the accuracy and reproducibility of feature extraction. Therefore, it can improve clinical applicability to a certain extent. Four kinds of radiomics features were extracted from each segmented ROI, including shape features, first-order statistical features, texture features and wavelet features. A total of 2264 radiomics features were extracted from each intratumoral and peritumoral ROI. For task 1 and task 2, Mann–Whitney *U*-test, *Z*-score normalization, variance threshold, K-best, least absolute shrinkage and selection operator (LASSO) were used to select radiomics features strongly associated with HER-2 positive and HER-2 low expression breast cancer. More information about the method of radiomics features extraction and selection can be found in the [Supplementary Data](#).

## HER-2 Status Predictive Models Construction and Performance Evaluation

Patients in both tasks were randomly divided into training sets ( $n_1 = 305$ ,  $n_2 = 199$ ) and testing sets ( $n_1 = 77$ ,  $n_2 = 50$ ) according to the ratio of 8:2. Three radiomics models (DCE-MRI intratumoral, peritumoral 5 mm, intratumoral+peritumoral 5 mm) and one clinical combined radiomics model were constructed in both tasks. The three radiomics models were established by decision tree. The performance is evaluated with the sensitivity, specificity, accuracy, area under the receiver operating characteristic curve (AUC), DeLong test and decision curve analysis (DCA).

To analyze the relationship between clinicopathological features, MRI features and HER-2 expression status, single and multifactor logistic regression was used to select the independent risk factors.  $P < 0.05$  is considered to indicate a significant difference. Nomograms were established by combining the radscores of intratumoral+peritumoral radiomics model, with the independent risk factors using logistic regression models. To evaluate the calibration of the nomogram, calibration curves were plotted, and Hosmer–Lemeshow tests were performed.

## Statistical Analysis

Statistical analysis was performed using SPSS software (Version 27.0, IBM, NY, USA) and R software (Version 4.3.2, R Foundation for Statistical Computing, Vienna, Austria). *P* values were calculated using the Mann–Whitney *U*-test or *t* test for continuous variables and the  $\chi^2$  test or Fisher exact test for categorical variables. Single and multifactor logistic regression analysis was used to select the independent risk factors. ROC and DCA were plotted using R software. The AUC values of different models were compared by the DeLong tests. A two-sided *P* value  $< 0.05$  was considered statistically significant.

## Results

### Clinical Findings

According to the inclusion and exclusion criteria, a total of 382 breast cancer patients were finally included. All patients were female, ranging in age from 25 to 82 years old, with an average age of 49 years old. In our study, the clinical stages of patients range from Stage 0 to Stage IV, and the pathological types include invasive breast cancer of nonspecific type (IBC-NST) and ductal carcinoma in situ (DCIS). For Task 1, ER, PR, Ki67, and MRI-associated ALN status showed statistically significant differences between the HER-2 positive and HER-2 negative groups (all  $P < 0.05$ ; [Table 1](#)). For task 2, histological grade, ER, PR and Ki67 showed statistically significant differences between HER-2 low expression

**Table 1** Comparison of Clinicopathological, MRI Characteristics Between Groups in Task1 and Task2

Characteristic	HER-2 Expression Status: Task 1			HER-2 Expression Status: Task 2		
	Positive (n=133)	Negative (n=249)	P value	Low (n=170)	Zero (n=79)	P value
Age (Mean ± SD, year)	48.5±9.6	49.2±10.7	0.560	49.2±10.2	49.2±11.8	0.987
Position						
Left	64 (48.1%)	120 (48.2%)	0.989	82 (48.2%)	38 (48.1%)	0.984
Right	69 (51.9%)	129 (51.8%)		88 (51.8%)	41 (51.9%)	
History of breast cancer						
Present	128 (96.2%)	238 (95.6%)	0.760	162 (95.3%)	76 (96.2%)	1.000
Absent	5 (3.8%)	11 (4.4%)		8 (4.7%)	3 (3.8%)	
Menopausal status						
Postmenopausal	60 (45.1%)	111 (44.6%)	0.920	79 (46.5%)	32 (40.5%)	0.378
Premenopausal	73 (54.9%)	138 (55.4%)		91 (53.5%)	47 (59.5%)	
Histological grade						
I	0 (0.0%)	10 (4.0%)	0.064	8 (4.7%)	2 (2.5%)	<b>0.031</b>
II	86 (64.7%)	154 (61.8%)		113 (66.5%)	41 (51.9%)	
III	47 (35.3%)	85 (34.1%)		49 (28.8%)	36 (45.6%)	
ER status						
<1%	60 (45.1%)	49 (19.7%)	<b>&lt;0.001</b>	17 (10.0%)	32 (40.5%)	<b>&lt;0.001</b>
≥1%	73 (54.9%)	200 (80.3%)		153 (90.0%)	47 (59.5%)	
PR status						
<1%	84 (63.2%)	85 (34.1%)	<b>&lt;0.001</b>	46 (27.1%)	39 (49.4%)	<b>&lt;0.001</b>
≥1%	49 (36.8%)	164 (65.9%)		124 (72.9%)	40 (50.6%)	
Ki67 status						
≤20%	27 (20.3%)	89 (35.7%)	<b>0.002</b>	68 (40.0%)	20 (25.3%)	<b>0.024</b>
>20%	106 (79.7%)	160 (64.3%)		102 (60.0%)	59 (74.7%)	
ALN status						
Nonmetastasis	68 (51.1%)	152 (61.0%)	0.062	100 (58.8%)	52 (65.8%)	0.292
Metastasis	65 (48.9%)	97 (39.0%)		70 (41.2%)	27 (34.2%)	
Gland type						
Fatty type	23 (17.3%)	47 (18.9%)	0.920	29 (17.1%)	18 (22.8%)	0.634
Scattered type	32 (24.1%)	60 (24.1%)		44 (25.9%)	16 (20.3%)	
Heterogeneous dense type	46 (34.6%)	78 (31.3%)		54 (31.8%)	24 (30.4%)	
Extremely dense type	32 (24.1%)	64 (25.7%)		43 (25.3%)	21 (26.6%)	
BPE						
Minimal	34 (25.6%)	62 (24.9%)	0.460	42 (24.7%)	20 (25.3%)	0.652
Mild	55 (41.4%)	122 (49.0%)		86 (50.6%)	36 (45.6%)	
Moderate	40 (30.1%)	59 (23.7%)		37 (21.8%)	22 (27.8%)	
Marked	4 (3.0%)	6 (2.4%)		5 (2.9%)	1 (1.3%)	
Lesion size [M(Q1,Q3)]/mm	22.0 (15.5,29.5)	21.0 (16.0,29.5)	0.976	20.5 (16.0,29.3)	22.0 (16.0,30.0)	0.277
MRI associated ALN status						
Nonmetastasis	51 (38.3%)	133 (53.4%)	<b>0.005</b>	90 (52.9%)	43 (54.4%)	0.826
Metastasis	82 (61.7%)	116 (46.6%)		80 (47.1%)	36 (45.6%)	
TIC						
I	8 (6.0%)	17 (6.8%)	0.853	12 (7.1%)	5 (6.3%)	0.531
II	56 (42.1%)	110 (44.2%)		71 (41.8%)	39 (49.4%)	
III	69 (51.9%)	122 (49.0%)		87 (51.2%)	35 (44.3%)	

**Notes:** Bold text represents p-values < 0.05.

**Abbreviations:** SD, standard deviation; MRI, magnetic resonance imaging; HER-2, human epidermal growth factor receptor-2; ER, estrogen receptor; PR, progesterone receptor; ALN, axillary lymph nodes; BPE, background parenchymal enhancement; the lesion size was the maximum diameter measured on MRI; TIC, time-intensity curve, TIC was classified into 3 classical types: type I – inflow type, type II – platform type, and type III – outflow type.

and HER-2 zero expression groups (all  $P < 0.05$ ; Table 1). For task 1 and task 2, there were no statistically significant in clinicopathological and MRI features between the training sets and the testing sets (all  $P > 0.05$ ; Table 2).

## Prediction Performance of Different Models Both in Task 1 and Task 2

For task 1, 10 intratumoral and 7 peritumoral features strongly correlated with HER-2 positive were finally selected. For task 2, 5 intratumoral and 3 peritumoral features strongly correlated with HER-2 low expression were finally selected. 17 and 7 features were selected to construct intratumoral + peritumoral models in task1 and task2, respectively.

**Table 2** Comparison of Clinicopathological, MRI Characteristics Between Training Sets, Testing Sets in task1 and task2

Characteristic	Task1			Task2		
	Training Set (n=305)	Testing Set (n=77)	P value	Training Set (n=199)	Testing Set (n=50)	P value
Age (Mean $\pm$ SD, year)	48.8 $\pm$ 10.2	49.5 $\pm$ 10.7	0.626	49.7 $\pm$ 10.4	47.3 $\pm$ 11.6	0.164
Position						
Left	147 (48.2%)	37 (48.1%)	0.982	95 (47.7%)	25 (50.0%)	0.775
Right	158 (51.8%)	40 (51.9%)		104 (52.3%)	25 (50.0%)	
History of breast cancer						
Present	292 (95.7%)	74 (96.1%)	1.000	191 (96.0%)	47 (94.0%)	0.823
Absent	13 (4.3%)	3 (3.9%)		8 (4.0%)	3 (6.0%)	
Menopausal status						
Postmenopausal	133 (43.6%)	38 (49.4%)	0.365	93 (46.7%)	18 (36.0%)	0.172
Premenopausal	172 (56.4%)	39 (50.6%)		106 (53.3%)	32 (64.0%)	
Histological grade						
I	7 (2.3%)	3 (3.9%)	0.657	9 (4.5%)	1 (2.0%)	0.706
II	194 (63.6%)	46 (59.7%)		123 (61.8%)	31 (62.0%)	
III	104 (34.1%)	28 (36.4%)		67 (33.7%)	18 (36.0%)	
ER status						
<1%	89 (29.2%)	20 (26.0%)	0.578	40 (20.1%)	9 (18.0%)	0.738
$\geq$ 1%	216 (70.8%)	57 (74.0%)		159 (79.9%)	41 (82.0%)	
PR status						
<1%	140 (45.9%)	29 (37.7%)	0.193	69 (34.7%)	16 (32.0%)	0.722
$\geq$ 1%	165 (54.1%)	48 (62.3%)		130 (65.3%)	34 (68.0%)	
Ki67 status						
$\leq$ 20%	91 (29.8%)	25 (32.5%)	0.654	74 (37.2%)	15 (30.0%)	0.343
>20%	214 (70.2%)	52 (67.5%)		125 (62.8%)	35 (70.0%)	
ALN status						
Nonmetastasis	181 (59.3%)	39 (50.6%)	0.168	121 (60.8%)	31 (62.0%)	0.877
Metastasis	124 (40.7%)	38 (49.4%)		78 (39.2%)	19 (38.0%)	
Gland type						
Fatty type	59 (19.3%)	11 (14.3%)	0.489	42 (21.1%)	5 (10.0%)	0.261
Scattered type	69 (22.6%)	23 (29.9%)		45 (22.6%)	15 (30.0%)	
Heterogeneous dense type	101 (33.1%)	23 (29.9%)		63 (31.7%)	15 (30.0%)	
Extremely dense type	76 (24.9%)	20 (26.0%)		49 (24.6%)	15 (30.0%)	
BPE						
Minimal	71 (23.3%)	25 (32.5%)	0.222	49 (24.6%)	13 (26.0%)	0.821
Mild	149 (48.9%)	28 (36.4%)		98 (49.2%)	24 (48.0%)	
Moderate	77 (25.2%)	22 (28.6%)		48 (24.1%)	11 (22.0%)	
Marked	8 (2.6%)	2 (2.6%)		4 (2.0%)	2 (4.0%)	
Lesion size[M(Q1,Q3)]/mm	21.0 (16.0,29.0)	20.0 (16.5,30.0)	0.955	20.0 (16.0,29.0)	23.5 (16.0,35.3)	0.423

(Continued)

**Table 2** (Continued).

Characteristic	Task1			Task2		
	Training Set (n=305)	Testing Set (n=77)	P value	Training Set (n=199)	Testing Set (n=50)	P value
MRI associated ALN status						
Nonmetastasis	142 (46.6%)	42 (54.5%)	0.210	108 (54.3%)	25 (50.0%)	0.588
Metastasis	163 (53.4%)	35 (45.5%)		91 (45.7%)	25 (50.0%)	
TIC						
I	21 (6.9%)	4 (5.2%)	0.240	12 (6.0%)	5 (10.0%)	0.554
II	126 (41.3%)	40 (51.9%)		90 (45.2%)	20 (40.0%)	
III	158 (51.8%)	33 (42.9%)		97 (48.7%)	25 (50.0%)	

**Abbreviations:** SD, standard deviation; MRI, magnetic resonance imaging; HER-2, human epidermal growth factor receptor-2; ER, estrogen receptor; PR, progesterone receptor; ALN, axillary lymph nodes; BPE, background parenchymal enhancement; the lesion size was the maximum diameter measured on MRI; TIC, time-intensity curve, TIC was classified into 3 classical types: type I – inflow type, type II – platform type, and type III – outflow type.

After single and multi-factor logistic regression analysis, PR was an independent risk factor for predicting HER-2 positive, and ER was an independent risk factor for predicting HER-2 low expression.

The predictive performance details of radiomics models were shown in Table 3. For task 1, the model based on peritumoral radiomics features showed better predictive performance comparing with the other two models (intratumoral, intratumoral + peritumoral) both in the training and testing sets, and the AUC values were 0.774 (0.722–0.826) and 0.727 (0.620–0.835), respectively. When the clinicopathological factors added, the AUC values of combined model showed slightly increased (0.746 vs 0.743 in the training set, and 0.718 vs 0.703 in the testing set) comparing with the models of intratumoral + peritumoral radiomics features, but a little lower than that of peritumoral (0.746 vs 0.774 in the training set, and 0.718 vs 0.727 in the testing set).

For task 2, the model of intratumoral radiomics features in the training set and intratumoral + peritumoral radiomics model in the testing set showed the best predictive performance among the three models, and the AUC values were 0.834 (0.775–0.893) and 0.777 (0.637–0.916). When the clinicopathological factors added, the AUC values of combined model showed slightly decreased (0.750 vs 0.802 in the training set and 0.748 vs 0.777 in the testing set) comparing with the model of intratumoral + peritumoral radiomics features. The ROC curves more intuitively showed the AUC value of each model (Figure 3).

## DeLong Test and DCA Curve

The DeLong tests details of AUC value were shown in Table 4. In both task 1 and task 2, DCA curve showed that intratumoral, peritumoral, intratumoral + peritumoral, clinical combined radiomics had higher net benefits than the “treat none” or “treat all” strategies across a wide range of threshold probabilities (Figure 4).

## Clinical Use

The clinical combined radiomics model was also presented as a form of nomogram (Figure 5). The details of Hosmer-Lemeshow tests were shown in Table 5. Calibration curves (Figure 6) were plotted to assess the consistency between the nomogram-predicted probability of HER-2 expression status and the actual results.

## Discussion

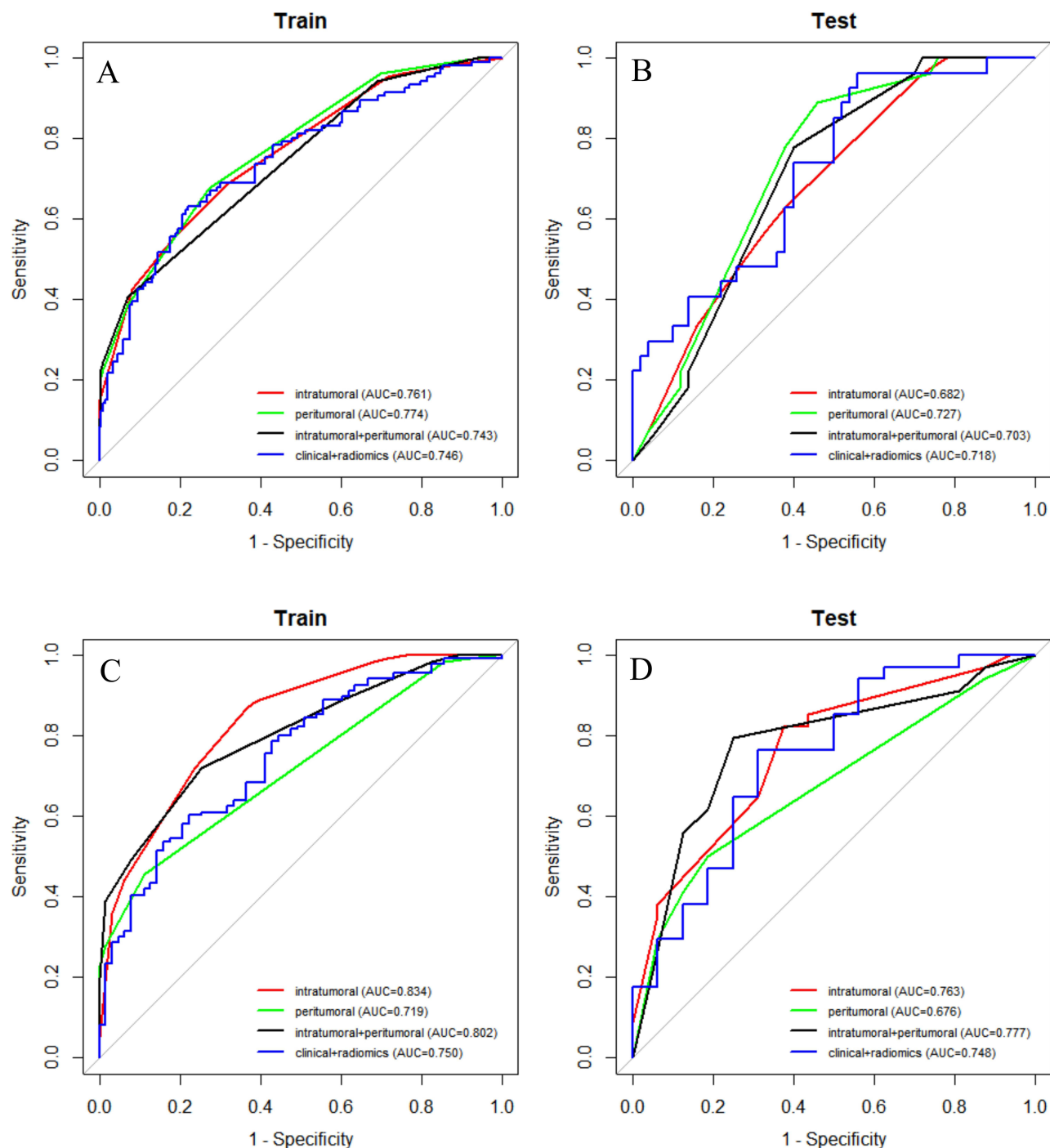
HER-2 is an important driver gene and prognostic indicator of breast cancer. About 20–25% of breast cancer patients are reported existing HER-2 over-expression.<sup>14</sup> HER-2-positive breast cancer is more aggressive and has a poor prognosis, and targeted therapies could improve the outcomes for the patients.<sup>15</sup> About 55% of breast cancer patients have HER-2 low expression.<sup>16</sup> Previous studies reported the expression status of HER-2 as positive and negative, and HER-2 low expression was regarded as negative. The emergence of T-DXd makes more and more scholars pay attention to breast cancer with HER-2 low expression. Therefore, noninvasive and accurate assessment of HER-2 expression status could

**Table 3** Prediction Performance of Different Models in Both Tasks

Model	Training Set					Testing Set				
	AUC(95% CI)	Sensitivity	Specificity	Accuracy	FI score	AUC(95% CI)	Sensitivity	Specificity	Accuracy	FI score
Task 1: Distinguish HER-2 positive and HER-2 negative										
Intratumoral	0.761 (0.706~0.816)	55.7%	81.4%	72.5%	0.584	0.682 (0.567~0.798)	55.6%	68.0%	63.6%	0.517
Peritumoral	0.774 (0.722~0.826)	67.0%	73.4%	71.1%	0.617	0.727 (0.620~0.835)	88.9%	54.0%	66.2%	0.649
Intratumoral+Peritumoral	0.743 (0.694~0.792)	40.6%	93.0%	74.8%	0.528	0.703 (0.594~0.813)	77.8%	60.0%	66.2%	0.618
Clinical+Radiomics(combined)	0.746 (0.687~0.805)	73.6%	59.8%	64.6%	0.591	0.718 (0.600~0.835)	63.0%	60.0%	61.0%	0.531
Task 2: Distinguish HER-2 low expression and HER-2 zero expression										
Intratumoral	0.834 (0.775~0.893)	86.8%	63.5%	79.4%	0.852	0.763 (0.624~0.902)	82.4%	62.5%	76.0%	0.824
Peritumoral	0.719 (0.661~0.776)	45.6%	88.9%	59.3%	0.605	0.676 (0.539~0.814)	50.0%	81.2%	60.0%	0.630
Intratumoral+Peritumoral	0.802 (0.743~0.861)	72.1%	74.6%	72.9%	0.784	0.777 (0.637~0.916)	79.4%	75.0%	78.0%	0.831
Clinical+Radiomics(combined)	0.750 (0.679~0.821)	67.6%	63.5%	66.3%	0.733	0.748 (0.595~0.901)	76.5%	68.8%	74.0%	0.800

**Note:** The clinical + radiomics model is based on clinicopathological feature and the radscore of intratumoral + peritumoral model.

**Abbreviation:** AUC, area under the receiver operating characteristic curve.



**Figure 3** (A and B) Are ROC curves of training set and testing set in task 1. (C and D) Are ROC curves of training set and testing set in task 2.

**Abbreviation:** AUC, area under the receiver operating characteristic curve.

help clinicians select appropriate therapies for breast cancer patients. MRI was widely used in the diagnosis and prognosis evaluation of breast cancer because of its high soft tissue resolution. Radiomics revealed the heterogeneity of tumor cells and the tumor microenvironment at a deeper level and had been widely applied in the diagnosis, efficacy evaluation, and prognosis assessment of tumors.<sup>17,18</sup> In previous studies, intratumoral and peritumoral radiomics combined with clinical indicators had been used to predict HER-2 positive breast cancer; however, there had been limited use of combining radiomics with clinical indicators to jointly predict HER-2 low expression in breast cancer.<sup>19</sup>

**Table 4** DeLong Tests of AUC Values of Training Sets and Testing Sets in Different Models

Model	Training Set	Testing Set
	P	P
Task 1: Distinguish HER-2 positive and HER-2 negative		
Intratumoral vs Peritumoral	0.722	0.529
Intratumoral vs Intratumoral+Peritumoral	0.584	0.789
Intratumoral vs Clinical+Radiomics	0.698	0.656
Peritumoral vs Intratumoral+Peritumoral	0.162	0.633
Peritumoral vs Clinical+Radiomics	0.447	0.901
Intratumoral+Peritumoral vs Clinical+Radiomics	0.923	0.838
Task 2: Distinguish HER-2 low expression and HER-2 zero expression		
Intratumoral vs Peritumoral	<b>0.003</b>	0.368
Intratumoral vs Intratumoral+Peritumoral	0.374	0.878
Intratumoral vs Clinical+Radiomics	<b>0.024</b>	0.882
Peritumoral vs Intratumoral+Peritumoral	<b>0.030</b>	0.244
Peritumoral vs Clinical+Radiomics	0.443	0.378
Intratumoral+Peritumoral vs Clinical+Radiomics	0.244	0.708

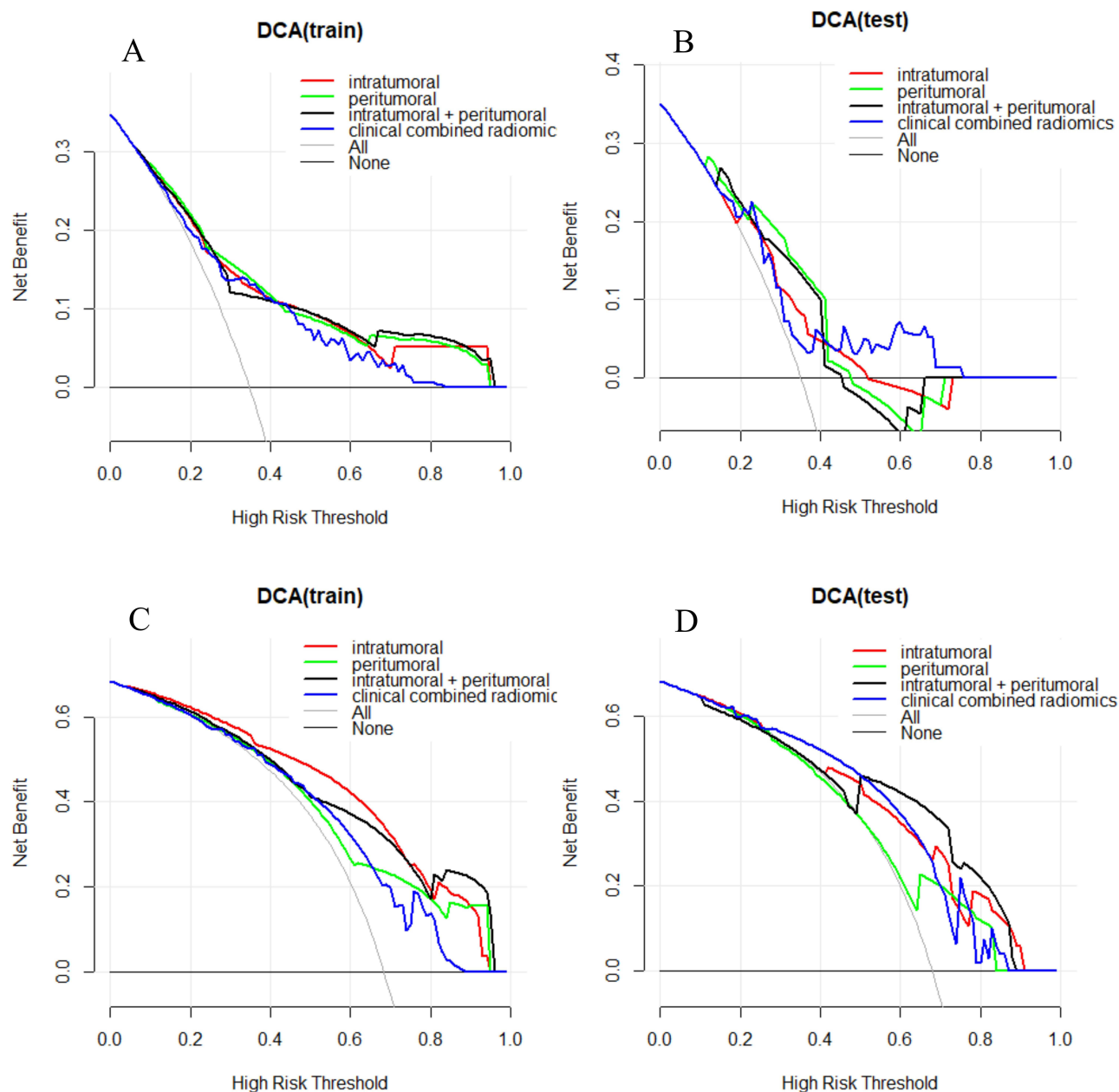
**Note:** Bold text represents p-values < 0.05.

**Abbreviations:** AUC, area under the receiver operating characteristic curve; HER-2, human epidermal growth factor receptor-2;

We not only predicted HER-2 positive and negative expression based on DCE-MRI intratumoral and peritumoral radiomics but also further predicted HER-2 low expression and zero expression. In addition, additional clinical indicators were combined when constructing the prediction models comparing with the previous studies.<sup>20,21</sup>

In this study, ER positive rate (200, 80.3%), PR positive rate (164, 65.9%), Ki67 low expression (89, 35.7%) and MRI associated ALN nonmetastasis (133, 53.4%) in the HER-2 negative group were higher than those in the HER-2 positive group ( $P$  values <0.001, <0.001, 0.002, 0.005). Breast cancer that is ER positive, PR positive, with low Ki67 expression and MRI-associated ALN non-metastasis has a lower degree of malignancy and a better prognosis, making HER-2 negative breast cancer with these indicators less aggressive, such as Luminal-A type breast cancer. Our research results suggest that I and II histological grades were more common in HER-2 low expression breast cancer patients, which was consistent with the results of Peiffer et al<sup>22</sup> and Dai et al.<sup>23</sup> In this study, ER positive rate (153, 90.0%), PR positive rate (124, 72.9%) and Ki67 low expression rate (68, 40.0%) in patients with HER-2 low expression were higher than those in patients with HER-2 zero expression ( $P$  values <0.001, <0.001, 0.024). This was consistent with the research results of Peiffer et al<sup>22</sup> and Hu et al.<sup>24</sup> HER-2 low expression breast cancer patients with ER positive, PR positive, Ki67 low expression, I and II histological grades have better prognosis.

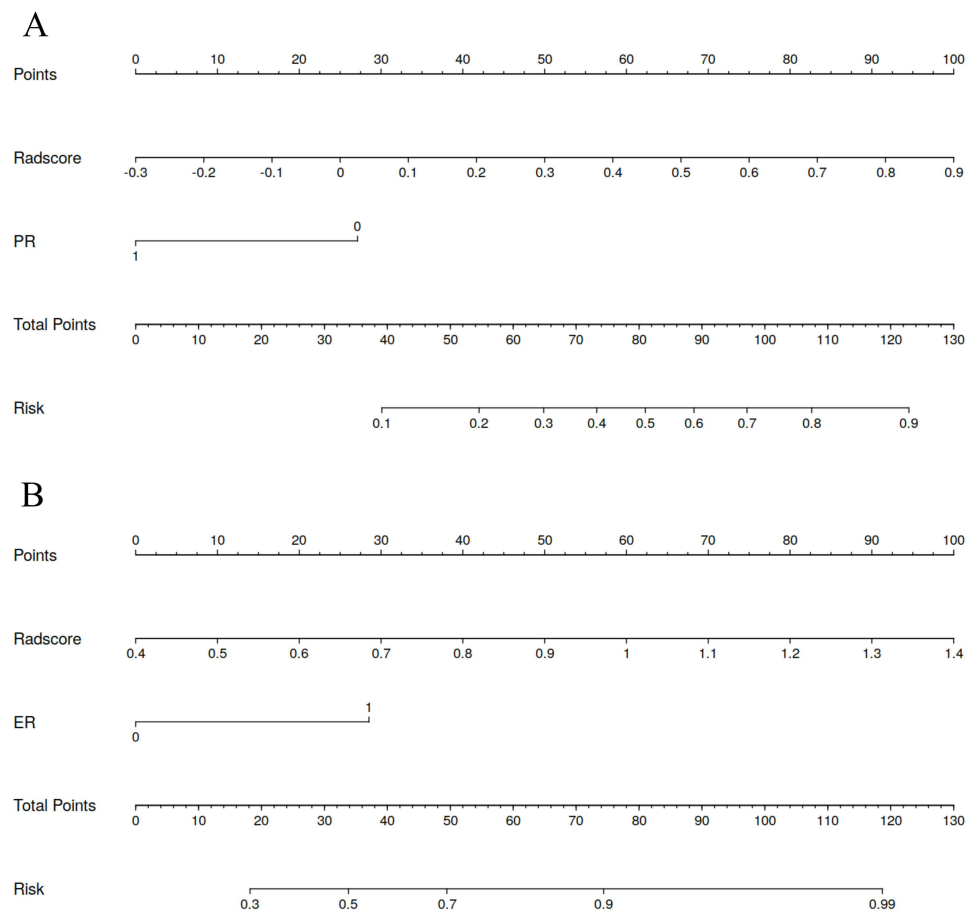
Intratumoral radiomics is one of the important indicators to predict HER-2 expression status in breast cancer. In previous studies, there is no consensus on which stage of DCE provides the best predictive performance. Compared with other imaging stages, the phase 3 DCE-MRI image has higher contrast and detail display ability in the diagnosis of breast cancer. It can more accurately evaluate the tumor boundary, provide hemodynamic information, and reflect the heterogeneity of the tumor.<sup>25</sup> The peritumoral region within a few millimeters from the tumor edge may contain significant biological activity, such as tumor invasion, angiogenesis, or immune response. A 5 mm margin might provide a sufficient number of pixels or voxels for robust radiomics feature extraction and analysis. Smaller margins might not provide enough data points for reliable statistical analysis. Previous studies have shown that MRI intratumoral and peritumoral radiomics could be used for preoperative noninvasive prediction HER-2 positive expression.<sup>26,27</sup> In the past, Li et al<sup>26</sup> built intratumoral and peritumoral radiomics models based on DCE-MRI for prediction of breast cancer HER-2 positive



**Figure 4** (A and B) are DCA curves of training set and testing set in task 1. (C and D) are DCA curves of training set and testing set in task 2.

**Abbreviation:** DCA, decision curve analysis.

and negative status, and the results of validation set showed that the combined intratumoral and peritumoral radiomics feature model (AUC = 0.713) was superior to the independent intratumoral (AUC = 0.683) and peritumoral (AUC = 0.690) feature model. The results of our study differ from it, probably because of the different methods used when constructing models and selecting features. In our study, a variety of methods were tried to construct models and select features, and it is the advantage of our study. However, little attention has been paid to the clinical value of intratumoral combined peritumoral radiomics methods in predicting HER-2 low expression status in breast cancer. Bian et al<sup>20</sup> distinguished HER-2 positive and negative based on multi-parametric MRI radiomics features and the AUC of model based on DCE-MRI radiomics features in internal and external validation set were 0.674 and 0.641. They further distinguished HER-2 low expression and zero expression and the AUC of model based on DCE-MRI radiomics features in internal and external validation set were 0.755 and 0.678. Compared with Bian,<sup>20</sup> Ramtohul et al's<sup>21</sup> study also showed



**Figure 5 (A and B)** are nomogram of clinical combined radiomics model in Task 1 and Task 2.

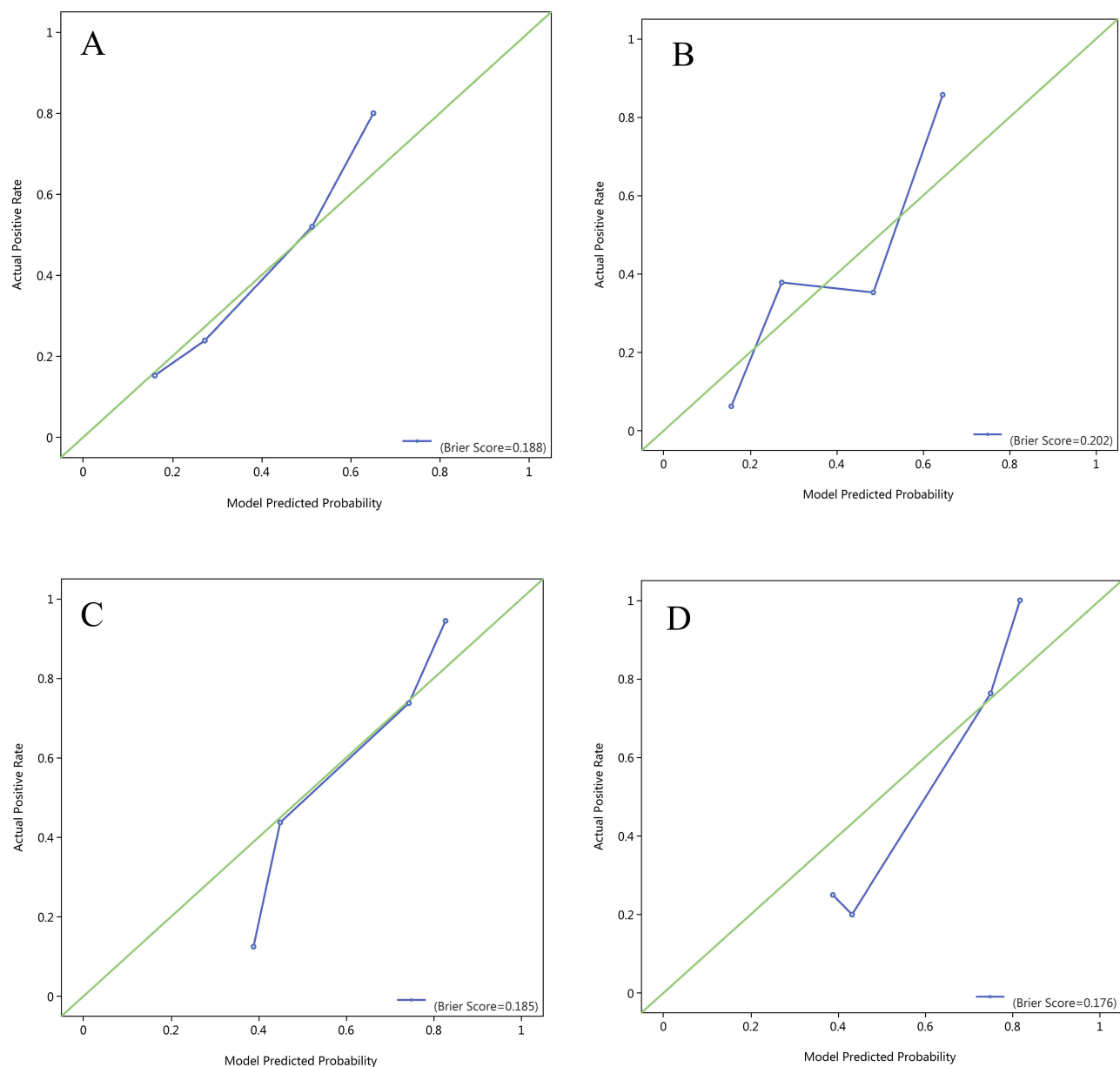
that multi-parameter MRI radiomics could predict HER-2 low, positive and zero expression in breast cancer, with AUC values of 0.800 in external validation sets. In addition, he explored multi-parameter MRI features to predict HER-2 expression status, and the AUC value was 0.770 in external validation set. Compared with their researches, we not only explored the value of intratumoral combined peritumoral radiomics in predicting HER-2 low expression but also added clinicopathological factors after single and multi-factor logistic regression analysis, which is the advantage of our study. The prediction efficacy of the clinical combined radiomics model is lower than that of the model based on intratumoral + peritumoral radiomics features, probably because the MRI features we added were not comprehensive enough. In future studies, we will collect MRI features more comprehensively and further explore the value of clinicopathological and MRI features combined with radiomics to predict HER-2 low expression.

There are some limitations in this study. It is difficult to avoid the subjective influence of the sketcher when manually sketching ROI. This study is a single-center study, and there is a lack of multi-center studies for verification. In this study,

**Table 5** Hosmer–Lemeshow Tests of Clinical Combined Radiomics Model

Model	Training Set	Testing Set
	P	P
Clinical combined radiomics (Task 1)	0.340	<b>0.003</b>
Clinical combined radiomics (Task 2)	0.070	0.487

**Note:** Bold text represents p-values < 0.05.



**Figure 6** The calibration curves for the nomogram in task 1 ((A) represents the training set; (B) represents the testing set) and task 2 ((C) represents the training set; (D) represents the testing set). The blue line represents the actual predicted performance. Perfect prediction would correspond to the 45° green line.

phase 3 DCE-MRI images were selected, mainly because breast cancer is significantly enhanced in phase 3, but it may provide different important information in other stages, which can be further explored in the future.

## Conclusion

In our study, radiomics models based on intratumoral and peritumoral DCE-MRI demonstrated the ability to noninvasively predict HER-2 expression status in breast cancer. Notably, the peritumoral radiomics model exhibited the best performance in predicting HER-2 positive expression, while the combined intratumoral and peritumoral model excelled in predicting HER-2 low expression. These findings underscore the significance of tumor heterogeneity, as intratumoral and peritumoral regions contribute uniquely to HER-2 status prediction. However, ambiguities in the interpretations of different models remain. To address these limitations, future studies should focus on enlarging the sample size and incorporating multi-center external validation to improve the reliability and clinical applicability of the models.

## Images Published Statement

Participants consented to have these images published.

## Abbreviations

DCE-MRI, dynamic contrast-enhanced magnetic resonance imaging; HER-2, human epidermal growth factor receptor-2; LASSO, least absolute shrinkage and selection operator; AUC, area under the curve; ROC, receiver operating characteristic; DCA, decision curve analysis; ASCO/CAP, American Society of Clinical Oncology/College of American Pathologists; IHC, immunohistochemistry; FISH, fluorescence in situ hybridization; MRI, Magnetic resonance imaging; ER, estrogen receptor; PR, progesterone receptor; ALN, axillary lymph nodes; BPE, background parenchymal enhancement; TIC, time-intensity curve; T1/T2WI, T1/T2-weighted imaging; DCE-T1, dynamic contrast-enhanced T1-weighted; PACS, picture archiving and communication systems; DICOM, digital imaging and communication in medicine; ROI, region of interest.

## Ethics Approval and Consent to Participate

The study was approved by the Ethics Committee of Henan Provincial People's Hospital (No: 2022-124), and the participants informed consent requirement was waived.

## Funding

This study was supported by the Medical Science and Technological Project of Henan Province (No. LHGJ20220055).

## Disclosure

The authors have no conflicts of interest to declare.

## References

1. Miller KD, Nogueira L, Devasia T, et al. Cancer treatment and survivorship statistics, 2022. *CA Cancer J Clin.* 2022;72(5):409–436. doi:10.3322/caac.21731
2. Sung H, Ferlay J, Siegel RL, et al. Global Cancer Statistics 2020: GLOBOCAN estimates of incidence and mortality worldwide for 36 cancers in 185 countries. *CA Cancer J Clin.* 2021;71(3):209–249. doi:10.3322/caac.21660
3. Wolff AC, Hammond MEH, Allison KH, et al. Human epidermal growth factor receptor 2 testing in breast cancer: American Society of Clinical Oncology/College of American Pathologists Clinical Practice Guideline Focused Update. *J Clin Oncol.* 2018;36(20):2105–2122. doi:10.1200/JCO.2018.77.8738
4. Wolff AC, Somerfield MR, Dowsett M, et al. Human epidermal growth factor receptor 2 testing in breast cancer: ASCO-College of American Pathologists Guideline Update. *J Clin Oncol.* 2023;41(22):3867–3872. doi:10.1200/JCO.22.02864
5. T-DXd: new Standard for HER2-Low Breast Cancer. *Cancer Discov.* 2022;12(8):1828. doi:10.1158/2159-8290.CD-NB2022-0043
6. Denkert C, Seither F, Schneeweiss A, et al. Clinical and molecular characteristics of HER2-low-positive breast cancer: pooled analysis of individual patient data from four prospective, neoadjuvant clinical trials. *Lancet Oncol.* 2021;22(8):1151–1161. doi:10.1016/S1470-2045(21)00301-6
7. Zhang G, Ren C, Li C, et al. Distinct clinical and somatic mutational features of breast tumors with high-, low-, or non-expressing human epidermal growth factor receptor 2 status. *BMC Med.* 2022;20(1):142. doi:10.1186/s12916-022-02346-9
8. Mittal S, Brown NJ, Holen I. The breast tumor microenvironment: role in cancer development, progression and response to therapy. *Expert Rev Mol Diagn.* 2018;18(3):227–243. doi:10.1080/14737159.2018.1439382
9. Gillies RJ, Kinahan PE, Hricak H. Radiomics: images are more than pictures, they are data. *Radiology.* 2016;278(2):563–577. doi:10.1148/radiol.2015151169
10. Xu A, Chu X, Zhang S, et al. Development and validation of a clinicoradiomic nomogram to assess the HER2 status of patients with invasive ductal carcinoma. *BMC Cancer.* 2022;22(1):872. doi:10.1186/s12885-022-09967-6
11. Morris EA, Comstock CE, Lee CH, et al. ACR BI-RADS<sup>®</sup> magnetic resonance imaging. In: *ACR BI-Radsatlas, Breast Imaging Reporting and Data System.* Reston, VA: American College of Radiology; 2013.
12. Allison KH, Hammond MEH, Dowsett M, et al. Estrogen and progesterone receptor testing in breast cancer: ASCO/CAP guideline update. *J Clin Oncol.* 2020;38(12):1346–1366. doi:10.1200/JCO.19.02309
13. Bustreo S, Osella-Abate S, Cassoni P, et al. Optimal Ki67 cut-off for luminal breast cancer prognostic evaluation: a large case series study with a long-term follow-up. *Breast Cancer Res Treat.* 2016;157(2):363–371. doi:10.1007/s10549-016-3817-9
14. Slamon DJ, Clark GM, Wong SG, Levin WJ, Ullrich A, McGuire WL. Human breast cancer: correlation of relapse and survival with amplification of the HER-2/neu oncogene. *Science.* 1987;235(4785):177–182. doi:10.1126/science.3798106
15. Slamon DJ, Leyland-Jones B, Shak S, et al. Use of chemotherapy plus a monoclonal antibody against HER2 for metastatic breast cancer that overexpresses HER2. *N Engl J Med.* 2001;344(11):783–792. doi:10.1056/NEJM200103153441101
16. Marchiò C, Annaratone L, Marques A, Casorzo L, Berrino E, Sapino A. Evolving concepts in HER2 evaluation in breast cancer: heterogeneity, HER2-low carcinomas and beyond. *Semin Cancer Biol.* 2021;72:123–135. doi:10.1016/j.semcancer.2020.02.016

17. Li C, Lu N, He Z, et al. A noninvasive tool based on magnetic resonance imaging radiomics for the preoperative prediction of pathological complete response to neoadjuvant chemotherapy in breast cancer. *Ann Surg Oncol*. 2022;29(12):7685–7693. doi:10.1245/s10434-022-12034-w
18. Wang X, Xie T, Luo J, Zhou Z, Yu X, Guo X. Radiomics predicts the prognosis of patients with locally advanced breast cancer by reflecting the heterogeneity of tumor cells and the tumor microenvironment. *Breast Cancer Res*. 2022;24(1):20. doi:10.1186/s13058-022-01516-0
19. Fang C, Zhang J, Li J, et al. Clinical-radiomics nomogram for identifying HER2 status in patients with breast cancer: a multicenter study. *Front Oncol*. 2022;12:922185. doi:10.3389/fonc.2022.922185
20. Bian X, Du S, Yue Z, et al. Potential antihuman epidermal growth factor receptor 2 target therapy beneficiaries: the role of MRI-based radiomics in distinguishing human epidermal growth factor receptor 2-low status of breast cancer. *J Magn Reson Imaging*. 2023;58(5):1603–1614. doi:10.1002/jmri.28628
21. Ramtohul T, Djerroudi L, Lissavali E, et al. Multiparametric MRI and radiomics for the prediction of HER2-zero, -low, and -positive breast cancers. *Radiology*. 2023;308(2):e222646. doi:10.1148/radiol.222646
22. Peiffer DS, Zhao F, Chen N, et al. Clinicopathologic characteristics and prognosis of ERBB2-low breast cancer among patients in the national cancer database. *JAMA Oncol*. 2023;9(4):500–510. doi:10.1001/jamaoncol.2022.7476
23. Dai LJ, Ma D, Xu YZ, et al. Molecular features and clinical implications of the heterogeneity in Chinese patients with HER2-low breast cancer. *Nat Commun*. 2023;14(1):5112. doi:10.1038/s41467-023-40715-x
24. Hu XE, Yang P, Chen S, et al. Clinical and biological heterogeneities in triple-negative breast cancer reveals a non-negligible role of HER2-low. *Breast Cancer Res*. 2023;25(1):34. doi:10.1186/s13058-023-01639-y
25. Liu J, Sun D, Chen L, et al. Radiomics analysis of dynamic contrast-enhanced magnetic resonance imaging for the prediction of sentinel lymph node metastasis in breast cancer. *Front Oncol*. 2019;9:980. doi:10.3389/fonc.2019.00980
26. Li C, Song L, Yin J. Intratumoral and peritumoral radiomics based on functional parametric maps from breast DCE-MRI for prediction of HER-2 and Ki-67 status. *J Magn Reson Imaging*. 2021;54(3):703–714. doi:10.1002/jmri.27651
27. Song L, Li C, Yin J. Texture analysis using semiquantitative kinetic parameter maps from DCE-MRI: preoperative prediction of HER2 status in breast cancer. *Front Oncol*. 2021;11:675160. doi:10.3389/fonc.2021.675160

## Breast Cancer: Targets and Therapy

Dovepress

### Publish your work in this journal

Breast Cancer - Targets and Therapy is an international, peer-reviewed open access journal focusing on breast cancer research, identification of therapeutic targets and the optimal use of preventative and integrated treatment interventions to achieve improved outcomes, enhanced survival and quality of life for the cancer patient. The manuscript management system is completely online and includes a very quick and fair peer-review system, which is all easy to use. Visit <http://www.dovepress.com/testimonials.php> to read real quotes from published authors.

Submit your manuscript here: <https://www.dovepress.com/breast-cancer—targets-and-therapy-journal>