





Combined Abrocitinib and Acitretin Therapy for Darier's Disease: A Case Report

Hui Ye ^{1,2,*}, Weifeng Chen ^{1,2,*}, Wenyan Liu ^{1,2}, Junhui Zhu ^{1,2}, Jingyao Liang ^{1,2}, Xibao Zhang ^{1,2}

¹Institute of Dermatology, Guangzhou Medical University, Guangzhou, Guangdong, 510095, People's Republic of China; ²Department of Dermatology, Guangzhou Dermatology Hospital, Guangzhou, Guangdong, 510095, People's Republic of China

*These authors contributed equally to this work

Correspondence: Jingyao Liang; Xibao Zhang, Guangzhou Dermatology Hospital, No. 56 hengfu Road, Guangzhou, 510095, People's Republic of China, Email lly20221228@163.com; gzpbfzs@163.com

Abstract: Darier's disease (DD) is a rare chronic keratinizing skin disease characterized by dyskeratosis of epidermal cells. We report a case of DD with a medical history spanning over 20 years and recurring symptoms. Pathologically confirmed DD was treated with a combination of abrocitinib and acitretin, resulting in rapid symptom resolution within 2 weeks. No recurrence was noted in an 11-week follow-up. The mechanism may involve acitretin's inhibition of proliferation and anti-inflammation, while abrocitinib acts on IL-6 implicated in DD pathogenesis, exerting an immunomodulatory and anti-inflammatory effect, leading to rapid symptom relief. The combination of abrocitinib and acitretin is an effective therapy for DD, offering a promising new option for refractory patients.

Keywords: keratosis follicularis, Darier's disease, abrocitinib, acitretin

Introduction

Darier's disease (DD), also referred to as Keratosis Follicularis, is an autosomal dominant genetic disorder with a prevalence rate ranging from 1 in 300,000 to 100,000. It exhibits no significant sex difference.^{1,2} DD typically manifests in childhood, persisting through puberty, presenting with various clinical features, including scales, plaques, scabs, palmoplantar keratoma, and fragile fingernails and toenails.² DD may be accompanied by non-cutaneous symptoms, including mental aspects such as mental retardation, epilepsy, or bipolar disorder.² Various treatment modalities are available for DD. To date, several conventional treatments have been reported, but long-term remission of the disease is difficult to achieve. Topical corticosteroids have poor therapeutic effects and are prone to recurrence after discontinuation.³ Systemic Acitretin is among the treatment options, exhibiting a certain therapeutic effect, albeit with individual variations.¹ Ablative therapies (dermabrasion, CO2 laser, Er: YAG laser) are effective but limited by the size of the areas that can be treated.⁴ Intermittent courses of therapy or long-term maintenance may be required in the management of DD. Abrocitinib, a highly selective JAK1 inhibitor, demonstrates immunomodulatory and anti-inflammatory effects.

Case Presentation

A 32-year-old female presented with follicular papules on the head, neck, upper limbs, and trunk, along with oil scabs persisting for 20 years. Two decades ago, the patient initiated the development of craniofacial papules and oil scabs, progressively extending to the trunk and upper limbs. This condition, marked by itching, underwent repetitive symptomatic treatment involving both traditional Chinese and Western medicine. Despite recurrent symptoms, there was no evident growth and development, no mental abnormalities, and no comparable family medical history. Physical examination revealed irregular follicular papules conglomerating on the scalp, face, neck, and trunk, along with surface oil scabs. Brown papules and nodules were dispersed on the back and vulva of both hands, accompanied by irregular white longitudinal lines on the fingernails and triangular defects on the free edge of the nails (Figure 1, a1–e1). To rule

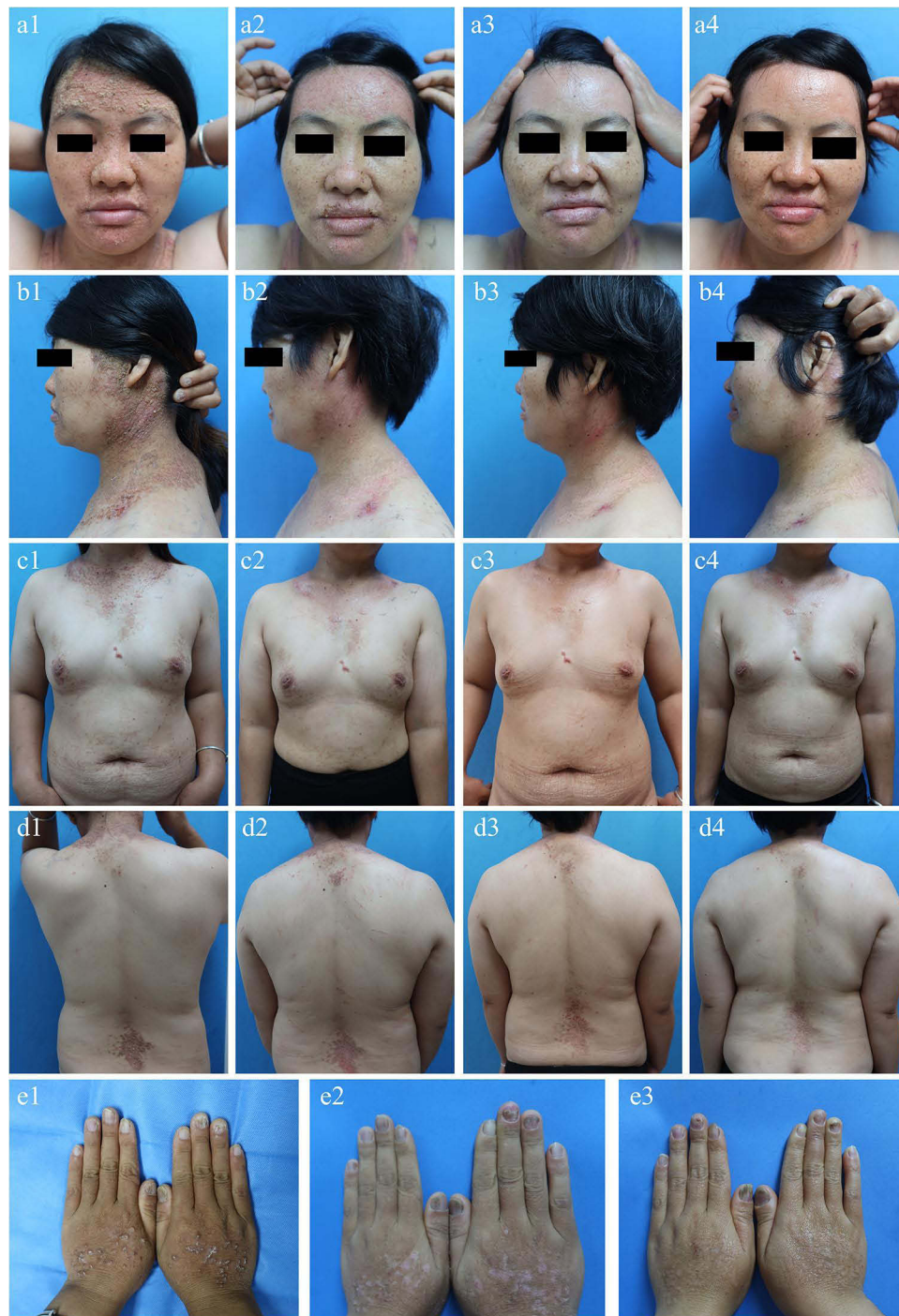


Figure 1 A 32-year-old female presented with before abrocitinib and Acitretin treatment (**a1–e1**); keratinized papules and oil scabs on the face, neck, and trunk disappeared, and local erythema and brown papules on the back of both hands flattened 2 weeks after treatment (**a2–e2**); the erythema area was reduced compared to baseline 6 weeks after treatment (**a3–d3**); a significant reduction in erythema was observed, with slight discoloration 11 weeks after treatment (**a4–d4, e3**).

out secondary causes of DD, a series of examinations were conducted, including complete blood count, liver and kidney function tests, fasting sugar levels, thyroid function tests, hormone level examination, tumor marker examination and anti nuclear antibody test. All the reports were found within normal limits. Microscopic examination revealed complete pathology, including hyperkeratosis, dyskeratosis, corps ronds and grains, acantholysis, and superficial and middle dermis lymphocyte infiltration (Figure 2).

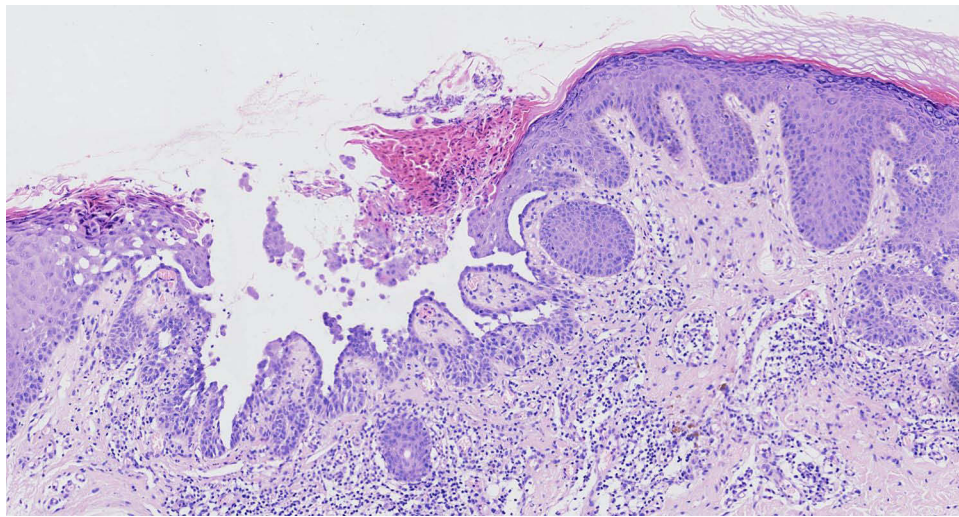


Figure 2 Histopathological examination revealed hyperkeratosis, dyskeratosis, corps ronds and grains, acantholysis, as well as lymphocyte infiltration in the superficial and middle dermis. (HE, $\times 100$).

Based on clinical manifestations, physical examination, and pathology, a diagnosis of DD was made. Treatment commenced with abrocitinib 100mg qd in conjunction with acitretin 20mg bid. Following 2 weeks of treatment, keratinized papules and oil scabs on the face, neck, and trunk vanished. Local erythema and brown papules on the back of both hands flattened, with mild dryness noted on the lips (Figure 1, a2–e2). Subsequently, acitretin dosage was adjusted to 20mg qd, while abrocitinib continued at 100mg qd. At the 6-week mark, the erythema area on the face, neck, and trunk reduced compared to the initial state. Keratinizing papules and oil scabs showed no recurrence, and hand papules flattened (Figure 1, a3–d3). At the 11-week mark, the majority of erythema and papules on the face, neck, trunk, and back of the hand had subsided, with no presence of oil scabs (Figure 1, a4–d4, e3). Consequently, abrocitinib was adjusted to 100mg qod, while acitretin continued at 20mg qd for maintenance treatment.

Discussion

DD results from an ATP2A2 mutation. The ATP2A2 gene is located at 12q23–24.1 on chromosome 12, encoding sarco/endoplasmic reticulum ATPase type 2 (SERCA2).² SERCA2 is responsible for transporting Ca^{2+} from the cytoplasm to the endoplasmic reticulum cavity, where Ca^{2+} is stored at a higher concentration.^{5,6} However, the response of the mechanism underlying epidermal keratinocyte division and dyskeratosis to calcium homeostasis remains unclear. The elevation of serum IL-6 levels is a contributing factor to the exacerbation of DD in patients. IL-6 downregulates ATP2A2 mRNA levels in differentiated keratinocytes.^{7,8} Adding anti-IL-6 antibodies to undifferentiated keratinocytes could alleviate the inhibition of ATP2A2 and ATP2C1 mRNA levels induced by ultraviolet radiation B.⁹

Treatment for DD typically involves retinoids, immunosuppressants, steroids, vitamin D analogues, photodynamic therapy, and surgical resection. Acitretin is a viable option for treating DD. Metabolites of acitretin bind to retinoic acid receptors, resulting in the alteration of gene transcription through response elements. This leads to antiproliferative and anti-inflammatory effects. In keratosis, acitretin stimulates differentiation and normalizes the accelerated epidermopoiesis of pathological epidermis. Additionally, it inhibits the production of vascular endothelial growth factor by keratinocytes.¹⁰ An initial dose of acitretin, ranging from 25–35mg per day, has been recommended for treating various keratosis disorders. The dose is then gradually adjusted to the optimal treatment level for individual patients. However, there are also related literature reports where some patients increased the dose to 45 mg, and even 60 mg daily, yet disease control remains poor, and pruritus is not significantly improved.¹¹

Abrocitinib is a highly selective oral JAK1 inhibitor. JAK1 is involved in signaling downstream of cytokines that utilize the γc receptor subunit, including IL-2, IL-4, IL-7, IL-9, IL-15, and IL-21. It regulates a key group of pro-inflammatory

cytokines, including IL-6, and others that utilize the gp130 subunit, such as IL-11. Moreover, in T cells, IL-6 activation of STAT1, as well as cytokine activation of STAT pathways, is dependent on JAK1.¹²

IL-6 plays a role in DD. IL-6 is produced by various cell types, including antigen-presenting cells, namely macrophages, dendritic cells, and B cells. Elevated IL-6 expression is associated with the disruption of the skin barrier, which functions as a water regulator and permeability barrier in keratinocytes.¹³ IL-6 mediates the activation of nuclear factors in activated T cells, leading to the production of IL-4 by naive CD4⁺ T cells, resulting in their differentiation into effector Th2 cells. Simultaneously, IL-6 interferes with the development of Th1 cells by upregulating the expression of cytokine signal transduction inhibitor 1, thereby inhibiting the differentiation of Th1 cells.¹⁴ Considering IL-6 is associated with the activation of Th2 and Th1, intervening in IL-6 mediation implicated in DD may contribute to treatment. Abrocitinib can inhibit IL-31 by up to 85%, achieve peak blood concentration within 1 hour, and exhibit a rapid antipruritic effect.¹⁵ The potential mechanism underlying the use of abrocitinib in treatment is its ability to reduce inflammation through immunomodulatory and anti-inflammatory properties.

This study has the following limitations: Firstly, the diagnosis of Darier's disease in this setting lacks whole-genome sequencing or targeted sequencing to identify ATP2A2 mutations. In addition, the study lacked a comparative analysis to determine whether the observed improvement was due to acitretin alone, abrocitinib alone, or the combination therapy. Finally, follow-up period for this case was limited to 11 weeks lacking long-term effective observations.

Conclusion

Although specific research on the precise mechanism of abrocitinib in Darier's disease is lacking, our study offers clinicians new options and perspectives for drug selection and treatment strategies.

Data Sharing Statement

No datasets were generated or analyzed during the current study.

Consent for Publication

We have confirmed with the patients that the details of any images, videos, recordings, etc can be published, and that the person(s) providing consent have been shown the article contents to be published. The Medical Ethics Committee of Guangzhou Dermatology Hospital has granted ethical approval for this study to publish case details (No. gzsps202474).

Acknowledgments

The authors express their sincere appreciation to the referenced studies and consortiums for generously providing open access datasets for our analysis.

Disclosure

The authors report no conflicts of interest in this work.

References

1. Hanna N, Lam M, Fleming P, et al. Therapeutic Options for the Treatment of Darier's Disease: a Comprehensive Review of the Literature. *J Cutan Med Surg.* 2022;26(3):280–290. doi:10.1177/12034754211058405
2. Takagi A, Kamijo M, Ikeda S. Darier disease. *J Dermatol.* 2016;43(3):275–279. doi:10.1111/1346-8138.13230
3. Rogner DF, Lammer J, Zink A, et al. Darier and Hailey-Hailey disease: update 2021. *J Dtsch Dermatol Ges.* 2021;19(10):1478–1501. doi:10.1111/ddg.14619
4. Gao T, Xiao J, Pan N, et al. ALA-PDT combined with 2940 nm ablative fractional Er:YAG laser for Darier's disease. *Photodiagnosis Photodyn Ther.* 2024;45:103892. doi:10.1016/j.pdpdt.2023.103892
5. Liu X, O'Connell A, Ambudkar IS. Ca²⁺-dependent inactivation of a store-operated Ca²⁺ current in human submandibular gland cells. Role of a staurosporine-sensitive protein kinase and the intracellular Ca²⁺ pump. *J Biol Chem.* 1998;273(50):33295–33304. doi:10.1074/jbc.273.50.33295
6. Savignac M, Edir A, Simon M, et al. Darier disease: a disease model of impaired calcium homeostasis in the skin. *Biochim Biophys Acta.* 2011;1813(5):1111–1117. doi:10.1016/j.bbamcr.2010.12.006
7. Mayuzumi N, Ikeda S, Kawada H, et al. Effects of ultraviolet B irradiation, proinflammatory cytokines and raised extracellular calcium concentration on the expression of ATP2A2 and ATP2C1. *Br J Dermatol.* 2005;152(4):697–701. doi:10.1111/j.1365-2133.2005.06383.x

8. Mayuzumi N, Ikeda S, Kawada H, et al. Effects of drugs and anticytokine antibodies on expression of ATP2A2 and ATP2C1 in cultured normal human keratinocytes. *Br J Dermatol.* 2005;152(5):920–924. doi:10.1111/j.1365-2133.2005.06394.x
9. Yamamoto T, Aoyama Y. Role of pro-inflammatory cytokines in the pathophysiology of herpes simplex virus superinfection in Darier's disease. *J Dermatol.* 2021;48(10):1607–1611. doi:10.1111/1346-8138.16097
10. Sarkar R, Chugh S, Garg VK. Acitretin in dermatology. *Indian J Dermatol Venereol Leprol.* 2013;79(6):759. doi:10.4103/0378-6323.120721
11. van Dooren-Greebe RJ, van de Kerkhof PC, Happle R. Acitretin monotherapy in Darier's disease. *Br J Dermatol.* 1989;121(3):375–379. doi:10.1111/j.1365-2133.1989.tb01432.x
12. Spinelli FR, Colbert RA, Gadina M. JAK1: number one in the family; number one in inflammation? *Rheumatology.* 2021;60(Suppl 2):ii3–ii10. doi:10.1093/rheumatology/keab024
13. Lee KS, Chun SY, Lee MG. The prevention of TNF- α /IFN- γ mixture-induced inflammation in human keratinocyte and atopic dermatitis-like skin lesions in Nc/Nga mice by mineral-balanced deep seawater. *Biomed Pharmacother.* 2018;97:1331–1334. doi:10.1016/j.biopha.2017.11.056
14. Meng JH, Li YQ, Fischer MJM, et al. Th2 Modulation of Transient Receptor Potential Channels: an Unmet Therapeutic Intervention for Atopic Dermatitis. *Front Immunol.* 2021;12:696784. doi:10.3389/fimmu.2021.696784
15. Gooderham MJ, Forman SB, Bissonnette R, et al. Efficacy and safety of oral Janus kinase 1 inhibitor abrocitinib for patients with atopic dermatitis: a Phase 2 randomized clinical trial. *JAMA Dermatol.* 2019;155(12):1371–1379. doi:10.1001/jamadermatol.2019.2855

Clinical, Cosmetic and Investigational Dermatology

Dovepress

Publish your work in this journal

Clinical, Cosmetic and Investigational Dermatology is an international, peer-reviewed, open access, online journal that focuses on the latest clinical and experimental research in all aspects of skin disease and cosmetic interventions. This journal is indexed on CAS. The manuscript management system is completely online and includes a very quick and fair peer-review system, which is all easy to use. Visit <http://www.dovepress.com/testimonials.php> to read real quotes from published authors.

Submit your manuscript here: <https://www.dovepress.com/clinical-cosmetic-and-investigational-dermatology-journal>