

Predictive Value of Plasma D-Dimer for Cerebral Herniation Post-Thrombectomy in Acute Ischemic Stroke Patients

Wensheng Zhang^{1,2,*}, Weifang Xing^{1,*}, Jiyun Feng^{3,*}, Yangchun Wen¹, Xiaojing Zhong¹, Li Ling^{2,4}, Jinzhao He^{1,5}

¹Department of Neurology, Heyuan People's Hospital, Guangdong Provincial People's Hospital Heyuan Hospital, Heyuan, People's Republic of China; ²Department of Neurology, Shenzhen Hospital, Southern Medical University, Shenzhen, People's Republic of China; ³Department of Neurology, Lianzhou People's Hospital, Lianzhou, People's Republic of China; ⁴The Third School of Clinical Medicine, Southern Medical University, Guangzhou, People's Republic of China; ⁵Heyuan Key Laboratory of Molecular Diagnosis & Disease Prevention and Treatment, Doctors Station of Guangdong Province, Heyuan People's Hospital, Heyuan, People's Republic of China

*These authors contributed equally to this work

Correspondence: Jinzhao He, Department of Neurology, Heyuan People's Hospital, Guangdong Provincial People's Hospital, No. 733 Wenxiang Road, Yuancheng District, Heyuan City, Guangdong Province, 517000, People's Republic of China, Email hejinzhao2019@163.com; Li Ling, Department of Neurology, Shenzhen Hospital, Southern Medical University, The Third School of Clinical Medicine, Southern Medical University, 1333 Xinhua Road, Bao'an District, Shenzhen, Guangdong Province, 518101, People's Republic of China, Email linglirabbit@163.com

Background: Cerebral hernia is a serious complication after thrombectomy in patients with acute ischemic stroke (AIS). This study aims to explore the predictive value of emergency preoperative plasma D-dimer levels in cerebral herniation after successful thrombectomy.

Methods: Between January 2019 and December 2023, patients with AIS who received a successful thrombectomy in our single comprehensive stroke center were retrospectively enrolled. We conducted a statistical analysis on the data using SPSS 26.0. Receiver operating characteristic curve (ROC) was used to evaluate the predictive value of D-dimer level for cerebral herniation.

Results: Among 278 enrolled patients, 20 cases (7.19%) experienced cerebral herniation. In patients with cerebral hernia, the score of the National Institutes of Health Stroke Scale was higher (16.5 vs 12.0, $P < 0.001$), the Alberta Stroke Plan early CT score was lower (6.5 vs 8.0, $P < 0.001$), the score of collateral circulation was lower (2.0 vs 3.0, $P < 0.001$), the proportion of eTICI blood flow grading of 3 of the occluded vessel was less (35% vs 75.19%), the proportion of pathogenesis of large atherosclerosis was less (5.00% vs 46.51%, $P < 0.001$), and the level of plasma D-dimer was higher (2.61 vs 0.82). After adjusting for potential confounders, the level of D-dimer (adjusted OR = 1.131, 95% CI 1.022–1.250, $P = 0.017$) was significantly correlated with cerebral hernia. Based on the ROC curve, the sensitivity and specificity of D-dimer in predicting cerebral herniation were 75.0% and 73.3%, respectively, and the area under the curve was 0.766.

Conclusion: Although our study had certain limitations, we found that elevated emergency preoperative plasma D-dimer level is an independent predictive factor for the cerebral herniation after successful thrombectomy in patients with AIS, which is of great clinical significance.

Keywords: plasma D-dimer, acute cerebral infarction, thrombectomy, cerebral herniation

Introduction

Thrombectomy is one of the most important treatment methods for patients with AIS.¹ Cerebral herniation is a fatal complication after thrombectomy. Cerebral herniation is often more severe than malignant brain edema and symptomatic cerebral hemorrhage, which can seriously affect the efficacy of thrombectomy and is one of the influencing factors with a higher proportion of futile recanalization.^{2–6} The main type of cerebral herniation after thrombectomy for AIS due to anterior circulation occlusion is cerebral falx hernia.⁷ In clinical practice, it is very necessary to discover laboratory

indicators that can predict cerebral herniation early before thrombectomy, develop appropriate surgical plans, optimize postoperative management strategies and continuously improve the efficacy of thrombectomy.

Plasma D-dimer is a product of fibrinogen degradation, and its content is within a certain range in healthy individuals. However, its content significantly elevates during thrombosis, high fibrinolysis and infection.^{8,9} Elevated plasma D-dimer has been proven to be associated with pulmonary embolism, deep vein thrombosis, acute myocardial infarction and active cancer.⁸⁻¹² Plasma D-dimer has also been found to be an independent predictor of symptomatic bleeding transformation after mechanical thrombectomy for anterior circulation large vessel occlusion.¹³ A retrospective study by Hisamitsu Y et al¹⁴ found that patients with acute cerebral infarction due to large blood vessel occlusion and received mechanical thrombectomy who had a high value of D-dimer at admission may have a poor prognosis. A retrospective study by Ohbuchi H et al¹⁵ found that the plasma D-dimer level before mechanical thrombectomy could predict the success rate and outcome of patients in mechanical thrombectomy in acute cerebral infarction with large vessel occlusion. A study by Xie T et al¹⁶ explored whether the emergency admission plasma D-dimer level could predict the first pass effect of stent thrombectomy in the treatment of acute ischemic stroke and found that a lower emergency admission plasma D-dimer level was an independent predictor of the first-pass effect in patients undergoing stent thrombectomy. In addition, studies have found that elevated plasma D-dimer can predict the presence of acute cerebral infarction with large vessel occlusion.¹⁷ Considering the association between plasma D-dimer and large vessel occlusion and its independent correlation with symptomatic bleeding transformation after mechanical thrombectomy of occluded cerebral blood vessels. At the same time, previous studies had confirmed that plasma D-dimer can predict the success rate, outcome and first pass effect of mechanical thrombectomy for acute cerebral infarction with large vessel occlusion. It is possible that plasma D-dimer is associated with the formation of cerebral herniation after mechanical thrombectomy. Therefore, we believe it is necessary to explore the relationship between plasma D-dimer and the formation of cerebral herniation after mechanical thrombectomy. At present, there is no research using emergency preoperative plasma D-dimer or other laboratory indicators to predict cerebral herniation after successful thrombectomy. Our study aimed to explore whether emergency preoperative plasma D-dimer can effectively predict cerebral herniation after successful thrombectomy.

Materials and Methods

Study Population

Data of patients diagnosed with AIS admitted to our single comprehensive stroke center and received successful thrombectomy from January 2019 to December 2023 was retrospectively collected. All data is obtained from the clinical medical record system. This study plan had been approved by the Medical Ethics Committee of Heyuan People's Hospital. Considering that this study collected medical record data and conducted retrospective analysis and did not intervene patients' treatment plan, the Medical Ethics Committee of Heyuan People's Hospital approved the exemption of informed consent for this study.

The inclusion criteria for this study were as follows: (1) preoperative Computed Tomography (CT) angiography or Magnetic Resonance (MR) angiography confirmed occlusion of large anterior circulation vessels, including the internal carotid artery, M1 segment of the middle cerebral artery, M2 segment of the middle cerebral artery and A1 segment of the anterior cerebral artery; (2) At the onset of the disease, National Institute of Health stroke scale (NIHSS) score ≥ 6 points; (3) The Alberta Stroke Program Early CT (ASPECT) score of preoperative cranial CT ≥ 6 points; (4) Age ≥ 18 years old; (5) modified Rankin scale (mRS) score before onset ≤ 2 points; (6) Time from onset to femoral artery puncture < 24 hours; (7) The patient's family members signed and agreed to undergo thrombectomy. Exclusion criteria included: (1) Acute cerebral infarction with posterior circulation occlusion of large blood vessels; (2) Prior to collecting blood samples, intravenous thrombolysis was administered to the external hospitals; (3) mRS score before onset > 2 points; (4) Diseases that may affect plasma D-dimer levels, such as acute myocardial infarction, deep vein thrombosis, pulmonary thromboembolism and active cancer prior to onset; (5) Plasma D-dimer was not tested before emergency thrombectomy; (6) Instability of vital signs at onset of illness.

Detection of Plasma D-Dimer

For all patients that may be diagnosed with AIS, routine coagulation function tests should be performed during emergency visits. If the patient received intravenous thrombolysis treatment, blood samples should be collected before intravenous thrombolysis. Peripheral venous blood should be taken from each patient and placed in a blood collection tube containing sodium citrate as an anticoagulant. Plasma was centrifuged at 3000 rpm for 10 minutes. The detection of plasma D-dimer was carried out using an automated biochemical detector using immunoturbidimetric assay (Stago Emo Express, manufacturer: Stago, France). The detection results of plasma D-dimer can be obtained within 30 minutes after blood collection. According to the current standards of multicenter prospective studies and clinical trials, elevation of D-dimer was defined as $\geq 0.5\text{mg/L}$.¹⁸

Methods of Thrombectomy

According to the existing guidelines and thrombectomy techniques for the treatment of AIS,^{19,20} if the patient's time from onset to hospital was less than 4.5 hours and there were no contraindications for intravenous thrombolysis, with the patient or family member's signed consent, alteplase intravenous thrombolysis treatment can be used. After imaging evaluation, it was found that there was still a salvageable ischemic penumbra in AIS with anterior circulation occlusion. After the patient's family signed and agreed to undergo thrombectomy, treatment was carried out under local anesthesia and sedation. If the patient's condition required, tracheal intubation and general anesthesia can be administered. The neurointerventional physician selected one or more methods for thrombectomy, including stent thrombectomy, thrombus aspiration, balloon dilation, stent implantation, and intra-arterial use of tirofiban, based on the patient's location, pathogenesis and pathway of the lesion. The thrombectomy stents we used included Solitaire AB, RECO and TREVO. The suction catheters we used included Sofia, ACE Penumbra, and Tianxun distal pathway catheters. The balloon we used was the Gateway balloon dilation catheter. The carotid artery stent we used was the Protege stent. The intracranial stent we used was the Apollo intracranial stent. Extended thrombolysis in cerebral infarction (eTICI) blood flow grading was used to evaluate the situation of occluded vessel recanalization, grades 0 to 2a were defined as recanalization failure, and grades 2b to 3 were defined as successful interventional recanalization.

Assessment of Cerebral Herniation Formation

Non-enhanced CT examination should be performed immediately and 24 hours after thrombectomy routinely. Non-enhanced CT or MR should be re-examined based on the patient's condition from 24 hours to 72 hours after thrombectomy. If the patient's condition worsened, cranial CT should be re-examined immediately. Referring to the definition of cerebral herniation that of existing studies,^{6,7} our study's diagnosis criteria of cerebral hernia should meet the following conditions simultaneously: (1) The patient's symptoms worsen, the NIHSS score increased by ≥ 2 points of all evaluation section, or the NIHSS score increased by ≥ 1 point in the consciousness evaluation section, and physical examination revealed unequal pupil size on both sides; (2) Swelling of brain parenchyma, compression of lateral ventricle and space occupying effect can be found; (3) The sulcus and gyrus of the brain became shallow or disappeared; (4) Middle line displacement of the brain and brain tissue.

Cerebral herniation was evaluated by two neuroradiologists who were unaware of the patient's laboratory test results on imaging data. If there was any disagreement between the two evaluators, another experienced neuroradiologist will re-evaluate the patient's imaging data and ultimately reached a consensus.

Patient and Public Involvement

Patients or the public WERE NOT involved in the design or conduct, or reporting, or dissemination plans of our research.

Statistical Analysis

Continuous data were expressed as mean \pm standard deviation or median (interquartile range). Continuous data that conformed to normal distribution was analyzed using Student's test, while continuous data that did not conform to normal distribution was analyzed using Mann-Whitney *U*-test. The categorical data were expressed in frequency and

percentage, and statistical analysis was conducted using X^2 test. The predictive factors ($P < 0.05$) found in univariate analysis related to cerebral herniation formation were included into univariate and multivariate logistic regression analysis to determine independent predictive factors. The forest map of the meaning risk factors of cerebral herniation in multivariate logistic regression analysis was drawn. Simultaneously, the cutoff value, sensitivity and specificity of the predictive indicators were determined using the ROC. Statistical analysis was conducted using SPSS 26.0 software.

Results

This study included a total of 278 patients diagnosed with AIS due to anterior circulation large vessel occlusion and received successful thrombectomy. The research flowchart is shown in [Figure 1](#). The average age of all patients was 66.59 ± 11.64 years, with 189 males (66.19%) and 20 patients (7.19%) receiving intravenous thrombolysis. At the time of onset, the median NIHSS score was 12.00 (IQR 10.00–16.00), and the median ASPECT score was 7.00 (IQR 7.00–9.00). The average level of D-dimer was 0.90 (IQR 0.46–2.07) mg/L. In terms of the pathogenesis of cerebral infarction, 121 cases (43.53%) were large atherosclerosis (LAA), 91 cases (32.73%) were cardiogenic embolism and 66 cases (23.74%) were other causes.

Twenty patients (7.19%) experienced cerebral herniation after successful thrombectomy. Patients with cerebral hernia had a higher NIHSS score (16.5 vs 12.0, $P < 0.001$), a lower ASPECT score (6.5 vs 8.0, $P < 0.001$), a higher proportion of patients receiving intravenous thrombolysis (60.0% vs 3.10%, $P = 0.044$), a lower collateral circulation score of American Society of Interventional and Therapeutic Neuroradiology/Society of Interventional Radiology (ASTIN/SIR) (2.0 vs 3.0, $P < 0.001$), less use of tirofiban in arteries (5% vs 25.19%), less proportion of recanalized blood flow eTICI grading 3 (35.00% vs 75.19%), less pathogenesis of large atherosclerosis (5.00% vs 46.51%, $P < 0.001$), and emergency preoperative plasma D-dimer levels were higher (2.61 vs 0.82, $P < 0.001$). There was no statistical difference between the two groups in terms of other baseline data. The baseline clinical data of patients with cerebral hernia and those without cerebral hernia are shown in [Table 1](#).

The indicators with statistical differences in X^2 test, Student's test, or Mann–Whitney U -test were included in univariate and multivariate logistic regression analysis. After adjusting for potential confounders, preoperative ASPECT score (aOR = 0.392; 95% Confidence interval (CI) 0.168–0.915), recanalized blood flow eTICI grading 3 (aOR = 0.275; 95% CI 0.085–0.893), pathogenesis of cardioembolic stroke (aOR = 9.586; 95% CI 1.085–84.668), pathogenesis of other etiologies (aOR = 12.215; 95% CI 1.172–127.271), and emergency preoperative plasma D-dimer (aOR = 0.131; 95% CI 1.022–1.250) were significantly associated with the formation of cerebral herniation after successful thrombectomy in

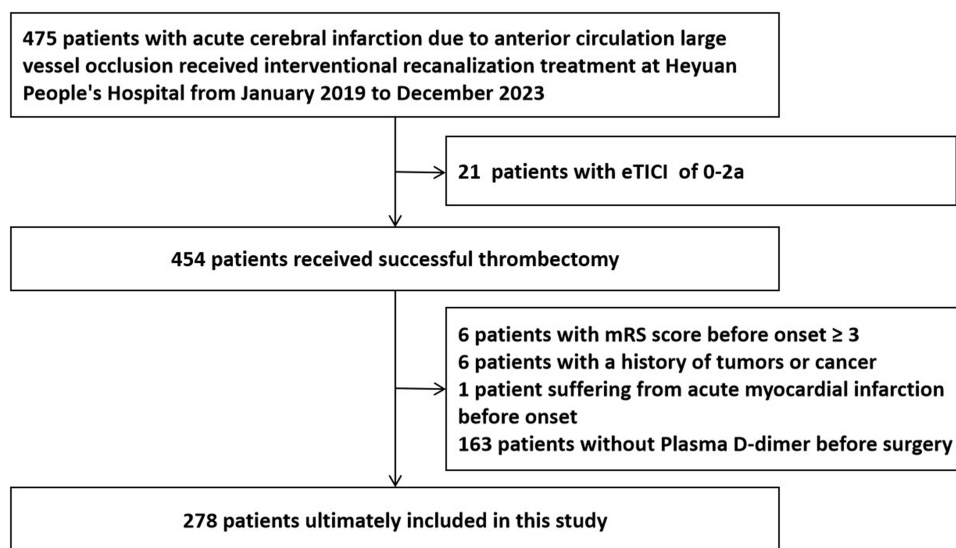


Figure 1 Research flowchart of our study.

Abbreviations: eTICI, extended thrombolysis in cerebral infarction; mRS, modified Rankin Scale.

Table 1 Univariate Analysis of Patients Suffered from Cerebral Herniation After Successful Thrombectomy with AIS Due to Anterior Circulation Occlusion of Large Blood Vessels

Variables	All Patients (n=278)	Cerebral Hernia (n=20)	No Cerebral Hernia (n=258)	P Value
Age, years, (mean ± standard deviation)	66.59±11.64	69.50±11.00	66.36±11.68	0.256
Gender, Male, n (%)	184(66.19)	15(75.00)	169(65.50)	0.387
Medical History				
Hypertension, n (%)	145(52.16)	13(65.00)	132(51.16)	0.233
Diabetes, n (%)	55(19.78)	2(10.00)	53(20.54)	0.254
Cerebral infarction, n (%)	41(14.75)	2(10.00)	39(15.12)	0.534
Coronary heart disease, n (%)	40(14.39)	5(25.00)	35(13.57)	0.160
Atrial fibrillation, n (%)	59(21.22)	7(35.00)	52(20.16)	0.118
Smoking, n (%)	110(39.57)	10(50.00)	100(38.76)	0.322
Drinking, n (%)	63(22.66)	6(30.00)	57(22.09)	0.416
mRS score before onset, (mean ± standard deviation)	0.10±0.42	0.15±0.49	0.10±0.42	0.559
The situation at the onset of stroke				
NIHSS score at onset, median (IQR)	12.00(10.00–16.00)	16.50(12.5–17.75)	12.00(9.00–15.00)	<0.001
Preoperative ASPECT score, median (IQR)	7.00(7.00–9.00)	6.50(6.00–7.00)	8.00(7.00–9.00)	<0.001
Received intravenous thrombolysis treatment, n (%)	20(7.19)	12(60.00)	8(3.10)	0.044
Location of occluded blood vessels, n (%)				0.814
M1 segment of middle cerebral artery	125(44.96)	7(35.00)	118(45.74)	
Middle cerebral artery M2 segment	20(7.19)	1(5.00)	19(7.36)	
Internal carotid artery	38(13.67)	4(20.00)	34(13.18)	
Anterior cerebral artery	1(0.36)	0(0)	1(0.39)	
Anterior circulation tandem lesion	94(33.81)	8(40.00)	86(33.33)	
Collateral circulation score of ASTIN/SIR, median (IQR)	3.00(2.00–3.00)	2.00(1.00–2.00)	3.00(2.00–3.00)	<0.001
Intraarterial use of tirofiban injection, n (%)	66(23.74)	1(5.00)	65(25.19)	0.041
eTICI grading, n (%)				0.001
2b	59(21.22)	10(50.00)	49(18.99)	
2c	18(6.47)	3(15.00)	15(5.81)	
3	201(72.30)	7(35.00)	194(75.19)	
Time nodes				
Time from admission to femoral artery puncture, min, median (IQR)	121.00(97.75–157.75)	127.50(84.25–142.50)	120.50(97.75–162.00)	0.445
Time from puncture to recanalization of occluded blood vessel, min, median (IQR)	95.00(73.75–128.25)	101.50(76.25–130.00)	94.00(72.00–128.00)	0.513
Time from onset to recanalization of occluded blood vessel, min, median (IQR)	527.00(393.75–723.50)	467.00(389.25–596.00)	535.00(393.75–751.00)	0.131
Pathogenesis, n (%)				0.001
Atherosclerotic type	121(43.53)	1(5.00)	120(46.51)	
Cardiogenic embolism	91(32.73)	11(55.00)	80(31.01)	
Other causes	66(23.74)	8(40.00)	58(22.48)	
Plasma D-dimer, median (IQR)	0.90(0.46–2.07)	2.61(1.41–8.65)	0.82(0.44–1.88)	<0.001

Abbreviations: AIS, Acute ischemic stroke; mRS, modified Rankin scale; NIHSS, National Institute of Health stroke scale; ASPECT, Alberta Stroke Program Early CT; ASTIN/SIR, American Society of Interventional and Therapeutic Neuroradiology/Society of Interventional Radiology; eTICI, extended thrombolysis in cerebral infarction.

patients diagnosed with AIS due to anterior circulation large vessel occlusion. Univariate and multivariate logistic regression analyses are shown in [Table 2](#).

According to indicators with statistical differences in the multivariate logistic regression analysis, a forest plot of the risk factors of cerebral herniation formation is drawn as shown in [Supplementary Figure 1](#). The ROC curve for predicting cerebral herniation using plasma D-dimer was drawn, with an area under the curve (AUC) of 0.766, a cutoff value of 1.675mg/L, a sensitivity of 75.0%, and a specificity of 73.3%. The ROC curve is shown in [Figure 2](#).

Table 2 Univariate and Multivariate Logistic Regression Analysis of Patients with Cerebral Hernia

Variables	Univariate Analysis			Multivariate Analysis		
	OR	95% CI	P Value	OR	95% CI	P Value
NIHSS score at onset	1.100	1.026–1.180	0.007	1.011	0.903–1.132	0.845
Preoperative ASPECT score	0.295	0.157–0.557	<0.001	0.392	0.168–0.915	0.030
Received intravenous thrombolysis treatment	2.531	0.999–6.412	0.050			
Collateral circulation score of ASTIN/SIR	0.270	0.144–0.505	<0.001	0.423	0.178–1.004	0.051
Intraarterial use of tirofiban injection	0.156	0.021–1.190	0.073			
eTICI grading						
2b	Reference			Reference		
2c	0.980	0.238–4.030	0.978	1.941	0.360–10.474	0.441
3	0.177	0.064–0.488	0.001	0.275	0.085–0.893	0.032
Pathogenesis						
Atherosclerotic type	Reference			Reference		
Cardiogenic embolism	16.500	2.089–130.312	0.008	9.586	1.085–84.668	0.042
Other causes	16.552	2.022–135.482	0.009	12.215	1.172–127.271	0.036
Plasma D-dimer, median (IQR)	1.154	1.070–1.245	<0.001	1.131	1.022–1.250	0.017

Abbreviations: NIHSS, National Institute of Health stroke scale; ASPECT, Alberta Stroke Program Early CT; ASTIN/SIR, American Society of Interventional and Therapeutic Neuroradiology/Society of Interventional Radiology; eTICI, extended thrombolysis in cerebral infarction; CI, Confidence interval.

In terms of bone flap decompression surgery, 4 cases (%) of patients in the cerebral herniation group underwent bone flap decompression surgery, while no patients in the cerebral hernia group underwent bone flap decompression surgery. There was a statistical difference between the two groups ($P < 0.001$). In terms of prognosis, patients with cerebral herniation had higher mRS scores at 3 months after surgery, a lower proportion of mRS scores ≤ 2 and mRS scores ≤ 1 , and a higher mortality rate. The comparison of bone flap decompression surgery and prognosis of two groups of patients is shown in [Table 3](#). The distribution of mRS scores at 3 months after surgery for patients with and without cerebral herniation is shown in [Supplementary Figure 2](#).

We further divided patients into a normal D-dimer group (D-dimer $< 0.50\text{mg/L}$) and an elevated D-dimer group (D-dimer $\geq 0.50\text{mg/L}$) based on plasma D-dimer levels. The baseline clinical data of patients in the normal and elevated D-dimer groups are shown in [Supplementary Table 1](#). The elevated D-dimer group had a higher average age (68.74 vs 61.08, $P < 0.001$), a higher proportion of coronary heart disease (17.00% vs 7.69%, $P = 0.047$), a higher proportion of atrial fibrillation (26.00% vs 8.97%, $P = 0.002$), a higher NIHSS score at onset (13.00 vs 11.00, $P = 0.012$), a lower

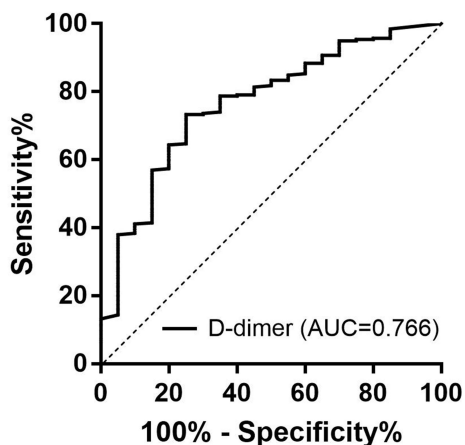


Figure 2 ROC curve of predicting cerebral herniation after successful thrombectomy using emergency preoperative plasma D-dimer levels. The corresponding AUC is 0.766.

Abbreviations: ROC, receiver operating characteristic curve; AUC, area under the curve.

Table 3 Bone Flap Decompression Surgery and Prognostic Differences Between Patients with Cerebral Hernia and Those with No Cerebral Hernia After Mechanical Thrombectomy for Acute Cerebral Infarction with Large Vessel Occlusion in the Anterior Circulation

Variables	All Patients (n=278)	Cerebral Hernia (n=20)	No cerebral Hernia (n=258)	P Value
Bone flap decompression surgery, n (%)	4(1.44)	4(20.00)	0(0)	<0.001
mRS score 3 months after thrombectomy, median (IQR)	2.50(1.00–4.00)	6.00(5.25–6.00)	2.00(1.00–4.00)	<0.001
mRS score 3 months after thrombectomy ≤ 2 points, n (%)	139(50.00)	0(0)	139(53.88)	<0.001
mRS score 3 months after thrombectomy ≤ 1 points, n (%)	100(35.97)	0(0)	100(38.76)	0.001
Death within 3 months after thrombectomy, n (%)	24(8.63)	15(75.00)	9(3.49)	<0.001

Abbreviation: mRS, modified Rankin scale.

preoperative ASPECT score (7.00 vs 8.00, $P = 0.011$), a lower collateral circulation score of ASTIN/SIR (2.00 vs 3.00, $P = 0.026$), and a higher proportion of cardioembolic mechanisms (38.50% vs 17.95%). After adjusting for variables with significant differences in univariate analysis, it was found that age (aOR = 1.060; 95% CI 1.030–1.090) was significantly correlated with an elevation in baseline D-dimer levels (as shown in [Supplementary Table 2](#)).

Discussion

With the continuous updating of interventional instruments, the success rate of thrombectomy in AIS due to large vessel occlusion can reach up to 90%, but the proportion of futile recanalization is still as high as 50% or even higher.^{21–28} The formation of cerebral herniation after thrombectomy is one of the important factors affecting futile recanalization. At present, clinical researches pay less attention to the formation of cerebral herniation after thrombectomy, and there is a lack of relevant literature on the incidence of cerebral herniation. Our study found that the incidence of cerebral herniation is 7.19%. After adjusting for potential confounders, this study showed a significant correlation between emergency preoperative plasma D-dimer level above 1.675mg/L and the formation of cerebral herniation after successful thrombectomy in AIS due to large vessel occlusion.

A retrospective study by Yao T et al²⁹ found a significant correlation between elevated plasma D-dimer levels at admission and adverse outcomes in patients with AIS after admission. Plasma D-dimer levels can serve as a predictor for short-term adverse outcomes in patients with AIS. Nam KW et al³⁰ detected plasma D-dimer levels at admission and discharge in patients with AIS and found that plasma D-dimer levels at admission and discharge were associated with early neurological deterioration. A retrospective study by Qiu K et al¹³ found that elevated levels of D-dimer upon admission were an independent predictor of symptomatic intracerebral hemorrhage after thrombectomy in patients with AIS and large vessel occlusion. The higher the D-dimer level in patients, the higher the risk of symptomatic cerebral hemorrhage. In the prediction model of futile recanalization in AIS with large vessel occlusion constructed by Huang et al,³¹ the risk of futile recanalization increased with the elevation of plasma D-dimer levels. It is currently clear that the elevation in plasma D-dimer is associated with early neurological deterioration, symptomatic cerebral hemorrhage and futile recanalization. However, there is currently no research on predicting the formation of cerebral herniation after successful thrombectomy in AIS with large vessel occlusion using emergency preoperative plasma D-dimer. Our study confirmed that the elevation of plasma D-dimer levels is associated with the formation of cerebral herniation after successful thrombectomy. To our knowledge, our study is the first to propose the prediction of cerebral herniation formation after successful thrombectomy using plasma D-dimer. This discovery will contribute to the early prediction and perioperative management of cerebral hernia formation, such as obtaining recanalized blood flow eTICI grading 3 during thrombectomy, guiding early dehydration, reducing intracranial pressure and preparing for craniotomy and bone flap removal.

Plasma D-dimer is a degradation product of fibrinogen and a classic biomarker for various thrombotic diseases.³¹ After brain tissue injury, the coagulation cascade can be enhanced by activating intrinsic coagulation factors and platelet aggregation. At the same time, high D-dimer levels reflect the formation of microthrombosis in the microcirculation of occluded blood vessels, which can cause widespread activation of the coagulation system, leading to high fibrinolysis and coagulation dysfunction. The reason why we only chose plasma D-dimer as a laboratory indicator to predict the formation of cerebral herniation was mainly because the waiting time for reporting immune, inflammatory and liver function indicators is long, which is not suitable for use before emergency thrombectomy. The single indicator of plasma D-dimer can often be reported within 30 minutes and does not require additional calculations, making it more suitable for use before emergency thrombectomy.

Our study also found that patients with cerebral hernia had higher NIHSS score, lower preoperative ASPECT score, lower collateral circulation score of ASTIN/SIR, and a higher proportion of cardioembolic mechanisms at onset. Patients with elevated plasma D-dimer were found to have higher NIHSS score, lower preoperative ASPECT score, lower collateral circulation score of ASTIN/SIR, and a higher proportion of cardioembolic mechanisms at onset. This suggested that plasma D-dimer can accurately reflect the burden of disease, and an increase in plasma D-dimer is associated with more severe neurological deficits, larger infarct size, poorer collateral compensation, and larger proportion of pathogenesis of cardioembolic stroke. In multivariate logistic regression analysis, we found that lower preoperative ASPECT score, pathogenesis of cardioembolism, and pathogenesis of other causes were independent risk factors for cerebral hernia, while recanalization eTICI grading 3 was the protective factor for cerebral hernia. Because the above indicators were not laboratory test indicators, their objectivity is not as strong as that of emergency preoperative plasma D-dimer relatively, so we tried to use emergency preoperative plasma D-dimer to predict cerebral hernia after successful mechanical thrombectomy. For patients with increased plasma D-dimer before emergency surgery, the important clinical significance is that we should pay special attention to taking corresponding measures to prevent patients from cerebral hernia and other complications after mechanical thrombectomy. In terms of recanalized blood flow eTICI grading, patients with grading 3 have a lower proportion of postoperative cerebral herniation, which suggests that neurointerventional physicians should strive to achieve complete reperfusion of occluded blood vessels in patients with high risk of postoperative cerebral herniation.

Brain herniation indicates an increase in intracranial pressure in patients.³² The higher the plasma D-dimer level, the more severe the formation of thrombosis and microthrombus. Although there may be a more accurate indicator than plasma D-dimer to predict cerebral herniation formation after successful mechanical thrombectomy, plasma D-dimer is an easily obtainable available detection indicator before emergency surgery. The level of plasma D-dimer may also be correlated with increased intracranial pressure, but further research is needed.

Our research had some limitations. First, this study was a single center, retrospective study, which was not necessarily of universal significance, and the findings of this study need to be interpreted with caution. Second, the number of cases of cerebral herniation in this study was relatively limited, which inevitably led to bias. However, the sample size of patients without cerebral herniation was relatively large, which makes our data relatively reliable. Third, we only included plasma D-dimer levels before emergency thrombectomy and did not dynamically reviewed plasma D-dimer levels. Fourth, the exclusion of patients with conditions affecting D-dimer levels may have introduced selection bias, which may to some extent affect the statistical results. Fifth, data on post-thrombectomy management that could influence cerebral herniation development was not explored. Further research is needed to determine whether emergency preoperative plasma D-dimer levels are associated with cerebral herniation in patients with AIS after successful thrombectomy, as well as the specific pathological and physiological mechanisms.

Conclusion

Although our study had certain limitations, we found that elevated emergency preoperative plasma D-dimer level is an independent predictive factor for the cerebral herniation after successful thrombectomy in patients with AIS, which is of great clinical significance. Based on D-dimer, which is an easily obtainable laboratory indicator, it can be used in clinical practice to early predict cerebral herniation after successful thrombectomy, helping to guide the thrombectomy

programme and precise perioperative management. In the future, multicenter or prospective studies are needed to validate our finding and provide stronger evidence.

Abbreviations

AIS, Acute ischemic stroke; ROC, Receiver operating characteristic curve; CT, Computed Tomography; MR, Magnetic Resonance; NIHSS, National Institute of Health stroke scale; ASPECT, Alberta Stroke Program Early CT; mRS, modified Rankin scale; LAA, Large atherosclerosis; ASTIN/SIR, American Society of Interventional and Therapeutic Neuroradiology/Society of Interventional Radiology; eTICI, extended thrombolysis in cerebral infarction; AUC, area under the curve.

Data Sharing Statement

The datasets generated during and/or analyzed during the current study are not publicly available but are available from the corresponding author Jinzhao He on reasonable request.

Ethical Approval

Our study complied with the Declaration of Helsinki. Approval was obtained from the Medical Ethics Committee of Heyuan People's Hospital (YXYJLL-YJZFQ33).

Consent for Publication

The Medical Ethics Committee of Heyuan People's Hospital approved the exemption of informed consent forms for this study.

Author Contributions

All authors made a significant contribution to the work reported, whether that is in the conception, study design, execution, acquisition of data, analysis and interpretation, or in all these areas; took part in drafting, revising or critically reviewing the article; gave final approval of the version to be published; have agreed on the journal to which the article has been submitted; and agree to be accountable for all aspects of the work.

Funding

This study was funded by the Guangdong Medical Research Foundation (A2024137).

Disclosure

The authors declare that there are no conflicts of financial or non-financial interests that are directly or indirectly related to the work.

References

1. Wassélius J, Arnberg F, von Euler M, et al. Endovascular thrombectomy for acute ischemic stroke. *J Intern Med.* 2022;291(3):303–316. doi:10.1111/joim.13425
2. Krishnan R, Mays W, Elijovich L. Complications of Mechanical Thrombectomy in Acute Ischemic Stroke. *Neurology.* 2021;97(20 Suppl 2):S115–S125. doi:10.1212/WNL.0000000000012803
3. Deng G, Xiao J, Yu H, et al. Predictors of futile recanalization after endovascular treatment in acute ischemic stroke: a meta-analysis. *J Neurointerv Surg.* 2022;14(9):881–885. doi:10.1136/neurintsurg-2021-017963
4. Meinel TR, Lerch C, Fischer U, et al. Multivariable Prediction Model for Futile Recanalization Therapies in Patients With Acute Ischemic Stroke. *Neurology.* 2022;99(10):e1009–e1018. doi:10.1212/WNL.00000000000200815
5. Wu S, Wang Y, Yuan R, et al. Predicting the emergence of malignant brain oedema in acute ischaemic stroke: a prospective multicentre study with development and validation of predictive modelling. *EClinicalMedicine.* 2023;59:101977. doi:10.1016/j.eclinm.2023.101977
6. Huang X, Yang Q, Shi X, et al. Predictors of malignant brain edema after mechanical thrombectomy for acute ischemic stroke. *J Neurointerv Surg.* 2019;11(10):994–998. doi:10.1136/neurintsurg-2018-014650
7. Riveros Gilardi B, Muñoz López JI, Hernández Villegas AC, et al. Types of Cerebral Herniation and Their Imaging Features. *Radiographics.* 2019;39(6):1598–1610. doi:10.1148/rg.2019190018
8. Sendama W, Musgrave KM. Decision-Making with D-Dimer in the Diagnosis of Pulmonary Embolism. *Am J Med.* 2018;131(12):1438–1443. doi:10.1016/j.amjmed.2018.08.006

9. Lee AY, Ginsberg JS. The role of D-dimer in the diagnosis of venous thromboembolism. *Curr Opin Pulm Med.* 1997;3(4):275–279. doi:10.1097/00063198-199707000-00007
10. Linkins LA, Bates SM, Lang E, et al. Selective D-dimer testing for diagnosis of a first suspected episode of deep venous thrombosis: a randomized trial. *Ann Intern Med.* 2013;158(2):93–100. doi:10.7326/0003-4819-158-2-201301150-00003
11. Li W, Tang Y, Song Y, et al. Prognostic Role of Pretreatment Plasma D-Dimer in Patients with Solid Tumors: a Systematic Review and Meta-Analysis. *Cell Physiol Biochem.* 2018;45(4):1663–1676. doi:10.1159/000487734
12. Kaito D, Yamamoto R, Nakama R, et al. D-dimer for screening of aortic dissection in patients with ST-elevation myocardial infarction. *Am J Emerg Med.* 2022;59:146–151. doi:10.1016/j.ajem.2022.07.024
13. Qiu K, Jia ZY, Cao Y, et al. Emergency admission plasma D-dimer: a novel predictor for symptomatic intracranial hemorrhage after thrombectomy in acute ischemic stroke. *J Neurointerv Surg.* 2023;15(e3):e375–e380. doi:10.1136/jnis-2022-019719
14. Hisamitsu Y, Kubo T, Fudaba H, et al. High D-Dimer Concentration Is a Significant Independent Prognostic Factor in Patients with Acute Large Vessel Occlusion Undergoing Endovascular Thrombectomy. *World Neurosurg.* 2022;160:e487–e493. doi:10.1016/j.wneu.2022.01.052
15. Ohbuchi H, Kanazawa R, Hagiwara S, et al. Preoperative plasma D-dimer level may be predictive for success of cerebral reperfusion and outcome after emergency mechanical thrombectomy for intracranial large vessel occlusion. *J Clin Neurosci.* 2022;97:75–81. doi:10.1016/j.jocn.2021.12.034
16. Xie T, Tang WW. Could emergency admission plasma D-dimer level predict first pass effect of stent retriever thrombectomy in acute ischemic stroke? *Acta Radiol.* 2024;65(4):367–373. doi:10.1177/02841851231218375
17. Ramos-Pachón A, López-Cancio E, Bustamante A, et al. D-Dimer as Predictor of Large Vessel Occlusion in Acute Ischemic Stroke. *Stroke.* 2021;52(3):852–858. doi:10.1161/STROKEAHA.120.031657
18. Freund Y, Chauvin A, Jimenez S, et al. Effect of a Diagnostic Strategy Using an Elevated and Age-Adjusted D-Dimer Threshold on Thromboembolic Events in Emergency Department Patients With Suspected Pulmonary Embolism: a Randomized Clinical Trial. *JAMA.* 2021;326(21):2141–2149. doi:10.1001/jama.2021.20750
19. Jadhav AP, Desai SM, Jovin TG. Indications for Mechanical Thrombectomy for Acute Ischemic Stroke: current Guidelines and Beyond. *Neurology.* 2021;97(20 Suppl 2):S126–S136. doi:10.1212/WNL.0000000000012801
20. Munoz A, Jabre R, Orenday-Barraza JM, et al. A review of mechanical thrombectomy techniques for acute ischemic stroke. *Interv Neuroradiol.* 2023;29(4):450–458. doi:10.1177/15910199221084481
21. Broderick JP, Berkhemer OA, Palesch YY, et al. Endovascular Therapy Is Effective and Safe for Patients With Severe Ischemic Stroke: pooled Analysis of Interventional Management of Stroke III and Multicenter Randomized Clinical Trial of Endovascular Therapy for Acute Ischemic Stroke in the Netherlands Data. *Stroke.* 2015;46(12):3416–3422. doi:10.1161/STROKEAHA.115.011397
22. Campbell BC, Mitchell PJ, Yan B, et al. A multicenter, randomized, controlled study to investigate EXTending the time for Thrombolysis in Emergency Neurological Deficits with Intra-Arterial therapy (EXTEND-IA). *Int J Stroke.* 2014;9(1):126–132. doi:10.1111/ijvs.12206
23. Goyal M, Demchuk AM, Menon BK, et al. Randomized assessment of rapid endovascular treatment of ischemic stroke. *N Engl J Med.* 2015;372(11):1019–1030. doi:10.1056/NEJMoa1414905
24. Saver JL, Goyal M, Bonafe A, et al. Stent-retriever thrombectomy after intravenous t-PA vs. t-PA alone in stroke. *N Engl J Med.* 2015;372(24):2285–2295. doi:10.1056/NEJMoa1415061
25. Jovin TG, Chamorro A, Cobo E, et al. Thrombectomy within 8 hours after symptom onset in ischemic stroke. *N Engl J Med.* 2015;372(24):2296–2306. doi:10.1056/NEJMoa1503780
26. Molina CA, Chamorro A, Rovira À, et al. REVASCAT: a randomized trial of revascularization with SOLITAIRE FR device vs. best medical therapy in the treatment of acute stroke due to anterior circulation large vessel occlusion presenting within eight-hours of symptom onset. *Int J Stroke.* 2015;10(4):619–626. doi:10.1111/ijvs.12157
27. Nogueira RG, Jadhav AP, Haussen DC, et al. Thrombectomy 6 to 24 hours after Stroke with a Mismatch between Deficit and Infarct. *N Engl J Med.* 2018;378(1):11–21. doi:10.1056/NEJMoa1706442
28. Albers GW, Marks MP, Kemp S, et al. Thrombectomy for Stroke at 6 to 16 hours with Selection by Perfusion Imaging. *N Engl J Med.* 2018;378(8):708–718. doi:10.1056/NEJMoa1713973
29. Yao T, Tian BL, Li G, et al. Elevated plasma D-dimer levels are associated with short-term poor outcome in patients with acute ischemic stroke: a prospective, observational study. *BMC Neurol.* 2019;19(1):175. doi:10.1186/s12883-019-1386-3
30. Nam KW, Kwon HM, Lee YS. Clinical significance of D-dimer levels during acute period in ischemic stroke. *Thromb J.* 2023;21(1):55. doi:10.1186/s12959-023-00496-1
31. Huang S, Xu J, Kang H, et al. A Comprehensive Prediction Model for Futile Recanalization in AIS Patients Post-Endovascular Therapy: integrating Clinical, Imaging, and No-Reflow Biomarkers. *Aging Dis.* 2024;2024:1.
32. Tadevosyan A, Kornbluth J. Brain Herniation and Intracranial Hypertension. *Neurol Clin.* 2021;39(2):293–318. doi:10.1016/j.ncl.2021.02.005