

Atypical Presentation of Choroidal Osteoma: Two Case Reports

Dafne Fernandes Machado¹, Stela Souza Peña¹, Mariana Carneiro Alves¹,
Giovana Capecci Siqueira¹, Leonardo Amarante Pereira¹, Samantha Sanches de Carvalho²,
Thais Moura Gascon², Beatriz da Costa Aguiar Alves², Glaucia Luciano da Veiga^{1,2},
Fernando Luiz Affonso Fonseca¹⁻³, Vagner Loduca Lima¹, Priscilla Ballalai¹

¹Ophthalmology Discipline, Centro Universitário Saúde ABC/ Faculdade de Medicina Do ABC, Santo André, Brasil; ²Clinical Analysis Laboratory, Centro Universitário Saúde ABC/ Faculdade de Medicina Do ABC, Santo André, Brasil; ³Department of Pharmaceutical Sciences, Universidade Federal de São Paulo, Diadema, Brasil

Correspondence: Dafne Fernandes Machado, Ophthalmology Discipline, Centro Universitário Saúde ABC/ Faculdade de Medicina do ABC, Av. Lauro Gomes, 2.000, Santo André, São Paulo, 09060-870, Brasil, Tel +55-114993-5400, Email dafnefm13@gmail.com

Abstract: Choroidal osteoma is a rare, benign, osseous choristoma presenting as an orange-yellow, well-defined fundus mass. It presents unilaterally in most cases, has a predilection for the female sex, and favor a juxtapapillary location, becoming clinically manifest when it involves the macula. Almost 60% of eyes with osteoma may suffer significant visual loss. Choroidal osteomas can easily be mistaken for other conditions with similar presentations. We herein report two rare cases presentation of choroidal osteoma: a 74-year-old male with 2-year blurred vision in the right eye (RE) initially misdiagnosed with age-related macular degeneration received intravitreal injections and after a multimodal evaluation, following cataract surgery in RE, confirmed to be choroidal osteoma and a 19-year-old female with a history of choroidal hemangioma presented with blurred vision in her left eye (LE), with examination revealed an irregular orange-yellow lesion along the superotemporal arcade with serous macular detachment, later diagnosed as choroidal osteoma.

Keywords: choroidal osteoma, osseous choristoma, visual loss, case reports

Introduction

Choroidal osteoma is a rare, benign, osseous choristoma presenting as an orange-yellow, well-defined fundus mass.¹ It presents unilaterally in most cases, has a predilection for the female sex, and favor a juxtapapillary location, becoming clinically manifest when it involves the macula.² Almost 60% of eyes with osteoma may suffer significant visual loss.³ One of the principal causes is the development of choroidal neovascularization.⁴

Choroidal osteomas can easily be mistaken for other conditions with similar presentations. Studies have estimated that up to 90% of eye care practitioners initially miss the diagnosis of choroidal osteoma, likely due to its inclusion in the broad differential diagnosis of ocular tumors and ocular calcification.⁵ The diagnosis of choroidal osteoma is mainly clinical. Over time, ocular ultrasound (US) and optical coherence tomography (OCT) have been widely used for diagnosis and follow-up.^{6,7}

Case Description

Case report 01: A 74-years old caucasian male with a 2 years history of blurred vision in the right eye (RE) was referred for evaluation and management of age-related macular degeneration after 4 intravitreal injections in other service. At presentation, best corrected visual acuity (BVCA) was counting fingers in his right eye (RE) and 20/40 in his left eye (LE). On slit-lamp exam nuclear cataract +2 and posterior subcapsular cataract +3 in his RE and nuclear cataract +2 in his OS. Fundus examination was normal in the left eye, while in the right eye revealed extensive macular white lesion. In addition to the indicated phacoemulsification with intraocular lens implantation in his RE, a multimodal evaluation was carried out with ultrasound, optical coherence tomography (OCT) and fluorescein angiography, which revealed that it

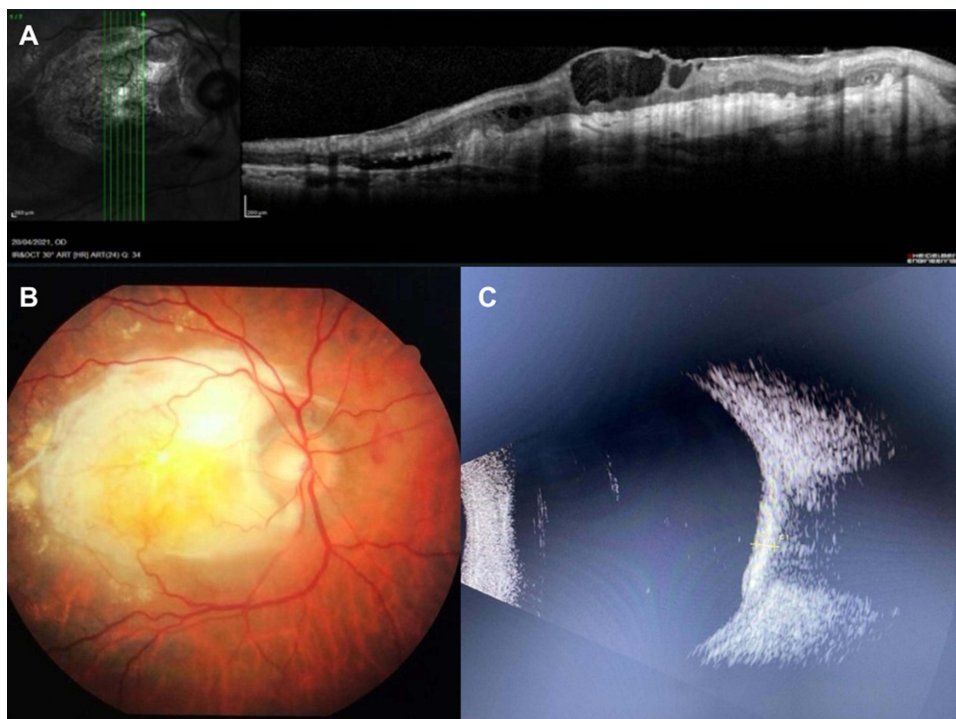


Figure 1 (A) Optical coherence tomography (OCT) showing subretinal fibrosis. (B) Retinography demonstrating choroidal osteoma. (C) Ocular ultrasound demonstrating high reflectivity lesion causing shadowing of posterior structures.

was a choroidal osteoma (Figure 1). The presence of a choroidal osteoma explains the macular white lesion and is consistent with the imaging results.

Case report 02: A 19-years old caucasian female with a 1 month history of blurred vision and metamorphopsia in the left eye (LE). Referred a diagnosis of choroidal hemangioma 2 years ago. At presentation, best corrected visual acuity (BVCA) was 20/20 in her right eye (RE) and 20/40 with metamorphopsia in her left eye (LE). The anterior segment examination was unremarkable in both eyes. Fundus examination was normal in the right eye, while in the left eye revealed an orange-yellow lesion, with not well-defined margins, extending from them disc along the superotemporal arcade up to the midperiphery sparing the macula.

The ultrasound examination demonstrated an area of high reflectivity on the ocular wall, causing posterior shadowing, suggestive of calcification. The OCT revealed hyperreflective lines in the choroid, photoreceptor atrophy and choroidal compression in the area corresponding to the lesion, with serous macular detachment (Figure 2). The diagnostic hypothesis was choroidal osteoma associated with serous macular detachment. The combination of imaging findings—particularly the OCT revealing hyperreflective lines, photoreceptor atrophy, and serous macular detachment—aligns with the known characteristics of choroidal osteomas. The presence of serous macular detachment further supports the diagnosis, as these lesions can induce retinal complications. The patient was treated with an intravitreal injection of Bevacizumab with improvement in vision and serous detachment.

Conclusions

Choroidal osteoma is often confused with other lesions mainly with an atypical presentation. Therefore, a multimodal evaluation is important, especially with low-gain ultrasound for diagnostic confirmation. These cases illustrate the diverse presentations of choroidal osteoma and the necessity of a thorough multimodal evaluation for accurate diagnosis. By integrating ultrasound, OCT, and fluorescein angiography, clinicians can effectively differentiate choroidal osteoma from other similar lesions and provide appropriate management.

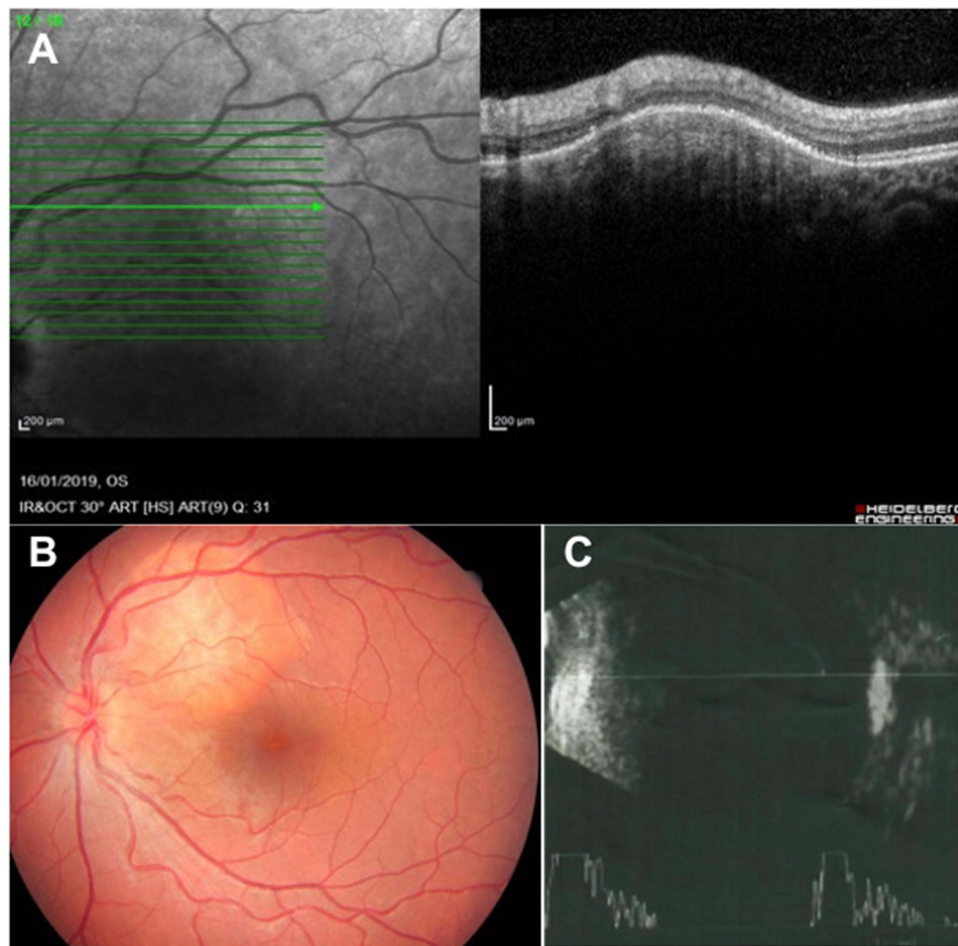


Figure 2 (A) Optical coherence tomography (OCT). (B) Retinography demonstrating choroidal osteoma. (C) Ocular ultrasound with low gain demonstrating calcification.

Informed Consent Statement

Written informed consent was obtained from the patient for the publication of this paper. Approval to publish the case details was not required in our institution.

Funding

The author(s) received no financial support for the research, authorship, and/or publication of this article.

Disclosure

The author(s) declared no potential conflicts of interest with respect to the research, authorship, and/or publication of this article.

References

1. Papastefanou V, Pefkianaki M, Al Harby L, et al. Intravitreal bevacizumab monotherapy for choroidal neovascularisation secondary to choroidal osteoma. *Eye*. 2016;30:843–849. doi:10.1038/eye.2016.50
2. Baum M, Pinkerton AR, Berler DK, Kramer KK. Choroidal osteomas. *Ann Ophthalmol*. 1979;11:1849–1851.
3. Aylward GW, Chang TS, Pautler SE, Gass JD. A long-term follow-up of choroidal osteoma. *Arch Ophthalmol*. 1998;116(10):1337–1341. doi:10.1001/archophth.116.10.1337
4. Shields CL, Sun H, Demirci H, Shields JA. Factors predictive of tumor growth, tumor decalcification, choroidal neovascularization, and visual outcome in 74 eyes with choroidal osteoma. *Arch Ophthalmol*. 2005;123(12):1658–1666. doi:10.1001/archophth.123.12.1658
5. Alameddine RM, Mansour AM, Kahtani E, Salman A, Jaroudi M. Review of choroidal osteomas. *Middle East Afr J Ophthalmol*. 2014;21(3):244–250. doi:10.4103/0974-9233.134686

6. Olguin-Manríquez F, Enríquez AB, Crim N, et al. Multimodal imaging in choroidal osteoma. *Int J Retina Vitreous*. 2018;4:30. PMID: 30128167; PMCID: PMC6092861. doi:10.1186/s40942-018-0132-0
7. Shields CL, Shields JA. Choroidal Osteoma. In: Albert D, Miller J, Azar D, Young LH, editors. *Albert and Jakobiec's Principles and Practice of Ophthalmology*. Cham: Springer; 2021. doi:10.1007/978-3-319-90495-5_261-1

International Medical Case Reports Journal

Dovepress

Publish your work in this journal

The International Medical Case Reports Journal is an international, peer-reviewed open-access journal publishing original case reports from all medical specialties. Previously unpublished medical posters are also accepted relating to any area of clinical or preclinical science. Submissions should not normally exceed 2,000 words or 4 published pages including figures, diagrams and references. The manuscript management system is completely online and includes a very quick and fair peer-review system, which is all easy to use. Visit <http://www.dovepress.com/testimonials.php> to read real quotes from published authors.

Submit your manuscript here: <https://www.dovepress.com/international-medical-case-reports-journal-journal>