

Complete Hydatidiform Mole with Twin Live Fetuses in a Triplet Pregnancy: A Case Report and Literature Review

Qiong Li¹, Cancan Zou¹, Linli Xie¹, Suzhen Ran², Yanlin Chen¹, Tianjing Yan¹

¹Department of Pathology, Women and Children's Hospital of Chongqing Medical University, Chongqing Health Center for Women and Children, Chongqing, People's Republic of China; ²Department of Ultrasound, Women and Children's Hospital of Chongqing Medical University, Chongqing Health Center for Women and Children, Chongqing, People's Republic of China

Correspondence: Tianjing Yan; Yanlin Chen, Email 64672420@qq.com; chenyl_doctor@163.com

Introduction: The coexistence of a complete hydatidiform mole with twin live fetuses in a triplet pregnancy is an extremely rare condition with an unknown incidence.

Case Report: This report presents a case of a dichorionic diamniotic triplet pregnancy complicated by the coexistence of a complete hydatidiform mole and twin live fetuses. The pregnancy resulted in a preterm delivery at 30 weeks and 5 days of gestation, with both live fetuses surviving to date. During the pregnancy, the patient was diagnosed with pre-eclampsia and intrahepatic cholestasis. Post-delivery, she was found to have an invasive mole with lung metastases, which was ultimately successfully treated.

Conclusion: This report highlights critical considerations for managing a multiple pregnancy complicated by a complete hydatidiform mole, alongside the associated potential complications. In light of the limited literature on the clinical management of this condition, our findings offer valuable insights into navigating the risks and optimizing patient outcomes.

Keywords: hydatidiform mole, triplet pregnancy, live fetuses

Introduction

Complete hydatidiform mole coexisting with a live fetus (CHMCF) in twin pregnancies is an extremely rare condition, with a reported global incidence ranging from approximately 1 in 22,000 to 1 in 100,000 pregnancies.¹ Twin molar pregnancies significantly elevate the risk of complications such as antepartum haemorrhage, spontaneous abortion, preterm delivery, intrauterine fetal death, pre-eclampsia and hyperthyroidism, resulting in a survival rate of less than 50% for delivered fetuses.² Furthermore, up to 63% of patients may develop persistent gestational trophoblastic disease (pGTD) after delivery, with approximately half of the cases potentially progressing to metastatic disease.^{3,4} Given these risks, many patients facing this condition may opt for early termination of the pregnancy.

The coexistence of a complete hydatidiform molar pregnancy with twin live fetuses in a triplet pregnancy is even rarer. We conducted a systematic literature review on triplet pregnancies with a complete hydatidiform mole (CHM) and twin live fetuses. Our search strategy involved using the keywords “triplet pregnancy” and “complete mole” in PubMed, Medline, and Google Scholar databases. This search yielded a total of 89 results. We then applied inclusion criteria, selecting only studies published in English and cases involving triplet pregnancies with CHM and twin live fetuses. After analyzing all titles and abstracts, we identified 24 papers covering 25 relevant cases. We extracted and compiled information regarding patient characteristics, pregnancy details, and outcomes, which is presented in [Table 1](#).

In this article, we report a case of a triplet pregnancy complicated by the presence of a complete hydatidiform mole and twin live fetuses. Two female infants were successfully delivered via cesarean section at 30 weeks and 5 days of gestation and have survived to date. Initially, this case was misdiagnosed as a twin pregnancy accompanied by a partial hydatidiform mole. However, it was only after the delivery of the fetuses and the placenta that the correct diagnosis of

Table 1 Summary of Case Reports on Triplet Pregnancies Complicated by Complete Hydatidiform Mole

Case	Age (yr)	History of Infertility Treatment	Vaginal Bleeding	Pre-eclampsia	Complications	Delivery (Week)	Weight of Fetus	Pregnancy Outcome	pGTD	Therapy of pGTD
Azuma et al ⁵	24	hMG-hCG	+	-	-	Spontaneous abortion at 19 weeks	Female-235 g Female-275 g	Dead	-	-
Sauerbrei et al ⁶	22	Clomiphene	+	+	Not mentioned	Spontaneous abortion at 22 weeks	Male-440 g Male-370 g	Dead	-	-
Ohmichi et al ⁷	34	hMG-hCG	+	-	-	Spontaneous abortion at 17 weeks	Female- 155 g Male- 160 g	Dead	+	5 courses of Act-D and MTX
Van de et al ⁸	31	GIFT	+	-	-	Vaginal delivery at 24 weeks	Male-595 g Male-525 g	Dead	-	-
Shahabi et al ⁹	25	IVF-ET	-	-	Hyperthyroidism	Induced abortion at 17 weeks	Not mentioned	Dead	+	2 courses of MTX + folic acid
Shozu et al ¹⁰	31	IVF-ET	+	-	-	Induced abortion at 15+4 weeks	Not mentioned	Dead	+	6 courses of Act-D and MTX
Higashino et al ¹¹	23	Clomiphene +FSH + hCG	-	+	Hyperthyroidism	Induced abortion at 15 weeks	Female- 110 g Male- 120 g	Dead	+	7 courses MTX + 2 courses of VP
Gray-Henry et al ¹²	33	Metrodin + hCG	+	Not mentioned	-	Uterine evacuation at 16 weeks	Not mentioned	Dead	+	β -hCG levels were normal after 6 months
Rajesh et al ¹³	29	-	+	-	-	Vaginal delivery at 24 weeks	Female-500 g Male-560 g	Dead	Close Surveillance of β -hCG	Close surveillance of β -hCG
Amr et al ¹⁴	30	Clomiphene + hCG	-	-	-	Delivery at 30 weeks	Female- 1300g Male- 1500g	Male-Dead Female-live	-	-
Malhotra et al ¹⁵	29	-	+	-	-	Spontaneous abortion at 21 weeks	Female-270g Male-270g	Dead	-	-
Takagi et al ¹⁶	37	hMG-hCG	-	-	-	Cesarean section at 28 weeks	Female-880g Male- 1258g	Live	+	6 courses of MTX
Bovicelli et al ¹⁷	32	IVF-ET	+	-	-	Cesarean section at 31+4 weeks	Female- 1700g Male- 1640g	Male-Dead Female-live	-	-

Ko et al ¹⁸	36	IVF-ET	Not mentioned	+	Not mentioned	Cesarean section at 33 weeks	F1- 1800g F2- 1860g	Live	-	-
SUZUKI et al ¹⁹	34	Clomiphene + hCG	-	-	-	Uterine evacuation at 10 weeks	Not mentioned	Dead	-	-
Yang et al ²⁰	27	Not mentioned	+	-	-	Cesarean section at 31 weeks	Female- 1500g Male- 1700g	Live	Close Surveillance of β -hCG	Close Surveillance of β -hCG
Polonsky et al ²¹	24	Clomiphene	+	-	-	Uterine evacuation	Not mentioned	Dead	Close Surveillance of β -hCG	Close Surveillance of β -hCG
Suganya et al ²²	35	Clomiphene	-	-	Hypothyroid	Lower segment cesarean section	F1-2010g F2-3213g	Live	-	-
Jang et al ²³	32	Intrauterine insemination	-	+	-	Cesarean section	F1- 1490g F2-680g	F1-Live F2-Dead	-	-
Siwatch et al ²⁴	25	Spontaneous conception	+	-	Hyperthyroidism	Uterine evacuation	Not mentioned	Dead	-	-
Rajasekaran et al ²⁵	37	IVF-ET	-	-	-	Cesarean section at 28+2 weeks	Female- 1008g Male- Not mentioned	Male-Dead Female-live	-	-
Sheng et al ²⁶	29	Clomiphene	+	-	Hyperthyroidism	Cesarean section at 30+ weeks	Female- 1230g Female-810 g	Live	-	-
Sheng et al ²⁶	32	IVF+ICST	+	-	Hyperthyroidism	Induced abortion at 18+ weeks	Not mentioned	Dead	-	-
Marjorie et al ²⁷	32	Clomiphene + Intrauterine insemination	+	-	PPROM	Cesarean section at 27 weeks	F1- 1080g F2- 1100g	F1-Live F2-Dead	+	1 month of MTX

(Continued)

Table I (Continued).

Case	Age (yr)	History of Infertility Treatment	Vaginal Bleeding	Pre-eclampsia	Complications	Delivery (Week)	Weight of Fetus	Pregnancy Outcome	pGTD	Therapy of pGTD
Filomena et al ²⁸	37	IVF-ET	-	-	Subclinical hyperthyroidism	TOP	Not mentioned	Dead	+	10 courses of MTX/FA
Current study	28	Clomiphene	+	+	ICP	Cesarean section at 30+ 5 weeks	Female-720 g Female- 1270g	Live	+	5 courses of MTX

Abbreviations: HCG, human chorionic gonadotropin; hMG, human menopausal gonadotropin; GIFT, gamete intrafallopian transfer; IVF-ET, in vitro fertilisation-embryo transfer; ICST, Intracytoplasmic sperm injection; FSH, folliclestimulating hormone; PPROM, premature rupture of the membrane; ICP, intrahepatic cholestasis of pregnancy; TOP, Termination of pregnancy; MTX, methotrexate; pGTD, persistent gestational trophoblastic disease; Act-D, Actinomycin D; VP, Vepeside.

a triplet pregnancy with a complete hydatidiform mole was confirmed through histopathological and immunohistochemical tests.

Case Report

A 28-year-old Chinese woman, gravida 1, para 0, conceived naturally after ovulation induction with Clomiphene at a local hospital. Early in her pregnancy, at 7 weeks gestation, she experienced slight vaginal discharge and was prescribed oral dydrogesterone tablets. After taking the medication for over 3 months, there was no further vaginal bleeding. A pelvic color Doppler scan confirmed a dichorionic diamniotic twin intrauterine pregnancy. Routine tests, including liver, kidney, and thyroid function, as well as complete blood counts and urine analysis, were all within normal limits. At 23+ weeks of gestation, the patient presented to the local hospital with itchy skin. She was diagnosed with intrahepatic cholestasis of pregnancy (ICP), characterized by elevated total bile acid (TBA) levels of 30.1 $\mu\text{mol/L}$ (normal range: 0–10 $\mu\text{mol/L}$). Treatment included bile acid-lowering agents, liver protection measures, and promotion of fetal lung maturation, including an adequate course of dexamethasone. During this time, her blood pressure was elevated, ranging from 138–170/80–103 mmHg (normal range: <140/90mmHg), leading to her transfer to our hospital for specialist care.

Upon admission to our hospital, relevant tests were repeated. Results showed persistently elevated TBA levels (14.6 $\mu\text{mol/L}$, normal range: 0–10 $\mu\text{mol/L}$), along with raised alanine aminotransferase (ALT: 81 U/L, normal range: 7–40 U/L) and aspartate aminotransferase (AST: 45 U/L, normal range: 13–35 U/L). Her 24-hour urinary protein was also elevated at 0.41 g/24h (normal range: <0.15 g/24h). Based on these findings, she was diagnosed with preeclampsia and ICP, and managed accordingly with antihypertensive and bile acid-lowering therapies. An oral glucose tolerance test (OGTT) revealed borderline gestational diabetes (5.22–9.78–9.03 mmol/L, normal range: 5.10–10.00–8.50 mmol/L), which was controlled through dietary modifications and exercise. A subsequent pelvic color Doppler ultrasound scan at our hospital confirmed the twin pregnancy with two live fetuses. Fetus A appeared to be developmentally appropriate for 23 weeks and 3 days gestation, while fetus B appeared smaller, consistent with 22 weeks and 6 days gestation. Partial honeycomb-like changes were noted in the placenta of fetus B (Figure 1), raising concerns about possible mesenchymal dysplasia of the placenta (PMD) or partial molar pregnancy. Due to the advanced gestational age, it has become very difficult to accurately distinguish the structure of the placenta and fetal membranes, as well as to confirm the exact number of fetuses. Amniocentesis was recommended to confirm the diagnosis but was refused by the patient and her family, who expressed a strong desire to continue the pregnancy.

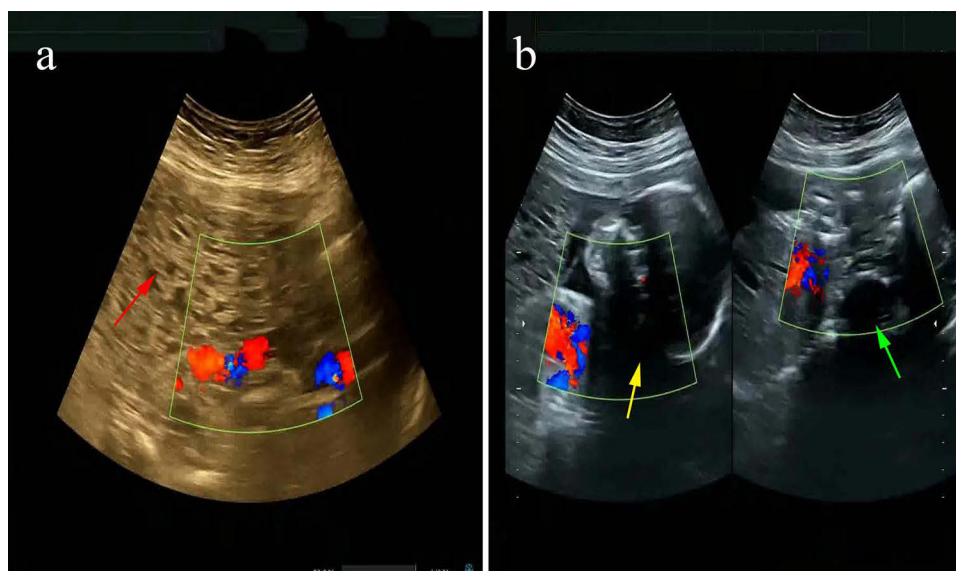


Figure 1 (a) Pelvic color Doppler ultrasound scan at 24 weeks revealed molar placenta of fetus B (red arrow). (b) Fetus A appeared to be developmentally appropriate for 23 weeks and 3 days gestation (yellow arrow), fetus B appeared smaller, consistent with 22 weeks and 6 days gestation (green arrow).

After stabilizing the patient's blood pressure and bile acid levels, regular prenatal check-ups were scheduled at our hospital's outpatient clinic. At 27 weeks and 5 days of gestation, a pelvic color Doppler scan revealed that the ultrasonic gestational age of fetus B was lagging behind the clinically determined gestational age. Furthermore, there were concerning findings of an elevated cardiothoracic ratio and partial honeycomb-like alterations in the placenta. A notable weight discrepancy of 14% between the twins was also observed. The patient was thoroughly counseled about the potential complications related to a suspected molar pregnancy. This included information about the risk of excessive bleeding, the possibility of early pregnancy termination, the risk of metastasis (particularly in the case of a complete molar pregnancy), the potential need for chemotherapy if a molar gestation was confirmed, and the risk of an abnormal fetal karyotype if it was a partial mole. Furthermore, we emphasized the importance of close follow-up and monitoring, even after delivery, due to the risk of persistent trophoblastic disease. We strongly recommended amniocentesis again to confirm the diagnosis and obtain crucial genetic information. However, despite our detailed explanation of the benefits and risks, the patient and her family still declined the procedure.

At 29 weeks gestation, the patient was readmitted to the hospital with worsening generalized pruritus. She did not experience nausea, vomiting, scleral or skin jaundice, abdominal pain, or vaginal bleeding. Her liver function tests showed elevated levels of ALT (238 U/L, normal range: 7–40 U/L), AST (117 U/L, normal range: 13–35 U/L), and TBA (51.4 umol/L, normal range: 0–10 umol/L). The patient's 24-hour urinary protein level was 3.39 g/24h, which is significantly higher than the reference range of <0.15 g/24h. Throughout her hospital stay, her blood pressure fluctuated between 121–180/69–81 mmHg (normal range: <140/90mmHg). Due to ultrasonographic indications of intermittent absent end-diastolic flow in the umbilical artery of the smaller fetus and a decreased pulsatility index (PI) in the middle cerebral artery, which raised concerns about fetal intrauterine distress, the decision was made to perform a cesarean section at 30 weeks and 5 days of gestation. The procedure was successful with an estimated blood loss of approximately 420mL, and two female infants were delivered. One infant, weighing 720g, had an Apgar score of 9–9–10, while the other, weighing 1270g, had an Apgar score of 10–10–10.

Following their birth, both premature infants, one larger and one smaller, exhibited tachypnea and inspiratory three concave signs at 35 and 31 minutes post-birth, respectively. They were admitted to neonatal intensive care, where they survived for durations of 15 days and 20 days. During their hospital stay, both infants received extensive examinations, including blood tests, imaging studies, and various screenings. The larger newborn was diagnosed with respiratory issues and hyperbilirubinemia, while the smaller one was found to have wet lung, multiple metabolic disturbances, and an elevated Thyroid-Stimulating Hormone (TSH) level. Fortunately, both infants' hearing, vision, metabolic, neuromotor, and electroencephalogram tests were normal. The larger infant was discharged after 5 weeks, while the smaller infant was discharged after 9 weeks. After six months, both infants demonstrated healthy growth; the smaller infant's thyroid levels normalized with Euthyrox treatment, and both continued to have a persistent patent foramen ovale that requires ongoing observation.

After delivery, histopathological and immunohistochemical examinations were performed on the placenta. Gross examination revealed a fused placenta with two umbilical cords attached, with localised vesicular changes and a pile of scattered vesicular tissue (Figure 2). Microscopically, villis were highly oedematous, central cysts were formed and trophoblastic cells proliferated massively. The immunohistochemical staining results were as follows: both villous interstitial cells and cytotrophoblastic cells in the vesicular areas tested negative for P57 (Figure 3), while Ki67 positivity exceeded 80%, aligning with a diagnosis of a complete hydatidiform mole. Given the discrepancy with the pelvic color Doppler ultrasound findings, we conducted additional staining for P57 and Ki67 on several sections, which confirmed the initial results. Subsequently, chromosomal analysis of the fetus was performed, revealing a karyotype of 46XX. Based on these findings, it was concluded that the patient had a triplet pregnancy complicated by a complete hydatidiform mole, and that earlier ultrasound examinations may have overlooked this diagnosis.

The patient presented with postpartum vaginal bleeding lasting over 30 days. Serum β -human chorionic gonadotropin (β -HCG) levels were abnormally high, measuring 7046.4 mIU/mL one week postpartum (normal range: < 5.0 mIU/mL). Two weeks later, the level decreased to 2631.0 mIU/mL, but rose slightly to 2837.2 mIU/mL three weeks postpartum. Imaging studies, including a chest X-ray and computed tomography scan, revealed multiple lung lesions up to 1.0 cm in size. However, a cranial magnetic resonance imaging (MRI) showed no abnormalities. Based on the clinical history and test results, a diagnosis

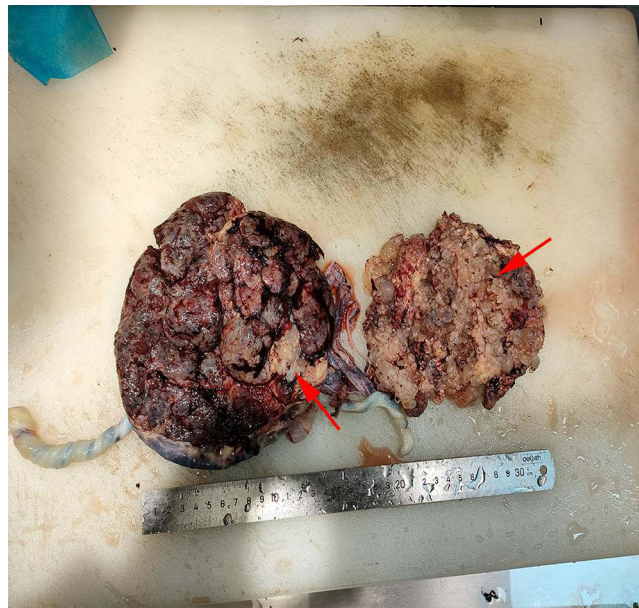

Figure 2 Gross examination: revealed a fused placenta with two umbilical cords attached, with localised vesicular changes and a pile of scattered vesicular tissue (red arrow) (H&E, $\times 400$).

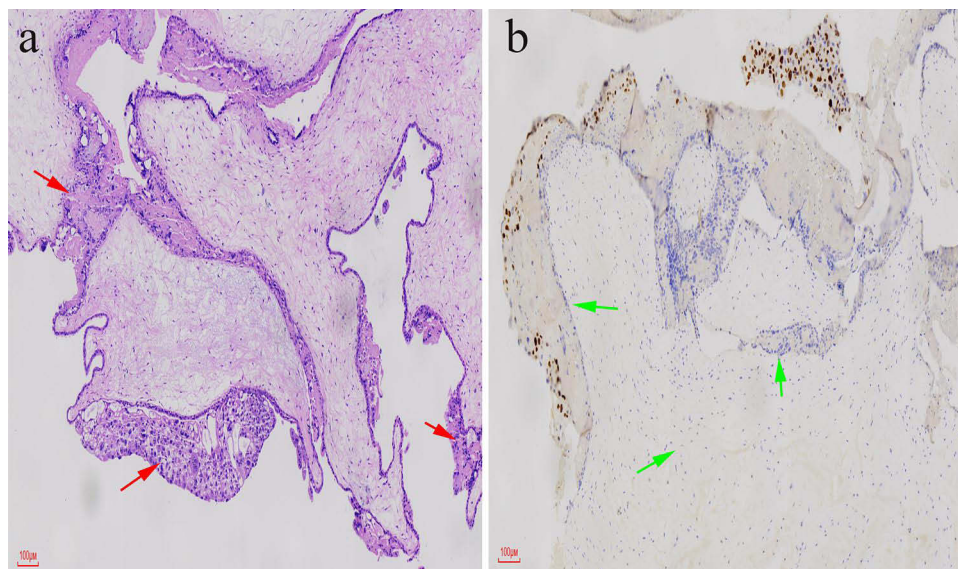


Figure 3 (a) Microscopic examination: villi were highly oedematous, central cysts were formed and trophoblastic cells proliferated massively (red arrow). (b) The immunohistochemical staining result: both villous interstitial cells and cytotrophoblastic cells in the vesicular areas tested negative for P57 (green arrow).

of invasive mole with lung metastases was made, with a Federation International of Gynecology and Obstetrics (FIGO) score of 1 point. Following one course of treatment of methotrexate (MTX), the β -HCG level dropped significantly to 1236.7 mIU/mL. After two courses, it further decreased to 136.1 mIU/mL, and after three courses, it reached 4.8 mIU/mL. Five days subsequent to the last measurement, β -HCG levels dropped to 2 mIU/mL. The patient continued to receive consolidation therapy for two additional courses, and responded well to the chemotherapy. She has remained in remission for six months, indicating successful treatment and good prognosis.

Discussion

The coexistence of hydatidiform mole with viable fetuses in multiple pregnancies is an exceptionally rare phenomenon, often linked to infertility treatments such as ovulation induction with clomiphene citrate and/or hmg-hcg, as well as advanced reproductive technologies like gamete intrafallopian transfer (GIFT) and in vitro fertilisation-embryo transfer (IVFET).²⁷ This complex condition can manifest as either a complete or partial hydatidiform mole. Approximately 80% of complete hydatidiform moles are homozygous for 46XX, arising either from the duplication of a haploid genome after the fertilization of an egg that has lost its maternal chromosomes during meiosis by a single sperm, or from the diploidization of a triploid zygote.^{29–31} Conversely, about 20% result from the fertilization of a single oocyte by two sperms, potentially leading to karyotypes of 46XX or 46XY. Notably, the nuclear DNA of these moles predominantly originates from the paternal side, indicating a predominantly male origin. Chromosomal investigations of unfertilized oocytes and abnormal zygotes following in vitro fertilization have revealed that disruptions in the meiotic process can give rise to chromosomal abnormalities, ultimately leading to the formation of complete hydatidiform moles from the zygote.³² Furthermore, it has been hypothesized that ovulation induction, which may result in the production of immature oocytes, could contribute to the development of hydatidiform moles. Specifically, the use of medications like clomiphene or gonadotropins to stimulate the growth of multiple follicles during the treatment of anovulation might increase the likelihood of a nuclear empty oocyte production.⁵

The rarity of triplet pregnancies complicated by complete hydatidiform mole (CHM) with coexisting fetuses poses significant diagnostic challenges. Previous studies have primarily relied on retrospective case analyses, often utilizing histopathological examinations or fetal karyotyping for differential diagnosis. While modern ultrasound technology offers the potential for early detection, accurate diagnosis can be confounded by its similarity to other conditions, such as early miscarriage or subchorionic hematoma. When placental polycystic changes are identified, careful differentiation is required to distinguish between various conditions, including twin pregnancies complicated by partial or complete hydatidiform mole, PMD, placental chorionic hemangioma, subchorionic hematoma, and chromosomal trisomy. The ultrasonographic appearance of hydatidiform mole and PMD can be particularly similar, further complicating diagnosis. Although PMD typically exhibits a “stained glass” sign, this characteristic may not always be present due to decreased blood flow within the dilated and dysplastic villi. Additionally, elevated serum β -hCG levels are observed in 38% of preterm infants, adding another layer of complexity to the diagnostic process.^{33,34}

MRI may provide valuable adjunctive information in later stages of pregnancy, as it can more clearly delineate the relationship between vesicular tissue and normal anatomic structures. CHMCF is typically located outside the gestational sac and associated with intra-and/or extra-lesional hemorrhage, whereas PMD is located within the gestational sac and is not associated with hemorrhage. Therefore, the integration of MRI with traditional diagnostic methods may aid in distinguishing PMD from CHMCF based on disease location. Furthermore, elevated serum alpha-fetoprotein (α -AFP) levels are often associated with PMD, a finding not typically observed in other conditions.

Distinguishing CHMCF and partial hydatidiform mole coexisting with a live fetus (PHMCF) in the prenatal period can be particularly challenging and may only be definitively diagnosed postnatally or following pregnancy termination. Complete hydatidiform mole pregnancies are characterized by marked cystic changes and mass formation; while partial mole pregnancies typically present with milder cystic placental changes that may not be sufficient for ultrasound diagnosis. Partial molar pregnancies may also be associated with a fetus; however, fetal tissue is often triploid, and over 92% of cases exhibit fetal malformations on ultrasound. Prenatal diagnosis by chorionic villus sampling (CVS) or amniotic fluid testing (AFT) is the most effective means of confirming fetal malformations. However, due to the invasive nature of these procedures and the increased risk of fetal loss, they should be carefully considered and discussed with the patient in this high-risk population. Thorough ultrasound examination can aid in the identification of triploid fetuses.

Complete hydatidiform mole coexisting with a fetus appears to significantly elevate the risk of adverse perinatal outcomes, particularly diminished pregnancy success rates and heightened chances of preterm birth. The survival rate of fetuses delivered from twin pregnancies complicated by a molar pregnancy is less than 50%.² However, specific data on triplet pregnancies remains murky due to their rarity. A review of the literature revealed 25 reported cases of triplet pregnancies with a complete hydatidiform mole. Of these, 16 chose to continue the pregnancy, resulting in 4 miscarriages (25%) before 24 weeks. Ten cases successfully delivered two infants, with a live birth rate of 40%, all before 34 weeks’

gestation, ranging from 28 to 33 weeks. Half of these cases had one surviving fetus, while the other half had both fetuses surviving. Tragically, 2 cases resulted in the death of both infants at 24 weeks' gestation. In our instance, however, the mother successfully gave birth to two female infants at 30+5 weeks, who have since thrived. In contrast, twin and triplet pregnancies without a coexisting molar pregnancy typically have an average gestational age of 36 weeks and 32 weeks, respectively.²⁸ Therefore, gestational age at delivery emerges as a critical factor in pregnancy management, particularly in cases where a molar pregnancy is present.

Multiple pregnancies complicated by a hydatidiform mole and coexisting fetuses pose a significant risk of fetal malformations and intrauterine growth restriction. As highlighted in a recent review by Libretti et al,³⁵ ultrasonography combined with serial scans is imperative to rule out congenital abnormalities in the living fetus. These scans should be conducted at regular intervals of at least every 2–3 weeks to closely monitor fetal development. However, in this particular case, reliable data could not be gathered before the 23rd week of gestation. From the 23rd week onwards, we conducted regular ultrasound scans to monitor fetal growth. We have compiled the Estimated Fetal Weight (EFW) data for both fetuses, which demonstrates a growing discrepancy between the larger and smaller fetus. Consequently, significant intrauterine growth restriction was evident in the smaller fetus after the 27th week of gestation. This condition can be associated with serious complications, such as refractory vaginal bleeding, hyperemesis gravidarum, early-onset pre-eclampsia, hyperthyroidism, and persistent gestational trophoblastic disease.

Vaginal bleeding is particularly prevalent in molar pregnancies, primarily resulting from shallow placental implantation and the premature entry of maternal blood into the villous space.^{36,37} Prolonged and excessive vaginal bleeding can lead to severe maternal anemia, a condition that is especially common in cases of complete hydatidiform mole. Furthermore, vaginal bleeding can cause focal inflammation, which also increases the risk of preterm birth. In a meta-analysis of twin pregnancies complicated by complete hydatidiform mole, over 70% of patients experienced vaginal bleeding of varying degrees, which contributed to the elevated rate of premature births. While the risk of hyperthyroidism appears to be relatively lower, at approximately 23.3%, it is nonetheless associated with exceptionally high levels of maternal serum hCG, which can reach up to 200 times the median for normal gestational age.¹ Among reported cases of triplet pregnancies with molar pregnancies, 15 cases (60%) presented with vaginal bleeding, and 6 cases (24%) developed hyperthyroidism. In our specific case, vaginal bleeding occurred at 7 weeks of gestation but was successfully controlled following oral administration of dydrogesterone.

Early-onset preeclampsia and eclampsia are recognized complications of molar pregnancies, particularly in nulliparous or older mothers.³⁸ Additionally, women with higher pre-ovulatory β -hCG levels face an elevated risk of developing persistent preeclampsia and gestational trophoblastic neoplasia. Therefore, continuous β -hCG monitoring and ultrasound examinations are essential, not only throughout pregnancy but also postpartum, to detect early signs of progression or metastasis.¹⁸ A retrospective study reported that while the incidence of preeclampsia in normal twin pregnancies was 11.8%, it rose to 21.9% in twin pregnancies complicated by complete hydatidiform mole.¹ Two literature reviews by Sukasi et al and Lin et al further indicate that the incidence of preeclampsia in twin pregnancies with complete hydatidiform mole can range from 20% to 30%.^{2,39} However, the precise rate of preeclampsia in triplet pregnancies with complete hydatidiform mole remains unknown, with four cases (16%) reported in the literature developing preeclampsia. Our case presented with severe preeclampsia at 23+5 weeks gestation, potentially attributed to early delivery at 30+5 weeks resulting from placental insufficiency, gestational diabetes (GDM) inducing inflammation and cellular harm, and molar pregnancy disrupting placental function and elevating sFlt-1 levels.⁴⁰

Molar pregnancy accompanied by preeclampsia is clinically aggressive, leading some experts to recommend immediate pregnancy termination. Other indications for termination include refractory vaginal bleeding, severe hyperemesis gravidarum, hyperthyroidism, or trophoblastic embolism. Nevertheless, there are documented instances of successful management of these complications leading to uneventful deliveries, suggesting that expectant management may be a viable option, especially for women who have experienced infertility for many years.

ICP is a liver condition that frequently arises during gestation, affecting approximately 1.5–4% of healthy pregnancies.⁴¹ Its precise etiology remains elusive and may encompass genetic, hormonal, and environmental components. ICP is more prevalent among women with multiple pregnancies and typically resolves spontaneously post-delivery. However, in 45–90% of subsequent pregnancies, the condition tends to recur in a more severe

manifestation.⁴² Elevated bile acids, often observed in women undergoing assisted reproductive therapy, may contribute to the increased incidence of ICP.⁴³ Notably, among reported cases of triplet pregnancies complicated by complete hydatidiform mole and coexisting fetuses, ICP has not been previously documented as a complication. In the present case, the pregnant woman developed ICP at 23+5 weeks of gestation and later experienced a more pronounced recurrence. Potential maternal outcomes for her include preeclampsia and gestational diabetes.

The increased risk of pGTD is another important consideration with this particular type of pregnancy. While pGTD can arise after any pregnancy, its likelihood increases significantly following a molar pregnancy when compared to a normal gestation. Compared to singleton pregnancies with CHM, the risk of pGTD may be even higher in multiple pregnancies, although reported incidence rates vary. One study showed that approximately 54.55% of CHMCF in twin pregnancies developed into pGTD;⁴⁴ One retrospective study of 14 cases of CHMCF reported that 50% of cases progressed to gestational trophoblastic neoplasia (GTN);⁴⁵ another meta-analysis showed that approximately 34% of CHMCF in twin pregnancies were diagnosed with GTN postpartum.¹ These discrepancies may be due to variations in study size, selection bias and disease classification. Among the cases reviewed, approximately 8 cases (32%) developed pGTD, with two cases also exhibiting lung metastases. One pregnancy was terminated at 17 weeks, while another underwent a caesarean section at 28+3 weeks due to severe uterine contractions. Our case, however, resulted in a successful delivery at 30+5 weeks with no maternal deaths reported.

According to the FIGO criteria for diagnosis of pGTD: (1) Plateau of β -HCG lasting for four measurements over a period of 3 weeks or longer (days 1, 7, 14, and 21); (2) Rise in β -HCG for three consecutive weekly measurements over at least a period of 2 weeks or more (days 1, 7, 14); (3) β -HCG levels remaining elevated over a period of 6 months or longer. Our case was also diagnosed with GTN with pulmonary metastases after delivery, and the condition was well controlled after treatment. The incidence of pGTD is not influenced by whether the pregnancy is spontaneously terminated, treated, or allowed to continue to term, nor is it associated with the gestational age at termination or delivery.¹ Favorable outcomes are often associated with factors such as lower HCG levels, later gestational age at diagnosis, and the absence of prenatal complications.^{2,46} Faced with the dilemma of continuing or terminating the pregnancy, especially for mothers who have a strong desire to have children, some scholars suggest that pregnancy should be terminated only in the presence of severe maternal complications⁴⁷ or fetal malformations incompatible with long-term survival, such as extreme oligohydramnios or triploidy.^{48,49} While complete hydatidiform molar pregnancies carry a higher risk of invasive trophoblastic disease for the mother, they also present an opportunity for the delivery of healthy newborns, as evidenced by numerous successful delivery cases.

Recent advancements in the management and therapeutic strategies for recurrent hydatidiform moles have been highlighted in a case report by Riccio et al,⁵⁰ which underscores the clinical challenges associated with this condition. Although multiple pregnancy with hydatidiform mole and recurrent hydatidiform mole are different types of abnormal pregnancies, they share certain commonalities in management and treatment strategies, particularly in terms of genetic counseling, early diagnosis, personalized treatment, and fertility guidance. Their research provides valuable insights and the latest information for the current practice of managing such cases.

Conclusion

In conclusion, our report describes a rare case of a triplet pregnancy with a complete hydatidiform mole and two viable fetuses. Although the advent and use of assisted reproductive technologies have slightly increased the incidence of such complex cases, they remain extremely rare. We have gained valuable insights and recommendations from reviewing previous reports. Accurate diagnosis and effective treatment are critical to the management of this unique condition, and further case studies are warranted to enhance our understanding. The decision to continue pregnancy requires a comprehensive consultation process with the patient, taking into account the potential for live birth, the risks of associated pregnancy complications, the likelihood of developing gestational trophoblastic neoplasia, and the possibility of requiring post-pregnancy chemotherapy, followed by personalized management plan.

Abbreviations

CHMCF, complete hydatidiform mole coexisting with a live fetus; pGTD, persistent gestational trophoblastic disease; ICP, intrahepatic cholestasis of pregnancy; TBA, total bile acid; ALT, alanine transaminase; AST, aspartate transaminase; β -HCG, β -human chorionic gonadotropin; hMG, human menopausal gonadotropin; OGTT, oral glucose tolerance test; MRI, magnetic resonance imaging; MTX, methotrexate; FIGO, federation International of Gynecology and Obstetrics; GIFT, gamete intrafallopian transfer; IVF-ET, in vitro fertilisation-embryo transfer; CHM, complete hydatidiform mole; PMD, placental mesenchymal dysplasia; α -AFP, alpha-fetoprotein; PHMCF, partial hydatidiform mole coexisting with a live fetus; CVS, chorionic villus sampling; AFT, amniotic fluid testing; GTN, gestational trophoblastic neoplasia; EFW, estimated fetal weight; TSH, Thyroid-Stimulating Hormone; PI, pulsatility index.

Ethics Statement

For case studies based on available clinical data, no approval by the Medical Ethics Committee of Chongqing Health Center for Women and Children is required. Written informed consent was obtained from the patient for publication of this case report and any accompanying images.

Funding

The Fund of the Women and Children's Hospital of Chongqing Medical University provided financial support (grant no. 2021YJMS01).

Disclosure

The authors declare that they have no known competing financial interests or personal relationships that could have appeared to influence the work reported in this paper.

References

1. Zilberman SN, Maymon R, Melcer Y, Jauniaux E. Obstetric outcomes of twin pregnancies presenting with a complete hydatidiform mole and coexistent normal fetus: a systematic review and meta-analysis. *BJOG*. 2020;127(12):1450–1457. doi:10.1111/1471-0528.16283
2. Suksai M, Suwanrath C, Kor-Anantakul O, et al. Complete hydatidiform mole with co-existing fetus: predictors of live birth. *Eur J Obstet Gynecol Reprod Biol*. 2017;212:1–8. doi:10.1016/j.ejogrb.2017.03.013
3. Steller MA, Genest DR, Bernstein MR, Lage JM, Goldstein DP, Berkowitz RS. Natural history of twin pregnancy with complete hydatidiform mole and coexisting fetus. *Obstet Gynecol*. 1994;83(1):35–42.
4. Steller MA, Genest DR, Bernstein MR, Lage JM, Goldstein DP, Berkowitz RS. Clinical features of multiple conception with partial or complete molar pregnancy and coexisting fetuses. *J Reprod Med*. 1994;39(3):147–154.
5. Azuma C, Saji F, Takemura M, et al. Triplet pregnancy involving complete hydatidiform mole and two fetuses: genetic analysis by deoxyribonucleic acid fingerprint. *Am J Obstet Gynecol*. 1992;166(2):664–667. doi:10.1016/0002-9378(92)91694-6
6. Sauerbrei EE, Salem S, Fayle B. Coexistent hydatidiform mole and live fetus in the second trimester: an ultrasound study. *Radiology*. 1980;135(2):415–417. doi:10.1148/radiology.135.2.7367637
7. Ohmichi M, Tasaka K, Suehara N, Miyake A, Tanizawa O. Hydatidiform mole in a triplet pregnancy following gonadotropin therapy. *Acta Obstet Gynecol Scand*. 1986;65(5):523–524. doi:10.3109/00016348609157401
8. van de Geijn EJ, Yedema CA, Hemrika DJ, Schutte MF, ten Velden JJ. Hydatidiform mole with coexisting twin pregnancy after gamete intra-fallopian transfer. *Hum Reprod*. 1992;7(4):568–572. doi:10.1093/oxfordjournals.humrep.a137692
9. Shahabi S, Naome G, Cobin L, et al. Complete hydatidiform mole and coexisting normal fetuses. A report of two cases with contrasting outcomes. *J Reprod Med*. 1997;42(11):756–760.
10. Shozu M, Akimoto K, Kasai T, Inoue M, Michikura Y. Hydatidiform moles associated with multiple gestations after assisted reproduction: diagnosis by analysis of DNA fingerprint. *Mol Hum Reprod*. 1998;4(9):877–880. doi:10.1093/molehr/4.9.877
11. Higashino M, Harada N, Hataya I, Nishimura N, Kato M, Niikawa N. Trizygotic pregnancy consisting of two fetuses and a complete hydatidiform mole with dispermic androgenesis. *Am J Med Genet*. 1999;82(1):67–69. doi:10.1002/(SICI)1096-8628(19990101)82:1<67::AID-AJMG13>3.0.CO;2-H
12. Gray-Henry DM, Ravindranath NT, Adeghe JH. Triplet pregnancy with complete hydatidiform mole coexisting with two fetuses. *J Obstet Gynaecol*. 1999;19(1):80–81. doi:10.1080/01443619966074
13. Rajesh U, Cohn MR, Foskett MA, Fisher RA, El Zaki D. Triplet pregnancy with a coexisting complete hydatidiform mole of monospermic origin in a spontaneous conception. *BJOG*. 2000;107(11):1439–1442. doi:10.1111/j.1471-0528.2000.tb11663.x
14. Amr MF, Fisher RA, Foskett MA, Paradinas FJ. Triplet pregnancy with hydatidiform mole. *Int J Gynecol Cancer*. 2000;10(1):76–81. doi:10.1046/j.1525-1438.2000.99064.x
15. Malhotra N, Deka D, Takkar D, Kochar S, Goel S, Sharma MC. Hydatiform mole with coexisting live fetus in dichorionic twin gestation. *Eur J Obstet Gynecol Reprod Biol*. 2001;94(2):301–303. doi:10.1016/S0301-2115(00)00338-9

16. Takagi K, Unno N, Hyodo HE, et al. Complete hydatidiform mole in a triplet pregnancy coexisting two viable fetuses: case report and review of the literature. *J Obstet Gynaecol Res.* 2003;29(5):330–338. doi:10.1046/j.1341-8076.2003.00124.x
17. Bovicelli L, Ghi T, Pilu G, et al. Prenatal diagnosis of a complete mole coexisting with a dichorionic twin pregnancy: case report. *Hum Reprod.* 2004;19(5):1231–1234. doi:10.1093/humrep/deh211
18. Ko PC, Peng HH, Soong YK, Chang SD. Triplet pregnancy complicated with one hydatidiform mole and preeclampsia in a 46,XY female with gonadal dysgenesis. *Taiwan J Obstet Gynecol.* 2007;46(3):276–280. doi:10.1016/S1028-4559(08)60034-0
19. Suzuki M, Itakura A, Ino K, Yamamoto T. A triplet pregnancy featuring a 47, XY+9 heterozygous complete mole coexisting with two fetuses at 9 weeks. *Acta Obstet Gynecol Scand.* 2007;86(5):635–637. doi:10.1080/00016340600608774
20. Yang J, He P, Lai Y, Zhang X. Triplet pregnancy with complete hydatidiform mole co-existing with two viable fetuses. *J Obstet Gynaecol.* 2011;31(8):768. doi:10.3109/01443615.2011.606936
21. Polonsky A, Olteanu I, Ben-David M, Mamet J, Agranat A, Fridman E. Viable triplet pregnancy coexisting with a complete molar pregnancy. *Clin Case Rep.* 2016;4(3):247–249. doi:10.1002/ccr3.417
22. Suganya U, Kanchana MP, Revathy M. Complete hydatidiform mole in a triplet pregnancy with coexisting two live fetuses-A case report and review of literature. *J Evol Med Dent Sci.* 2017;6(13):1056–1058. doi:10.14260/Jemds/2017/227
23. Jang WK, Ha J, Bae JG. Complete hydatidiform mole coexisting two live fetuses in triplet pregnancy. *Perinatology.* 2020;31(3):140–144. doi:10.14734/PN.2020.31.3.140
24. Siwatch S, Rohilla M, Jain V, Srinivasan R, Gainer S, Prasad GRV. Triplet pregnancy with complete mole. *J Obstet Gynaecol.* 2021;41(3):489–491. doi:10.1080/01443615.2020.1716311
25. Rajasekaran K, Dadhwal V, Jassim M. Incidental diagnosis of sad fetus syndrome in triplets. *BMJ Case Rep.* 2021;14(2):e238977. doi:10.1136/bcr-2020-238977
26. Sheng QJ, Wang YM, Wang BY, Shuai W, He XY. Triplet pregnancy with hydatidiform mole: a report of two cases with literature review. *J Obstet Gynaecol Res.* 2022;48(6):1458–1465. doi:10.1111/jog.15243
27. Thompson MH, Miller NR, Haugan SL, Gordon MC. Case report of a triplet pregnancy with complete hydatidiform mole and coexisting twins. *Case Rep Obstet Gynecol.* 2022;2022:2865342. doi:10.1155/2022/2865342
28. Sileo FG, Giuliani GA, Facchinetti F, Contu G, Chiossi G, Bertucci E. Complete hydatidiform mole in higher-order multiple pregnancies. *Minerva Obstet Gynecol.* 2022;74(3):308–313. doi:10.23736/S2724-606X.21.05031-4
29. Vassilakos P, Riotton G, Kajii T. Hydatidiform mole: two entities. A morphologic and cytogenetic study with some clinical consideration. *Am J Obstet Gynecol.* 1977;127(2):167–170. doi:10.1016/S0002-9378(16)33244-6
30. Kajii T, Ohama K. Androgenetic origin of hydatidiform mole. *Nature.* 1977;268(5621):633–634. doi:10.1038/268633a0
31. Yamashita K, Wake N, Araki T, Ichinoe K, Makoto K. Human lymphocyte antigen expression in hydatidiform mole: androgenesis following fertilization by a haploid sperm. *Am J Obstet Gynecol.* 1979;135(5):597–600. doi:10.1016/S0002-9378(16)32983-0
32. Balakier H, Casper RF. A morphologic study of unfertilized oocytes and abnormal embryos in human in vitro fertilization. *J in vitro Fert Embryo Transf.* 1991;8(2):73–79. doi:10.1007/BF01138658
33. Nayeri UA, West AB, Grossetta Nardini HK, Copel JA, Sfakianaki AK. Systematic review of sonographic findings of placental mesenchymal dysplasia and subsequent pregnancy outcome. *Ultrasound Obstet Gynecol.* 2013;41(4):366–374. doi:10.1002/uog.12359
34. Kuwata T, Takahashi H, Matsubara S. ‘Stained-glass’ sign for placental mesenchymal dysplasia. *Ultrasound Obstet Gynecol.* 2014;43(3):355. doi:10.1002/uog.13230
35. Libretti A, Longo D, Faiola S, De Pedrini A, Troia L, Remorgida V. A twin pregnancy with partial hydatidiform mole and a coexisting normal fetus delivered at term: a case report and literature review. *Case Rep Womens Health.* 2023;39:e00544. doi:10.1016/j.crwh.2023.e00544
36. Jauniaux E, Hustin J. Histological examination of first trimester spontaneous abortions: the impact of materno-embryonic interface features. *Histopathology.* 1992;21(5):409–414. doi:10.1111/j.1365-2559.1992.tb00424.x
37. Jauniaux E, Burton GJ. Pathophysiology of histological changes in early pregnancy loss. *Placenta.* 2005;26(2–3):114–123. doi:10.1016/j.placenta.2004.05.011
38. Fox NS, Roman AS, Saltzman DH, Hourizadeh T, Hastings J, Rebarber A. Risk factors for preeclampsia in twin pregnancies. *Am J Perinatol.* 2014;31(2):163–166. doi:10.1055/s-0033-1343775
39. Lin LH, Maestá I, Braga A, et al. Multiple pregnancies with complete mole and coexisting normal fetus in North and South America: a retrospective multicenter cohort and literature review. *Gynecol Oncol.* 2017;145(1):88–95. doi:10.1016/j.ygyno.2017.01.021
40. Eunjung J, Romero R, Lami Y, et al. The etiology of preeclampsia. *Am J Obstet Gynecol.* 2022;226:2 Suppl:S844–S866.
41. Hobson S, Gandhi S, Sobel M. Intrahepatic cholestasis of pregnancy. *CMAJ.* 2022;194(48):E1650. doi:10.1503/cmaj.220334
42. Piechota J, Jelski W. Intrahepatic cholestasis in pregnancy: review of the literature. *J Clin Med.* 2020;9(5):1361. doi:10.3390/jcm9051361
43. Bolukbas FF, Bolukbas C, YB H, et al. Intrahepatic cholestasis of pregnancy: spontaneous vs in vitro fertilization. *Euroasian J Hepatogastroenterol.* 2017;7(2):126–129. doi:10.5005/jp-journals-10018-1232
44. Liang H, Pan NP, Wang YF, Ye CS, Yan ZQ, Wu RJ. Obstetrical and oncological outcomes of twin pregnancies with hydatidiform mole and coexisting fetus. *Taiwan J Obstet Gynecol.* 2022;61(3):453–458. doi:10.1016/j.tjog.2022.03.010
45. Massardier J, Golfier F, Journet D, et al. Twin pregnancy with complete hydatidiform mole and coexistent fetus: obstetrical and oncological outcomes in a series of 14 cases. *Eur J Obstet Gynecol Reprod Biol.* 2009;143(2):84–87. doi:10.1016/j.ejogrb.2008.12.006
46. Lipi LB, Philp L, Goodman AK. A challenging case of twin pregnancy with complete hydatidiform mole and co-existing normal live fetus - A case report and review of the literature. *Gynecol Oncol Rep.* 2020;31:100519. doi:10.1016/j.gore.2019.100519
47. Ozoktay S, Abel-Bey G, Alexander LL. Hydatidiform mole with a live fetus. *J Natl Med Assoc.* 1982;74(10):1024–1026.
48. Sicuranza BJ, Tisdall LH. Hydatidiform mole and eclampsia with coexistent living fetus in the second trimester of pregnancy. *Am J Obstet Gynecol.* 1976;126(4):513–514. doi:10.1016/0002-9378(76)90652-9
49. Ozarpaci C, Yalti S, Gürbüz B, Ceylan S, Cakar Y. Complete hydatidiform mole with coexistent live fetus in dichorionic twin gestation. *Arch Gynecol Obstet.* 2005;271(3):270–273. doi:10.1007/s00404-004-0642-x
50. Riccio S, Galanti F, Scudo M, et al. Recurrent hydatidiform moles: a clinical challenge-a case report and an update on management and therapeutic strategies. *Case Rep Obstet Gynecol.* 2023;2023:3752274. doi:10.1155/2023/3752274

International Journal of Women's Health

Dovepress

Publish your work in this journal

The International Journal of Women's Health is an international, peer-reviewed open-access journal publishing original research, reports, editorials, reviews and commentaries on all aspects of women's healthcare including gynecology, obstetrics, and breast cancer. The manuscript management system is completely online and includes a very quick and fair peer-review system, which is all easy to use. Visit <http://www.dovepress.com/testimonials.php> to read real quotes from published authors.

Submit your manuscript here: <https://www.dovepress.com/international-journal-of-womens-health-journal>