

# Magnetic Resonance Images for the Prediction of Chronological Age Using Maxillary Third Molar Teeth: An Observational Study

Komal Smriti<sup>1,\*</sup>, Murali Venkata Rama Mohan Kodali<sup>2</sup>, Mathangi Kumar<sup>1,\*</sup>, Anoushka Saraf<sup>1</sup>, Medhini Madi<sup>1</sup>, Kalyana Chakravarthy Pentapati<sup>3</sup>, Prakashini K<sup>4</sup>, Yogesh Chhapparwal<sup>1</sup>, Unati Sai Kodali<sup>5</sup>, Srikanth Gadicherla<sup>6</sup>

<sup>1</sup>Department of Oral Medicine & Radiology, Manipal College of Dental Sciences, Manipal, Manipal Academy of Higher Education, Manipal, Karnataka, 576104, India; <sup>2</sup>Department of Oral and Maxillofacial surgery, College of Dentistry, King Faisal University, Al Hofuf, Eastern Province-Al Ahsa, 31982, Kingdom of Saudi Arabia; <sup>3</sup>Department of Public Health Dentistry, Manipal College of Dental Sciences, Manipal, Manipal Academy of Higher Education, Manipal, Karnataka, 576104 India; <sup>4</sup>Department of Radio Diagnosis, Kasturba Medical College & Hospital, Manipal, Manipal Academy of Higher Education, Manipal, Karnataka, 576104, India; <sup>5</sup>Dr Pinnamaneni Siddhartha Institute of Medical Sciences & Research Foundation, Dr. NTR University of Health Sciences, Vijayawada, India; <sup>6</sup>Department of Oral & Maxillofacial Surgery, Manipal College of Dental Sciences, Manipal, Manipal Academy of Higher Education, Manipal, 576104, Karnataka, India

\*These authors contributed equally to this work

Correspondence: Medhini Madi; Yogesh Chhapparwal, Department of Oral Medicine and Radiology, Manipal College of Dental Sciences, Manipal, Manipal Academy of Higher Education, Manipal, Karnataka, 576104, India, Email medhini.madi@manipal.edu; yogesh.chhapparwal@manipal.edu

**Introduction:** Dental age estimation using third molars is a reliable method for estimating the age of individuals. Recently, magnetic resonance imaging (MRI) of the head and neck has been found to be applicable for age estimation of third molar teeth. In the present study, we aimed to apply the Modified Demirjian method of age estimation to magnetic resonance (MR) image sections for dental age estimation by determining the mineralization patterns of the maxillary third molars.

**Methods:** MRI scans of the patients were performed using SIGNA™ 3.0Tesla MRI GE Healthcare (Chicago, USA) with a moving, multifunctional coil. Two expert radiologists with more than three years of experience independently analyzed the image sections using the open-source Digital Imaging and Communications in Medicine (DICOM) viewer software. The age and sex of the patients whose images were included in the study were recorded using a specially designed proforma. The stage of development of the maxillary third molars was determined using the modified Demirjian method. Inter observer agreement was calculated using the intra class correlation coefficient. Simple linear regression analysis was used to predict the actual age at the third molar development stage.

**Results:** There was excellent agreement between observers (ICC =0.99 (95% CI = 0.98–0.99)). There was also a significant association between the maxillary third molar tooth development stage and chronological age of the individual (P=0.001; B=1.54; 95% CI = 0.71–2.37).

**Discussion:** The findings from the present study establish that the Modified Demirjian method can also be reliably applied for dental age assessment in MR sections.

**Keywords:** third molars, forensic science, age estimation by teeth, odontogenesis

## Introduction

Dental age estimation is vital for identifying individuals. Tooth selection is an important aspect of age estimation because of its unique features of resilience, calcification, and age-associated progressive changes. Age estimation is of paramount importance in routine forensic and judicial practices. The increasing number of unidentified cadavers and human remains necessitate accurate and reliable methods for human identification. Various clinical and radiographic methods are employed in the process of age and sex estimation based on dental tissue and tooth structure, such as morphological, radiographic, histological, and biochemical methods.<sup>1–4</sup> Morphological and radiographic methods (Schour and Massler's

method, Demirjian's method, and Kvaal's method) are useful for living adolescents and adults, whereas histological and biochemical methods (Gustafson's and Johanson's method, Bang and Ramm's method, aspartic acid racemization, and the cemental annulation technique) are useful for dead victims.<sup>5,6</sup> Among these, radiographic techniques are reliable and accurate tools. Tooth development patterns have made a breakthrough in forensic science owing to systematic programmed development, calcification, and maturation processes. This unique phenomenon can be readily visualized on radiographs, rendering forensic odontology more reliable and reproducible. Radiographs of various tooth-like incisors, canines, first molars, and second molars were evaluated to assess the age of an individual. Third molars have been used most extensively and accurately.<sup>7-9</sup> The process of root formation and completion was used for dental age estimation using the Modified Demirjian method.<sup>10</sup>

Individual identification using medical and dental health records has evolved as a significant source of information, owing to the digital availability of imaging records. Archiving of images may be employed for applications in forensic studies, particularly in the absence of incomplete clinical and on-site records. Panoramic radiography is the most commonly recommended screening radiograph and a reliable tool for dental age estimation.<sup>11</sup> However, the accuracy of the evaluation and calculation of age estimation may vary owing to the magnification of panoramic radiographs. Though dental radiographs are a valuable tool for age estimation they have the disadvantage of being an ionizing imaging modality.

Imaging modalities such as computed tomography (CT) and magnetic resonance imaging (MR) provide accurate details without deterioration of important information. Hence, the data from these images may serve as valuable aids for accurate age estimation.<sup>12</sup> Recently, magnetic resonance imaging (MRI) of the head and neck has been found to be applicable for age estimation of third molar teeth which is a non-ionizing imaging modality. This non-ionizing imaging technique reduces the risk of stochastic mutations and its effects. Teeth or sections of teeth that are seen in proximity to the cranial structures on MR images taken for craniofacial trauma or intracranial pathologies can be easily analyzed for age estimation.<sup>13,14</sup>

Studies that have evaluated the reliability of MRI for dental age estimation have used the mineralization patterns of the teeth.<sup>15</sup> The use of MRI for dental age estimation was reported by Baumann et al<sup>15</sup> and Guo Y et al<sup>16</sup> using the Demirjian and Olze method. Given this background, we aimed to evaluate the applicability of mineralization patterns obtained by MRI of the maxillary third molars to predict age by applying the modified Demirjian method. The assessment of maxillary third molars for sex and age estimation necessitates an understanding of their proximity to the maxillary sinus and the developmental morphological variations present in the roots of these teeth.

With advancements in forensic odontology, third molar teeth have emerged as one of the most reliable sources for dental age estimation.<sup>4,17</sup> Dental age and sex estimation and prediction has been sparsely performed using maxillary third molar teeth using magnetic resonance image sections. Since the MRI imaging is frequently employed for visualization of the brain and associated structures, the images obtained can be extrapolated for age and sex prediction due to the enhanced visibility of the maxillary molars in those sections. Hence, we aimed to apply the Modified Demirjian method of age estimation to MR image sections for dental age estimation by determining the mineralization patterns of the third molars.

## Materials and Methods

This retrospective pilot study was conducted in the Department of Oral Medicine and Radiology, in coordination with the Department of Radiodiagnosis, between January 2014 and October 2019. Kasturba Medical College and Kasturba Hospital Institutional Ethics Committee approved the conduct of this study (IEC 952/2019). This study complies with the Declaration of Helsinki. 1100 brain MRI images were retrieved from the archives of the Radiodiagnosis Wing attached to the Department of Trauma and Emergency where the images are saved with complete demographic data of the patients. 110 MRI scans of the patient's head and neck region, which clearly depicted the third molars, were screened by both the radiologists and selected for the study. Approximately 60 MRIs of patients aged 13–65 years were considered for the third molar analysis after excluding images with artifacts that obscured imaging of the third molars, maxillary third molars with developmental anomalies were excluded. 37 MRI images that clearly showed the maxillary molars at various stages of development were included as the final sample for the study. All scans were performed using a SIGNA™ 3.0Tesla MRI scanner (GE Healthcare, Chicago, IL, USA) attached to 12 channel head coil incorporated

with a high resolution T1- weighted turbo-spin-echo 3D scan. The subjects were scanned in the supine position without anesthesia and instructed to breathe from the nose, close their mouth, and restrict their movement. Field view was kept large with isotropic resolution maintained at 0.80 cycles in 4 minutes. The MRI data were transferred to a Digital Imaging and Communications in Medicine (DICOM) viewer to visualize the velum, and the 3D data were sliced along the midsagittal plane. Image sections were obtained at an interval of 3 mm. Written informed consent was obtained from the patients and patients' guardians (in cases where their age was less than 18 years). Consent states that the images may be utilized for future research purposes. To ensure patient anonymity, images were completely decoded by a person who was not part of the study. The nationality, age and sex of the patients whose images were included in the study were recorded using a specially designed proforma. Image sections (axial, coronal, and sagittal) revealing the molar teeth were used for the study. The sagittal sections of all images best depicted the various calcification stages from crown formation to root completion.<sup>15,18</sup> Hence, it was decided that the sagittal sections of all the images shall be analyzed for the staging of tooth development.

The images were anonymized. Two Radiologists with more than three years of experience independently evaluated the left and right sagittal sections to assess the developmental stage of maxillary third molars using the modified Demirjian method.<sup>10</sup> Calcification of the third molar tooth (stages 0–9) was observed in the MR image. A schematic representation of the stage of development of third molar teeth is shown in Figure 1.

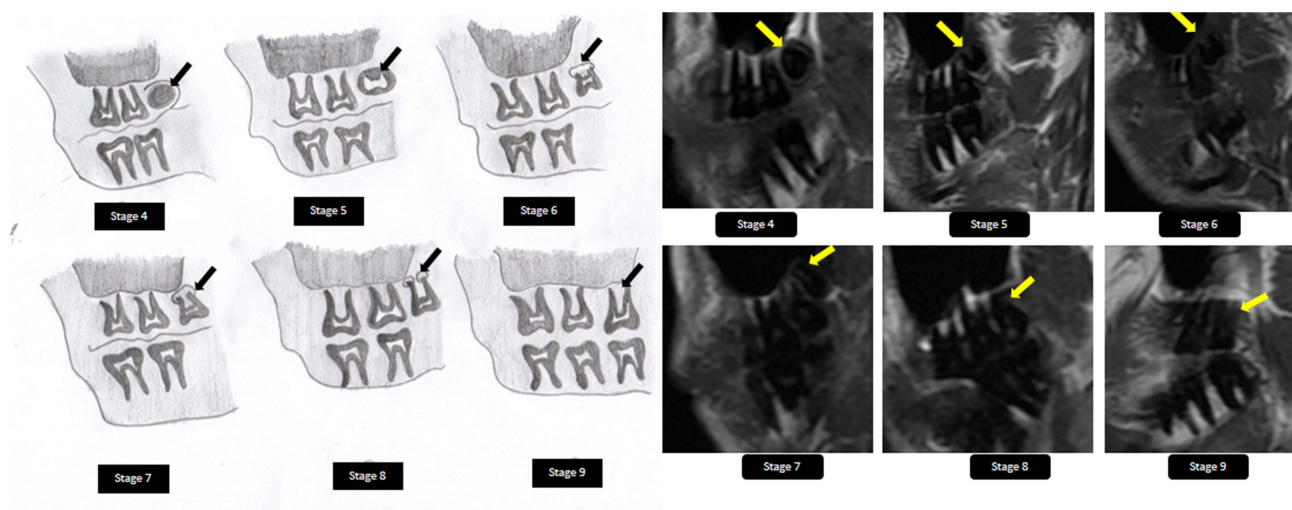
## Statistical Analysis

All the analysis was done using SPSS version 20 (IBM Corp. Released 2011. IBM SPSS Statistics for Windows, Version 20.0. Armonk, NY: IBM Corp). Statistical significance was set at  $p < 0.05$ . Interobserver agreement was calculated using the intraclass correlation coefficient. Simple linear regression analysis was used to predict the actual age at the third molar development stage.

## Results

A total of 110 head and neck magnetic resonance imaging (MRIs) scans were retrieved from the Department of Radiology Diagnosis Archives. Of these, 37 MRIs scans revealed the presence of a maxillary third molar in sagittal sections. There was excellent agreement between observers (ICC = 0.99 (95% CI = 0.98–0.99)). The mean age of the participants was 18.03 ( $\pm 4.5$ ). The distribution of the stages of third molar development among the participants is shown in Table 1. The graph showing correlation between the stage of development of third molar teeth and the chronological age (in years) is depicted in Figure 2.

Two simple linear regression models were formulated from the study population.

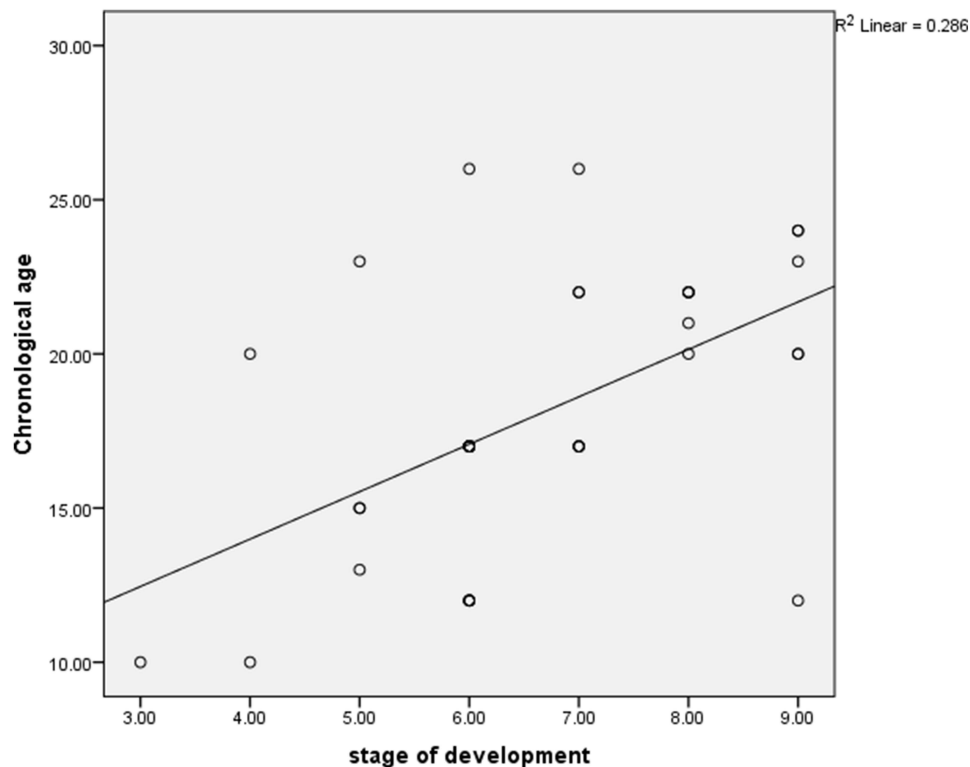


**Figure 1** Diagrammatic representation of the various stages of development of third molar tooth. The black and yellow arrows indicate the stages of tooth development.

**Table 1** Table Showing the Distribution of Stages of Development of the Maxillary Third Molars of the Study Subjects

Stage of development of 3 <sup>rd</sup> molar	N	%
3	1	2.7
4	2	5.4
5	4	10.8
6	13	35.1
7	6	16.2
8	5	13.5
9	6	16.2

- Model 1 showed a significant association between the maxillary third molar tooth development stage and age of the individual ( $P=0.001$ ;  $B=1.54$ ; 95% CI = 0.71–2.37). The model explains only 28.6% (0.286) of the variance. (Table 2)
- In Model 2, the age and sex of the individuals were included. There was a significant association between the maxillary third molar tooth development stage and the age of the individual ( $P=0.001$ ;  $B=1.45$ ; 95% CI = 0.64–2.28) while no significant association was observed with the sex of the individual. The variance explained by the model was 34.2% (0.342) (Table 3)



**Figure 2** Graph showing correlation between the stage of development of third molar teeth and the chronological age.

**Table 2** Model 1 depicting the Association of Maxillary Third Molar Tooth Development Stage with the Age of the Individual

	<b>B</b>	<b>Std. Error</b>	<b>T</b>	<b>P-value</b>	<b>95% CI</b>
(Constant)	7.841	2.791	2.809	0.008	2.18–13.51
Stage of development	1.538	0.411	3.746	0.001	0.71–2.37

**Notes:** R<sup>2</sup> (Variance)= 28.6% (0.286). Chronological age = 7.841+ (1.538 × stage of development).

**Table 3** Model 2 Depicting the Association of Maxillary Third Molar Tooth Development Stage with the Sex of the Individual

	<b>B</b>	<b>Std. Error</b>	<b>T</b>	<b>P-value</b>	<b>95% CI</b>
(Constant)	5.404	3.073	1.759	0.088	–0.84–11.65
Stage of development	1.456	0.403	3.614	0.001	0.64–2.28
Sex	2.163	1.272	1.700	0.098	–0.42–4.75

**Notes:** R<sup>2</sup> (Variance)= 34.2% (0.342). Chronological age = 5.4+ (1.456 × stage of development) + (2.163 × sex).

The equation that can be used to estimate age using maxillary third molar stage is as follows:

$$\text{Age} = 7.84 + (\text{Stage} \times 4.71).$$

## Discussion

Radiological methods for age estimation are widely employed in forensic odontology. Various stages of mineralization and calcification of the tooth and surrounding structures are considered to predict the dental age of an individual. There seems to be a variation in the third molar development in the male and the female gender and between the maxillary and the mandibular arches.<sup>18</sup> Numerous studies have tested the predictability of the different age estimation methods with varying outcomes.<sup>2,10,19,20</sup> In the present study, we adopted a higher imaging modality (MRI) that can help visualize the maxillary third molar tooth development stage. MRI is a preferred imaging modality owing to its non-ionizing nature, image enhancing tools which help to attain high precision data. Furthermore, the International Olympic committee also recommends using MRI of the third molars for age estimation in fraudulent cases.<sup>14</sup>

The tooth bud undergoes sequential calcification and mineralization processes at specific times in an individual. The tooth bud and adjacent structures undergo a gradation of changes until they are ready for eruption. This involves a dynamic interaction between the enamel organ and the adjacent ecto-mesenchymal tissue, which leads to the formation of a mature tooth bud. To visualize these changes, radiographs are important tools that are highly reliable and predictive of calcified structures. This cannot adequately reflect the actual changes in the developing tooth buds. Higher imaging modalities, such as MRI, have been tested for accurate assessment of tooth development. Moreover, the usefulness of MRI in fetal tooth bud visualization has been demonstrated in a study by Kunzendorf et al.<sup>21</sup> Radiographs are ionizing imaging modality with increased availability. Though MR imaging is non-ionizing in nature, the cost and the accessibility is limited. Hence, very few studies have assessed the reliability and efficacy of MR in predicting dental age. Dental age prediction using third molars is well established in literature.<sup>4,10,19,22</sup> Hence, in this study, we aimed to integrate the modified Demirjian method for maxillary third molars with MR for age estimation.

Recently, a study conducted by Bjork et al established a model for combining tissue volume measurements in MR images of the first, second and third molars for age prediction and concluded that third molars are the most reliable for dental age estimation.<sup>14</sup>

Mincer et al used various combinations of radiographs to predict age with the help of the third molar development. Their models could explain a variance ranging from 37 to 46% and a composite model that explained 50% of the variance.<sup>17</sup> Our study used only the maxillary third molars, which could explain only 29% of the variance.

Haglund et al systematically reviewed X-ray-based studies on fully formed third molars as indicators of adulthood. They concluded the need for additional methods to assess age.<sup>23</sup> Similar findings were reported in the studies conducted by Lucas et al, who tested the reliability and accuracy of classification of individuals based on panoramic radiographic findings.<sup>24</sup>

There is a growing demand for the utilization of non-ionizing radiation imaging modalities such as MRI.<sup>25</sup> Few studies have been done on the age estimation using third molars and MRI.<sup>15,25</sup> Guo et al<sup>16</sup> performed a study of 613 young adolescents to test MR images of the lower third molars teeth can be used to predict the age of individuals. It was concluded that MR images can be an effective alternative to panoramic radiography for assessing mineralization of third molar teeth. Baumann et al established the utility of MRI for dental age assessment by using the Demirjian and Olze methods. They concluded that the classification system was as reliable as applicable to panoramic radiographs.<sup>15</sup> De Tobel et al designed a technique for assessing MR image sections and found that MR images exhibited reproducibility comparable to that of radiographs for age estimation.<sup>25</sup> Widek et al estimated the age with the help of third molar tooth developmental stages using MRI in an Austrian male population.<sup>26</sup> The authors concluded that dental MRI is a suitable alternative to orthopantomography. The findings of our study establish that the Modified Demirjian method can be reliably applied for the assessment of MR images of maxillary third molar tooth development stages, which can then be used for dental age assessment.

This is the first ever study that has assessed the applicability of the Modified Demirjian method to MR image sections for dental age assessment taking maxillary third molar tooth into consideration. The findings from the present study establish that the Modified Demirjian method can also be applied for dental age assessment in MR sections.

The limitations of the present study include its retrospective nature in a hospital-based population and the limited validation of the Modified Demirjian method for MR image sections. Further, the limitations of MRI in dental age estimation are due to factors such as the accessibility and cost involved. Specialized Dental MRI with specific surface coils for dental imaging is valuable to achieve high image resolution but with limited availability and high cost.<sup>13</sup> We suggest that further studies on larger populations focusing on different age groups can pave the way for a more accurate dental age estimation using third molar teeth in MRI.

## Conclusion

The present study evaluated the efficacy of MR sections for dental age estimation using maxillary third molar teeth. This non-ionizing imaging modality may serve as a valuable tool in the field of forensic odontology and further the prediction of age and sex using third molar teeth can be employed as a reliable tool in future. A significant association was observed between the stage of development of the third molar and the age of the individual. A formula for estimating age based on the stage of development of the third molar was derived in this study.

## Ethics

Ethics Approval: Obtained (IEC: 952/2019)

## Disclosure

Komal Smriti and Mathangi Kumar are co-first authors. The authors report no conflicts of interest in this work.

## References

1. Thevissen PW, Fieuws S, Willems G. Third molar development: evaluation of nine tooth development registration techniques for age estimations. *J Forensic Sci.* 2013;58(2):393–397. doi:10.1111/1556-4029.12063
2. Periyakaruppan S, Meundi MA, David CM. Accuracy of age estimation in 6-21 year old South Indian population - A comparative analysis of clinical and radiographic methods. *J Forensic Odontostomatol.* 2018;36:10–19.
3. Rao NG. *Textbook of Forensic Medicine and Toxicology.* Jaypee brothers publishers: 2010.
4. Thevissen PW, Alqerban A, Asaumi J, et al. Human dental age estimation using third molar developmental stages: accuracy of age predictions not using country specific information. *Forensic Sci Int.* 2010;201(1–3):106–111. doi:10.1016/j.forsciint.2010.04.040

5. Rajendran R. *Shafer's Textbook of Oral Pathology*. Elsevier India; 2009.
6. Reppien K, Sejrsen B, Lynnerup N. Evaluation of post-mortem estimated dental age versus real age: a retrospective 21-year survey. *Forensic Sci Int*. 2006;159:84–88. doi:10.1016/j.forsciint.2006.02.021
7. Švábová Nee Uhrová P, Beňuš R, Chovancová Nee Kondeková M, Vojtušová A, Novotný M, Thurzo A. Use of third molar eruption based on Gambier's criteria in assessing dental age. *Int J Legal Med*. 2023;137(3):691–699. doi:10.1007/s00414-023-02953-y
8. Švábová P, Soták M, Galis B, et al. Dental age assessment based on developmental stages and maturity index of third molars for medico-legal purposes. *Diagnostics*. 2024;14(14):1559. doi:10.3390/diagnostics14141559
9. Gambier A, Rérolle C, Faisant M, Lemarchand J, Paré A, Saint-Martin P. Contribution of third molar eruption to the estimation of the forensic age of living individuals. *Int J Legal Med*. 2019;133(2):625–632. doi:10.1007/s00414-018-01991-1
10. Bijjaragi S, Sangle V, Saraswathi F, Patil V, Ashwini Rani S, Bapure S. Age estimation by modified demirjian's method (2004) and its applicability in Tibetan young adults: a digital panoramic study. *J Oral Maxillofac Pathol*. 2015;19(1):100–105. doi:10.4103/0973-029X.157223
11. Olze A, Schmeling A, Taniguchi M, Maeda H, Van Niekerk P. Forensic age estimation in living subjects: the ethnic factor in wisdom tooth mineralization. *Int J Leg Med*. 2004;118(3):170–173. doi:10.1007/s00414-004-0434-7
12. Bjørk MB, Kvaal SI. CT and MR imaging used in age estimation: a systematic review. *J Forensic Odontostomatol*. 2018;36(1):14–25. doi:10.1002/ajpa.1330130206
13. Flugge T, Gross C, Ludwig U, et al. Dental MRI-only a future vision or standard of care? A literature review on current indications and applications of MRI in dentistry. *Dentomaxillofacial Radiol*. 2023;52(4):1–13. doi:10.1259/dmfr.20220333
14. Bjørk MB, Bleka Ø, Kvaal SI, et al. MRI segmentation of tooth tissue in age prediction of sub-adults — a new method for combining data from the 1st, 2nd, and 3rd molars. *Int J Legal Med*. 2024;138(3):939–949. doi:10.1007/s00414-023-03149-0
15. Baumann P, Widek T, Merckens H, et al. Dental age estimation of living persons: comparison of MRI with OPG. *Forensic Sci Int*. 2020;253:76–80. doi:10.1016/j.forsciint.2015.06.001
16. Guo Y, Olze A, Ottow C, et al. Dental age estimation in living individuals using 3.0 T MRI of lower third molars. *Int J Legal Med*. 2015;129(6):1265–1270. doi:10.1007/s00414-015-1238-7
17. Mincer HH, Harris FE, Berryman HE. The A.B.F.O. Study of third molar development and its use as an estimator of chronological age. *J Forensic Sci*. 1993;38(2):379–390. doi:10.1520/JFS13418J
18. De Tobel J, Hillewig E, Bogaert S, Deblaere K, Verstraete K. Magnetic resonance imaging of third molars: developing a protocol suitable for forensic age estimation. *Ann Hum Biol*. 2017;44(2):130–139. doi:10.1080/03014460.2016.1202321
19. Chhapparwal Y, Kumar M, Madi M, Chhapparwal S. Age estimation by modified demirjian's method in a hospital- based population: a radiographic study. *Pesqui Bras Odontopediatria Clin Integr*. 2021;21:1–7.
20. Orhan K, Ozer L, Orhan AI, Dogan S, Paksoy CS. Radiographic evaluation of third molar development in relation to chronological age among Turkish children and youth. *Forensic Sci Int*. 2007;165(1):46–51. doi:10.1016/j.forsciint.2006.02.046
21. Kunzendorf B, Diogo MC, Covini DI, et al. Comparison of the visibility of fetal tooth buds on 1.5 and 3 tesla MRI. *J Clin Med*. 2020;9(11):3424. doi:10.3390/jcm9113424
22. Thevissen PW, Kaur J, Willems G. Human age estimation combining third molar and skeletal development. *Int J Legal Med*. 2012;126(2):285–292. doi:10.1007/s00414-011-0639-5
23. Haglund M, Mörnstad H. A systematic review and meta-analysis of the fully formed wisdom tooth as a radiological marker of adulthood. *Int J Leg Med*. 2019;133(1):231–239. doi:10.1007/s00414-018-1842-4
24. Lucas VS, McDonald F, Andiappan M, Roberts G. Dental age estimation — root pulp visibility (RPV) patterns: a reliable mandibular maturity marker at the 18 year threshold. *Forensic Sci Int*. 2017;270:98–102. doi:10.1016/j.forsciint.2016.11.004
25. Thevissen PW. Forensic age estimation based on development of third molars: a staging technique for magnetic resonance imaging. *J Forensic Odontostomatol*. 2017;35:117.
26. Widek T, Genet P, Merckens H, et al. Dental age estimation: The chronology of mineralization and eruption of male third molars with 3T MRI. *Forensic Sci Int*. 2019;297:228–235 doi:10.1016/j.forsciint.2019.02.019

## Clinical, Cosmetic and Investigational Dentistry

Dovepress

### Publish your work in this journal

Clinical, Cosmetic and Investigational Dentistry is an international, peer-reviewed, open access, online journal focusing on the latest clinical and experimental research in dentistry with specific emphasis on cosmetic interventions. Innovative developments in dental materials, techniques and devices that improve outcomes and patient satisfaction and preference will be highlighted. The manuscript management system is completely online and includes a very quick and fair peer-review system, which is all easy to use. Visit <http://www.dovepress.com/testimonials.php> to read real quotes from published authors.

Submit your manuscript here: <https://www.dovepress.com/clinical-cosmetic-and-investigational-dentistry-journal>