


Estradiol Valerate Tablets Caused Rare Severe Drug Eruption: The First Reported Case

Fang Yang, Yuedan Xu, Xiangyu Li 

Department of Pharmacy, Shaoxing Keqiao Women & Children's Hospital, Shaoxing, Zhejiang, People's Republic of China

Correspondence: Xiangyu Li, Department of Pharmacy, Shaoxing Keqiao Women & Children's Hospital, Shaoxing, Zhejiang, 312030, People's Republic of China, Tel +86-0575-85028228, Email 1070817321@qq.com

Abstract: Severe drug eruption is a severe allergic reaction to a drug, usually due to irritation with certain drugs. It may be present as a generalized erythematous maculopapular rash, a pleomorphic rash, with or without blisters and ulcers. To the best of our knowledge to date, there is no report of estradiol valerate-induced severe drug eruption. A case of rare severe drug eruption after taking estradiol valerate tablets was first reported to promote clinical drug safety management, especially for rare severe adverse reactions. Meanwhile, it is speculated that estrogen dermatitis might be associated with dendritic cell-mediated allergic mechanisms, inflammation-induced expression of estrogen receptor β , and elevated estrogen levels during pregnancy, according to previous studies. Therefore, pregnant women using this drug need to be focused on. Early and systemic use of glucocorticoids is beneficial to the outcome and prognosis of the disease. It highlights the need for clinicians to be vigilant about rare but serious adverse drug reactions, even with medications that are generally considered safe.

Keywords: severe drug eruption, estrogen dermatitis, estradiol valerate, adverse drug reaction, pharmacovigilance

Introduction

Severe drug eruptions are serious adverse drug reactions, including Steven-Johnson syndrome, toxic epidermal necrolysis (TEN), acute generalized exanthematous pustulosis, and drug hypersensitivity syndrome or drug reaction with eosinophilia and systemic symptoms (DRESS). In recent years, generalized bullous fixed drug eruption was classified as a type of severe drug eruption. Although the incidence of severe drug eruption is low, patients with severe drug eruption are usually in serious condition, with rapid progress and high mortality, especially the mortality rate of TEN and DRESS is extremely high. In addition to the common drugs, some new sensitizing drugs have been reported, such as antihypertensive drugs (hydrochlorothiazide¹), antifungal drugs (griseofulvin,² terbinafine³), non-steroidal antiaromatase (letrozole⁴). An essential component of hormone therapy is estradiol valerate, an oral long-acting estrogen supplement. Additionally, it has been licensed to treat severe menstrual bleeding and prevent pregnancy.^{5,6} According to the latest clinical trial, estradiol valerate is a relatively safe drug with mild common adverse reactions, such as increased triglyceride levels, increased uric acid, and thyroid-stimulating hormone.⁷ No serious adverse events were observed during the fasting and feeding studies. Seven individuals with cyclical exacerbations of papulovesicular lesions, urticaria, eczema, or widespread pruritus were first documented to have estrogen dermatitis in 1995.⁸ It was observed that the eruption in the latter group of individuals resolved after estrogen medication was stopped or tamoxifen was used as an antiestrogen.^{8,9} In this study, a case of a rare severe drug eruption was first reported after taking estradiol valerate tablets.

Case Report

A 33-year-old female patient visited the gynecological clinic of our hospital on March 25, 2024, due to 60 days of amenorrhea and 1 day of abnormal ultrasound examination. The last menstrual period was January 25, 2024, and menstruation was as usual. Urine pregnancy test was positive with cessation of menstruation >30d. Transvaginal ultrasound examination of the uterine appendage on March 24 showed an echo of a gestational sac with a size of about 29*16*13mm in the lower segment of

the uterine cavity, with yolk sac and a few fetal buds inside, and no heartbeat. The patient was diagnosed with a cesarean scar pregnancy. The patient now asked to terminate the pregnancy and came to our hospital for treatment, and she was admitted to the hospital with the diagnosis of cesarean scar pregnancy.

The patient had no history of food or drug allergy. Physical examination on admission exhibited normal skin and mucous membrane color, no edema, no rash, and no subcutaneous hemorrhage. Blood routine, liver function, renal function, coagulation function and other routine tests before surgery showed no abnormalities. The admission diagnosis was pregnancy at the uterine scar. The patient underwent hysteroscopic surgery for pregnancy within a caesarean scar on April 1. She was successfully discharged from the hospital on April 3, and treated with oral estradiol valerate tablets 2mg bid for 21 days to regulate menstruation, promote endometrial repair and growth.

Oral estradiol valerate tablets 2mg bid were started on April 4 (After discharge, the patient took only estradiol valerate tablets). After taking the drug on April 5, the patient developed fever, generalized rash with itching, and severe symptoms. The drug was discontinued, and “polymorphic drug eruption, drug hypersensitivity syndrome ” were considered and hospitalized on April 7 (Figure 1). Liver function tests after admission showed alanine aminotransferase 149 U/L; aspartate aminotransferase was 104 U/L. This suggests that liver function is impaired.

She was treated with compound glycyrrhizin injection 60mg ivgtt qd for liver protection, methylprednisolone injection 40mg bid, corticotrophins for injection 25 units for anti-inflammation, ebastine tablets 10mg qd, desloratadine citrate tablets 8.8mg qd for anti-allergy, and other comprehensive treatments. After treatment, the skin lesions subsided and pruritus was relieved. On April 12, methylprednisolone was gradually reduced to 40mg qd. On April 18, the original erythema on the patient’s whole body subsided, and no new skin lesions were found. At present, the patient’s condition was controlled and stable, the rash all over the body subsided, and there was no obvious itching.

Discussion

The patient had no history of food or drug allergy. The patient began to use estradiol valerate tablets on the third day after surgery. On the second day of medication, the patient developed fever, generalized erythema multiforme with pruritus, and the symptoms were severe. Then, the drug was withdrawn and the patient was admitted to the hospital for multi-drug combined anti-allergic treatment for more than 10 days. The patient’s condition was controlled, the rash all over the body subsided, and there was no obvious itching. The patient did not use other drugs during the treatment, and the daily diet was not different, so food and other drugs can be excluded as causes. In addition, there was no clear relationship between the adverse reaction of the drug and the patient’s condition. Meanwhile, combined with Naranjo’s probability scale to score the adverse reactions in this case, the results are shown in Table 1, with a total score of 6 (very likely related). It was preliminarily considered that the patient’s adverse reactions were caused by estradiol valerate tablets.

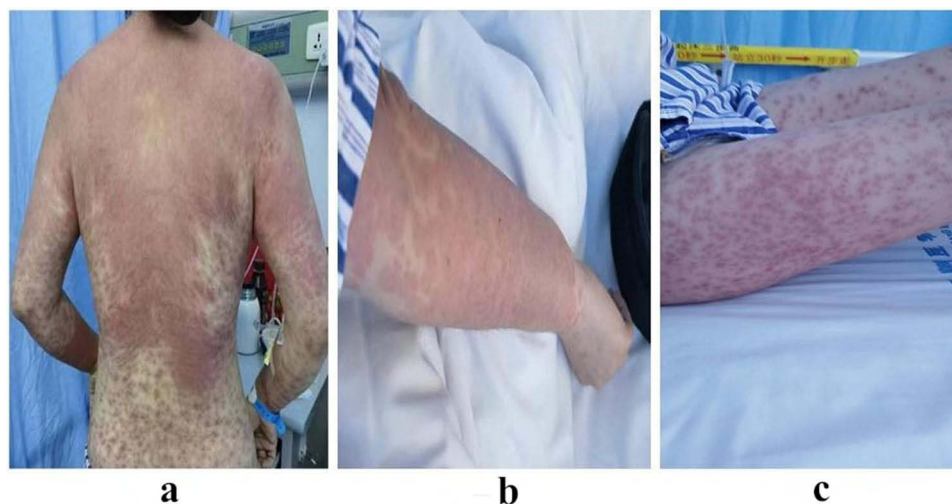


Figure 1 Manifestations of drug hypersensitivity syndrome in patients treated with estradiol valerate tablets (a) drug eruption on the back (b) drug eruption on the arms (c) drug eruption on the legs.

Table 1 Scores of Naranjo's Assessment

Questions	Status of score				
	Yes	No	Unknown	Score	Reasons for scoring
1. Are there previous conclusive reports of this reaction?	+1	0	0	0	No severe drug eruptions have been reported
2. Did the adverse event appear after the drug was given?	+2	0	0	2	The drug eruption occurred after the administration of estradiol valerate
3. Did the adverse reaction improve when the drug was discontinued or a specific antagonist was given?	+1	0	0	1	The rash resolved only after the drug was stopped and anti-allergic drugs were added
4. Did the adverse reaction reappear upon readministering the drug?	+2	-1	0	0	Not used again
5. Were there other possible causes for the reaction?	-1	+2	0	2	No other medications were used while the patient was on estradiol valerate
6. Did the adverse reaction reappear upon administration of placebo?	-1	+1	0	0	No placebo experiments were performed
7. Was the drug detected in the blood or other fluids in toxic concentrations?	+1	0	0	0	The plasma concentration was not measured
8. Was the reaction worsened upon increasing the dose? Or, was the reaction lessened upon decreasing the dose?	+1	0	0	0	The patient did not undergo this trial
9. Did the patient have a similar reaction to the drug or a related agent in the past?	+1	0	0	0	No similar reactions were documented in the patient's medical history or outside the hospital
10. Was the adverse event confirmed by any other objective evidence?	+1	0	0	1	The area of skin lesions confirmed this reaction
Total score				6	

Notes: The total score ≥ 9 points indicated that the causal relationship between the drug and the adverse reaction was certain; a total score of 5–8 represented very likely related; a total score of 1 to 4 represented may be related; a total score no more than 0 represented suspicious, indicating chance or little association.

Drugs such as antibiotics (such as sulfonamides and tetracyclines), antiepileptic drugs (such as phenobarbital), and nonsteroidal anti-inflammatory drugs (such as aspirin) are the triggers of polymorphic drug eruptions.^{10–12} Symptoms usually present as target-like lesions with multiple concentric circles, dark red in the center and light pink in the periphery. Although there are a variety of treatments for severe drug eruption, there are still controversies in the timing and dose of use. All patients with suspected drug eruptions should immediately stop using suspected allergenic drugs and strengthen nutrition support therapy. Glucocorticoids are still the first-line treatment for severe drug eruptions. Early and systemic use of glucocorticoids is beneficial to the outcome and prognosis of the disease. It is one of the most important methods for the treatment of severe drug eruption. However, the dose and timing of glucocorticoids are still controversial.^{13,14} At the same time, new biological agents such as tumor necrosis factor (TNF) antagonists and mepolizumab are still being explored in terms of types, doses and indications. According to past experience, estradiol valerate is a relatively safe drug. No reports of severe drug eruptions associated with estradiol valerate were found by searching databases (Web of Science and PubMed).

Estradiol valerate has the pharmacological effects of estrogen. That dermatitis has been observed with estradiol according to a past report.¹⁵ Shelley WB et al first studied estrogen dermatitis.⁸ Patients with positive intradermal skin test for estrogen presented with vesicular, popular, and inflammatory rashes: pruritus on the face, upper arms, and trunk; generalized, exterior-negative, perianal urticaria. The rash resolved after discontinuation of oral estrogen therapy or the use of antiestrogen therapy. Since then, there have been several case reports in which the rash occurred periodically before the menstrual period and improved 5 days after the beginning of the menstrual period.^{16,17} The clinical manifestations were macules, papules, blisters, urticarial lesions, bullae, eczematous plaques, and erythema multiforme. These individuals had positive intradermal tests for estrogen and showed marked improvement with tamoxifen. Japanese researchers had studied the possible mechanisms of estrogen dermatitis: three cases of skin biopsy specimens with clinical features of pruritus, urticaria, acneiform rash, and annular erythema showed obvious histopathological changes.¹⁸ Immunohistochemistry showed that CD1a and CD83 positive dendritic cells were distributed in hair follicles and

epidermis, and lymphocytes were densely gathered near dendritic cells. Thus, estrogen dermatitis appears to be associated with a dendritic cell-mediated allergic mechanism. Some scholars have also found that inflammation may induce the expression of estrogen receptor β in dermal blood vessels, which may promote the secretion of proinflammatory molecules in endothelial cells and/or eosinophils, lymphocytes and other inflammatory cell chemical inducers, produce a response to estrogen, and lead to the occurrence of estrogen dermatitis.¹⁹ Moreover, estrogen dermatitis will worsen during pregnancy. The level of estradiol in the first trimester increased gradually with the increase in gestational age. In this case, the patient herself was pregnant (8 weeks of pregnancy) with higher endogenous estrogen, which increases the risk of severe estrogen dermatitis. At the same time, the patient took estradiol valerate orally after induced abortion, which further increased the level of estrogen in the body. We speculate that the combination of the above factors may lead to a more severe allergic reaction. When women appear with an abnormal course of eruption that waxes and wanes in response to changes in endogenous hormone levels or exposure to exogenous hormones, it is vital to consider the diagnosis of autoimmune hormone dermatitis.

This study also has some limitations: the lack of re-administration of estradiol valerate to confirm the reaction, and the inability to measure the drug's concentration in the patient's blood. This leads to deficiencies in a clearer understanding of the case's scope and the challenges in establishing causality with absolute certainty.

Conclusion

This case report suggests that estradiol valerate may cause severe drug eruptions. Additionally, this case suggests that estrogen dermatitis may involve complex immune mechanisms, which warrants further research. The findings could lead to increased attention in pharmacovigilance related to hormone therapies. We speculate that estrogen dermatitis may combine effect of multiple factors (dendritic cell-mediated allergic mechanisms, inflammation-induced expression of estrogen receptor β , and elevated estrogen levels during pregnancy) according to previous studies. The future research might further explore the role of estrogen receptor β in allergic skin reactions. The patient is in early pregnancy and has a high level of estradiol, which is more likely to develop estrogen dermatitis. Therefore, before taking estradiol valerate, the patient should be carefully asked about the history of drug allergy and the corresponding medication education should be done. Once the patient developed manifestations such as rash, suspicious drugs were immediately discontinued and symptomatic treatment such as steroids or antihistamines was given. In the case of serious adverse drug reactions, screening diagnosis and symptomatic treatment should be carried out quickly to avoid misdiagnosis and ensure patient medication safety.

Data Sharing Statement

The data that support the findings of this study are available from the corresponding author upon reasonable request.

Ethics Statements

Written informed consent for publication of their clinical details and clinical images was obtained from the patient. No institutional approval from Shaoxing Keqiao Women & Children's Hospital was required for either the study of the case or publication of the case details.

Author Contributions

All authors made a significant contribution to the work reported, whether that is in the conception, study design, execution, acquisition of data, analysis and interpretation, or in all these areas; took part in drafting, revising or critically reviewing the article; gave final approval of the version to be published; have agreed on the journal to which the article has been submitted; and agree to be accountable for all aspects of the work.

Funding

This work was supported by a grant from the Zhejiang Provincial Medical Science and Technology Plan Project (2022KY419).

Disclosure

The authors report no conflicts of interest in this work.

References

1. Reap LE, Rodd C, Larios J, Marshall M. Hydrochlorothiazide-induced acute generalised exanthematous pustulosis presenting with bilateral periorbital impetigo. *BMJ Case Rep.* 2019;12(2). doi:10.1136/bcr-2017-223528
2. Le Guern A, Kerrad I, Oehler E. Severe cutaneous drug reactions to misused griseofulvin: 2 cases. *Ann Dermatol Venereol.* 2016;143(3):219–222. doi:10.1016/j.annder.2015.12.012
3. Olivier S, De Montjoye L, Tromme I, Baeck M. Two cases of annular acute generalized exanthematous pustulosis induced by terbinafine. *Eur J Dermatol.* 2018;28(2):236–238. doi:10.1684/ejd.2017.3199
4. Sarradin V, Dalenc F, Sibaud V, Tournier E, Roché H. Acute Generalized Exanthematous Pustulosis Induced by Docetaxel and Recurrent With Letrozole: a Case Report. *Clin Breast Canc.* 2018;18(5):e743–e746. doi:10.1016/j.clbc.2018.06.009
5. Kiley JW, Shulman LP. Estradiol valerate and dienogest: a new approach to oral contraception. *Int J Womens Health.* 2011;3:281–286. doi:10.2147/IJWH.S22645
6. Micks EA, Jensen JT. Treatment of heavy menstrual bleeding with the estradiol valerate and dienogest oral contraceptive pill. *Advances in Therap.* 2013;30(1). doi:10.1007/s12325-012-0071-3
7. Zhang L, Li M, Fan L, et al. Pharmacokinetics and Safety of Estradiol Valerate Tablet and Its Generic: a Phase 1 Bioequivalence Study in Healthy Chinese Postmenopausal Female Subjects. *Drug Des Devel Ther.* 2024;18:2891–2904. doi:10.2147/DDDT.S460681
8. Shelley WB, Shelley ED, Talanin NY, Santoso-Pham J. Estrogen dermatitis. *J Am Acad Dermatol.* 1995;32(1):25–31. doi:10.1016/0190-9622(95)90179-5
9. Leylek OA, Unlü S, Öztürkcan S, Cetin A, Sahin M, Yildiz E. Estrogen dermatitis. *Eur J Obstet Gynecol Reprod Biol.* 1997;72(1). doi:10.1016/s0301-2115(96)02657-7
10. Trubiano JA, Aung AK, Nguyen M, et al. A Comparative Analysis Between Antibiotic- and Nonantibiotic-Associated Delayed Cutaneous Adverse Drug Reactions. *J Allergy Clin Immunol Pract.* 2016;4(6):1187–1193. doi:10.1016/j.jaip.2016.04.026
11. Özkaya E, Kutlay A. Suppositories for fever as a major risk for phenobarbital-induced fixed drug eruption in children. *J Eur Acad Dermatol Ven.* 2017;31(10):e443–e444. doi:10.1111/jdv.14261
12. Orellana-Barrios M, Medrano Juarez R, Patel NJ. Fixed drug eruption associated with aspirin. *BMJ Case Rep.* 2018;2018. doi:10.1136/bcr-2017-222004
13. Morita K, Matsui H, Michihata N, Fushimi K, Yasunaga H. Association of Early Systemic Corticosteroid Therapy with Mortality in Patients with Stevens-Johnson Syndrome or Toxic Epidermal Necrolysis: a Retrospective Cohort Study Using a Nationwide Claims Database. *Am J Clin Dermatol.* 2019;20(4):579–592. doi:10.1007/s40257-019-00443-9
14. Liu W, Nie X, Zhang L. A retrospective analysis of Stevens-Johnson syndrome/toxic epidermal necrolysis treated with corticosteroids. *Int J Dermatol.* 2016;55(12):1408–1413. doi:10.1111/ijd.13379
15. Corazza M, Mantovani L, Montanari A, Virgili A. Allergic contact dermatitis from transdermal estradiol and systemic contact dermatitis from oral estradiol. A case report. *J Reprod Med.* 2002;47(6):507–509. doi:10.3109/01674820209042795
16. Bourgeault E, Bujold J, Doucet M-E. A Rare Case of Oestrogen Dermatitis. *J Cutan Med Surg.* 2017;21(3):261–262. doi:10.1177/1203475416685075
17. Elcin G, Gülseren D, Bayraktar M, Gunalp S, Gurgan T. Autoimmune estrogen dermatitis in an infertile female. *Cutan Ocul Toxicol.* 2017;36(2):195–198. doi:10.1080/15569527.2016.1245197
18. Yotsumoto S, Shimomai K, Hashiguchi T, et al. Estrogen dermatitis: a dendritic-cell-mediated allergic condition. *Dermatology.* 2003;207(3):265–268. doi:10.1159/000073088
19. Fukayama M, Asano Y, Shinozaki-Ushiku A, Sato S. Estrogen dermatitis: case report and examination of estrogen receptor- β in the skin. *J Dermatol.* 2019;46(3):263–266. doi:10.1111/1346-8138.14750

Clinical, Cosmetic and Investigational Dermatology

Dovepress

Publish your work in this journal

Clinical, Cosmetic and Investigational Dermatology is an international, peer-reviewed, open access, online journal that focuses on the latest clinical and experimental research in all aspects of skin disease and cosmetic interventions. This journal is indexed on CAS. The manuscript management system is completely online and includes a very quick and fair peer-review system, which is all easy to use. Visit <http://www.dovepress.com/testimonials.php> to read real quotes from published authors.

Submit your manuscript here: <https://www.dovepress.com/clinical-cosmetic-and-investigational-dermatology-journal>