

# Follow Up Care After Penile Sparing Surgery for Penile Cancer: Current Perspectives

Francesco Lasorsa<sup>1,2</sup>, Gabriele Bignante<sup>1,3</sup>, Angelo Orsini<sup>1,4</sup>, Sofia S Rossetti<sup>1</sup>, Michele Marchioni<sup>4</sup>, Francesco Porpiglia<sup>3</sup>, Pasquale Ditunno<sup>2</sup>, Giuseppe Lucarelli<sup>2</sup>, Riccardo Autorino<sup>1</sup>, Celeste Manfredi<sup>5</sup>

<sup>1</sup>Department of Urology, Rush University, Chicago, IL, USA; <sup>2</sup>Department of Precision and Regenerative Medicine and Ionian Area- Urology, Andrology and Kidney Transplantation Unit, University of Bari 'Aldo Moro', Bari, Italy; <sup>3</sup>Division of Urology, Department of Oncology, University of Turin, San Luigi Gonzaga Hospital, Orbassano, Turin, Italy; <sup>4</sup>Urology Unit, Department of Medical, Oral and Biotechnological Sciences, "G. d'Annunzio" University, Chieti, Italy; <sup>5</sup>Department of Woman, Unit of Urology, Child and General and Specialized Surgery, University of Campania "Luigi Vanvitelli" Naples Italy

Correspondence: Riccardo Autorino, Director of Surgical Innovation & Clinical Research, Department of Urology, Rush University Medical Center, 1725 W. Harrison Street, Suite 970, Chicago, IL, 60612, USA, Tel +1 312-563-7622, Email ricautor@gmail.com; riccardo\_autorino@rush.edu

**Abstract:** Penile cancer (PeCa) is a rare urologic tumor worldwide. In 2024, 2100 new cases and 500 deaths are estimated in the United States. Radical surgery via total penectomy has historically been the cornerstone of treatment, since it provides excellent long-term oncological control. The rationale of surgery for penile cancer was to achieve a 2 cm macroscopic surgical margin that is historically advocated to reduce recurrences. Over time, numerous studies have demonstrated that resection margin status does not affect patients' survival. Different penile-sparing techniques are currently recommended in the European Association of Urology-American Society of Clinical Oncology (EAU-ASCO) guidelines for the treatment of localized primary PeCa. Centralization of care could yield multiple benefits, including improved disease awareness, higher rates of penile-sparing surgery, enhanced detection rates, increased utilization of less invasive lymph node staging techniques, enhanced quality of specialized histopathological examinations, and the establishment of specialized multidisciplinary teams. Compared to more aggressive treatments, the higher recurrence rates after penile-sparing surgery do not hamper neither the metastasis-free survival nor the overall survival. Repeated penile-sparing surgery could be considered for selected cases. The psychological impact of penile cancer is not negligible since the perceived loss of masculinity might adversely affect mental health and overall well-being. Quality of life may be compromised by sexual and urinary dysfunction which may be the result either of the loss of penile tissue or the psychological status of the patient. It is of utmost importance to offer rehabilitative treatment as sexual therapy, physical therapy, occupational therapy, family and peer counseling.

**Keywords:** penile cancer, penile-sparing surgery, quality of life, sexual function, survival

## Introduction

Penile cancer (PeCa) is a rare urologic tumor worldwide, despite higher frequency in Brazil, India and Sub-Saharan Africa. In 2024, 2100 new cases and 500 deaths are estimated in the United States.<sup>1</sup> Squamous cell carcinoma (SCC) represents the main histological subtype of PeCa, with the glans penis and foreskin being its most common primary sites. In 2022, the World Health Organization (WHO) introduced subclassifications for both precursor and invasive tumors, distinguishing between those human papillomavirus (HPV)-associated and those HPV-independent.<sup>2</sup> Indeed, HPV, phimosis, and smoking history are well-known risk factors for PeCa.<sup>3</sup> Since clinical and histological examination are necessary, delayed diagnosis are usually the results of patients' shame and the lack of awareness of the disease.<sup>4</sup> Alcohol abuse and rural areas were revealed to contribute to delayed diagnosis in a study from China.<sup>5</sup> De Rose et al later investigated potential risk factors associated with delayed physician referral in a Northern Italian population. Education, extramarital relations, and sexual activity were found to influence the diagnosis. Specifically, higher levels of education, higher sexual activity, and extramarital affairs were associated with a shorter time to seek consultations.<sup>6</sup>

Nevertheless, approximately 40% of cases are identified in a localized stage, yielding a five-year survival rate close to 90%.<sup>7</sup> Radical surgery via total penectomy has historically been the cornerstone of treatment, since it provides excellent

long-term oncological control. However, it significantly affects cosmetic appearance, sexual and urinary function, with possible important psychological repercussions, resulting in a worsening of the patient's quality of life. Additionally, total penectomy is not always necessary to achieve satisfactory oncological outcomes.<sup>8</sup> This paved the way to the implementation of different penile-sparing surgical techniques for the treatment of localized PeCa.<sup>9</sup> Wide local excision (WLE) and partial penectomy resulted as the most common surgical strategies from a large population-based study.<sup>10</sup>

The assessment of primary tumor extension and the involvement of loco-regional lymph nodes also relies on imaging techniques as ultrasounds (US), computed tomography (CT) scan, and magnetic resonance imaging (MRI). Upon intracavernosal injection of prostaglandin E1, artificial erections were previously considered for MRI because of the increased blood flow. This invasive protocol is no longer mandatory as per the latest international guidelines. The advancement of functional sequences and contemporary multiparametric MRI (mpMRI) protocols enables non-invasive evaluations with accurate outlining of the tumor, which is crucial prior to organ-sparing surgery.<sup>11</sup>

The aim of this review is to provide a comprehensive analysis of the evidence currently available on penile-sparing surgery and to discuss follow-up strategies for these patients.

## Literature Search

A literature search was conducted in July 2024 using the Medline (via PubMed) database by searching publications up to date. Articles not in English, not original investigations (such as editorials, commentaries, or abstracts), studies reporting experimental studies on animals or cadavers, and studies not describing penile-sparing surgeries were excluded.

## Indications of Penile-Sparing Surgery

During the decision-making process for the surgical management of PeCa, several factors should be taken into consideration: tumor features (location, grade, and stage), patients' characteristics (length of penis, sexual function, comorbidities, possible adherence to follow-up, desires), and surgeons' expertise. Inevitably, a delayed diagnosis may compromise the feasibility of a penile-sparing surgery.

Different penile-sparing techniques are currently recommended in the European Association of Urology-American Society of Clinical Oncology (EAU-ASCO) guidelines for the treatment of localized primary PeCa (Table 1 and Figure 1).<sup>12,13</sup> These recommendations are based on T parameter, appearing quite flexible as the same procedure may generally be performed for different T stages.

In this context, total penectomy with perineal urethrostomy remains strongly recommended only for patients with large invasive primary tumors not amenable to partial amputation.

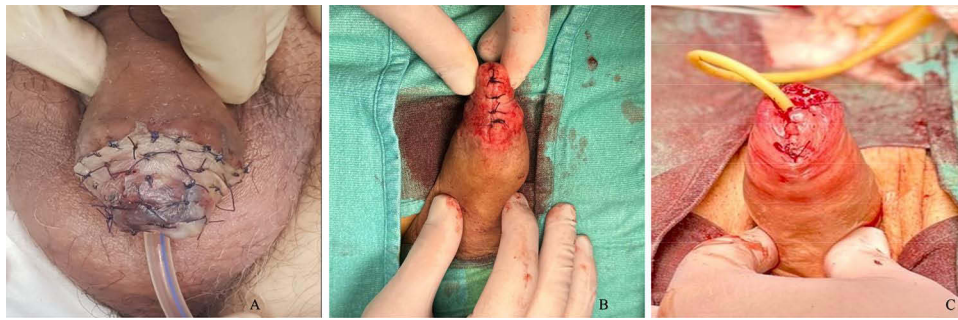
## Surgical Margins

Traditionally, the rationale of surgery for penile cancer was to achieve a 2 cm macroscopic surgical margin that is historically advocated to reduce recurrences. Over time, numerous studies have demonstrated that resection margin status

**Table 1** Indications for Penile-Sparing Surgery According to EAU-ASCO Guidelines 2024

Penile-sparing surgery	Tis	Ta	T1	T2	T3
Circumcision	+	+	+		
Glans resurfacing	+	+	+		
Laser ablation	+	+	+	±	
Wide local excision			+	+	
Glansectomy			+	+	
Partial penectomy				±	+

**Abbreviations:** +, indicated; ±, indicated in selected patients.



**Figure 1** Penile sparing techniques. a: glans resurfacing; b: wide local excision; c: partial penectomy.

does not hamper patients' survival. Philippou et al reported the long-term oncological outcomes of 179 patients who underwent penile-sparing surgery. During follow-up, 16 (8.9%) patients developed local recurrences, 19 (10.6%) regional metastases (groin or pelvic nodes) and 9 (5.0%) distant metastases. For patients experiencing local recurrence, the 5-year disease-specific survival (DSS) rate was 91.7%, whereas it was 38.4% for those with regional recurrence. Unlike tumor grade ( $p = 0.003$ ), stage ( $p = 0.021$ ), and lymphovascular invasion ( $p = 0.014$ ), the distance between tumor edge and surgical margin was not a predictor of local recurrence ( $p = 0.269$ ) so as the type of surgery ( $p = 0.220$ ) and histological subtype ( $p = 0.362$ ).<sup>14</sup> Similarly, grade 1 and grade 2 lesions were found not to microscopically extend beyond 10 mm to the macroscopic margins, whilst grade 3 lesions not beyond 15mm. Therefore, Agrawal et al<sup>15</sup> suggested that a 10 mm margin is sufficient for grade 1 or 2 penile SCC, while a 15 mm margin is recommended for grade 3 lesions. No significant difference in local recurrence was found between patients with margins  $<5$  mm versus  $>5$  mm, but  $<1$  mm margins significantly increased recurrence risk ( $p < 0.001$ ; RR = 5.9). Predictors of disease recurrence were lymphovascular invasion ( $p = 0.001$ ), T3 stage ( $p = 0.001$ ), grade 3 disease ( $p = 0.013$ ), and cavernosal involvement ( $p = 0.014$ ). Hence, the authors considered the embolic spread the backbone for the pathophysiology of local recurrences.<sup>16</sup> Intraoperative frozen section and re-operation in case of positive margins further allow to expand the option of penile-preserving surgery as a primary treatment for more patients.

## Penile-Sparing Procedures

### Moh's Micrographic Surgery (MMS)

This surgical technique was first described in the 1930s at the University of Wisconsin. It involves the removal of the lesion in a geometrical fashion in horizontal layers, followed by microscopic examination of all margins after fixation in zinc chloride or through frozen section analysis. Microscopically negative surgical margins are aimed.<sup>17</sup> Tis, Ta and T1 PeCa could benefit from this surgery. A 5-year recurrence-free survival of 79.3% was reported in the first series of patients who underwent MMS from 1936 to 1986.<sup>18</sup> Subsequently, a recurrence-free survival of 68% was noted in 33 patients after a total of 41 procedures.<sup>19</sup> In a cohort of 42 patients, the combined recurrence rate for both invasive and in situ SCC of the penis was 11.1%.<sup>20</sup> Lukowiak et al retrospectively reviewed a series of 119 cancers treated with MMS. The local recurrence was 0.84% and no patients complained about postoperative urinary and sexual disorders.<sup>21</sup> Postoperative meatal stenosis and urethral strictures may occur in case of urethral involvement of SCC or Tis. As data on MMS are currently very limited, EAU-ASCO guidelines does not routinely recommend this procedure.<sup>13</sup>

### Circumcision and WLE

Radical circumcision is a safe management option for patients with superficial tumors (Tis, Ta and T1), as penile lesions limited to the foreskin comprise 15.2% of cases. It eradicates the inflammatory environment which may foster the disease progression. PeCa involving the glans, and the penile shaft could require WLE, even in case of T2 lesions. Though its low sensitivity raises concerns, especially when it comes to HPV detection, acetic acid may be used to guide excision margins.<sup>22</sup> Topical 5-FU may be utilized as adjuvant therapy.<sup>23</sup> If sufficient penile skin remains after resection to prevent

any deformity, primary suture may be carried out. Alternatively, a skin flap or split thickness skin graft may be utilized to improve the cosmetic appearance.<sup>24</sup> Acceptable oncological outcomes are achieved with no local recurrences after treatment for Tis.<sup>25</sup> On the contrary, T2 penile carcinoma patients exhibited a 40% 5-year local recurrence rate.<sup>26</sup> Nonetheless, local recurrence rates was reported to range from 7.7% to 23% in patients with T1 or small T2 tumors in another series.<sup>27</sup>

## Glans Resurfacing

As first described for the treatment of severe lichen sclerosus, glans resurfacing requires the epithelial and subepithelial layers to be excised using sharp dissection and to spare the meatus.<sup>28</sup> A split-thickness skin graft may be applied to cover the defect. A split-thickness skin graft includes the epidermis and a partial layer of the dermis, and it is usually harvested from the thigh.<sup>29</sup> Using an air-driven or electric dermatome, a 0.04–0.06 cm-thick graft was described in recent reports.<sup>30</sup> It is regarded as the gold standard for the treatment of superficial PeCa (Tis, Ta and T1a) limited to the glans since it spares penile length and function. Previous studies noted recurrence rates ranging from 0 to 20% while positive margins ranged between 0 and 48%.<sup>31–34</sup> Falcone et al retrospectively reviewed surgical and oncological outcomes of 26 consecutive procedures. Minimal postoperative complications occurred along with only three cases of local recurrences which required salvage organ-sparing surgery. At one year, the overall survival rate was 100%.<sup>34</sup> Meatal stenosis, wound infection, graft contracture and graft loss were also described as postoperative complications.<sup>35–37</sup>

## Glansectomy

Partial or complete glansectomy is indicated either for the treatment of benign conditions (pyoderma gangrenosum, trauma, glans destruction due to radiotherapy) or PeCa of the glans penis (Ta, T1 and T2). Additionally, salvage glansectomy is also recommended in case of local recurrence after organ-sparing surgery.<sup>38</sup> A skin graft might be applied after the glans excision. The most common postoperative complications are wound infection, partial graft loss or failure, and meatal stenosis.<sup>30</sup> Meatal dilation, definitive meatoplasty or even distal urethroplasty may be considered afterwards.<sup>39</sup>

The rate of positive surgical margins were found to be less than 17% with local recurrences ranging between 0 to 18%, as well as cancer-specific mortality (0–18%).<sup>40–42</sup>

## Partial Penectomy

Invasive penile lesions (T2 or T3) extending into the corporal bodies or urethra necessitate more aggressive surgical resection, typically involving distal corporectomy or partial penectomy. The urethra is separated from the corporal bodies, spatulated, and sutured circumferentially to the penis' tip to form a neomeatus.<sup>43</sup> A skin graft might be used for the neo-glans. Alternatively, the penile shaft skin is advanced over the corpora and sutured in a circumferential manner around the neomeatus. A full-thickness skin graft (epidermis and the entire dermis) is necessary in the context of wider shaft reconstruction.<sup>44</sup> This approach aims to preserve some degree of sexual function and enable voiding in a standing position. Satisfying oncological outcomes were reported in previous series with low local recurrence rates.<sup>45,46</sup>

## Laser Therapy

Superficial PeCa (Tis, Ta, and T1) could be managed with laser ablation either as monotherapy or in combination with incisional or excisional biopsy. Neodymium: yttrium-aluminum-garnet (Nd:YAG) and CO<sub>2</sub> are commonly employed as sources of laser energy. The CO<sub>2</sub> laser enables histological examination and has a tissue penetration of 2–2.5 mm depth. More invasive lesions may be treated with the Nd:YAG laser since it has higher coagulative capacity and penetrates tissue more deeply (4–6 mm).<sup>47</sup> No intraoperative complications were noted in men treated with lasers; however, postoperative complications, including meatal stenosis and hemorrhage, developed in as many as 7% of patients.<sup>48,49</sup> Remarkably, the reported local recurrence rate ranged between 6% and 48% as well as disease progression occurred up to 30% of cases.<sup>50–52</sup> Musi et al retrospectively analyzed the oncological outcomes of 71 patients treated with thulium-yttrium-aluminum-garnet (Tm:YAG) laser ablation for superficial PeCa. Local recurrences involved 33 (50.3%) patients and required either organ-sparing surgery (laser ablation, glansectomy or partial penectomy) or total penectomy.

Compared to low-grade tumors (G1), high-grade PeCa (G3) emerged to be characterized by a higher risk of local recurrences (HR 6.1, 0.97–38.5,  $p = 0.05$ ). In total, disease progression occurred in 5 patients, constituting 7.5% of the cohort, while cancer-specific mortality was observed in two patients, accounting for 3.0% of the group.<sup>53,54</sup>

## Centralization of Care

Considering the low incidence of PeCa, a rising tendency is the centralization of care to high-volume hospitals to improve patients' outcomes.<sup>55</sup> Centralization of care could yield multiple benefits, including improved disease awareness, higher rates of penile-sparing surgery, enhanced detection rates, increased utilization of less invasive lymph node staging techniques (ie, dynamic sentinel lymph node biopsy [DSNB]), enhanced quality of specialized histopathological examinations, and the establishment of specialized multidisciplinary teams. Poor adherence to guidelines may result from non-standardized care as underutilization of surgical inguinal lymph node staging. This may negatively hamper oncological outcomes since the putative risk of harboring micrometastatic disease. At present, centralization of care has been only implemented in few European countries: United Kingdom, Norway, Sweden, Denmark, Netherlands, and Poland.<sup>24,56</sup> Pecoraro et al presented a detailed care pathway adopted in their tertial referral center. Since its adoption in 2015, a higher proportion of penile-sparing surgery has been performed without an increase of positive surgical margins. The length of stay was reduced and no differences in postoperative complications were detected. The authors further observed an increase in pathological groin staging from 35% to 96.3%. This increase reflects a heightened awareness of the potential for inguinal micrometastasis in patients with cN0 intermediate- or high-risk PeCa.<sup>57</sup> Nonetheless, centralization of care is not devoid of disadvantages as accessibility and travel logistics for patients and wait list and resource for referral center.

## Follow-Up and Post-Operative Management

Compared to more aggressive treatments, the higher recurrence rate after penile-sparing surgery was found not to affect neither the metastasis-free survival nor the overall survival.<sup>58</sup> Surveillance is therefore paramount as early recurrence detection may improve the chance of curative treatment. Local and most of regional lymph node recurrences typically occurs within the first 2 years following surgery. EAU guidelines recommend physical examination to be performed every 3 months in the first 2 years and every 6 months in the following 3 years (Table 2).<sup>13</sup> Salvage total amputation is traditionally performed in case of recurrences, thus jeopardizing the functional outcomes of the prior treatments.<sup>59</sup> Nonetheless, a repeated penile-sparing surgery could be considered for limited local ones. Musi et al acknowledged the technical feasibility and oncological safety of penile-sparing surgery for the recurrences after previous glansctomy or partial penectomy. Local excision, local excision + circumcision and laser ablation were used for the re-treatment of 13 patients. During a median follow-up of 41 months, three patients experienced additional local recurrences requiring WLE or salvage penectomy.<sup>60</sup>

**Table 2** Follow-Up Strategies According to EAU-ASCO Guidelines 2024

		Years 1–2		Years 3–5	
Primary tumor	Penile-sparing surgery	3-mo	Physical exam Re-biopsy after topical or laser ablation for Tis (optional)	6-mo	Physical exam Re-biopsy after topical or laser ablation for Tis (optional)
	Amputation	3-mo	Physical exam	Annually	Physical exam
Lymph nodes	Surveillance (pNx)	3-mo	Physical exam US ± FNAC (optional)	6-mo	Physical exam
	pN0	3-mo	Physical exam US ± FNAC (optional)	Annually	Physical exam US ± FNAC (optional)
	pN+	3-mo	Physical exam US ± FNAC, CT or 18FDG-PET/CT (optional)	6-mo	Physical exam US ± FNAC, CT or 18FDG-PET/CT (optional)

**Abbreviations:** US, ultrasound; FNAC, fine needle aspiration cytology; CT, computed tomography; 18FDG, 18F-fluoro-2-deoxy-D-glucose; PET, positron emission tomography.

The psychological impact of penile cancer is not negligible since it includes the effects of the surgical treatment in addition to emotional stress provoked by the tumor diagnosis itself. The perceived loss of masculinity might adversely affect mental health and overall well-being, potentially leading to conditions such as anxiety, depression, post-traumatic stress disorders (PTSD), and other psychological disorders.<sup>61</sup> These might have extensive consequences, including disability, concurrent health issues, suicidal ideation, reduced socioeconomic status, increased caregiver responsibilities and medical costs, and diminished quality of life.<sup>62,63</sup> The health-related quality of life (HRQoL) may be investigated by administering validated questionnaire such as the European Organization for Research and Treatment of Cancer (EORTC QLQ-C30). Global health status, physical, role (work and home activity), emotional and social functioning are the five sub-scales that make up the EORTC QLQ-C30, which is composed of thirty questions. Notably, controversial results were achieved when comparing amputation to penile-sparing surgery in term of the reported quality of life. On one hand, Sosnowski et al highlighted that it decreases with increased surgical aggressiveness (total penectomy vs penile-sparing surgery).<sup>64</sup> On the other hand, comparable results were found when using the EuroQoL-5D-3L (EQ-5D) and the Short Form Health Survey (SF-36) tools.<sup>65</sup>

Quality of life may be compromised by sexual dysfunction, which may be the result either of the loss of penile tissue or the psychological status of the patient (ie, shame or fear of rejection).<sup>66,67</sup> Patients might even opt for preserved sexual potency rather than longer survival. A significant reduction in erectile and orgasmic function, sexual desire and intercourse satisfaction was reported in a series of partial penectomy.<sup>68</sup> In turn, different studies confirmed positive outcomes in terms of sexual function after penile-sparing surgery for PeCa, as in case of laser ablation, circumcision, and WLE.<sup>69</sup> A higher orgasmic function was recognized after other penile-sparing surgery by Kieffer et al<sup>70</sup> A full recovery of rigid erections, preserved libido and ejaculation was assessed after glansectomy through the International Index of Erectile Function Questionnaire (IIEF).<sup>71</sup> Cilio et al recently compared the sexual results of men treated with WLE or glansectomy according to IIEF in its 5-item form (IIEF-5) and the Changes in Sexual Function Questionnaire (CSFQ). Worse scores were shown in the cohort of glansectomy than WLE. Individuals with diabetes who underwent glansectomy were found to have a greater risk of developing erectile dysfunction, especially among younger patients.<sup>72</sup> Glansectomy inevitably reduces glanular sensation during intercourse.

Penile reconstruction or phalloplasty is another outstanding scenario, which might arise after total penectomy or organ-sparing surgery where the functional penile length is inadequate. Microsurgical techniques are required to transfer either free or pedicled flaps usually from the radial forearm, the anterolateral thigh, the latissimus dorsi or the abdomen. Afterwards, an erectile device may be implanted at a later stage.<sup>73</sup> Garaffa et al described functional and cosmetic outcomes of 15 successful phalloplasties after total penectomy for PeCa.<sup>74</sup> Penile transplantation could eventually become a future alternative to reconstruction even for PeCa patients. To date, a single case of transplantation has been performed after partial penectomy for PeCa.<sup>75</sup>

In case of surgery for PeCa, assessing sexual function via IIEF has some limitations since it is not applicable to individuals who perform self-stimulation or obtain sexual excitement through methods other than penetrative intercourse.

Urinary function might be involved by cancer surgery, and it is commonly evaluated through the International Consultation on Incontinence Modular Questionnaire for Male Lower Urinary Tract Symptoms (ICIQ-MLUTS) or its long form (ICIQ-MLUTS LF). Despite urine spraying being more frequent after partial penectomy, no significant differences were revealed among different penile-sparing surgeries in term of functional results.<sup>76</sup> Remarkably, the ability to void while standing was confirmed in all patients who underwent partial penectomy with an inverted urethral flap.<sup>77</sup>

Unaddressed needs in patients following penile cancer treatment include communication between patients and clinicians, access to health system information, spiritual support, and interpersonal and intimate relationships, among other aspects.<sup>78</sup> Therefore, it is of utmost importance to offer rehabilitative treatment as sexual therapy, physical therapy, occupational therapy, family and peer counseling.

## Conclusions

A variety of organ-sparing surgeries provide acceptable oncological control together with optimal functional and aesthetic results. Since there are no international recommendations regarding which strategy to prefer, each treatment should be individualized considering tumor, patient and surgeon factors. The glans and foreskin represent the main sites

of the development of penile cancer, thus allowing less demolitive surgery. Local recurrences could be experienced so patients need close monitoring (self-examination and physician evaluation). Recognizing and addressing emotional stress is critically important, and ensuring timely referral to therapists and psychiatric support services is essential for effectively improving overall quality of life.

## Disclosure

The authors report no conflicts of interest in this work.

## References

1. Siegel RL, Giaquinto AN, Jemal A. Cancer statistics, 2024. *Ca a Cancer J Clin.* 2024;74(1):12–49. doi:10.3322/caac.21820
2. Menon S, Moch H, Berney DM, et al. WHO 2022 classification of penile and scrotal cancers: updates and evolution. *Histopathology.* 2023;82(4):508–520. doi:10.1111/his.14824
3. Amicuzi U, Grillo M, Stizzo M, et al. Exploring the multifactorial landscape of penile cancer: a comprehensive analysis of risk factors. *Diagnostics.* 2024;14(16):1790. doi:10.3390/diagnostics14161790
4. Marchioni M, Berardinelli F, De Nunzio C, et al. New insight in penile cancer. *Minerva Urol Nefrol.* 2018;70(6). doi:10.23736/S0393-2249.18.03215-0
5. Gao W, Song L, Yang J, et al. Risk factors and negative consequences of patient's delay for penile carcinoma. *World J Surg Oncol.* 2016;14(1):124. doi:10.1186/s12957-016-0863-z
6. De Rose AF, Mantica G, Gallo F, et al. Risk factors for the delay in the diagnosis of penile lesions: results from a single center in Italy. *Minerva Urol Nefrol.* 2019;71(3):258–263. doi:10.23736/S0393-2249.18.03189-2
7. Scornajenghi CM, Asero V, Bologna E, et al. Organ-sparing treatment for T1 and T2 penile cancer: an updated literature review. *Curr Opin Urol.* 2023;33(5):383–389. doi:10.1097/MOU.0000000000001109
8. Emmanuel A, Watkin N. Update on organ preserving surgical strategies for penile cancer. *J Urol Oncol.* 2022;40(5):179–183. doi:10.1016/j.urolonc.2021.01.012
9. White J, Mason R, Lawen T, et al. Therapeutic approaches to penile cancer: standards of care and recent developments. *RRU.* 2023;15:165–174. doi:10.2147/RRU.S387228
10. Bologna E, Licari LC, Franco A, et al. Characteristics, trends, and management of penile cancer in the United States: a population-based study. *Urol Oncol.* 2024;42(10):334.e11–334.e18. doi:10.1016/j.urolonc.2024.05.013
11. Switlyk MD, Hopland A, Reitan E, et al. Multiparametric magnetic resonance imaging of penile cancer: a pictorial review. *Cancers.* 2023;15(22):5324. doi:10.3390/cancers15225324
12. Fallara G, Basile G, Poterek A, et al. Oncological and functional outcomes of penile shaft sparing surgery for localised penile cancer: a systematic review. *European Urol Focus.* 2024. doi:10.1016/j.euf.2024.05.004
13. *EAU Guidelines. Edn. Presented at the EAU Annual Congress Paris 2024;* EAU Guidelines Office, Arnhem, the Netherlands; ISBN: 978-94-92671-23-3.
14. Philippou P, Shabbir M, Malone P, et al. Conservative surgery for squamous cell carcinoma of the penis: resection margins and long-term oncological control. *J Urol.* 2012;188(3):803–808. doi:10.1016/j.juro.2012.05.012
15. Agrawal A, Pai D, Ananthkrishnan N, Smile SR, Ratnakar C. The histological extent of the local spread of carcinoma of the penis and its therapeutic implications. *BJU Int.* 2000;85(3):299–301. doi:10.1046/j.1464-410x.2000.00413.x
16. Sri D, Sujenthiran A, Lam W, et al. A study into the association between local recurrence rates and surgical resection margins in organ-sparing surgery for penile squamous cell cancer. *BJU Int.* 2018;122(4):576–582. doi:10.1111/bju.14222
17. Mohs FE, Snow SN, Messing EM, Kuglitsch ME. Microscopically controlled surgery in the treatment of carcinoma of the penis. *J Urol.* 1985;133(6):961–966. doi:10.1016/s0022-5347(17)49334-7
18. Mohs FE, Snow SN, Larson PO. Mohs micrographic surgery for penile tumors. *Urol Clin North Am.* 1992;19(2):291–304. doi:10.1016/S0094-0143(21)00392-X
19. Shindel AW, Mann MW, Lev RY, et al. Mohs micrographic surgery for penile cancer: management and long-term followup. *J Urol.* 2007;178(5):1980–1985. doi:10.1016/j.juro.2007.07.039
20. Machan M, Brodland D, Zitelli J. Penile squamous cell carcinoma: penis-preserving treatment with mohs micrographic surgery. *Dermatol Surg.* 2016;42(8):936–944. doi:10.1097/DSS.0000000000000795
21. Lukowiak TM, Perz AM, Aizman L, et al. Mohs micrographic surgery for male genital tumors: local recurrence rates and patient-reported outcomes. *J Am Acad Dermatol.* 2021;84(4):1030–1036. doi:10.1016/j.jaad.2020.11.060
22. Figliuolo G, Maia J, Jalkh AP, Miranda AE, Ferreira LCL. Clinical and laboratorial study of HPV infection in men infected with HIV. *Int Braz J Urol.* 2012;38(3):411–418. doi:10.1590/s1677-55382012000300015
23. Pang KH, Alnajjar HM, Muneer A. Advances in penile-sparing surgical approaches. *Asian J Urol.* 2022;9(4):359–373. doi:10.1016/j.ajur.2022.02.005
24. Hogan D, Norton SM, Patterson K, et al. Phallus preservation and reconstruction: 5-year outcomes of national penile cancer centralisation in the Republic of Ireland. *Surgeon.* 2024;22(5):292–295. doi:10.1016/j.surge.2024.04.002
25. Chipollini J, Yan S, Ottenhof SR, et al. Surgical management of penile carcinoma *in Situ*: results from an international collaborative study and review of the literature. *BJU Int.* 2018;121(3):393–398. doi:10.1111/bju.14037
26. Baumgarten A, Chipollini J, Yan S, et al. Penile sparing surgery for penile cancer: a multicenter international retrospective cohort. *J Urol.* 2018;199(5):1233–1237. doi:10.1016/j.juro.2017.10.045
27. Bissada NK, Yakout AH, Fahmy WE, et al. Multi-institutional long-term experience with conservative surgery for invasive penile carcinoma. *J Urol.* 2003;169(2):500–502. doi:10.1097/01.ju.0000043808.58188.52

28. Depasquale I, Park AJ, Bracka A. The treatment of balanitis xerotica obliterans. *BJU Int.* 2000;86(4):459–465. doi:10.1046/j.1464-410x.2000.00772.x
29. Braza ME, Fahrenkopf MP. Split-thickness skin grafts. In: *StatPearls*. Treasure Island (FL): StatPearls Publishing; 2024.
30. Parnham AS, Albersen M, Sahdev V, et al. Glansectomy and split-thickness skin graft for penile cancer. *Eur Urol.* 2018;73(2):284–289. doi:10.1016/j.eururo.2016.09.048
31. Ayres B, Lam W, Al-Najjar H, Corbishley C, Perry M, Watkin N. 746 ONCOLOGICAL OUTCOMES OF GLANS RESURFACING IN THE TREATMENT OF SELECTED SUPERFICIALLY INVASIVE PENILE CANCERS. *J Urol.* 2012;187(4S). doi:10.1016/j.juro.2012.02.832
32. Hadway P, Corbishley CM, Watkin NA. Total glans resurfacing for premalignant lesions of the penis: initial outcome data. *BJU Int.* 2006;98(3):532–536. doi:10.1111/j.1464-410X.2006.06368.x
33. Cakir OO, Schifano N, Venturino L, et al. Surgical technique and outcomes following coronal-sparing glans resurfacing for benign and malignant penile lesions. *Int J Impot Res.* 2022;34(5):495–500. doi:10.1038/s41443-021-00452-5
34. Falcone M, Preto M, Oderda M, et al. EAU-YAU men's health working group total glans resurfacing for the management of superficial penile cancer: a retrospective cohort analysis in a tertiary referral center. *Urology.* 2020;145:281–286. doi:10.1016/j.urology.2020.06.066
35. Veeratterapillay R, Sahadevan K, Aluru P, Asterling S, Rao GS, Greene D. Organ-preserving surgery for penile cancer: description of techniques and surgical outcomes. *BJU Int.* 2012;110(11):1792–1795. doi:10.1111/j.1464-410X.2012.11084.x
36. Håkansson U, Kirrander P, Uvelius B, Baseckas G, Torbrand C. Organ-Sparing reconstructive surgery in penile cancer: initial experiences at two Swedish referral centres. *Scand J Urol.* 2015;49(2):149–154. doi:10.3109/21681805.2014.955822
37. Shabbir M, Muneer A, Kalsi J, et al. Glans resurfacing for the treatment of carcinoma in situ of the penis: surgical technique and outcomes. *Eur Urol.* 2011;59(1):142–147. doi:10.1016/j.eururo.2010.09.039
38. Bracka A. Glans resection and plastic repair. *BJU Int.* 2010;105(1):136–144. doi:10.1111/j.1464-410X.2009.09087.x
39. Falcone M, Preto M, Blecher G, et al. The outcomes of glansectomy and split thickness skin graft reconstruction for invasive penile cancer confined to glans. *Urology.* 2022;165:250–255. doi:10.1016/j.urology.2022.01.010
40. Morelli G, Pagni R, Mariani C, et al. Glansectomy with split-thickness skin graft for the treatment of penile carcinoma. *Int J Impot Res.* 2009;21(5):311–314. doi:10.1038/ijir.2009.17
41. Beech BB, Chapman DW, Rourke KF. Clinical outcomes of glansectomy with split-thickness skin graft reconstruction for localized penile cancer. *Can Urol Assoc J.* 2020;14(10):E482–E486. doi:10.5489/cuaj.6277
42. Falcone M, Oderda M, Callaris G, Peretti F, Gontero P. Surgical outcomes of glansectomy and split thickness skin graft reconstruction for localized penile cancer. *Urology.* 2021;152:195. doi:10.1016/j.urology.2021.03.022
43. Sansalone S, Garaffa G, Vespasiani G, et al. Glans reconstruction with the use of an inverted urethral flap after distal penile amputation for carcinoma. *Arch Ital Urol Androl.* 2013;85(1):24–27. doi:10.4081/aiua.2013.1.24
44. Kristinsson S, Johnson M, Ralph D. Review of penile reconstructive techniques. *Int J Impot Res.* 2021;33(3):243–250. doi:10.1038/s41443-020-0246-4
45. Korets R, Koppie TM, Snyder ME, Russo P. Partial penectomy for patients with squamous cell carcinoma of the penis: the memorial sloan-kettering experience. *Ann Surg Oncol.* 2007;14(12):3614–3619. doi:10.1245/s10434-007-9563-9
46. Ornellas AA, Kinchin EW, Nóbrega BLB, Wisnesky A, Koifman N, Quirino R. Surgical treatment of invasive squamous cell carcinoma of the penis: Brazilian national cancer institute long-term experience. *J Surg Oncol.* 2008;97(6):487–495. doi:10.1002/jso.20980
47. Tang DH, Yan S, Ottenhof SR, et al. Laser ablation as monotherapy for penile squamous cell carcinoma: a multi-center cohort analysis. *Urol Oncol.* 2018;36(4):147–152. doi:10.1016/j.urolonc.2017.09.028
48. Lont AP, Gallee MPW, Meinhardt W, van Tinteren H, Horenblas S. Penis conserving treatment for T1 and T2 penile carcinoma: clinical implications of a local recurrence. *J Urol.* 2006;176(2):575–580. doi:10.1016/j.juro.2006.03.063
49. Bandieramonte G, Colecchia M, Mariani L, et al. Peniscopically controlled co2 laser excision for conservative treatment of in situ and T1 penile carcinoma: report on 224 patients. *Eur Urol.* 2008;54(4):875–882. doi:10.1016/j.eururo.2008.01.019
50. Tewari M, Shukla HS, Shukla HS. Nd:YAG laser treatment of early stage carcinoma of the penis preserves form and function of penis. *Asian J Surg.* 2007;30(2):126–130. doi:10.1016/S1015-9584(09)60145-7
51. Meijer RP, Boon TA, van Venrooij GEPM, Wijburg CJ. Long-term follow-up after laser therapy for penile carcinoma. *Urology.* 2007;69(4):759–762. doi:10.1016/j.urology.2007.01.023
52. Schlenker B, Tilki D, Gratzke C, et al. Intermediate-differentiated invasive (pT1 G2) penile cancer--oncological outcome and follow-up. *Urol Oncol.* 2011;29(6):782–787. doi:10.1016/j.urolonc.2009.08.022
53. Musi G, De Cobelli O, Molinari F, et al. Oncological outcomes of thulium-yttrium-aluminum-garnet (Tm:YAG) laser ablation for penile cancer. *Urology.* 2024;184:149–156. doi:10.1016/j.urology.2023.09.064
54. Musi G, Russo A, Conti A, et al. Thulium-yttrium-aluminium-garnet (Tm:YAG) laser treatment of penile cancer: oncological results, functional outcomes, and quality of life. *World J Urol.* 2018;36(2):265–270. doi:10.1007/s00345-017-2144-z
55. Diaz KA, Spiess PE, García-Perdomo HA. Patient-reported outcomes in penile cancer patients: quality of life, sexual and urinary function. what do we know? *Urology.* 2022;169:1–5. doi:10.1016/j.urology.2022.08.021
56. Wnętrzak I, Czajkowski M, Barańska K, et al. Epidemiology of penile cancer in Poland compared to other European countries. *Cancer Med.* 2024;13(16):e70092. doi:10.1002/cam4.70092
57. Pecoraro A, Elst L, Roussel E, et al. Impact of the standardization of penile cancer care on the quality of care, outcomes, and academic-driven centralization in a single eurogen referral center. *European Urol Focus.* 2024;10(1):57–65. doi:10.1016/j.euf.2023.07.003
58. Lindner AK, Schachtner G, Steiner E, et al. Organ-sparing surgery of penile cancer: higher rate of local recurrence yet no impact on overall survival. *World J Urol.* 2020;38(2):417–424. doi:10.1007/s00345-019-02793-9
59. Saidian A, Ceballos B, Necchi A, Baumgarten AS, Spiess PE. Salvage therapy for localized recurrences of penile cancer. *Curr Opin Urol.* 2021;31(3):214–219. doi:10.1097/MOU.0000000000000871
60. Musi G, Molinari F, Mistretta FA, et al. Penile-sparing surgery for tumour recurrence after previous glansectomy/partial penectomy: treatment feasibility and oncological outcomes. *Cancers.* 2023;15(19):4807. doi:10.3390/cancers15194807
61. Simpson WG, Klaassen Z, Jen RP, Hughes WM, Neal DE, Terris MK. Analysis of suicide risk in patients with penile cancer and review of the literature. *Clin Genitourin Cancer.* 2018;16(2):e257–e261. doi:10.1016/j.clgc.2017.09.011

62. Maddineni SB, Lau MM, Sangar VK. Identifying the needs of penile cancer sufferers: a systematic review of the quality of life, psychosexual and psychosocial literature in penile cancer. *BMC Urol.* 2009;9(1):1–6. doi:10.1186/1471-2490-9-8
63. Witty K, Branney P, Evans J, Bullen K, White A, Eardley I. The impact of surgical treatment for penile cancer – patients’ perspectives. *Eur J Oncol Nurs.* 2013;17(5):661–667. doi:10.1016/j.ejon.2013.06.004
64. Sosnowski R, Wolski JK, Kulpa M, et al. Assessment of quality of life in patients surgically treated for penile cancer: impact of aggressiveness in surgery. *Eur J Oncol Nurs.* 2017;31:1–5. doi:10.1016/j.ejon.2017.08.011
65. Pérez J, Chavarriaga J, Ortiz A, et al. Oncological and functional outcomes after organ-sparing plastic reconstructive surgery for penile cancer. *Urology.* 2020;142:161–165.e1. doi:10.1016/j.urology.2020.03.058
66. Stroe FA, Houlihan MD, Kohler TS. Sexual function in the penile cancer survivor: a narrative review. *Transl Androl Urol.* 2021;10(6):2544–2553. doi:10.21037/tau-20-1228
67. Sakalis VI, Campi R, Barreto L, et al. What is the most effective management of the primary tumor in men with invasive penile cancer: a systematic review of the available treatment options and their outcomes. *European Urol Open Sci.* 2022;40:58–94. doi:10.1016/j.euros.2022.04.002
68. Dos S. Romero FR, Romero KRP, de Mattos MAE, Garcia CRC, de Fernandes RC, Perez MDC. Sexual function after partial penectomy for penile cancer. *Urology.* 2005;66(6):1292–1295. doi:10.1016/j.urology.2005.06.081
69. Windahl T, Skeppner E, Andersson S-O, Fugl-Meyer KS. Sexual function and satisfaction in men after laser treatment for penile carcinoma. *J Urol.* 2004;172(2):648–651. doi:10.1097/01.ju.0000132891.68094.87
70. Kieffer JM, Djajadiningrat RS, van Muilekom EAM, Graafland NM, Horenblas S, Aaronson NK. Quality of life for patients treated for penile cancer. *J Urol.* 2014;192(4):1105–1110. doi:10.1016/j.juro.2014.04.014
71. Gulino G, Sasso F, Palermo G, et al. Sexual outcomes after organ potency-sparing surgery and glans reconstruction in patients with penile carcinoma. *Indian J Urol.* 2013;29(2):119–123. doi:10.4103/0970-1591.114033
72. Cilio S, Tufano A, Pezone G, et al. Sexual outcomes after conservative management for patients with localized penile cancer. *Curr Oncol.* 2023;30(12):10501–10508. doi:10.3390/curroncol30120765
73. Lee WG, Christopher AN, Ralph DJ. Phalloplasty following penectomy for penile cancer. *Asian J Urol.* 2022;9(4):460–466. doi:10.1016/j.ajur.2022.05.005
74. Garaffa G, Raheem AA, Christopher NA, Ralph DJ. Total phallic reconstruction after penile amputation for carcinoma. *BJU Int.* 2009;104(6):852–856. doi:10.1111/j.1464-410X.2009.08424.x
75. Lopez CD, Girard AO, Lake IV, et al. Lessons learned from the first 15 years of penile transplantation and updates to the Baltimore criteria. *Nat Rev Urol.* 2023;20(5):294–307. doi:10.1038/s41585-022-00699-7
76. Torres Irizarry VM, Paster IC, Ogbuji V, Gomez DM, McCormick K, Chipollini J. Improving quality of life and psychosocial health for penile cancer survivors: a narrative review. *Cancers.* 2024;16(7):1309. doi:10.3390/cancers16071309
77. Chavarriaga J, Becerra L, Camacho D, et al. Inverted urethral flap reconstruction after partial penectomy: long-term oncological and functional outcomes. *Urol Oncol.* 2022;40(4):169.e13–169.e20. doi:10.1016/j.urolonc.2022.02.006
78. Paterson C, Primeau C, Bowker M, et al. What are the unmet supportive care needs of men affected by penile cancer? A systematic review of the empirical evidence. *Eur J Oncol Nurs.* 2020;48:101805. doi:10.1016/j.ejon.2020.101805

## Research and Reports in Urology

Dovepress

### Publish your work in this journal

Research and Reports in Urology is an international, peer-reviewed, open access journal publishing original research, reports, editorials, reviews and commentaries on all aspects of adult and pediatric urology in the clinic and laboratory including the following topics: Pathology, pathophysiology of urological disease; Investigation and treatment of urological disease; Pharmacology of drugs used for the treatment of urological disease. The manuscript management system is completely online and includes a very quick and fair peer-review system, which is all easy to use. Visit <http://www.dovepress.com/testimonials.php> to read real quotes from published authors.

Submit your manuscript here: <https://www.dovepress.com/research-and-reports-in-urology-journal>