

Correlation Between Reduced IL-1 β Levels in Acne Lesions and the Decrease in Acne Inflammatory Lesions Following Topical Vitamin D Administration: A Double-Blind Randomized Controlled Trial

Nelly Herfina Dahlan^{1,*}, Irma Bernadette S Sitohang^{1,*}, Wresti Indriatmi¹, Heri Wibowo², Liani Elisabeth Enggy³

¹Department of Dermatology and Venereology, Faculty of Medicine, University of Indonesia, Dr. Cipto Mangunkusumo Hospital, Jakarta, Indonesia; ²Department of Integrated Laboratory, Faculty of Medicine, University of Indonesia, Dr. Cipto Mangunkusumo Hospital, Jakarta, Indonesia; ³Faculty of Medicine, Hasanuddin University, Makassar, Indonesia

*These authors contributed equally to this work

Correspondence: Irma Bernadette S Sitohang, Department of Dermatology and Venereology, Faculty of Medicine, Universitas Indonesia, dr. Cipto Mangunkusumo Hospital, Jalan Salemba Raya No. 6, Jakarta, 10430, Indonesia, Email irma_bernadette@yahoo.com

Background: The inflammatory process in acne vulgaris (AV) is characterized by the upregulation of specific pro-inflammatory cytokines, including interleukin (IL)-1 β , IL-6, and IL-8, within sebocytes and keratinocytes. Sebocytes have been identified as target cells for bioactive vitamin D. Experimental studies on animal models have demonstrated the potent comedolytic effects of topical vitamin D. However, further research is required to specifically evaluate the impact of vitamin D on inflammatory lesions in acne vulgaris (AV).

Objective: To evaluate the effectiveness of topical vitamin D in treating acne vulgaris (AV) lesions by investigating its anti-inflammatory effects on pro-inflammatory cytokine modulation, specifically assessing the correlation between IL-1 β levels in acne lesions and the reduction in AV severity.

Materials and Methods: This study is a double-blind, randomized, placebo-controlled clinical trial with a 2-arm design over an 8-week intervention period. Participants were randomly assigned to either the topical vitamin D group (cholecalciferol 50 mcg) or the topical placebo group, with each group comprising 32 subjects. All participants received concomitant treatment with topical adapalene 0.1%. Cytokine levels within acne lesions were assessed using Luminex Polystyrene Screening Assays to detect and quantify IL-1 β levels. The effectiveness of the treatment was evaluated by monitoring the reduction in the number of inflammatory lesions, while the safety of topical vitamin D was assessed by documenting and analyzing any reported side effects.

Results: The study found a significant correlation between the reduction in IL-1 β levels within acne lesions and the decrease in moderate and severe inflammatory lesions in acne vulgaris ($p = 0.028$). The topical application of vitamin D led to a significant reduction in inflammatory AV lesions ($p = 0.045$). No significant topical side effects were observed in either the vitamin D or placebo groups.

Conclusion: This study demonstrates that the topical administration of vitamin D in acne vulgaris (AV) lesions is effective in reducing pro-inflammatory cytokine levels within acne lesions and in decreasing the severity of AV.

Trial Registration: NCT05758259. September 5, 2022.

Keywords: acne vulgaris, topical vitamin D, IL-1 β , Luminex

Introduction

Acne vulgaris (AV) is an inflammatory disorder affecting the pilosebaceous gland unit. The etiology of AV is multifactorial, involving an increased rate of sebum production, endocrinological influences such as androgens, abnormal keratinization of the follicular infundibulum, proliferation of *Cutibacterium acnes*, and subsequent inflammatory responses.^{1,2} The inflammatory process plays a critical role in the pathogenesis of acne vulgaris (AV).² Locally activated infiltrating cells release cytokines, including interleukin 1 β (IL-1 β), IL-6, IL-8, IL-12, and tumor necrosis factor α (TNF- α), from macrophages, keratinocytes, and sebocytes. Among the proinflammatory mediators, IL-1 β has been detected in various active forms within acne lesions. IL-1 β is a cytokine that plays a crucial role in regulating the inflammatory response and serves as an initial mediator released during both acute and chronic inflammation.^{3,4} Kistowska et al⁵ states that the production of IL-1 β by *C. acnes*-exposed monocytic cells requires activation of the NOD-like receptor protein 3 (NLRP3) inflammasome, triggered by a wide variety of signals, including danger-associated molecular patterns (DAMPs), pathogen-associated molecular patterns (PAMPs), and bacterial toxins. This suggests that IL-1 β could be a promising therapeutic target in the treatment of AV.^{6,7}

Vitamin D regulates various skin functions, including keratinocyte proliferation, differentiation, apoptosis, and immunoregulation. Additionally, it possesses antioxidant and anti-comedogenic properties, contributing to its potential therapeutic benefits in skin conditions.⁸ Some studies have linked various cytokines to AV.⁹ Research by Lee et al¹⁰ reported that vitamin D reduces inflammatory biomarkers, including IL-6, IL-8, and metalloproteinase matrix-9 (MMP-9), in cultured sebocyte cells. A study by Agak et al¹¹ reported that *all-trans retinoic acid* (ATRA) and 1.25D3 can inhibit toll-like receptor 2 (TLR2) expression in monocytes by negatively regulating the transcription factors IL-17, *retinoic acid receptor alpha* (RAR α), and retinoic acid receptor-related orphan receptor gamma (RORc). This suggests that sebocytes, identified as target cells for bioactive vitamin D and its analogues, may serve as effective targets in the treatment of acne vulgaris (AV).¹² Topical vitamin D has demonstrated strong comedolytic effects in experimental animal studies; however, no research findings have been reported to date regarding its effects in patients with acne vulgaris (AV).

This study aimed to evaluate the effectiveness of topical vitamin D administration in treating acne vulgaris (AV) lesions by examining its anti-inflammatory effects on pro-inflammatory cytokine changes. Specifically, it assessed the correlation between the reduction in IL-1 β cytokine levels within acne lesions and the decrease in AV severity following topical vitamin D administration.

Materials and Methods

Research Design

This study employed a double-blind, randomized clinical trial with a two-arm design to evaluate the reduction in inflammatory lesions in acne vulgaris (AV) following an 8-week intervention with topical vitamin D. Additionally, an observational cohort design was used to assess the correlation between changes in IL-1 β levels in acne lesions and the reduction in inflammatory AV lesions after subjects received topical vitamin D treatment.

Place and Time of Research

This research was conducted at the Polyclinic of the Cosmetic Dermatology Division, Department of Dermatology and Venereology, FKUI/RSUPN dr. Cipto Mangunkusumo, and the Integrated Laboratory of FKUI/RSUPN dr. Cipto Mangunkusumo, Jakarta, Indonesia in February-August 2023.

Patients with acne vulgaris were consecutively recruited from the Cosmetic Dermatology Polyclinic of the Department of Dermatology and Venereology. All participants provided signed informed consent to participate in the study. The inclusion criteria were men and women aged 18–50 years, diagnosed with moderate to severe acne vulgaris, who had not used any skincare products, either oral or topical, on the face, and had not undergone treatments outside the standard AV therapy. The exclusion criteria for this study included: women who are pregnant or breastfeeding; a history of topical antibiotic use in the last two weeks; a history of topical corticosteroid use in the last 2 weeks; a history of vitamin D supplement use in the last one month; a history of oral antibiotic use in the last one month; a history of oral corticosteroid use in the last 1 month; a history of oral or topical retinoid use in the last 3 months; a history of topical

benzoyl peroxide (BPO) use in the last 1 month; the use of hormonal contraceptives in women; a history of drug allergies or skin disorders due to side effects of first-line moderate or severe acne vulgaris therapy; and impaired liver or kidney function. The patient's personal medical history, clinical examination, and laboratory analysis of the contents from acne lesions were conducted as part of the assessment.

Interventions

The study divided the subjects into two groups: one group received topical vitamin D (Topical cholecalciferol 50 mcg applied twice a day), while the other group received a placebo twice a day. All subjects received topical adapalene 0.1% applied every night as a standard treatment for acne. The intervention was conducted over an 8-week period. Subjects were randomized using permutation randomization techniques. Neither the researcher, the subjects, the attending physician, nor the laboratory staff were aware of the type of therapy administered, ensuring a double-blind study design.

Data collection encompassed demographic information, clinical data, and the status of acne vulgaris, which was assessed through six facial photo examinations. Additionally, laboratory data, specifically IL-1 β levels in the acne lesions, were collected. The IL-1 β levels were measured using Luminex technology. Data collection of IL-1 β levels was performed both before and after the 8-week intervention. The number of inflammatory acne vulgaris lesions was assessed at baseline (week 0) and subsequently monitored on a weekly basis at weeks 1, 2, 4, 6, and 8. The assessment of acne severity was conducted by a dermatologist using Lehmann's Grading System, which is adapted from the Global Alliance, the Indonesian Acne Expert Meeting (IAEM), and the Indonesian Association of Dermatology and Venereology Specialists (Perdoski). This system categorizes acne vulgaris into three levels—mild, moderate, and severe—based on the type and number of lesions, with a strong emphasis on both inflammatory and non-inflammatory lesions. Mild acne vulgaris (AV) is defined as having <20 comedones, <15 inflammatory lesions, or a total lesion count of <30. Moderate AV is characterized by 20–100 comedones, 15–50 inflammatory lesions, or a total lesion count of 30–125. Severe AV is identified as having >100 comedones, >50 inflammatory lesions, a total lesion count of >125, or >5 nodules.

The analysis was conducted on a per-protocol basis, which involved excluding subjects who dropped out of the study. All statistical analyses were performed with a 5% significance threshold.

The research has received ethical approval from the Research Ethics Committee of FKUI/RSCM with number: KET-922/UN2. F1/ETIK/PPM.00.02/2022 and has been registered in www.clinicaltrials.gov with identification: NCT05758259. This study adhered to the ethical guidelines outlined in the Declaration of Helsinki.

Research Methods

This study used the content of all acne lesions retrieved from moderate and severe acne vulgaris participants, with the following provisions: 1–2 lesions (blackheads, papules, pustules, nodules) / area from at least 3 of 5 different facial areas. Acne vulgaris lesions are first cleansed with alcohol for asepsis and, if needed, gently punctured with a 26G needle before extraction using a comedone extractor.

Cytokine levels in the extracted acne lesion contents were analyzed at the integrated laboratory of the Faculty of Medicine, Universitas Indonesia. Subsequently, cytokine levels in the supernatant were measured using *Luminex Polystyrene Screening Assays* (R&D Systems, catalog code LXSAH) conducted under dim light conditions.

Statistical Analysis

Data processing and analysis were performed using the Statistical Package for Social Sciences (SPSS) Version 21.0. The analysis in this study followed a per-protocol approach. Analysis of variance (ANOVA) was used to compare independent variables across more than two groups with normally distributed numerical dependent variables. The Kruskal–Wallis test was applied to compare independent variables across more than two groups with numerical dependent variables that had non-normal distributions. Correlation analysis was conducted using the Pearson correlation test for normally distributed data and the Spearman correlation test for non-normally distributed data. Statistical significance was determined using a p-value ≤ 0.05 with a 95% confidence interval.

Result

Over the 8-week study period, 3 participants in the topical vitamin D group and 3 in the placebo group did not complete the study. Despite these dropouts, clinical outcome analyses were performed on 32 subjects in each group at the end of the study. Baseline characteristics were well-balanced across the treatment groups. The sample predominantly consisted of female participants ($n = 46$, 71.8%), with a mean age of 23.5 years (SD 5.5). The majority of patients had completed junior high school ($n = 49$, 76.5%), while a smaller portion had completed senior high school ($n = 15$, 23.4%). At the time of initial diagnosis, most patients were classified as having moderate acne vulgaris ($n = 20$, 31.2%), while the remaining patients had severe acne vulgaris ($n = 44$, 68.7%) (Table 1).

The proportion of participants with a clinical diagnosis of moderate and severe acne vulgaris at weeks 1, 2, 4, 6, and 8 is presented in Table 2. Each follow-up visit revealed fluctuations in the number of acne lesions classified as mild, moderate, or severe, indicating a trend toward reduced acne severity over time. Notably, none of the participants were diagnosed with severe acne vulgaris at the end of the study in either group.

Here is a flowchart following the guidelines of the Consolidated Standards of Reporting Trials (CONSORT) (Figure 1).

Over the 8-week treatment period, both the topical vitamin D and topical placebo groups exhibited a reduction in the number of moderate and severe acne vulgaris lesions (Figures 2 and 3).

When evaluating the quantity of inflammatory acne vulgaris (AV) lesions, there was a significant difference in the reduction of inflammatory lesions between the topical vitamin D treatment group and the control group ($p = 0.028$) (Table 3). Furthermore, topical administration of vitamin D significantly reduced inflammatory AV lesions overall ($p = 0.045$) (Table 4).

Figure 4 illustrates the impact of topical vitamin D on IL-1 β levels within acne lesions after 8 weeks, revealing a significant decrease in both the experimental and control groups. Overall, dermatologic indicators showed a decline over time, as observed before and after the 8-week treatment period. Additionally, subjects treated with topical vitamin D appeared to exhibit greater improvement compared to those in the control group (Figures 5 and 6).

A total of 14 participants (43.75%) in the topical vitamin D group reported adverse events, which was consistent with the topical placebo group, where 14 participants (43.75%) also reported adverse events. No serious adverse events were reported. Details of adverse events of particular interest are presented in Table 5.

Discussion

The average age of the 64 subjects in this study was 23.8 ± 5.5 years, with the majority falling within the 18–28 age group. The age range of participants is consistent with the findings of Haroon et al,¹³ who reported that the age of acne vulgaris (AV) patients ranged from 14 to 28 years, with an average age of 21.6 ± 3.03 years. Notably, two-thirds of the

Table 1 Characteristics of the Subject by Socio-Demographics

Characteristics	Total (n = 64)	Topical Vitamin D	Topical Placebo
Age, Mean (SD)	23.8 (5.5)	24.3 (5.9)	25.1 (6.04)
Gender, n (%)			
Male	18	9 (50)	9 (50)
Female	46	23 (50)	23 (50)
Education level, n (%)			
Junior high school	49	24 (48.97)	25 (51.02)
Senior high school	15	8 (53.33)	7 (46.66)
Early Diagnosis			
Severe acne vulgaris	20	10 (50)	10 (50)
Moderate acne vulgaris	44	22 (50)	22 (50)

Notes: All data are N (%) unless otherwise indicated.

Table 2 Characteristics of Clinical Diagnosis Based on Visits

Characteristic	Total (n = 64)	Topical vitamin D (n = 32)	Topical Placebo (n = 32)
Visit I (1st Week Follow-up)			
Severe acne vulgaris	20	10 (50)	10 (50)
Moderate acne vulgaris	44	22 (50)	22 (50)
Visit II (2nd Week Follow-up)			
Severe acne vulgaris	9	4 (44.44)	5 (55.55)
Moderate acne vulgaris	42	24 (57.14)	18 (42.85)
Mild acne vulgaris	13	4 (25.0)	9 (56.2)
Visit III (4th Week Follow-up)			
Severe acne vulgaris	6	1 (16.66)	5 (83.33)
Moderate acne vulgaris	40	24 (60)	16 (40)
Mild acne vulgaris	16	7 (43.75)	9 (56.25)
Visit IV (6th Week Follow-up)			
Severe acne vulgaris	2	1 (50)	1 (50)
Moderate acne vulgaris	45	24 (53.33)	21 (46.66)
Mild acne vulgaris	17	7 (41.17)	10 (58.82)
Visit V (8th Week Follow-up)			
Moderate acne vulgaris	45	22 (48.88)	23 (51.12)
Mild acne vulgaris	19	10 (52.63)	9 (47.36)

Notes: All data are N (%) unless otherwise indicated.

study visits (65.2%) were made by women. This aligns with the Global Burden of Disease study, which found a lower prevalence of AV in men (8.96%) compared to women (9.81%).

The initial manifestation of AV is the formation of undetectable microcomedones, which typically appear on the forehead as blackheads or clinically visible whiteheads. These lesions can then progress into inflamed papules or red pustules.¹⁴ AV has the potential to progress into nodules and cysts, which may be further complicated by hypertrophic or atrophic scarring.¹ Approximately 80–85% of adolescents are affected by AV, a condition that can persist into adulthood. While AV is not life-threatening, it can cause significant physical and psychological distress.¹⁵

In inflammation stage of acne, there are a series of changes in keratinocytes and sebocytes through expression of the *Toll like receptor* (TLR) induced by colonization *C. acnes*.^{16,17} Sebaceous gland hyperplasia with excessive sebum production, changes the proliferation and differentiation of follicular keratinocytes, resulting in the formation of blackheads due to increased cell proliferation in the follicular epidermis. The inflammatory response is activated via the NF- κ B pathway, which is characterized by increased production of specific IL-1 β , IL-6, and IL-8 in sebocytes and keratinocytes. Formation of *NLRP-3 inflammasome* result *C. acnes* is found in sebocytes and triggers production IL-1 β .¹⁸

The primary principles of AV management are to improve follicular keratinization, decrease sebaceous gland activity, reduce *C. acnes* bacterial populations, and suppress inflammatory processes. AV therapy includes antibiotics, hormonals, retinoids, and anti-inflammatory agents, whether used as monotherapy or in combination.¹⁹ The Global Alliance recommends a first-line treatment for moderate AV that includes a combination of an oral antibiotic and a topical retinoid, with or without topical benzoyl peroxide.²⁰ However, improper antibiotic use, such as relying on them as monotherapy for more than 12 weeks, inadequate monitoring, and patient non-compliance, has contributed to increased antibiotic resistance.²¹ To address this concern, adjuvant therapies such as acne lesion extraction can be considered, a procedure commonly practiced in cosmetic dermatology. Sitohang reported that acne lesion extraction was more effective than oral doxycycline.²² Additionally, dermocosmetics have proven to be effective and well-tolerated in acne treatment. The combination of nicotinamide, an antibacterial adhesive agent, and zinc-pyrrolidone carboxylic acid has significantly reduced non-inflammatory lesions.^{23–25} The skin microbiome also plays a crucial role in exacerbating inflammation, with a higher proportion of *Malassezia* spp. found in non-inflammatory lesions.²⁶ Nonetheless, emerging

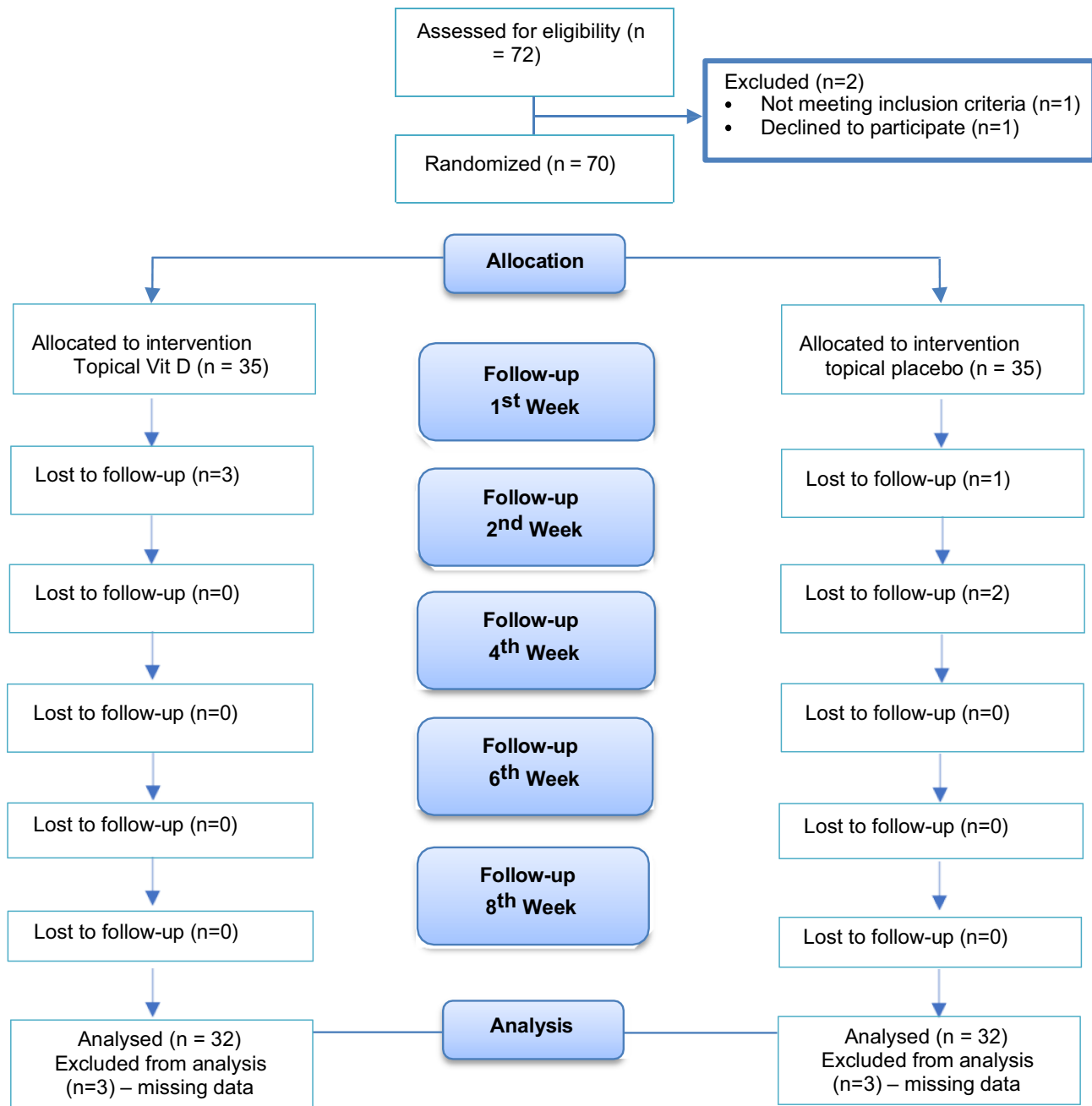


Figure 1 CONSORT Flow Diagram.

evidence suggests that vitamin D could be beneficial for the immune system and represents a potential novel treatment option.²⁷ Topical retinoids have long been effective in the treatment and prevention of AV.^{28,29} Retinoids work by decreasing the blockage of hair follicles, which in turn reduces the chances of rupture and the formation of inflammatory skin lesions. Some side effects were found such as irritation, redness and peeling of the skin, allergic contact dermatitis, as well as the development of antibiotic resistance to *C. acnes* limit the use of topical antibiotics for the long term.^{30,31}

LUMINEX *multiplex bead array assays* provide quantitative measurement of multiple targets simultaneously (requiring ~25-50 μ L for multiple samples) and are considered an effective tool in terms of time and price. The main difference between ELISA and LUMINEX is the use of its target capture system and reporting system. LUMINEX captures targets from *spherical beads* present in suspension whereas ELISA relies on flat surfaces in wells to capture

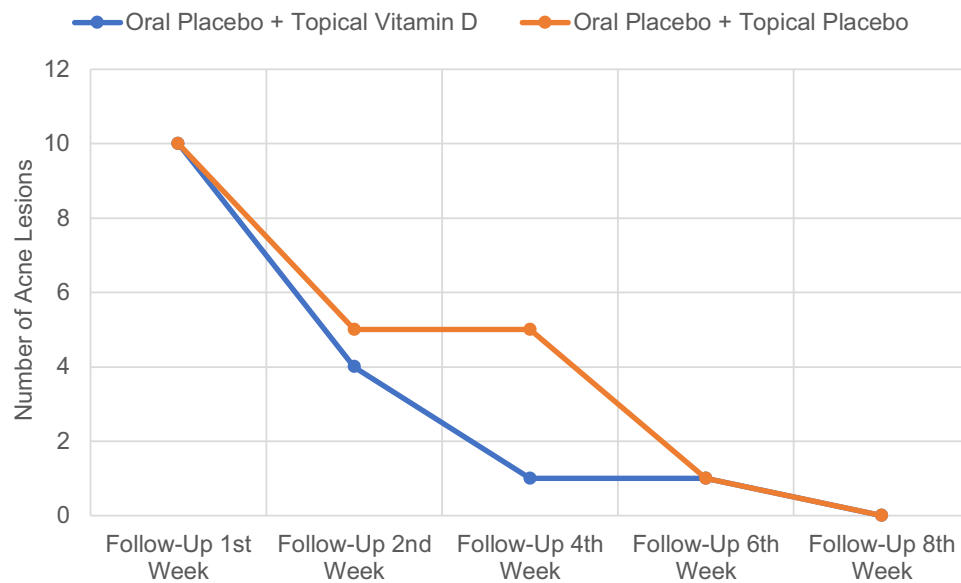


Figure 2 Reduction in the number of Severe Acne Patients.

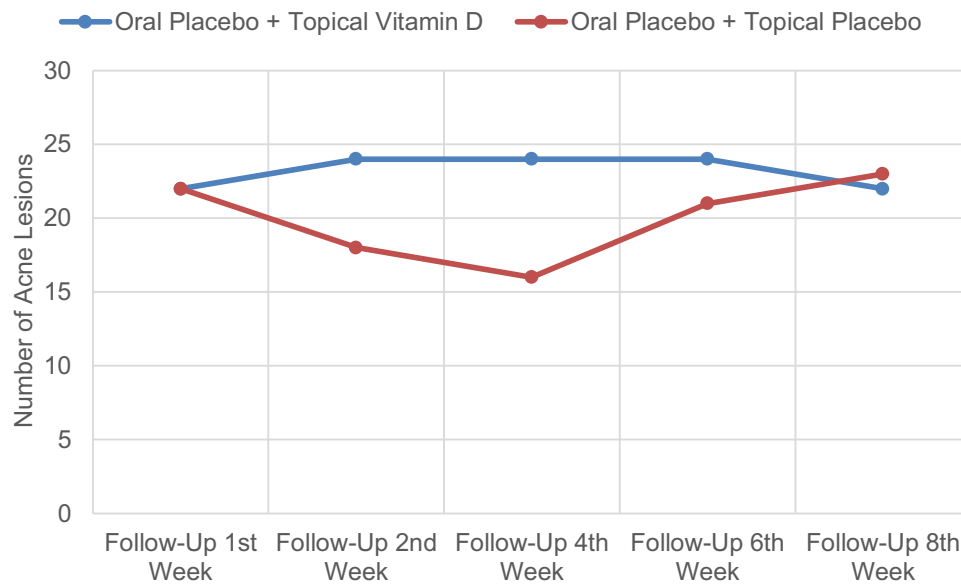


Figure 3 Reduction in the number of Moderate Acne Patients.

targets. LUMINEX uses fluorescence as a reporting system while ELISA uses amplification of enzymes that become colorimetric substrates. LUMINEX *multi-analyte-profiling* (xMAP) technology uses digital signals capable of classifying *colored polystyrene beads* in proportions from red to infrared fluorophores. The Luminex *immunoassay* procedure involves diluting a mixture of microparticles, a mixture of biotin, and streptavidin-PE labeled antibodies from the kit. Each step in the Luminex *immunoassay* procedure is performed in dim light to avoid *photobleaching*. Multiplexing technology has emerged as a valuable tool in cytokine detection, allowing for high-speed and accurate analysis through hundreds of specially prepared magnetic beads or microspheres. The Luminex kit is specifically designed to detect and quantify levels of IL-1 β and other cytokines efficiently.

Table 3 Differences in the Effect of Topical Vitamin D on the Reduction of Moderate and Severe Acne Vulgaris Lesions and Inflammatory Lesions for 8th Weeks

Indicators	Topical Vitamin D	Topical Placebo	P value
Number of lesions in 8th weeks (only pustules, papules, nodules, cysts)	1178	1567	0.0280 ^a
Total number of lesions in 8th weeks	1500	1330	0.235,417

Notes: ^aKruskal Wallis Test.

Table 4 Correlation Between Decreased IL-1 β with Decreased Number of Moderate and Severe Acne Vulgaris Lesions in Topical Vitamin D Compared to Control Group

Group	Decrease in the Number of Total Lesions		Decrease in Inflammatory Lesions	
	Correlation Coefficient (R)	P value	Correlation Coefficient (R)	P value
Topical vitamin D	0.048	0.792	0.356	0.045 ^a
Topical placebo	-0.037	0.84	-0.177	0.33

Note: ^aSpearman Test.

In vitro studies identifying vitamin D receptors in human sebocytes and evidence of vitamin D’s modulation of lipid and cytokine production suggest a potential link between vitamin D and the pathophysiology of acne vulgaris (AV).³² Previous research demonstrated that a subset of 2-methylene-19-nor-1,25(OH)2D exhibited intense comedolytic activity in rhino mouse skin.³³ However, further studies are needed to evaluate acne lesion content to provide direct evidence of vitamin D’s effects on AV inflammation. To our knowledge, this is the first study in Indonesia to examine the topical administration of vitamin D in moderate and severe AV, explicitly assessing the correlation between reduced IL-1 β levels in acne lesions and the decreased severity of AV.

Our results showed a significant correlation between a decrease in acne content IL-1 β and a decrease in the number of inflammatory lesions of acne vulgaris in the group receiving topical vitamin D therapy (p = 0.045). These results are in line with the study of Thanh et al, which showed almost all samples had mild or moderate IL-1 β expression in the dermis, epidermis, and around hair follicles, but the cells expressed were different, squamous cells and basal cells in the epidermis and most monocytes in the dermis and around hair follicles. *C. acnes* has been shown

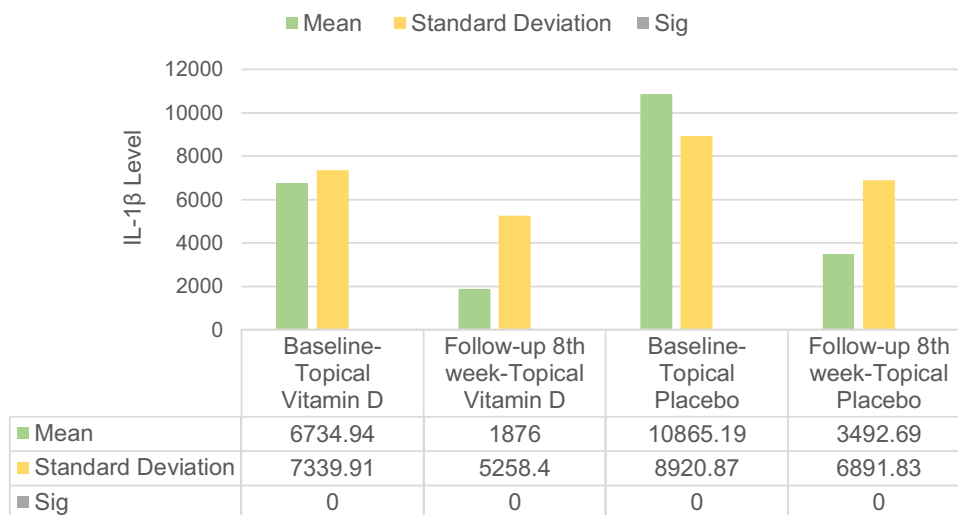


Figure 4 Comparison of Topical Vitamin D to IL-1 β Levels Compared to Control Group for 8 weeks.

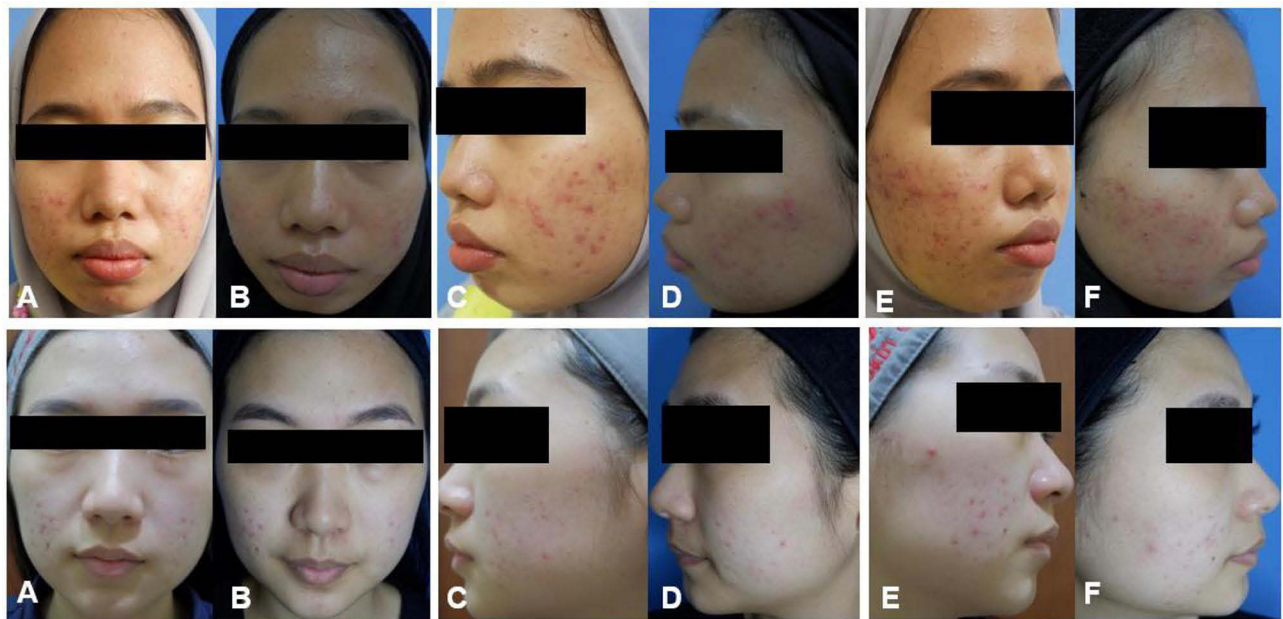

Figure 5 Two patients treated with topical vitamin D, improvement of erythema and inflammatory lesions during 8th weeks of treatment. (A, C and E) Before Treatment. (B, D and F) After 8th weeks of treatment.

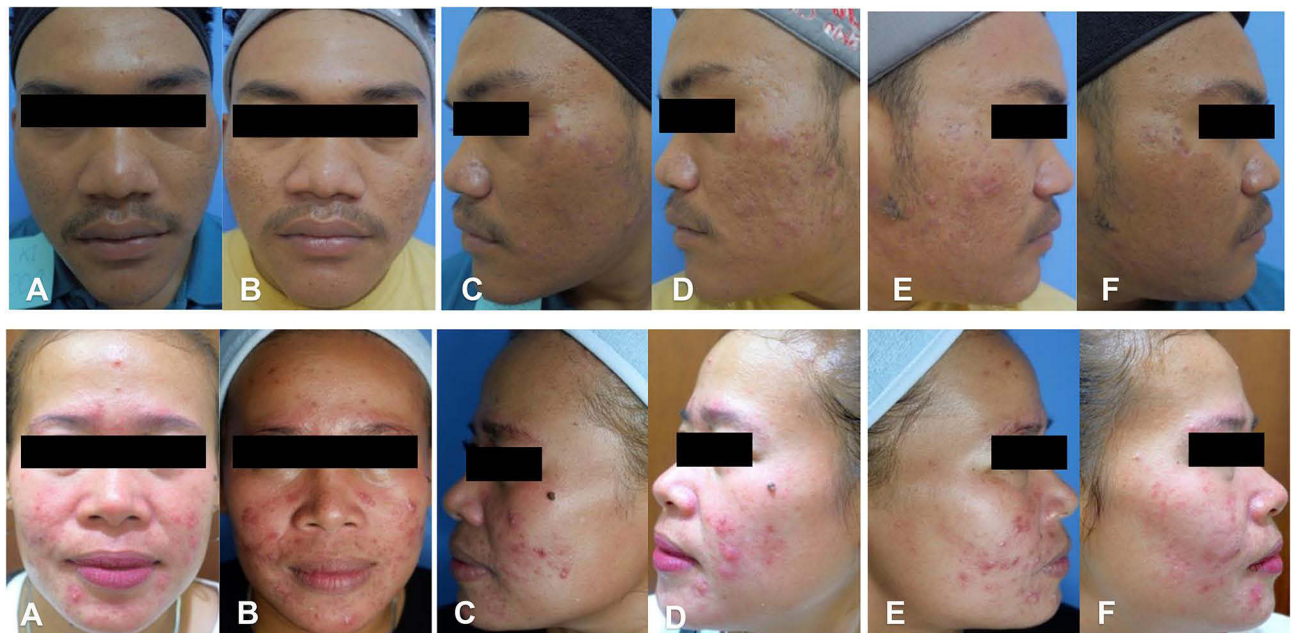


Figure 6 Two patients of control group, worsening of erythema and inflammatory lesions during the 8th weeks of treatment. (A, C and E) Before treatment. (B, D and F) After 8th weeks of treatment.

to increase IL-1 β secretion and activate inflammasomes in monocytes, macrophages, and sebocytes.^{32,34} The activation pathway remains poorly understood. However, some experimental evidence suggests that *C. acnes* peptidoglycan may play a role in activating TLR2, which in turn mediates the activation of the peptidoglycan component muramyl dipeptide.³⁵ Inflammation involving the NLRP3 complex and the role of NOD2 in *C. acnes* can also enhance immune system activation. Additionally, another study reported the presence of the active form of IL-1 β in inflammatory

Table 5 Comparison in Side Effects Between Groups with Vitamin D and Placebo on Moderate and Severe Acne Vulgaris for 8th Weeks

Side Effects	Group		Total n = 64
	Vit D Topical	Topical placebo	
None	18 (56.25)	18 (56.25)	36
Hot flashes	2 (6.25)	3 (9.38)	5
Redness	2 (6.25)	0	2
Dryness	1 (3.13)	3 (9.38)	4
Pain	7 (21.88)	5 (15.63)	12
Itchy	2 (6.25)	3 (9.38)	5
Total	32	32	64

Note: All data are N (%) unless otherwise indicated.

papules, with macrophages surrounding the sebaceous follicular unit, suggesting that *C. acnes* stimulates IL-1 β secretion in acne lesions.^{6,36} In another study, IL-1 β mRNA levels in pustules were 50 times higher than normal skin tissue.

Vitamin D is an antioxidant and controls the synthesis of AMP in the skin. The compounds 1.25(OH)₂D and calcipotriol contribute to immune suppression in the skin by reducing antigen presentation. This effect is achieved through direct modulation of Langerhans cells or by influencing cytokine production in keratinocytes.^{37–39} One study suggested calcipotriol mediates tolerance or immunosuppression in the skin through the induction of CD4+, CD25+, Tregs that prevent antigen-specific CD8+ T cell proliferation and IFN- γ production.^{40,41} Our research shows significant differences in changes in IL-1 β levels within acne lesions between the group that received topical vitamin D and the control group.

Topical vitamin D provides localized anti-inflammatory and immunoregulatory characteristics, as it diminishes the excessive growth of keratinocytes and aids in restoring normal keratinocyte differentiation.^{33,42,43} The predominant adverse effects encompass dermal irritation, sensation of burning, and pruritus after drug administration.⁴⁴ These findings are consistent with our study with Fisher's trial in which both the topical vitamin D and placebo groups experienced no notable adverse effects, either subjectively (itching, discomfort, heat) or empirically (erythema, dry skin).

Conclusion

The inflammatory response is a key factor in the pathogenesis of acne vulgaris (AV), with the cytokine IL-1 β being reported as a trigger for initiating inflammatory lesions in AV. This suggests that IL-1 β could be a promising therapeutic target in AV. Vitamin D regulates cell differentiation, inhibits proliferation, and modulates local immune responses. Studies identifying sebocytes as target cells for bioactive vitamin D and its analogues indicate that vitamin D may effectively treat AV. While topical vitamin D has demonstrated strong comedolytic effects in experimental animal models, there have been no reported clinical trials evaluating its efficacy in AV patients. Both bacterial activity and inflammation play crucial roles in acne formation. Antibiotics work by suppressing bacterial activity and exerting anti-inflammatory effects. Our study demonstrated that over an 8-week period, topical vitamin D effectively reduced pro-inflammatory cytokines and decreased the severity of acne vulgaris in inflammatory lesions. Therefore, using vitamin D as a treatment may be considered an adjuvant therapy.

Research Limitations

This clinical trial is strengthened by the validity of its double-blind randomization process, which ensured well-balanced groups across each intervention. Both researchers and participants were blinded to the interventions received throughout the study. The 8-week study duration aligns with the typical treatment period for acne vulgaris. However, the evaluation was limited to the effect of topical vitamin D on IL-1 β levels and AV severity. Further research is needed to explore the combination of oral and topical vitamin D and/or the standalone use of topical vitamin D to better understand its mechanism of action in improving acne severity. This could involve assessing changes in other inflammatory cytokines or exploring the role of vitamin D receptors (VDR) with a larger sample size. The findings of this study have significant implications for treating moderate to severe acne vulgaris.

Data Sharing Statement

The original data presented in the study are included in the article. Further inquiries can be directed to the corresponding author.

Acknowledgments

The author's thanks all colleagues from the Department of Dermatology and Venereology, Faculty of Medicine, Universitas Indonesia, who participated in this study.

Author Contributions

All authors made a significant contribution to the work reported, whether that is in the conception, study design, execution, acquisition of data, analysis and interpretation, or in all these areas; took part in drafting, revising or critically reviewing the article; gave final approval of the version to be published; have agreed on the journal to which the article has been submitted; and agree to be accountable for all aspects of the work.

Funding

The authors would like to thank Universitas Indonesia for funding this research through PUTI Grant with contract number NKB-420/UN2.RST/HKP.05.00/2022 the sponsor had no such involvement.

Disclosure

The authors declare that there are no conflicts of interest regarding the publication of this paper.

References

1. Knutsen-Larson S, Dawson AL, Dunnick CA, Dellavalle RP. Acne vulgaris: pathogenesis, treatment, and needs assessment. *Dermatologic Clinics*. 2012;30(1):99–106. doi:10.1016/j.det.2011.09.001
2. Wasitaatmadja S. *Erupsi AV formis, rosacea, rinofima*. *Djuanda A HMAS*. 6th ed. Jakarta: Fakultas Kedokteran Universitas Indonesia; 2001:945–973.
3. Lopez-Castejon G, Brough D. Understanding the mechanism of IL-1 β secretion. *Cytokine Growth Factor Rev*. 2011;22(4):189–195. doi:10.1016/j.cytogfr.2011.10.001
4. Ingham E, Walters CE, Eady EA, Cove JH, Kearney JN, Cunliffe WJ. Inflammation in acne vulgaris: failure of skin micro-organisms to modulate keratinocyte interleukin 1 α production in vitro. *Dermatology*. 1998;196(1):86–88. doi:10.1159/000017877
5. Kistowska M, Meier B, Proust T, et al. Propionibacterium acnes promotes Th17 and Th17/Th1 responses in acne patients. *J Invest Dermatol*. 2015;135(1):110–118. doi:10.1038/jid.2014.290
6. Thiboutot DM. Inflammasome activation by Propionibacterium acnes: the story of il-1 in acne continues to unfold. *J Invest Dermatol*. 2014;134(3):595–597. doi:10.1038/jid.2013.528
7. Van Thanh LT, Anh LV, Giang TH, Hung TQ, Trung VT, Vuong NL. Immunohistochemical expression of interleukin 1 beta in papule biopsies from patients with acne vulgaris. *Dermatol Rep*. 2022;14(3):110–114. doi:10.4081/dr.2022.9444
8. Elfadil GA, Mohammed NA, Elmugadam A, Ismail M, Altoum AEA, Osman AL. Vitamin d deficiency among females with acne vulgaris in relation to sun exposure: a cross-sectional study. *Open Access Maced J Med Sci*. 2021;9:1301–1304. doi:10.3889/oamjms.2021.7140
9. Puspita F, Simanungkalit R, Yosi A. Correlation between Serum 25-Hydroxyvitamin D Level with Acne Vulgaris Severity. *Internat J Sci Res Public*. 2020;10(1):p9750. doi:10.29322/ijrsrp.10.01.2020.p9750
10. Lee W, Choi Y, Sohn M, Lee S, Kim D. Expression of inflammatory biomarkers from cultured sebocytes was influenced by treatment with vitamin D. *Indian J Dermatol*. 2013;58(4):327. doi: 10.4103/0019-5154.113959
11. Agak GW, Qin M, Nobe J, et al. Propionibacterium acnes Induces an IL-17 Response in Acne Vulgaris that Is Regulated by Vitamin A and Vitamin D. *Journal of Investigative Dermatology*. 2014;134(2):366–373. doi: 10.1038/jid.2013.334

12. Zouboulis CC. Isotretinoin revisited: pluripotent effects on human sebaceous gland cells. *J Invest Dermatol.* 2006;126(10):2154–2156. doi:10.1038/sj.jid.5700418
13. Haroon MZ, Alam A, Ullah I, Ali R, Taimur MF, Raza K. Quality Of Life And Depression Among Young Patients Suffering From Acne. *J Ayub Med Coll Abbottabad.* 2019;31(3):436–440.
14. Bhat YJ, Latief I, Hassan I. Update on etiopathogenesis and treatment of Acne. *Indian J Dermatol Venereol Leprol.* 2017;83:298–306. doi:10.4103/0378-6323.199581
15. Lynn DD, Umari T, Dunnick CA, Dellavalle RP. The epidemiology of acne vulgaris in late adolescence. *Adolesce Health Med Therapeutics.* 2016;7:13–25. doi:10.2147/AHMT.S55832
16. Jappe U, Ingham E, Henwood J, Holland KT. Propionibacterium acnes and inflammation in acne; P. acnes has T-cell mitogenic activity. *Br J Dermatol.* 2002;146(2):202–209. doi:10.1046/j.1365-2133.2002.04602.x
17. Propionibacterium acnes. Reactive T helper-1 cells in the skin of patients with acne vulgaris; 1999:1226–1228.
18. Zielinski CE, Mele F, Aschenbrenner D, et al. Pathogen-induced human T H17 cells produce IFN- γ or IL-10 and are regulated by IL-1 β . *Nature.* 2012;484:514–518. doi:10.1038/nature10957
19. Gollnick H, Cunliffe W, Berson D, et al. Management of acne: a report from a global alliance to improve outcomes in acne. *J Am Acad Dermatol.* 2003;49:1–37. doi:10.1067/mjd.2003.618
20. Gollnick HPM. From new findings in acne pathogenesis to new approaches in treatment. *J Eur Acad Dermatol Venereol.* 2015;29(5):1–7. doi:10.1111/jdv.13186
21. Sitohang IBS, Fathan H, Effendi E, Wahid M. The susceptibility of pathogens associated with acne vulgaris to antibiotics. *Med J Indones.* 2019;28(1):21–27. doi:10.13181/mji.v28i1.2735
22. Sitohang IBS, Soebaryo RW, Kanoko M. Acne lesion extraction versus oral doxycycline for moderate acne vulgaris: a randomized clinical trial. *J Clin Aesthet Dermatol.* 2021;14(6):E61–E65.
23. Sitohang IBS, Yahya YF, Simanungkalit R, Adi Winarni DR, Madjid A. Efficacy and tolerability of topical nicotinamide plus antibacterial adhesive agents and zinc-pyrolidone carboxylic acid versus placebo as an adjuvant treatment for moderate acne vulgaris in Indonesia: a multicenter, double-blind, randomized, controlled trial. *J Clin Aesthet Dermatol.* 2020;13(7):27–31.
24. Araviiskaia E, Layton AM, Estebarez JLL, Ochsendorf F, Micali G. The synergy between pharmacological regimens and dermocosmetics and its impact on adherence in acne treatment. *Dermatol Res Pract.* 2022;2022:e3644720. doi:10.1155/2022/3644720
25. Araviiskaia E, Lopez Estebarez JL, Pincelli C. Dermocosmetics: beneficial adjuncts in the treatment of acne vulgaris. *J Dermatological Treat.* 2021;32(1):3–10. doi:10.1080/09546634.2019.1628173
26. Sutarjo AS, Sitohang IBS, Wahid MH, Widaty S. COMPARISON OF MALASSEZIA SPP. PROPORTIONS IN INFLAMMATORY AND NON-INFLAMMATORY FACIAL ACNE VULGARIS LESIONS. *Int J Appl Pharm.* 2020;7–11. doi:10.22159/ijap.2020.v12s3.39454
27. Saptarini D, Witjaksono F, Sitohang IBS. Correlation study of acne vulgaris and serum vitamin d levels in adolescents. *Int J Appl Pharm.* 2020;19–21. doi:10.22159/ijap.2020.v12s3.39462
28. El-Hamd MA, El Taieb MA, Ibrahim HM, Aly SS. Vitamin D levels in acne vulgaris patients treated with oral isotretinoin. *J Cosmet Dermatol.* 2019;18(1):16–20. doi:10.1111/jocd.12503
29. Zaenglein AL, Pathy AL, Schlosser BJ, et al. Guidelines of care for the management of acne vulgaris. *J Am Acad Dermatol.* 2016;74(5):945–973. e33. doi:10.1016/j.jaad.2015.12.037
30. Balato A, Schiattarella M, Lembo S, et al. Interleukin-1 family members are enhanced in psoriasis and suppressed by vitamin D and retinoic acid. *Archives of Dermatological Res.* 2013;305(3):255–262. doi:10.1007/s00403-013-1327-8
31. Cripps DJ. Current management of acne vulgaris. *Wisc Med J.* 1973;72(9):189–191.
32. Alhetheli G, Elneam AIA, Alsenaid A, Al-Dhubaibi M. Vitamin D levels in patients with and without acne and its relation to acne severity: a case-control study. *Clin Cosmet Invest Dermatol.* 2020;13:759–765. doi:10.2147/CCID.S271500
33. Bagot M, Charlie D, Lesca MC, Pamphile R, Revuz J. Immunosuppressive effects of 1,2 5-dihydroxyvitamin D3 and its analogue calcipotriol on epidermal cells. *Br J Dermatol.* 1994;130(4):424–431. doi:10.1111/j.1365-2133.1994.tb03373.x
34. Ingham E, Eady EA, Goodwin CE, Cove JH, Cunliffe WJ. Pro-inflammatory levels of interleukin-1 α -like bioactivity are present in the majority of open comedones in acne vulgaris. *J Invest Dermatol.* 1992;98(6):895–901. doi:10.1111/1523-1747.ep12460324
35. Selway JL, Kurczab T, Kealey T, Langlands K. Toll-like receptor 2 activation and comedogenesis: implications for the pathogenesis of acne. *BMC Dermatol.* 2013;13:13. doi:10.1186/1471-5945-13-10
36. Hammerberg C, Bata-Csorgo Z, Voorhees JJ, Cooper KD. IL-1 and IL-1 receptor antagonist regulation during keratinocyte cell cycle and differentiation in normal and psoriatic epidermis. *Archives of Dermatological Res.* 1998;290(7):367–374. doi:10.1007/s004030050319
37. Hong SP, Oh Y, Jung M, et al. Topical calcitriol restores the impairment of epidermal permeability and antimicrobial barriers induced by corticosteroids. *Br J Dermatol.* 2010;162(6):1251–1260. doi:10.1111/j.1365-2133.2010.09760.x
38. Orgaz-Molina J, Buendia-Eisman A, Arrabal-Polo MA, Ruiz JC, Arias-Santiago S. Deficiency of serum concentration of 25-Hydroxyvitamin D in psoriatic patients: a case-Control study. *J Am Acad Dermatol.* 2012;67(5):931–938. doi:10.1016/j.jaad.2012.01.040
39. Oda Y, Uchida Y, Moradian S, Crumrine D, Elias PM, Bikle DD. Vitamin D receptor and coactivators SRC2 and 3 regulate epidermis-specific sphingolipid production and permeability barrier formation. *J Invest Dermatol.* 2009;129(6):1367–1378. doi:10.1038/jid.2008.380
40. Layton AM, Morris C, Cunliffe WJ, Ingham E. Immunohistochemical investigation of evolving inflammation in lesions of acne vulgaris. *Experim Dermatol.* 1998;7(4):191–197. doi:10.1111/j.1600-0625.1998.tb00323.x
41. Gorman S, Judge MA, Hart PH. Immune-modifying properties of topical vitamin D: focus on dendritic cells and T cells. *J Steroid Biochem Mol Biol.* 2010;121(1–2):247–249. doi:10.1016/j.jsbmb.2010.02.034
42. Fujiyama T, Ito T, Umayahara T, et al. Topical application of a vitamin D3 analogue and corticosteroid to psoriasis plaques decreases skin infiltration of TH17 cells and their ex vivo expansion. *J Allergy Clin Immunol.* 2016;138(2):517–528.e5. doi:10.1016/j.jaci.2016.03.048
43. Ghoreishi M, Bach P, Obst J, Komba M, Fleet JC, Dutz JP. Expansion of antigen-specific regulatory T cells with the topical vitamin D analog calcipotriol. *J Immunol.* 2009;182(10):6071–6078. doi:10.4049/jimmunol.0804064
44. Sato-Deguchi E, Imafuku S, Chou B, Ishii K, Hiromatsu K, Nakayama J. Topical vitamin D 3 analogues induce thymic stromal lymphopoietin and cathelicidin in psoriatic skin lesions. *Br J Dermatol.* 2012;167(1):77–84. doi:10.1111/j.1365-2133.2012.10917.x

Clinical, Cosmetic and Investigational Dermatology

Dovepress

Publish your work in this journal

Clinical, Cosmetic and Investigational Dermatology is an international, peer-reviewed, open access, online journal that focuses on the latest clinical and experimental research in all aspects of skin disease and cosmetic interventions. This journal is indexed on CAS. The manuscript management system is completely online and includes a very quick and fair peer-review system, which is all easy to use. Visit <http://www.dovepress.com/testimonials.php> to read real quotes from published authors.

Submit your manuscript here: <https://www.dovepress.com/clinical-cosmetic-and-investigational-dermatology-journal>