

# Adjuvant Therapy in Acral Melanoma: A Systematic Review

Zhou Zhu<sup>1-3</sup>, Mingjuan Liu<sup>1-3</sup>, Hanlin Zhang<sup>1,2</sup>, Heyi Zheng<sup>1,2</sup>, Jun Li<sup>1,2</sup>

<sup>1</sup>Department of Dermatology, Peking Union Medical College Hospital, Chinese Academy of Medical Sciences & Peking Union Medical College, Beijing, People's Republic of China; <sup>2</sup>State Key Laboratory of Complex Severe and Rare Diseases, Peking Union Medical College Hospital, Chinese Academy of Medical Sciences & Peking Union Medical College, Beijing, People's Republic of China; <sup>3</sup>4+4 Medical Doctor Program, Chinese Academy of Medical Sciences & Peking Union Medical College, Beijing, People's Republic of China

Correspondence: Jun Li, Department of Dermatology, Peking Union Medical College Hospital, Chinese Academy of Medical Sciences and Peking Union Medical College, No.1 Shuaifuyuan Wangfujing Dongcheng District, Beijing, 100730, People's Republic of China, Email [lijun35@hotmail.com](mailto:lijun35@hotmail.com)

**Background:** Acral melanoma presents distinct biological characteristics compared to cutaneous melanoma. While adjuvant therapeutic strategies for high-risk resected acral melanoma closely resemble those for cutaneous melanoma, the evidence supporting the clinical application of adjuvant therapy for acral melanoma remains inadequate. Our aim was to systematically analyze the efficacy and safety profile of adjuvant therapy in acral melanoma.

**Methods:** This systematic review adhered to a pre-registered protocol. We comprehensively searched four electronic databases and reference lists of included articles to identify eligible studies. The primary outcome was therapeutic efficacy, and the secondary outcome was adverse events (AEs).

**Results:** This systematic review included 11 studies with 758 acral melanoma patients undergoing adjuvant therapy. High-dose interferon  $\alpha$ -2b (IFN) regimens showed no significant difference in recurrence-free survival (RFS), though the longer regimen was linked to increased hepatotoxicity. Adjuvant anti-PD-1 therapy demonstrated varying efficacy, with improved RFS in patients who experienced immune-related AEs. Targeted therapy with dabrafenib plus trametinib achieved high 12-month RFS in patients with BRAF-mutated acral melanoma. Comparative studies suggested that adjuvant anti-PD-1 therapy is similarly effective to IFN in prolonging survival for high-risk acral melanoma patients. Additionally, prior treatment with pegylated IFN enhanced RFS in patients receiving adjuvant pembrolizumab.

**Conclusion:** High-dose IFN was widely used as adjuvant therapy for acral melanoma, but serious AEs prompted the search for alternatives. Adjuvant anti-PD-1 therapy shows promise, though it may be less effective than in non-acral melanoma. Further prospective studies are needed to determine the optimal adjuvant treatment for acral melanoma.

**Keywords:** acral melanoma, adjuvant therapy, anti-PD-1 antibody, high-dose interferon  $\alpha$ -2b, systematic review

## Introduction

Acral melanoma is a rare subtype of melanoma that specifically affects the nail bed, palms, and soles of the feet.<sup>1</sup> While acral melanoma constitutes only 2–3% of all melanomas in Western countries, it is the predominant subtype in Asian, Hispanic, and African populations.<sup>2,3</sup> Since the development of acral melanoma is not associated with ultraviolet radiation (UVR) exposure, it tends to have a lower tumor mutation burden compared to cutaneous melanoma.<sup>4</sup> Additionally, acral melanoma exhibits a distinct pattern of oncogenic driver mutations compared to cutaneous melanoma, characterized by fewer *BRAF* and *NRAS* mutations and variable *KIT* mutations. Other significant mutations identified in acral melanoma include *NF1*, *TYRP1*, *PTEN*, *TERT*, and *CHEK2*.<sup>5,6</sup> Moreover, acral melanoma contains significantly higher frequencies of cell-cycle aberrations (*CDK4/6*, *CCND1/2*, *CDKN2A*), and copy number gains in receptor tyrosine kinase (RTK) genes than cutaneous melanoma.<sup>7</sup> The prognosis for acral melanoma is typically poorer compared to other subtypes, likely due to its diagnosis at more advanced stages. Over 62% of acral melanoma cases are diagnosed at stage II or higher, compared to approximately 32% for cutaneous melanoma.<sup>8,9</sup>

The standard of care for localized, resectable melanoma is surgical resection. However, postoperative adjuvant therapy may be considered for patients at high risk of loco-regional or distant recurrence.<sup>10</sup> Interferon  $\alpha$ -2b (IFN) has been the first approved systemic adjuvant therapy for melanoma by the US Food and Drug Administration (FDA) and has conventionally been used for decades. However, its use is associated with limited clinical benefits and severe toxicity.<sup>11–13</sup> Based on several landmark randomized control trials (RCTs), programmed death-1 (PD-1) inhibitors have been approved for adjuvant treatment of resected stage IIB/C<sup>14</sup> and stage III/IV<sup>15,16</sup> melanoma, as well as targeted therapy with BRAF plus MEK inhibitors for stage III melanoma.<sup>17</sup> However, the specific role of systemic therapy in the adjuvant setting for acral melanoma remains poorly understood due to limited available data from clinical trials. In this study, we conducted a systematic review to assess the efficacy and safety profile of adjuvant therapy in acral melanoma.

## Materials and Methods

The Preferred Reporting Items for Systematic Reviews and Meta-Analysis (PRISMA) guidelines are the basis for implementing this systematic review.<sup>18</sup> The protocol was registered on the PROSPERO (CRD42023485434).

### Search Strategy

We searched PubMed, Scopus, Embase and the Cochrane Central Register of Controlled Trials databases from database inception to March 11, 2024. The search keywords used were: “Acral”, “Melanoma” and “Adjuvant”. The language is restricted to English. We also manually searched reference lists and similar articles for additional relevant studies. The titles and abstracts of each record were independently analyzed and studies reporting the efficacy or safety of adjuvant therapy for acral melanoma were retrieved for a full-text review and assessed for eligibility. For missing, unclear or incomplete results, we contacted researchers for clarification before exclusion. Studies that met the inclusion criteria were included for further analysis.

### Selection Criteria

To reduce selection bias, two reviewers independently assessed each study and disagreements were resolved by consensus with a third reviewer, if necessary. The selection criteria were set prior to the literature search process. Studies that met the following criteria were eligible for inclusion: (1) published in English; (2) Participating patients were eligible if they had resected acral melanoma and received adjuvant therapy; (4) Reported relapse-free survival (RFS) and/or overall survival (OS), or data to calculate these; (5) Reported adverse events (AEs) of adjuvant therapy.

Studies were excluded if: (1) Study results from the same research institution were reported repeatedly; (2) Studies with patients who had unresectable stage IV melanoma; (3) any review, comment, letter, case report, meeting abstract, trial protocol or animal study.

### Data Extraction and Analysis

Two investigators independently read through the included studies and recorded basic information such as the first author and year of publication. We also collected information on characteristics of the included studies, including countries where studies were conducted, sample size, intervention, and outcomes. For the primary outcome, we extracted data on median RFS, median OS, as well as the incidence of one and two-year RFS and OS to demonstrate the efficacy of adjuvant therapy for acral melanoma. The second outcome was AEs.

Two authors utilized the Cochrane risk-of-bias tool to evaluate the quality of randomized controlled trials (RCTs). For retrospective studies, quality assessment tool developed by the National Heart, Lung, and Blood Institute (NHLBI) (<https://www.nhlbi.nih.gov/health-topics/study-quality-assessment-tools>) was used. Each of the studies was classified as low, fair, or high risk of bias. Any discrepancies were resolved by discussions with a third author.

## Results

This systematic literature search initially identified 680 records. After duplicates were excluded, 340 articles remained. After screening out irrelevant papers based on titles and abstracts, 87 records underwent full-text evaluation for eligibility

assessment. Finally, 11 studies (12 records) meeting the eligibility criteria were included in this systematic review (Figure 1). The data extracted from the included studies are summarized in Table 1.

## Interferon $\alpha$ -2b (IFN)

In a randomized phase II trial, 158 high-risk Chinese acral melanoma patients were included to receive either a 1-month regimen ( $15 \times 10^6$  U/m<sup>2</sup>/day for 5 days per week for 4 weeks) or a 1-year regimen ( $15 \times 10^6$  U/m<sup>2</sup>/day for 5 days per week for 4 weeks, followed by  $9 \times 10^6$  U three times per week for 48 weeks) of adjuvant high-dose IFN. The median RFS for the 1-month and 1-year regimen groups was 17.9 months and 22.5 months, respectively, with no statistically significant difference observed between the two groups ( $P = 0.72$ ). The incidences of all grades of AEs were similar between the two treatment groups. However, all grades of hepatotoxicity ( $P = 0.003$ ) and Grade 3 or 4 hepatotoxicity ( $P = 0.03$ ) were significantly higher in the 1-year regimen group compared to the 1-month regimen group. The incidence of dosage reduction was 2% in the 1-month regimen group and 10% in the 1-year regimen group.<sup>30</sup>

## Anti-PD-I Therapy

The efficacy and safety of adjuvant anti-PD-1 therapy in advanced melanoma were retrospectively investigated in a multicenter study of 78 Japanese patients with melanoma (including 31 acral melanoma). The 12-month RFS for acral melanoma was 25.8% (95% CI: 14.5–43.5%), which was significantly lower than that of other cutaneous types ( $P = 0.029$ ).<sup>24</sup> In this study, safety data were available for 30 patients with acral melanoma. 9 patients (30%) had immune-

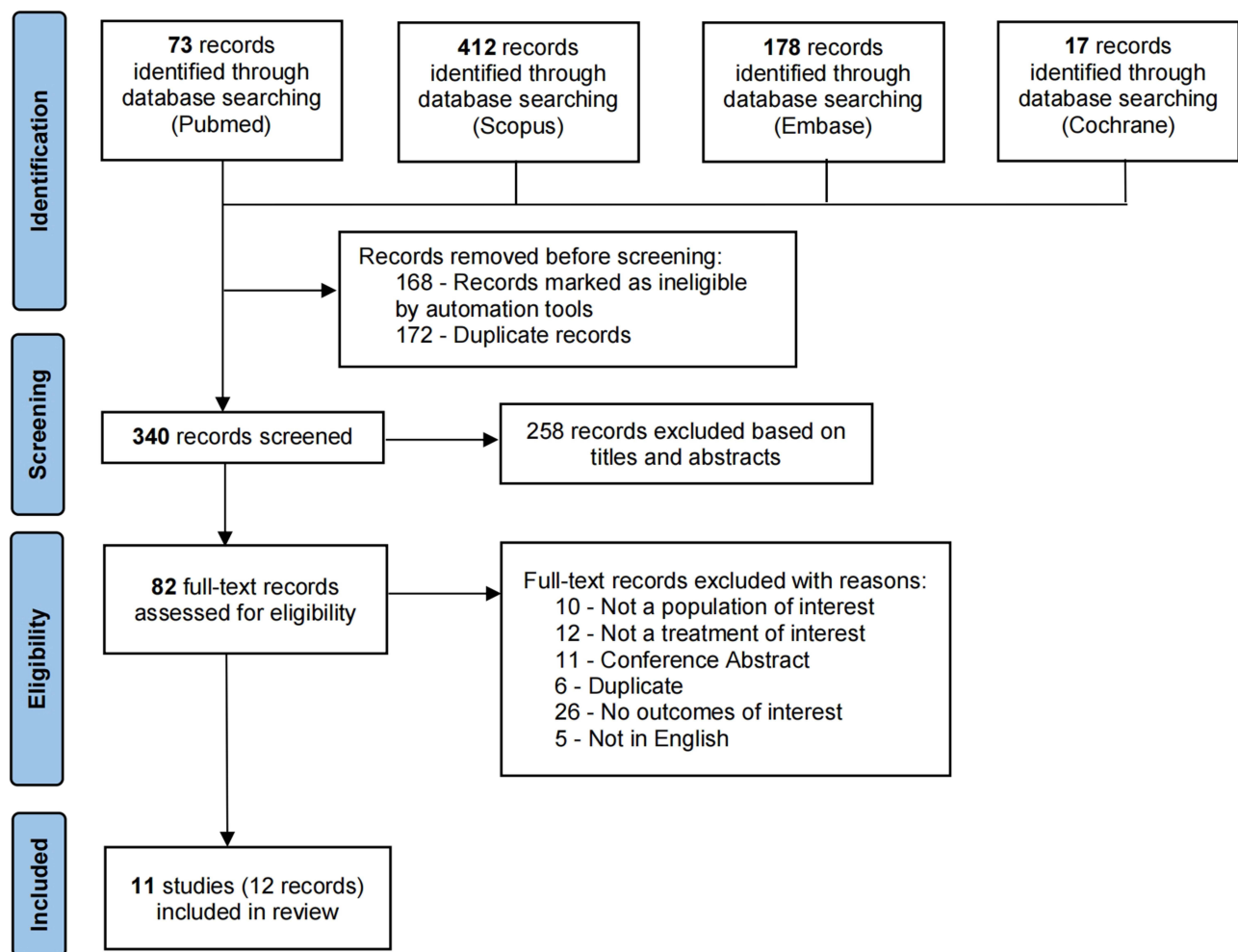


Figure 1 PRISMA flow diagram of the literature search.

Table 1 Characteristics of the Included Studies

Study	Country	Study design	Population	Stage	Intervention	Median follow-up time/ months	Median RFS/month	6-month RFS	1-year RFS	3-year RFS	Median DMFS/ month	3-year DMFS	Median OS/ month	AE	Quality
Arak 2024 <sup>19</sup>	Turkey	Retrospective, multicenter	n = 114	III–IV	Adjuvant therapy (n = 64: 31 PD-1 inhibitor, 9 Temozolomide, 19 IFN, 5 BRAF/MEK inhibitors) vs OBS (n = 50)	40	24.0 vs 15.0 (P = 0.021) (PD-1: NR; Temozolomide: 23; IFN: 22; BRAF/MEK: 23)	NA	NA	NA	NA	NA	71.0 vs 38.0 (P = 0.001)	NA	fair
Jacques 2024 <sup>20</sup>	International	Retrospective, multicenter	n = 194 (total), n = 139 (AM); control: a historical cohort (n = 229)	III	PD-1 inhibitor (pembrolizumab, nivolumab) vs OBS	29 (IQR 17.4–44.6)	HR: 0.69, 95% CI: 0.52–0.92, P = 0.013	NA	NA	43% vs 32%	HR: 0.58, 95% CI: 0.38–0.89, P = 0.013	78% vs 67%	HR: 0.59, 95% CI: 0.38–0.92, P = 0.020	NA	good
Mo 2023 <sup>21</sup>	China	Retrospective, single-center	n = 44	II–III	PD-1 inhibitor (pembrolizumab, toripalimab, sintilimab, tislelizumab, and camrelizumab)	18.4 (95% CI: 11.7–24.9)	21.6 (95% CI: 11.5–NR)	NA	NA	NA	30.6 (95% CI: 21.6–NR)	NA	NA	3 (6.8%) discontinued due to serious AEs	fair
Li 2023 <sup>22</sup>	China	Retrospective, single-center	n = 199 (total), n = 136 (AM)	III	PD-1 inhibitor (n = 84, pembrolizumab, toripalimab), IFN (n = 18), OBS (n = 34)	NA	PD-1 vs IFN+OBS (HR: 0.64, 95% CI: 0.40–1.02, P = 0.05); PD-1 vs IFN (P = 0.075)	NA	68.6% (PD-1)	NA	NA	NA	NA	NA	low
Maeda 2022 <sup>23</sup>	Japan	Retrospective, single-center	n = 27	III–IV	Nivolumab (n = 5) vs non-ICI (n = 22: 12 IFN+ 4 chemotherapy+6 OBS)	NA	Nivolumab is inferior to non-ICI (P = 0.15)	NA	NA	NA	NA	NA	NA	1 (20%) serious AE vs no serious AE	low
Muto 2022 <sup>24,25</sup>	Japan	Retrospective, multicenter	n = 78 (total), n = 31 (AM)	III–IV	PD-1 inhibitor (nivolumab, pembrolizumab)	NA	8.1	NA	25.8% (95% CI 14.5–43.5%)	NA	NA	NA	NA	All grades: 9/30 (30%); Grade 3 or 4: 4/30 (13.3%)	fair
Li 2021 <sup>26</sup>	China	Retrospective, single-center	n = 90 (total), n = 36 (AM)	III	PD-1 inhibitor (n = 12, pembrolizumab, nivolumab, toripalimab) vs HDI (n = 24)	16.1 vs 26.3	7.0 vs 15.3 (HR: 1.20, 95% CI: 0.52–2.78, P = 0.63)	75.0% vs 83.3% (HR: 1.60, 95% CI: 0.36–7.13, P = 0.58)	50.0% vs 61.6% (HR: 1.60, 95% CI: 0.57–4.50, P = 0.37)	NA	12.5 vs 23.9 (HR: 1.97, 95% CI: 0.74–5.21, P = 0.16)	NA	NA	NA	low
Jia 2021 <sup>27</sup>	China	Retrospective, single-center	n = 56 (total), n = 40 (AM)	III	PEG-IFN + pembrolizumab (19) vs pembrolizumab (21)	NA	8.5 vs 5.4 (HR: 0.54, 95% CI: 0.25–1.16, P = 0.11)	NA	NA	NA	NA	NA	NA	NA	low

<b>Amagai 2021</b> <sup>28</sup>	Japan	Retrospective, multicenter	n = 36 (total), n = 4 (AM)	III	Dabrafenib plus Trametinib	NA	NR	NA	100% (3/3)	NA	NA	NA	NA	1/4 (25%) dose reduction	fair
<b>Li 2020</b> <sup>29</sup>	China	Retrospective, single-center	n = 56 (total), n = 41 (AM)	III	Pembrolizumab (n = 21) vs HDI (n = 20)	NA	NR vs 25 (HR: 1.22, 95% CI: 0.29–5.19, P = 0.79)	79.5% (95% CI 57.4–101.6%) vs 90.0% (95% CI 76.9–103.1%)	NA	NA	NA	NA	NA	NA	low
<b>Mao 2011</b> <sup>30</sup>	China	Randomized Phase II trial	n = 147	II–III	1-month HDI (77) vs 1-year HDI (70)	36.1 (range: 13.2–41.3)	17.9 (95% CI: 4.8–31.0) vs 22.5 (95% CI: 15.0–30.0) (P = 0.72)	NA	NA	37.4% (95% CI: 26.6–48.2%) vs 35.6% (95% CI: 23.8–47.4%)	NA	NA	NR	Grade 3/4 hepatotoxicity: 5% vs 16% (P = 0.03); dose reduction: 2% vs 10%	good

**Abbreviations:** AE, adverse event; AM, acral melanoma; CI, confidence interval; DMFS, distant metastasis-free survival; HDI, high-dose interferon  $\alpha$ -2b; HR, hazard ratio; IFN, interferon  $\alpha$ -2b; IQR, interquartile range; NA, not available; NR, not reached; PEG-IFN, pegylated interferon  $\alpha$ -2b; RFS, recurrence-free survival; OBS, observation; OS, overall survival.

related AEs (irAEs) of any grade, and 4 patients (13.3%) patients had Grade 3 or 4 irAEs. These severe irAEs included liver dysfunction ( $n = 2$ ), interstitial pneumonia ( $n = 1$ ), and diarrhea ( $n = 1$ ). For patients with acral melanoma, those who experienced irAEs showed significantly better RFS compared to those who did not ( $P = 0.0398$ , HR: 0.36).<sup>25</sup>

A single-center retrospective cohort study included 44 participants with stage II–III acral melanoma to assess the efficacy and safety of PD-1 inhibitors as adjuvant therapy. The median RFS and median DMFS for all patients receiving adjuvant anti-PD-1 monotherapy were 21.6 months (95% confidence interval (CI): 11.5–not reached), and 30.6 months (95% CI: 21.6–not reached), respectively. In the subgroup analysis, no significant differences were observed in RFS between the pembrolizumab and toripalimab groups (24.4 vs 18.9 months,  $P = 0.43$ ), nor in DMFS (30.6 months vs not reached,  $P = 0.87$ ). The median DMFS was significantly longer in the wild-type NRAS group compared to the NRAS mutation group (41.1 vs 9.0 months,  $P < 0.001$ ). Only 3 patients (6.8%) discontinued treatment due to serious AEs, which included myocarditis, drug-induced hepatitis, and edema, with no related deaths.<sup>21</sup>

In an international retrospective cohort study involving 20 centers across 10 countries, adjuvant anti-PD-1 therapy for acral melanoma showed longer RFS (hazard ratio (HR): 0.69, 95% CI: 0.52–0.92,  $P = 0.013$ ), DMFS (HR: 0.58, 95% CI: 0.38–0.89,  $P = 0.013$ ), and OS (HR: 0.59, 95% CI: 0.38–0.92,  $P = 0.020$ ) compared to a historical cohort that did not receive adjuvant therapy.<sup>20</sup>

## Targeted Therapy

A multicenter retrospective study conducted in Japan, which involved 36 patients with *BRAF*-mutated advanced melanoma (including 4 cases of acral melanoma), evaluated the efficacy of targeted therapy consisting of dabrafenib plus trametinib. The RFS at 12 months was 82.1% (95% CI: 63.9–92.6%). Specifically, for acral melanoma with *BRAF* mutation in this study, the 12-month RFS was 100% (3/3).<sup>28</sup>

## Comparison of Different Therapies

In a retrospective cohort study conducted in China, 136 patients with stage III acral melanoma were investigated. They compared outcomes among patients receiving adjuvant PD-1 inhibitor ( $n = 84$ ), IFN ( $n = 18$ ), and simple observation ( $n = 34$ ). The study found a lower HR of the median RFS in the PD-1 inhibitor group (HR: 0.64, 95% CI: 0.40–1.02,  $P = 0.05$ ) compared to the IFN/observation group. However, no significant difference in median RFS was observed between the PD-1 inhibitor and IFN groups ( $P = 0.075$ ).<sup>22</sup>

A single-center retrospective study conducted in Japan compared adjuvant nivolumab treatment ( $n = 5$ ) with other treatments ( $n = 22$ , including 12 patients receiving IFN  $\beta$ , 4 chemotherapy, and 6 observation) and found no significant difference in RFS between the adjuvant nivolumab group and the non-immune checkpoint inhibitor (ICI) group ( $P = 0.15$ ).<sup>23</sup> In a retrospective study comprising 56 Chinese patients with resected stage III melanoma, those receiving adjuvant pembrolizumab were compared to those receiving IFN. Among the subgroup of 41 patients with acral melanoma, there was no significant difference in RFS between the pembrolizumab group and the IFN group (HR: 1.22, 95% CI: 0.29–5.19,  $P = 0.79$ ).<sup>29</sup> A retrospective study involving 90 Chinese patients with stage III cutaneous ( $n = 54$ ) and acral ( $n = 36$ , 12 receiving PD-1 inhibitor and 24 receiving high-dose IFN) melanoma compared adjuvant anti-PD-1 inhibitor monotherapy with high-dose IFN. The study found that adjuvant PD-1 inhibitor did not improve outcomes over high-dose IFN among patients with acral melanoma. The median RFS was 7.0 months in the PD-1 inhibitor group and 15.3 months in the high-dose IFN group (HR: 1.20, 95% CI: 0.52–2.78,  $P = 0.63$ ).<sup>26</sup>

A retrospective study from China indicated that prior treatment with pegylated IFN (PEG-IFN) significantly prolonged the median RFS of adjuvant pembrolizumab in resected stage III/IV melanoma (median RFS: 8.5 months vs 4.5 months,  $P = 0.037$ ). In acral melanoma ( $n = 40$ ), patients who received prior PEG-IFN therapy also showed a trend towards better clinical response to adjuvant pembrolizumab. The median RFS was 8.5 months in the IFN group and 5.4 months in the non-IFN group (HR: 0.54, 95% CI: 0.25–1.16,  $P = 0.11$ ).<sup>27</sup> In a multicenter retrospective study involving 114 patients with stage III or IV acral melanoma who underwent surgery in Turkey, those who received adjuvant treatment ( $n = 64$ ) demonstrated a longer median RFS (24 vs 15 months,  $P = 0.021$ ) and overall survival (71 vs 38 months,  $P = 0.001$ ) compared to those who did not receive adjuvant treatment ( $n = 50$ ). However, no significant difference was observed in RFS or OS between anti-PD-1 therapy and other adjuvant regimens.<sup>19</sup>

## Discussion

This systematic review included 11 studies involving 758 acral melanoma patients, offering a comprehensive overview of the efficacy and safety of adjuvant therapy in high-risk resected acral melanoma.

High-dose IFN was the first biological agent approved by the FDA for adjuvant treatment of high-risk melanoma in 1996. It demonstrated benefits in both RFS and OS for melanoma patients at stage IIB/III in the ECOG1684 trial.<sup>13</sup> However, the use of IFN as the standard treatment was limited for patients with ulcerated melanoma due to its severe toxicity and modest improvement in OS. Ipilimumab, an anti-CTLA-4 checkpoint antibody, showed efficacy compared to placebo in patients with completely resected high-risk melanoma<sup>31</sup> and was approved by the FDA in 2015. Given the severe toxicity, even with dose reduction, and the lack of significant difference in RFS compared to IFN, ipilimumab should no longer be considered as the first-line adjuvant therapy.<sup>32</sup> Nivolumab and pembrolizumab have shown significant efficacy in terms of RFS and have a more favorable toxicity profile when compared to ipilimumab.<sup>33,34</sup> Current guidelines recommend anti-PD-1 antibodies as the primary adjuvant therapy for melanoma. Meanwhile, if the patient has a positive BRAF mutation, treatment with BRAF plus MEK inhibitors should be considered. For stage III patients, the 12-month RFS rates were 63.5% with ipilimumab in EORTC-18071,<sup>31</sup> 72.3% with nivolumab in CheckMate-238,<sup>16</sup> 75.4% with pembrolizumab in Keynote-054,<sup>15</sup> and 88% with dabrafenib plus trametinib in COMBI-AD.<sup>17</sup>

The findings from a multicenter retrospective study involving 114 patients with stage III or IV acral melanoma in Turkey suggest that individuals who received adjuvant treatment exhibited a longer median RFS and OS. The results underscore the potential benefit of adjuvant therapy in improving both RFS and OS among patients with resected acral melanoma. Additionally, the international retrospective cohort study involving multiple centers across different countries reported more conclusive results regarding the efficacy of adjuvant anti-PD-1 therapy. Adjuvant anti-PD-1 therapy demonstrated longer RFS, DMFS, and OS compared to a historical cohort without adjuvant therapy. However, the efficacy of anti-PD-1 therapy in adjuvant treatment of acral melanoma remains controversial. According to our results, among the five studies comparing adjuvant anti-PD-1 therapy with non-ICI treatment for acral melanoma, four studies revealed no significant difference in RFS between the adjuvant anti-PD-1 group and the non-ICI group. Further research with larger sample size and prospective study design is warranted to confirm these findings and to explore the optimal adjuvant treatment strategies for acral melanoma.

Some studies included in this systematic review compared the effectiveness of adjuvant therapy in acral melanoma with that in other subtypes of melanoma. In a retrospective study involving 90 Chinese patients, adjuvant anti-PD-1 therapy was found to significantly improve RFS and DMFS compared to high-dose IFN in patients with cutaneous melanoma. However, no significant difference was observed in patients with acral melanoma.<sup>26</sup> Additionally, a retrospective multicenter study involving 78 Japanese patients showed that acral melanoma had a significantly lower 12-month RFS compared to other cutaneous types. Furthermore, the multivariate analysis confirmed that the acral type was an independent risk factor for poor RFS.<sup>24</sup> These findings suggest that adjuvant anti-PD-1 therapy may be less effective for acral melanoma compared to other cutaneous types. Many studies have demonstrated that acral melanoma exhibits distinct biological features when compared to cutaneous melanoma.<sup>1,2,20</sup> These differences may explain the lower effectiveness of conventional cutaneous melanoma therapies in treating acral melanoma. UV exposure plays a minor role in the development of acral melanoma, which demonstrates a lower TMB compared to melanomas originating from sun-exposed areas.<sup>6,35,36</sup> A higher TMB is associated with a more favorable response to immunotherapy. Consequently, adjuvant anti-PD-1 therapy seems to be less effective in treating resected acral melanoma.<sup>37,38</sup> A retrospective analysis conducted in China suggested that prior treatment with PEG-IFN improved the median RFS of adjuvant pembrolizumab in resected advanced melanoma, including the cases of acral type.<sup>27</sup> This implies that administering PEG-IFN before pembrolizumab could offer a more promising treatment option for patients with acral melanoma compared to pembrolizumab alone. Notably, PEG-IFN has a longer half-life in circulation than the parent drug, suggesting its potential in designing combination therapeutic strategies.<sup>10,39,40</sup>

The findings from the multicenter retrospective study in Japan underscore the potential efficacy of targeted therapy with dabrafenib plus trametinib in patients with *BRAF*-mutated advanced melanoma, including those with

**Table 2** Comparison of Recurrence-Free Survival (RFS), Distant Metastasis-Free Survival (DMFS), and Overall Survival (OS) Across Adjuvant Regimens for Acral Melanoma

Adjuvant Regimen	HR (95% CI)	P value
Comparison RFS		
PD-1 inhibitor vs Observation	0.69 (0.52–0.92)	0.013
PD-1 inhibitor vs IFN/Observation	0.64 (0.40–1.02)	0.05
PD-1 inhibitor vs High-dose IFN	1.20 (0.52–2.78)	0.63
PEG-IFN + pembrolizumab vs Pembrolizumab	0.54 (0.25–1.16)	0.11
Pembrolizumab vs High-dose IFN	1.22 (0.29–5.19)	0.79
Comparison DMFS		
PD-1 inhibitor vs Observation	0.58 (0.38–0.89)	0.013
PD-1 inhibitor vs High-dose IFN	1.97 (0.74–5.21)	0.16
Comparison OS		
PD-1 inhibitor vs Observation	0.59 (0.38–0.92)	0.020

**Abbreviations:** CI, confidence interval; DMFS, distant metastasis-free survival; HR, hazard ratio; IFN, interferon  $\alpha$ -2b; PEG-IFN, pegylated interferon  $\alpha$ -2b; RFS, recurrence-free survival; OS, overall survival.

acral melanoma. The observed 12-month RFS rate of 82.1% suggests a substantial benefit from this treatment approach, consistent with the COMBI-AD trial.<sup>17,28</sup> Additionally, the remarkable 100% 12-month RFS among patients with acral melanoma harboring *BRAF* mutation highlights the importance of targeted therapy in improving outcomes for this specific subtype of melanoma. However, given the limited sample size of patients with acral melanoma in this study, prospective clinical trials specifically focusing on acral melanoma could provide more robust evidence regarding the efficacy of targeted therapy.

The studies included in this systematic review had limited reporting on safety outcomes. The randomized phase II trial demonstrated that the incidence of most toxicities in Chinese patients was higher compared to the Greek trial,<sup>12</sup> despite dose reduction being performed. Although AEs were prevalent, the majority were Grade 1 or 2 and reversible. The most common Grade 3 or 4 AEs were leukopenia and hepatotoxicity.<sup>30</sup> For adjuvant anti-PD-1 therapy, major subtypes of irAEs include endocrine disorders and liver dysfunctions in Asians, whereas Caucasians tend to experience respiratory and gastrointestinal disorders as predominant subtypes.<sup>25,41</sup> A single-center retrospective study confirmed the safety of anti-PD-1 therapy, as only 3 patients (6.8%) discontinued treatment due to drug-related AEs, and there were no related deaths.

This study has several limitations. Firstly, the systematic review included a small number of studies due to limited exploration in this field. Secondly, most of the included studies were rated as having poor or fair methodological quality, with 10 out of 11 being retrospective in nature, which inherently introduces biases and limitations in data collection and analysis. Thirdly, the absence of reported data on key outcomes such as RFS, DMFS, OS, or AEs in some studies limited the comprehensive analysis of these parameters due to missing information. Larger prospective studies or clinical trials comparing various adjuvant therapies head-to-head are warranted.

## Conclusion

This systematic review comprehensively analyzed the efficacy and safety profile of adjuvant therapy in high-risk resected acral melanoma (Tables 1 and 2). The findings of this study suggest that high-dose IFN was commonly used as adjuvant therapy for acral melanoma, but serious AEs necessitated the exploration of alternative options. Adjuvant anti-PD-1 therapy demonstrates an anti-tumor effect in acral melanoma, although its efficacy may not be as effective as in non-acral cutaneous melanoma. Further prospective studies with larger sample sizes are warranted to explore the optimal adjuvant therapeutic strategies for acral melanoma.

## Data Sharing Statement

All inquiries can be directed to the corresponding authors.

## Ethics Statement

This study conformed to the principles of the Helsinki Declaration and ethical requirements involving human subjects. Informed consent was not required because of the retrospective design and anonymization of the study.

## Author Contributions

All authors made a significant contribution to the work reported, whether that is in the conception, study design, execution, acquisition of data, analysis and interpretation, or in all these areas; took part in drafting, revising or critically reviewing the article; gave final approval of the version to be published; have agreed on the journal to which the article has been submitted; and agree to be accountable for all aspects of the work.

## Disclosure

The authors have no conflicts of interest in this work.

## References

1. Carvalho LAD, Aguiar FC, Smalley KSM, Possik PA. Acral melanoma: new insights into the immune and genomic landscape. *Neoplasia*. 2023;46:100947. doi:10.1016/j.neo.2023.100947
2. Basurto-Lozada P, Molina-Aguilar C, Castaneda-Garcia C, et al. Acral lentiginous melanoma: basic facts, biological characteristics and research perspectives of an understudied disease. *Pigm Cell Melanoma Res*. 2021;34:59–71. doi:10.1111/pcmr.12885
3. Markovic SN, Erickson LA, Rao RD, et al. Malignant melanoma in the 21st century, part 1: epidemiology, risk factors, screening, prevention, and diagnosis. *Mayo Clin Proc*. 2007;82:364–380. doi:10.4065/82.3.364
4. Rawson RV, Johansson PA, Hayward NK, et al. Unexpected UVR and non-UVR mutation burden in some acral and cutaneous melanomas. *Lab Invest*. 2017;97:130–145. doi:10.1038/labinvest.2016.143
5. Newell F, Johansson PA, Wilmott JS, et al. Comparative genomics provides etiologic and biological insight into melanoma subtypes. *Cancer Discov*. 2022;12:2856–2879. doi:10.1158/2159-8290.CD-22-0603
6. Hayward NK, Wilmott JS, Waddell N, et al. Whole-genome landscapes of major melanoma subtypes. *Nature*. 2017;545:75–180.
7. Sheen Y-S, Tan K-T, Tse K-P, et al. Genetic alterations in primary melanoma in Taiwan. *Br J Dermatol*. 2020;182:1205–1213. doi:10.1111/bjd.18425
8. Alicea GM, Rebecca VW. Un-fair skin: racial disparities in acral melanoma research. *Nat Rev Cancer*. 2022;22:127–128. doi:10.1038/s41568-022-00443-8
9. Di Carlo V, Stiller CA, Eisemann N, et al. Does the morphology of cutaneous melanoma help to explain the international differences in survival? Results from 1 578 482 adults diagnosed during 2000-2014 in 59 countries (concord-3). *Br J Dermatol*. 2022;187:364–380. doi:10.1111/bjd.21274
10. Wada-Ohno M, Ito T, Furue M. Adjuvant therapy for melanoma. *Curr Treat Options Oncol*. 2019;20:63. doi:10.1007/s11864-019-0666-x
11. Eggermont AMM, Suciu S, Testori A, et al. Long-term results of the randomized phase III trial EORTC 18991 of adjuvant therapy with pegylated interferon alfa-2b versus observation in resected stage III melanoma. *J Clin Oncol*. 2012;30:3810–3818. doi:10.1200/JCO.2011.41.3799
12. Pectasides D, Dafni U, Bafaloukos D, et al. Randomized phase III study of 1 month versus 1 year of adjuvant high-dose interferon alfa-2b in patients with resected high-risk melanoma. *J Clin Oncol*. 2009;27:939–944. doi:10.1200/JCO.2008.16.3121
13. Kirkwood JM, Strawderman MH, Ernstoff MS, et al. Interferon alfa-2b adjuvant therapy of high-risk resected cutaneous melanoma: the Eastern cooperative oncology group trial EST 1684. *J Clin Oncol*. 1996;14:7–17. doi:10.1200/JCO.1996.14.1.7
14. Luke JJ, Rutkowski P, Queirolo P, et al. Pembrolizumab versus placebo as adjuvant therapy in completely resected stage IIB or IIC melanoma (KEYNOTE-716): a randomised, double-blind, Phase 3 trial. *Lancet*. 2022;399:1718–1729. doi:10.1016/S0140-6736(22)00562-1
15. Eggermont AMM, Blank CU, Mandala M, et al. Adjuvant pembrolizumab versus placebo in resected stage III melanoma. *N Engl J Med*. 2018;378:1789–1801. doi:10.1056/NEJMoa1802357
16. Weber J, Mandala M, Del Vecchio M, et al. Adjuvant nivolumab versus ipilimumab in resected stage III or IV melanoma. *N Engl J Med*. 2017;377:1824–1835. doi:10.1056/NEJMoa1709030
17. Long GV, Hauschild A, Santinami M, et al. Adjuvant dabrafenib plus trametinib in stage III BRAF -mutated melanoma. *N Engl J Med*. 2017;377:1813–1823. doi:10.1056/NEJMoa1708539
18. Liberati A, Altman DG, Tetzlaff J, et al. The PRISMA statement for reporting systematic reviews and meta-analyses of studies that evaluate health care interventions: explanation and elaboration. *PLoS Med*. 2009;6:e1000100. doi:10.1371/journal.pmed.1000100
19. Arak H, Erkiliç S, Yaslikaya Ş, et al. The effectiveness of adjuvant PD-1 inhibitors in patients with surgically resected stage III/IV acral melanoma. *J Immunother*. 2024;47:182–189. doi:10.1097/CJI.0000000000000508
20. Jacques SK, McKeown J, Grover P, et al. Outcomes of patients with resected stage III/IV acral or mucosal melanoma, treated with adjuvant anti-PD-1 based therapy. *Eur J Cancer*. 2024;199:113563. doi:10.1016/j.ejca.2024.113563
21. Mo Z, Liu J, Zhang J, et al. Association of NRAS mutations and tertiary lymphoid structure formation with clinical outcomes of adjuvant PD-1 inhibitors for acral melanoma. *Int Immunopharmacol*. 2023;124:110973. doi:10.1016/j.intimp.2023.110973
22. Li T, Li T, Fang G, et al. Adjuvant anti-PD-1 immunotherapy versus conventional therapy for stage III melanoma: a real-world retrospective cohort study. *Pharmaceuticals*. 2023;16:952. doi:10.3390/ph16070952
23. Maeda T, Yanagi T, Miyamoto K, et al. Adjuvant nivolumab therapy may not improve disease-free survival in resected acral lentiginous melanoma patients: a retrospective case series. *Dermatol Ther*. 2022;35:e15817. doi:10.1111/dth.15817
24. Muto Y, Kambayashi Y, Kato H, et al. Adjuvant anti-PD-1 antibody therapy for advanced melanoma: a multicentre study of 78 Japanese cases. *Acta Dermato-Venereologica*. 2022;102:adv00756. doi:10.2340/actadv.v102.678

25. Muto Y, Kambayashi Y, Kato H, et al. Adverse events associated with postoperative outcomes of adjuvant anti-PD-1 antibody therapy in both acral and non-acral cutaneous melanomas: a multicenter, observational, post hoc analysis study. *J Dermatol.* 2023;51:458–462. doi:10.1111/1346-8138.16912
26. Li J, Wang J, Li D, et al. Adjuvant PD-1 inhibitor versus high-dose interferon  $\alpha$ -2b for Chinese patients with cutaneous and acral melanoma: a retrospective cohort analysis. *Dermatol Ther.* 2021;34:e15067.
27. Jia DD, Niu Y, Zhu H, et al. Prior therapy with pegylated-interferon Alfa-2b improves the efficacy of adjuvant pembrolizumab in resectable advanced melanoma. *Front Oncol.* 2021;11:675873. doi:10.3389/fonc.2021.675873
28. Amagai R, Muto Y, Kato H, et al. Retrospective analysis of adjuvant therapy using dabrafenib plus trametinib in Japanese patients with advanced melanoma: analysis of 36 cases. *Melanoma Res.* 2021;31:575–578. doi:10.1097/CMR.0000000000000770
29. Li T, Jia -D-D, Teng L-S. Adjuvant pembrolizumab versus high-dose interferon  $\alpha$ -2b for Chinese patients with resected stage III melanoma: a retrospective cohort study. *Invest New Drugs.* 2020;38:1334–1341. doi:10.1007/s10637-020-00913-6
30. Mao L, Si L, Chi Z, et al. A randomised phase II trial of 1 month versus 1 year of adjuvant high-dose interferon  $\alpha$ -2b in high-risk acral melanoma patients. *Eur J Cancer.* 2011;47:1498–1503. doi:10.1016/j.ejca.2011.03.019
31. Eggermont AMM, Chiarion-Sileni V, Grob -J-J, et al. Prolonged survival in stage III melanoma with ipilimumab adjuvant therapy. *N Engl J Med.* 2016;375:1845–1855. doi:10.1056/NEJMoal611299
32. Tarhini AA, Lee SJ, Hodi FS, et al. Phase III study of adjuvant ipilimumab (3 or 10 mg/kg) versus high-dose interferon Alfa-2b for resected high-risk melanoma: North American intergroup E1609. *J Clin Oncol.* 2020;38:567–575. doi:10.1200/JCO.19.01381
33. Ascierto PA, Del Vecchio M, Mandalá M, et al. Adjuvant nivolumab versus ipilimumab in resected stage IIIB-C and stage IV melanoma (CheckMate 238): 4-year results from a multicentre, double-blind, randomised, controlled, phase 3 trial. *Lancet Oncol.* 2020;21:1465–1477. doi:10.1016/S1470-2045(20)30494-0
34. Grossmann KF, Othus M, Patel SP, et al. Adjuvant pembrolizumab versus IFN $\alpha$ 2b or ipilimumab in resected high-risk melanoma. *Cancer Discov.* 2022;12:644–653. doi:10.1158/2159-8290.CD-21-1141
35. Newell F, Wilmott JS, Johansson PA, et al. Whole-genome sequencing of acral melanoma reveals genomic complexity and diversity. *Nat Commun.* 2020;11:5259. doi:10.1038/s41467-020-18988-3
36. Newell F, Kong Y, Wilmott JS, et al. Whole-genome landscape of mucosal melanoma reveals diverse drivers and therapeutic targets. *Nat Commun.* 2019;10:3163. doi:10.1038/s41467-019-11107-x
37. Dousset L, Poizeau F, Robert C, et al. Positive association between location of melanoma, ultraviolet signature, tumor mutational burden, and response to Anti-PD-1 therapy. *JCO Precis Oncol.* 2021;5:1821–1829. doi:10.1200/PO.21.00084
38. Yarchoan M, Hopkins A, Jaffee EM. Tumor mutational burden and response rate to PD-1 inhibition. *N Engl J Med.* 2017;377:2500–2501. doi:10.1056/NEJMc1713444
39. Eggermont AM, Suci S, Santinami M, et al. Adjuvant therapy with pegylated interferon alfa-2b versus observation alone in resected stage III melanoma: final results of EORTC 18991, a randomised phase III trial. *Lancet.* 2008;372:117–126. doi:10.1016/S0140-6736(08)61033-8
40. Zhang Y, Lan S, Wu D. Advanced acral melanoma therapies: current status and future directions. *Curr Treat Options Oncol.* 2022;23:1405–1427. doi:10.1007/s11864-022-01007-6
41. Bai X, Shoushtari AN, Betof Warner A, et al. Benefit and toxicity of programmed death-1 blockade vary by ethnicity in patients with advanced melanoma: an international multicentre observational study. *Br J Dermatol.* 2022;187:401–410. doi:10.1111/bjd.21241

## Clinical, Cosmetic and Investigational Dermatology

Dovepress

### Publish your work in this journal

Clinical, Cosmetic and Investigational Dermatology is an international, peer-reviewed, open access, online journal that focuses on the latest clinical and experimental research in all aspects of skin disease and cosmetic interventions. This journal is indexed on CAS. The manuscript management system is completely online and includes a very quick and fair peer-review system, which is all easy to use. Visit <http://www.dovepress.com/testimonials.php> to read real quotes from published authors.

Submit your manuscript here: <https://www.dovepress.com/clinical-cosmetic-and-investigational-dermatology-journal>