


Hemodialysis Catheter-Related Bloodstream Infection Caused by *Pantoea*: Report of Two Cases and Literature Review

Xiuri Wang¹, Yunxiao Liang¹, Liuyang Hu^{1,2} 

¹Department of Gastroenterology, The People's Hospital of Guangxi Zhuang Autonomous Region, Guangxi Academy of Medical Sciences, Nanning, 530016, People's Republic of China; ²Department of Laboratory Medicine, The People's Hospital of Guangxi Zhuang Autonomous Region, Guangxi Academy of Medical Sciences, Nanning, 530016, People's Republic of China

Correspondence: Liuyang Hu, Department of Laboratory Medicine, The People's Hospital of Guangxi Zhuang Autonomous Region, Guangxi Academy of Medical Sciences, Nanning, 530016, People's Republic of China, Email 1225432679@qq.com

Abstract: Species of *Pantoea* are mainly environmental strains and plant pathogens, rarely causing human infections. Here, we describe two cases of hemodialysis catheter-related bloodstream infection caused by *Pantoea* in patients with uremia. To our knowledge, this is the first reported case of catheter related bloodstream infection caused by *Pantoea dispersa* (*P. dispersa*) in hemodialysis patients, as well as the first case of bloodstream infection caused by *Pantoea anthophila* (*P. anthophila*). Multiple blood cultures from the catheter showed the presence of *Pantoea*, and the isolated *P. dispersa* and *P. anthophila* were found to be highly sensitive to various antibiotics. Prompt use of antibiotics and catheter lock with gentamicin or amikacin led to rapid recovery of the patients, avoiding the economic burden of catheter replacement. Infections caused by *Pantoea* might be underestimated as methods such as VITEK[®] MS system often result in misidentification. Therefore, we recommend using advanced techniques such as matrix-assisted laser desorption/ionization time-of-flight mass spectrometry (MALDI-TOF MS) or 16S ribosomal RNA analysis to detect more cases of *Pantoea* infections. By sharing these cases, we hope to increase awareness among clinicians about the potential pathogenicity of *Pantoea* in hemodialysis patients. It is crucial to strengthen noting the primary concern for sources of infection with *Pantoea* species (plant and environmental exposures) to prevent outbreaks of *Pantoea*-related bloodstream infections in hospitals.

Keywords: hemodialysis catheter-related bloodstream infections, nosocomial bloodstream, *pantoea* genus, *pantoea dispersa*, *pantoea anthophila*

Introduction

Pantoea is a rare, gram-negative opportunistic pathogen. Species of this genus are usually isolated from soil, fruits, and vegetables.^{1,2} *Pantoea* occasionally causes human infections, including joint infections,³ urinary tract infections,⁴ and bloodstream infections,⁵ often in association with penetrating plant-related injuries or immunosuppression and indwelling vascular devices.^{1,5} *Pantoea* genus contain 20 different species, with *P. agglomerans* being the most common species associated with human infections and recently described as causing hospital outbreaks.^{6,7} Although *P. dispersa* is considered to have low virulence, it can be fatal in infants, postoperative patients, and those with immunocompromised conditions, and only a limited number of clinical cases of disseminated *P. dispersa* bloodstream infections have been described.⁸ *P. anthophila* has low pathogenicity characteristics, and the first case of urinary tract infection caused by *P. anthophila* was described by Zhang et al,⁴ with no reports of this microorganism causing bloodstream infections in humans. It has been observed that bloodstream infections events are significantly associated with hemodialysis vascular access.⁹ Common pathogens causing bloodstream infections in hemodialysis are often gram-positive cocci (*Staphylococcus aureus* and *Enterococcus*),¹⁰ while gram-negative bacteria and fungi are less common. Here, we describe two cases of hemodialysis patients with *Pantoea*-induced bloodstream infections related to dialysis catheters.

To our knowledge, this is the first reported case of catheter related bloodstream infection caused by *P. dispersa* in hemodialysis patients, as well as the first case of bloodstream infection caused by *P. anthophila*.

Case Presentation

Case I

A 59-year-old female patient was diagnosed with uremia in 2020. After undergoing a right internal jugular central venous catheter placement, she received regular hemodialysis twice a week. In 2021, during the hemodialysis process, the patient repeatedly experienced insufficient blood flow, with a maximum blood flow of 160 mL/min. Despite repeated thrombolytic therapy, the effect was unsatisfactory. During the next month, the patient was admitted to the Nephrology Department of People's Hospital of Guangxi Zhuang Autonomous Region due to fever and chills during hemodialysis. The routine physical examination on admission included a temperature of 38.6°C, a pulse rate of 87 beats/min, and a blood pressure of 110/76 mmHg. The laboratory examination revealed white blood cell count of $5.90 \times 10^9/L$, hemoglobin of 73 g/L, platelet count of $123 \times 10^9/L$. C-reactive protein of 101.22 mg/L (normal values 0–5 mg/L), procalcitonin of >100.00 ng/mL (normal values 0–0.05 ng/mL), ferritin of 505.0 ug/L, urea of 16.42 mmol/L, creatinine of 617.20 umol/L. Clinicians suspected long-term hemodialysis catheter infection and sent an aerobic and anaerobic culture bottle of catheter blood culture for examination. The patient received intravenous anti infection treatment with piperacillin tazobactam 2.25g Q8h and catheter lock with gentamicin. On the fourth day of hospitalization, two catheter blood cultures showed *P. dispersa*, which was only resistant to cefazolin and sensitive to other antibiotics (Table 1). Therefore, piperacillin-tazobactam was continued for the anti-infective treatment. After 6 days of hospitalization, the patient had no fever, C-reactive protein and procalcitonin decreased significantly, and a repeat catheter blood culture was negative. On the eighth day of hospitalization, the patient was able to undergo hemodialysis smoothly after catheter thrombolysis, avoiding the economic burden of catheter replacement. After 17 days of hospitalization, the patient's condition improved and discharged. During the one-year follow-up period, no further infections were observed.

Table 1 Antimicrobial Susceptibility of *P. Dispersa* and *P. Anthophila*

Antibiotics	<i>P. dispersa</i>		<i>P. anthophila</i>	
	MIC (mg/mL)	Interpretation	MIC (mg/mL)	Interpretation
Amikacin	≤8	S	≤8	S
Gentamicin	≤2	S	≤2	S
Tobramycin	≤2	S	≤2	S
Ertapenem	0.5	S	≤0.25	S
Imipenem	0.25	S	0.5	S
Meropenem	0.25	S	≤0.13	S
Cefazolin	16	R	≤2	S
Cefuroxime	4	S	≤4	S
Ceftazidime	≤1	S	≤1	S
Ceftriaxone	≤1	S	≤1	S
Cefepime	≤1	S	≤1	S
Cefoperazone/sulbactam	1/8	S	≤0.5/8	S
Aztreonam	≤2	S	≤2	S
Amoxicillin/clavulanate	8/4	S	≤8/4	S
Ampicillin/sulbactam	8/4	S	≤4/2	S
Piperacillin/tazobactam	≤4/4	S	≤4/4	S
Trimethoprim/sulfamethoxazole	≤1/19	S	≤1/19	S
Ciprofloxacin	≤0.25	S	≤0.25	S
Levofloxacin	≤0.5	S	≤0.5	S
Minocycline	≤1	S	≤1	S
Tetracycline	≤2	S	≤2	S
Tigecycline	≤1	S	≤1	S

Case 2

A 57-year-old female patient was diagnosed with uremia in 2020 and underwent regular hemodialysis three times a week after right internal jugular central venous catheter placement. In 2024, she was admitted to the Nephrology Department of People's Hospital of Guangxi Zhuang Autonomous Region due to chills during the dialysis process for one week. Her temperature was 36.5°C, blood pressure: 110/76 mmHg. Laboratory tests showed white blood cell count of $6.18 \times 10^9/L$, hemoglobin of 123 g/L, albumin of 37.1 g/L, urea of 19.90 mmol/L, creatinine of 921 $\mu\text{mol/L}$, cystatin C of 4.87 mg/L, uric acid of 421 $\mu\text{mol/L}$, C-reactive protein of 72.54 mg/L, procalcitonin 11.90 ng/mL, erythrocyte sedimentation rate (ESR) of 97.00 mm/h. The patient experienced chills during the dialysis process in the past week, and elevated C-reactive protein and procalcitonin, suggesting catheter-related infection. Two aerobic and two anaerobic culture bottle of catheter blood were sent for culture, and piperacillin-tazobactam 2.25g was administered every 8 hours for anti-infective treatment. Gentamicin was used for catheter lock after dialysis. On the second day of admission, the patient developed a fever (temperature 37.8°C) and chills. All four blood cultures grew a Gram-negative bacterium (Figure 1A) and showed yellow, smooth colonies (Figure 1B), which were confirmed as *P. anthophila* by MALDI-TOF MS (Figure 1C and D) and 16S rRNA gene sequencing. Therefore, the diagnosis of *P. anthophila* catheter-related bloodstream infection was confirmed. The antimicrobial susceptibility test conducted within 48 hours of a positive blood culture showed that the pathogen was susceptible to all tested antibiotics (Table 1). Although the drug susceptibility results indicated sensitivity to piperacillin-tazobactam currently being used, the patient had a fever and infection indicator procalcitonin increased to 22.40 ng/mL, suggesting poor response to the anti-infective treatment. According to the drug susceptibility results, the antibiotic regimen was switched to amikacin 0.3g intravenous drip daily and catheter lock after dialysis, combined with levofloxacin injection 0.5g every other day for anti-infective treatment. The patient was discharged after 14 days of hospitalization without removing the central venous catheter.

Discussion

Pantoea is a genus of Gram-negative bacteria in the family of Enterobacteriaceae, which has recently been separated from the genus *Enterobacter*. It is found in sewage, plants, feces, and soil. Many human infections are associated with plant-related injuries. Contaminated blood products, intravenous fluids, total parenteral nutrition, and anesthetics are also associated with *Pantoea* infections.^{6,7,11} It typically causes hospital-acquired infections in immunocompromised, elderly, and dialysis patients. As mentioned above, recent reports have suggested a correlation between *P. agglomerans* and severe peritoneal dialysis-related peritonitis,¹² but little is known about its association with hemodialysis. In hemodialysis patients, the use of central venous catheters increases the risk of infection compared to arteriovenous fistulas.¹

Currently, only a limited number of clinical cases of *Pantoea* genus bacteria have been described. Therefore, there is insufficient information about its pathogenic mechanisms. Infections caused by *Pantoea* may be underestimated, as a previous report documented that the VITEK[®] MS system falsely identified over 10% of *Pantoea* clinical isolates as species of the *Enterobacter* genus.¹³ Isolates of *Pantoea dispersa* were misidentified as *Klebsiella ozaenae* by MALDI Biotyper[®] and were ultimately identified as *Pantoea dispersa* by 16S rRNA analysis.¹⁴ Most reported cases that we identified in the literature were detected by MALDI-TOF MS, and half of them were diagnosed by 16S rRNA gene sequencing.^{8,14} More cases of infections caused by the *Pantoea* genus might be revealed with advancing technical methods, such as MALDI-TOF-MS or 16S rRNA analysis. A retrospective study on bloodstream infections caused by *Pantoea* in Italy from 2018 to 2023 demonstrated that *Pantoea* isolates showed high sensitivity to all antibiotics except ampicillin (63.2%), colistin (73.7%), and piperacillin/tazobactam (84.2%).¹⁵ The 28-day all-cause mortality rate for *Pantoea* bloodstream infections was 5.3%.¹⁵ In our case, the *Pantoea dispersa* was sensitive to all tested antibiotics except cefazolin, and *P. anthophila* was sensitive to all tested antibiotics. From a microbiological perspective, although *Pantoea* has multiple sensitivities, broad-spectrum antibiotics are mainly used for the treatment of *Pantoea* bloodstream infections.¹⁵ The most commonly used antibiotic treatments of bloodstream infections by *Pantoea* species for adults were piperacillin/tazobactam (21.4%), while pediatric patients were treated with meropenem (40%) and aminoglycosides (40%).¹⁵ Fortunately, our patient survived because appropriate antibiotic therapy was rapidly started. These results were similar to those of previous reports.^{16,17}

A total of eight cases of infections by *Pantoea* in hemodialysis patients, including ours, have previously been reported, as shown in Table 2. Previous reported 6 cases were caused by *P. agglomerans*, and our cases are the first

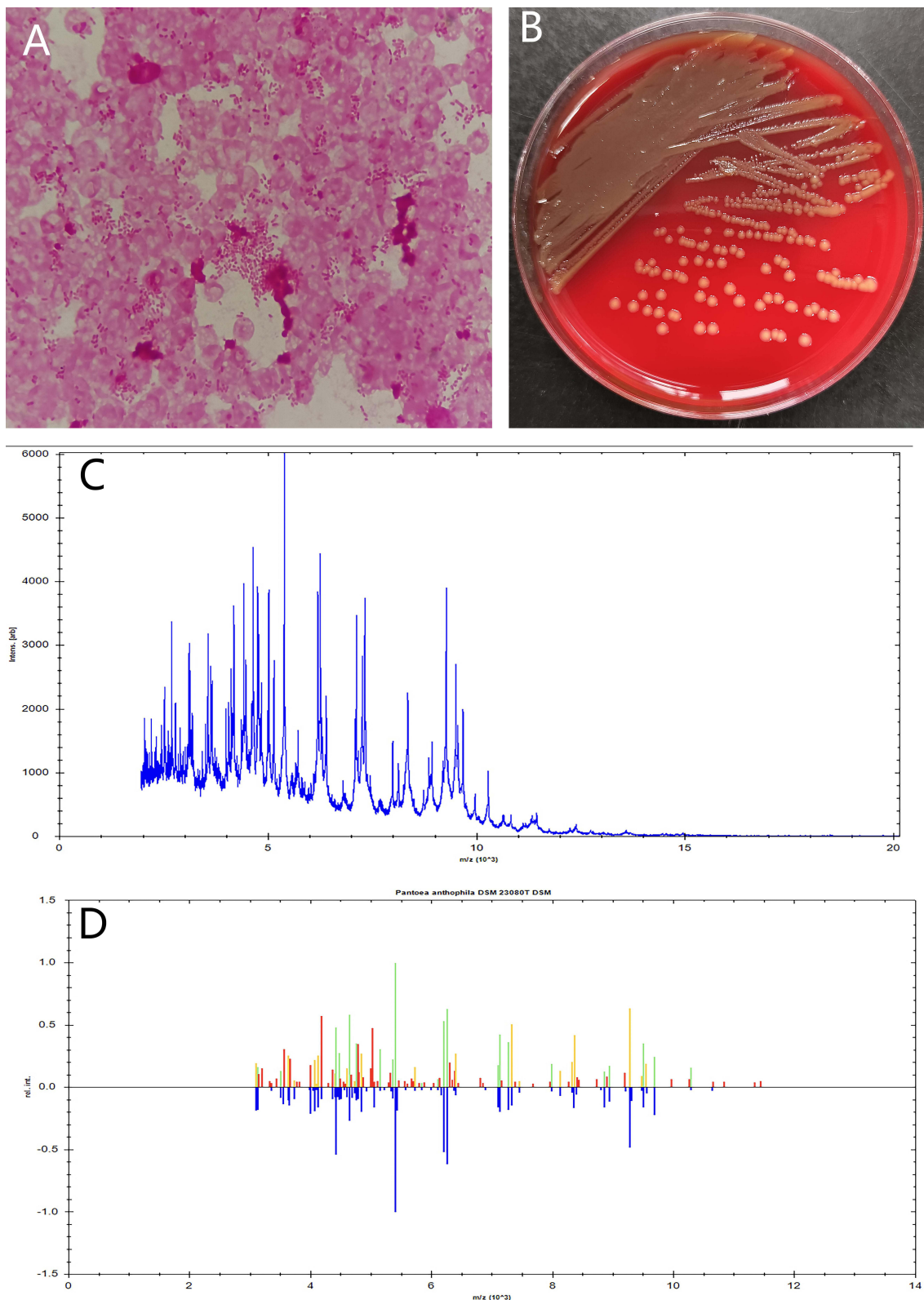


Figure 1 Isolation and identification of *P. anthophila*. **(A)** Gram stain of positive blood cultures showed Gram-negative bacteria; **(B)** Yellow, smooth colonies on Columbia blood agar after being cultured at 37°C, 5% CO₂ for 24 h; **(C)** The spectrogram with protein molecular mass of the strain acquired by MALDI-TOF MS; **(D)** Spectra comparison of the strain with that of known strains in a database matched to *P. anthophila* DSM 23080T with a high confidence level.

Table 2 Previous Cases of Hemodialysis Infection Caused by *Pantoea*

Year	Age/ Sex	Hemodialysis Vascular Access	Presentation	Diagnostic Sample	Causative Agent	Treatment	Prognosis	Treatment Duration
2013 ¹⁹	56/F	Central venous catheter	High-grade fever during dialysis for two weeks	Catheter blood culture	<i>P. agglomerans</i>	Sulperazone, ciprofloxacin, ceftriaxone; removed catheter	Cure	10w
2013 ¹⁹	39/M	Central venous catheter	Fever during hemodialysis	Catheter blood culture	<i>P. agglomerans</i>	Meropenem	Cure	14d
2015 ²⁰	40/F	Central venous catheter	Fever, Chills during hemodialysis	Blood culture	<i>P. agglomerans</i>	Ceftazidime and ciprofloxacin; removed catheter	Cure	3d
2020 ¹⁸	NR/F	Central venous catheter	NR	Peripheral blood culture, catheter blood culture	<i>P. agglomerans</i>	Vancomycin and gentamicin→meropenem; disinfect the water supply network and blood dialysis circuit	Cure	10d
2020 ¹⁸	NR/F	Central venous catheter	NR	Peripheral blood culture, catheter blood culture	<i>P. agglomerans</i>	Vancomycin and gentamicin→meropenem; disinfect the water supply network and blood dialysis circuit	Cure	10d
2020 ¹⁸	NR/F	Central venous catheter	NR	Peripheral blood culture, catheter blood culture	<i>P. agglomerans</i>	Vancomycin and gentamicin→meropenem; disinfect the water supply network and blood dialysis circuit	Cure	10d
Current Case (2021)	59/F	Central venous catheter	Fever, chills during hemodialysis	Catheter blood	<i>P. dispersa</i>	Piperacillin tazobactam; catheter lock with Gentamicin	Cure	17d
Current Case (2024)	57/F	Central venous catheter	Chills during hemodialysis	Catheter blood	<i>P. anthophila</i>	Piperacillin tazobactam, catheter lock with gentamicin→ amikacin, levofloxacin, catheter lock with amikacin	Cure	14d

Abbreviation: NR, not reported.

case of *P. dispersa* and *P. anthophila*-related hemodialysis-associated bloodstream infection. The epidemiological and clinical characteristics of *P. dispersa* and *P. anthophila* are still unclear. All 8 patients used central venous catheter to hemodialysis. The general recommendation for catheter-related infections is catheter removal, but in the context of hemodialysis, initial conservative treatment is attempted to preserve the venous access in the absence of other dialysis pathways. Currently, all 8 cases of *Pantoea*-related hemodialysis-associated bloodstream infections have had a good prognosis, with only 2 cases requiring catheter removal and the remaining 6 cases retaining the central venous catheter. In 2020, Borrego Garcia et al reported 3 cases of *P. agglomerans* caused a bloodstream infection outbreak in hemodialysis patients, all of whom had retained their internal jugular venous catheter.¹⁸ The patients showed improvement in infection status after receiving 10 days of post-dialysis treatment with meropenem. Correct disinfection of the tap water distribution system and hemodialysis circuit, as well as the implementation of updated aseptic measures for handling catheters, prevented the need for catheter replacement and the occurrence of new cases.¹⁸ In our case, prompt use of antibiotics and catheter lock with gentamicin or amikacin led to rapid recovery of the patients, avoiding the economic burden of catheter replacement.

Conclusion

In conclusion, we report two cases of catheter-related bloodstream infections in hemodialysis patients caused by *Pantoea dispersa* and *Pantoea anthophila*, respectively. Based on our experience, early detection of the pathogen, prompt use of antibiotics and catheter lock with gentamicin or amikacin led to rapid recovery of the patients, avoiding the economic burden of catheter. It is crucial to strengthen noting the primary concern for sources of infection with *Pantoea* species (plant and environmental exposures) to prevent outbreaks of *Pantoea*-related bloodstream infections in hospitals.

Data Sharing Statement

The datasets used and analysed during the current study available from the corresponding author on reasonable request.

Ethics Approval and Patient Consent

Written informed consents were obtained from both patients for the publication of the case details. The study was approved by the medical ethics committee of The People's Hospital of Guangxi Zhuang Autonomous Region and obtained The People's Hospital of Guangxi Zhuang Autonomous Region's approval for publish the case details.

Acknowledgments

We would like to acknowledge the reviewers for their helpful comments on this paper.

Author Contributions

All authors made a significant contribution to the work reported, whether that is in the conception, study design, execution, acquisition of data, analysis and interpretation, or in all these areas; took part in drafting, revising or critically reviewing the article; gave final approval of the version to be published; have agreed on the journal to which the article has been submitted; and agree to be accountable for all aspects of the work.

Funding

This study was supported by the Guangxi Natural Science Foundation under Grant No. 2024GXNSFBA010122 and Guangxi Natural Science Foundation under Grant No. 2023GXNSFBA026068.

Disclosure

The authors declare no conflict of interest in this work.

References

1. Cruz AT, Cazacu AC, Allen CH. Pantoea agglomerans, a plant pathogen causing human disease. *J Clin Microbiol.* 2007;45(6):1989–1992. doi:10.1128/JCM.00632-07
2. Van Rostenberghe H, Noraida R, Wan Pauzi WI, et al. The clinical picture of neonatal infection with pantoea species. *Jpn J Infect Dis.* 2006;59(2):120–121. doi:10.7883/yoken.JJID.2006.120
3. Koutserimpas C, Kotzias D, Naoum S, et al. Knee septic arthritis caused by pantoea agglomerans. *J Orthop Case Rep.* 2022;12(12):66–70. doi:10.13107/jocr.2022.v12.i12.3468
4. Zhang Y, Fan Y, Zhan Y, et al. Genomic characterization Of pantoea anthophila strain UI705 causing urinary tract infections in China. *Front Cell Infect Microbiol.* 2023;13:1208473. doi:10.3389/fcimb.2023.1208473
5. Cheng A, Liu CY, Tsai HY, et al. Bacteremia caused by pantoea agglomerans at a medical center in Taiwan, 2000-2010. *J Microbiol Immunol Infect.* 2013;46(3):187–194. doi:10.1016/j.jmii.2012.05.005
6. Boszczowski I, Nóbrega de Almeida Júnior J, Peixoto de Miranda EJ, et al. Nosocomial outbreak of Pantoea agglomerans bacteraemia associated with contaminated anticoagulant citrate dextrose solution: new name, old bug? *J Hosp Infect.* 2012;80(3):255–258. doi:10.1016/j.jhin.2011.12.006
7. Yablon BR, Dantes R, Tsai V, et al. Outbreak of pantoea agglomerans bloodstream infections at an oncology clinic-Illinois, 2012-2013. *Infect Control Hosp Epidemiol.* 2017;38(3):314–319. doi:10.1017/ice.2016.265
8. Ruan XL, Qin X, Li M. Nosocomial bloodstream infection pathogen Pantoea dispersa: a case report and literature review. *J Hosp Infect.* 2022;127:77–82. doi:10.1016/j.jhin.2022.06.011
9. Lok CE, Foley R. Vascular access morbidity and mortality: trends of the last decade. *Clin J Am Soc Nephrol.* 2013;8(7):1213–1219. doi:10.2215/CJN.01690213
10. Al-Solaiman Y, Estrada E, Allon M. The spectrum of infections in catheter-dependent hemodialysis patients. *Clin J Am Soc Nephrol.* 2011;6(9):2247–2252. doi:10.2215/CJN.03900411
11. Habsah H, Zeehaida M, Van Rostenberghe H, et al. An outbreak of pantoea spp. in a neonatal intensive care unit secondary to contaminated parenteral nutrition. *J Hosp Infect.* 2005;61(3):213–218. doi:10.1016/j.jhin.2005.01.004
12. Kazancioglu R, Buyukaydin B, Iraz M, et al. An unusual cause of peritonitis in peritoneal dialysis patients: pantoea agglomerans. *J Infect Dev Ctries.* 2014;8(7):919–922. doi:10.3855/jidc.3785
13. Richter SS, Sercia L, Branda JA, et al. Identification of Enterobacteriaceae by matrix-assisted laser desorption/ionization time-of-flight mass spectrometry using the VITEK MS system. *Eur J Clin Microbiol Infect Dis.* 2013;32(12):1571–1578. doi:10.1007/s10096-013-1912-y
14. Asai N, Koizumi Y, Yamada A, et al. Pantoea dispersa bacteremia in an immunocompetent patient: a case report and review of the literature. *J Med Case Rep.* 2019;13(1):33. doi:10.1186/s13256-019-1969-z
15. Casale R, Boattini M, Bianco G, et al. Bloodstream infections by pantoea species: clinical and microbiological findings from a retrospective study, Italy, 2018-2023. *Antibiotics.* 2023;12(12):1723. doi:10.3390/antibiotics12121723
16. Mehar V, Yadav D, Sanghvi J, et al. Pantoea dispersa: an unusual cause of neonatal sepsis. *Braz J Infect Dis.* 2013;17(6):726–728. doi:10.1016/j.bjid.2013.05.013
17. Hagiya H, Otsuka F. Pantoea dispersa bacteremia caused by central line-associated bloodstream infection. *Braz J Infect Dis.* 2014;18(6):696–697. doi:10.1016/j.bjid.2014.06.006
18. Borrego Garcia E, Ruiz Sancho AL, Plaza Lara E, et al. Bacteremia outbreak due to pantoea agglomerans in hemodialysis, an infection by an unexpected guest. *Nefrologia.* 2020;40(5):573–575. doi:10.1016/j.nefro.2019.11.002
19. Wong KW. Pantoea agglomerans as a rare cause of catheter-related infection in hemodialysis patients. *J Vasc Access.* 2013;14(3):306. doi:10.5301/jva.5000139
20. Abdalla A, Migdal S, Brock D, Bhat ZY. Pantoea Agglomerans: An Unusual Cause Of Catheter-Related Sepsis In A Hemodialysis Patient. *Am J Kidney Dis.* 2015;65(4):A15. doi:10.1053/j.ajkd.2015.02.003

Infection and Drug Resistance

Dovepress

Publish your work in this journal

Infection and Drug Resistance is an international, peer-reviewed open-access journal that focuses on the optimal treatment of infection (bacterial, fungal and viral) and the development and institution of preventive strategies to minimize the development and spread of resistance. The journal is specifically concerned with the epidemiology of antibiotic resistance and the mechanisms of resistance development and diffusion in both hospitals and the community. The manuscript management system is completely online and includes a very quick and fair peer-review system, which is all easy to use. Visit <http://www.dovepress.com/testimonials.php> to read real quotes from published authors.

Submit your manuscript here: <https://www.dovepress.com/infection-and-drug-resistance-journal>