

Surgical Management of Hereditary Gingival Fibromatosis: Case Series

Hassina Shadab¹, Aisha Nawabi¹, Abdurrahman Anwari², Mohammad Bashir Nejabi³,
Elaha Somaya Ghafari¹, Sajeya Karimi¹, Mohammad Eissa Ahmadi¹

¹Periodontics Department, Kabul University of Medical Sciences (KUMS), Kabul, Afghanistan; ²Operative/ Restorative Dentistry and Endodontics Department, Kabul University of Medical Sciences (KUMS), Kabul, Afghanistan; ³Prosthodontics Department, Kabul University of Medical Sciences (KUMS), Kabul, Afghanistan

Correspondence: Abdurrahman Anwari, Operative/ Restorative Dentistry and Endodontics Department, Kabul University of Medical Sciences (KUMS), Jamal Mena, 3rd District, Kabul, Afghanistan, Tel +93795125522, Email yammamyama@gmail.com

Abstract: Hereditary gingival fibromatosis (HGF) is an uncommon genetic condition marked by gradual and progressive overgrowth of fibrous tissue in the gums, which is benign in nature. It is a genetic disorder inherited in an autosomal dominant pattern, known for its considerable genetic diversity. The marginal, attached, and interdental gingivae are affected by this condition. The affected area appears pink, does not bleed easily, and exhibits a firm, fibrotic texture. Additionally, it displays a hard, widespread nodular growth that is smooth to stippled and has little bleeding tendency. Nevertheless, in certain instances, the enlargement may feel so dense and firm that it resembles bone upon palpation. Accordingly, esthetics and functions related to a healthy gingiva is also affected. The choice of treatment modality often depends on factors such as the severity of gingival overgrowth, available resources, and patient-specific considerations. Laser techniques and electrosurgery have emerged as valuable options, providing benefits like reduced discomfort and enhanced precision. However, traditional surgical methods remain highly effective, particularly when advanced technologies are not available. This article reports on three cases of hereditary gingival fibromatosis (HGF) treated with conventional gingivectomy, flap procedures, and resective osseous surgery (osteoplasty and osteotomy). The aim is to support the efficacy of these interventions in addressing patient complaints and preparing the groundwork for managing additional issues, such as speech and mastication difficulties, delayed eruption of permanent teeth, and malocclusion. The surgical treatment led to significant improvements: masticatory function was markedly enhanced, aesthetic outcomes were notably better, and oral hygiene significantly improved. Additionally, the procedures created favorable conditions for future treatments, including orthodontics, implants, or prosthetics, by providing a more manageable and functional oral environment.

Keywords: hereditary gingival fibromatosis, gingivectomy, osteoplasty, gingival enlargement, case series

Introduction

Hereditary gingival fibromatosis (HGF) is an uncommon, inherited, non-cancerous condition marked by the gradual and progressive overgrowth of fibrous tissue in the gums. The prevalence of HGF is rare, affecting approximately 1 in 175,000 individuals,¹ and it affects both sexes equally in terms of incidence.² It is a non-neoplastic infiltrative condition³ that, whether in an autosomal dominant or recessive form, can result in an isolated pathological condition or be linked with other disorders such as epilepsy, hypertrichosis, enlargement of facial bones, tumors of soft tissue, mental retardation, and Klippel-Trenaunay syndrome (KTS).^{4,5} This genetic autosomal dominant disorder^{4,6} is characterized by significant genetic diversity.⁷ Additionally, numerous studies have noted an increase in proliferation of subepithelial fibroblasts, along with heightened synthesis of collagen and fibronectin, coupled with a decrease in matrix metalloproteinases.⁸

Advancements in molecular genetics have linked gingival fibromatosis to chromosome locations 2p21-p22 and 5q13-q22. It has been determined that a mutation in the Son of Sevenless 1 (SOS-1) gene may be the cause of isolated GF.⁹ Furthermore, hormones related to sex and epidermal growth factor are also involved in the aberrant formation of gingival fibers.¹⁰ Clinical reports on enlarging gingiva state that they have a normal color,¹¹ hard consistency,¹² nodular form,¹³ and increased gingival

stippling.¹⁴ Gingival enlargement can manifest as localized or generalized and may affect both dental arches. It is most prevalent in the gingivae of the upper arch's tuber region and the lower arch's molar region.²

Clinically, HGF can lead to difficulties in speech, articulation, and mastication, as well as cause malocclusion, which can negatively affect a patient's appearance and mental health. It can also cause delayed eruption of permanent teeth. Periodontal disease will progress if treatment is not received.^{3,15} There have been reports of several HGF treatment methods, mostly surgical and laser-assisted removal of gingival enlargement.¹⁶ In this report, we describe three cases of severe HGF which were correlated within the family, along with the treatment implemented.

Case I

Patient information; A 24-year-old female patient, due to enlargement in her gingiva causing problems in mastication, speech, aesthetics, and psychosocial aspects, presented to the Periodontics ward of Dentistry Teaching Hospital, Ali Abad, Kabul, Afghanistan, on April 5th, 2022. The patient reported similar manifestations in her brother, cousins, uncle, and grandmother's gingiva. The patient did not have any other systemic disorders, and a thorough inquiry regarding her physical and mental status was conducted to rule out any syndrome associated with the enlargement. Additionally, the patient reported no usage of any specific medication.

The gingival overgrowth in the patient began during childhood in the tooth replacement stage. She underwent surgical treatment at the age of 9 years old. However, after some time, the symptoms of gingival enlargement recurred.

Clinical Findings

Intraoral examination revealed generalized enlargement of keratinized gingiva, with interdental papilla in the buccal, lingual, and palatal sides covering half of some teeth's anatomical crowns with gingiva (Figure 1). In soft tissue

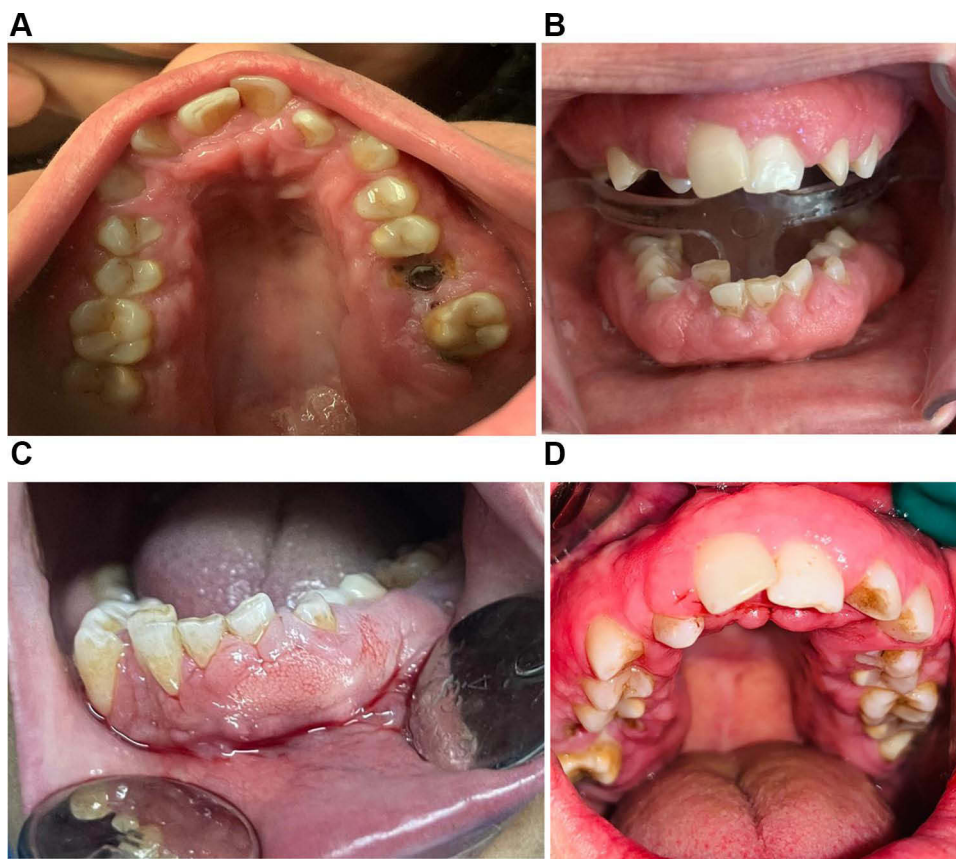


Figure 1 The intraoral view (A–D) of a patient with Hyperplastic Gingival Fibromatosis (HGF) shows a generalized overgrowth of the gingival tissues that covers a significant portion of the teeth, affecting both attached and free gingiva. The gingiva appears swollen and puffy, with a pale pink coloration and a granular texture, especially in the anterior mandible. The interdental papillae are notably pronounced, which has led to difficulties with mastication and oral hygiene. This symmetrical presentation significantly impacts both oral function and aesthetics.

examinations, the gingiva exhibited normal color, fibrotic texture, firm consistency, and fragile nature. Probing revealed some areas of pseudo pockets (4–6mm) with no signs of bleeding.

During extraoral examination, the lips, cheeks, and other areas appeared normal, with no signs of pathological conditions (Figure 2).

Radiographic examination, specifically orthopantomogram (OPG), revealed residual roots covered by gingiva with no signs of bone resorption (Figure 3).

Laboratory examination included a complete blood count (CBC), which showed results within the normal range.

Diagnostic Assessment

Based on the clinical findings and family history, the case was diagnosed as hereditary gingival fibromatosis, a diagnosis that was confirmed by pathological examination of a gingival biopsy (Figure 4). The patient and her parents were informed of the clinical and radiological results, and the patient's agreement regarding surgical intervention and participation in research were obtained.

Therapeutic Intervention

Periodontal maintenance, orthodontics, surgical periodontal therapy, and serial basic periodontal treatment were all part of our treatment strategy. During nonsurgical periodontal treatment, scaling, polishing, and oral hygiene instruction were provided to the patient, followed by a prescription of antibiotics (500 mg of Amoxicillin three times daily plus 400 mg of Metronidazole three times daily) for a duration of five days. Regrettably, there was no noticeable improvement in the gingival tissue.

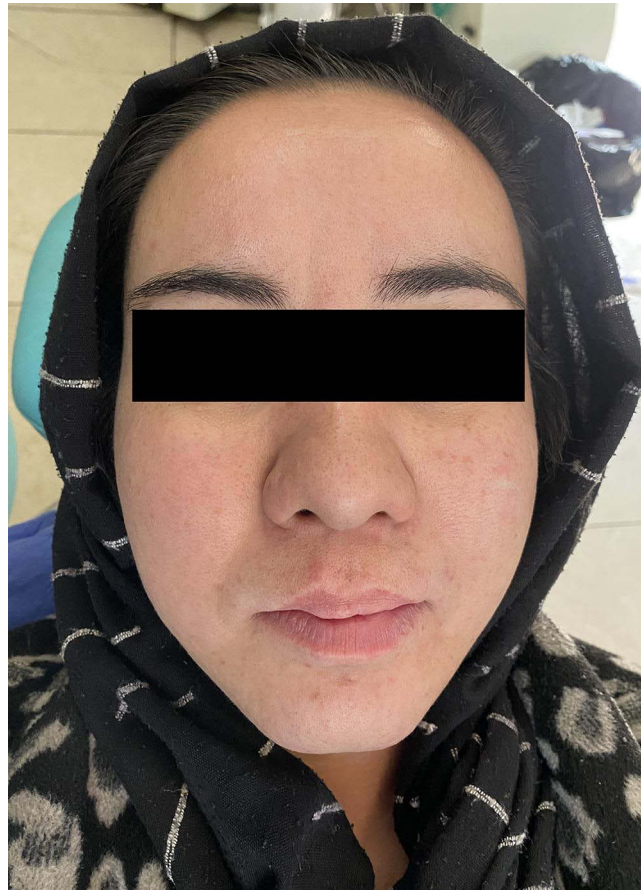

Figure 2 In the extraoral view of a patient with Hyperplastic Gingival Fibromatosis (HGF), the upper lip shows a slight bulge, while other facial features appear normal.

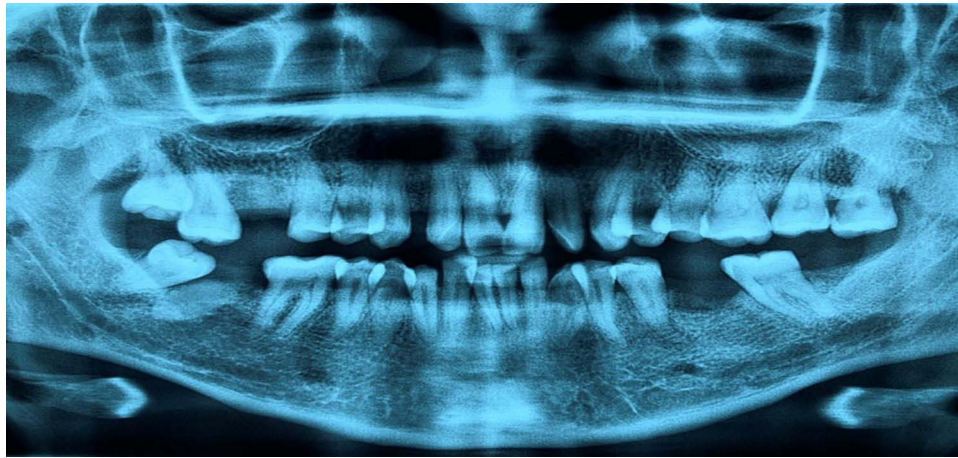


Figure 3 The orthopantomogram (OPG) of the mandible and maxilla shows mispositioning of some teeth, which may be related to gingival overgrowth. Additionally, missing teeth are noted in quadrants 1, 3, and 4, with a remaining root in quadrant 4.

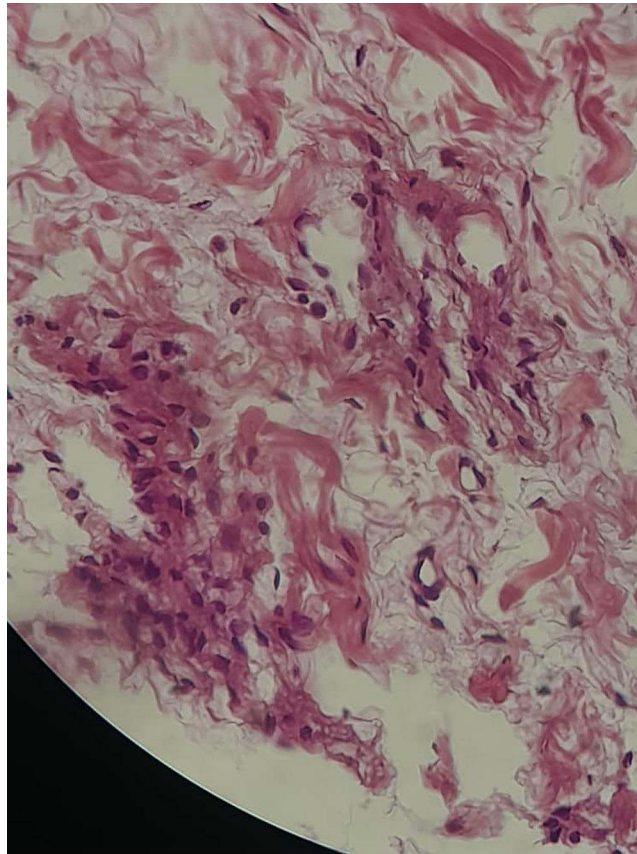


Figure 4 Microscopic examination revealed a dense collection of soft tissue neoplastic cells arranged in cellular fascicles and a storiform pattern. The cells are monomorphic, spindle-shaped, and have scant cytoplasm. The nucleoli are enlarged and hyperchromatic, with no cytological atypia observed. There is no evidence of mitosis in the examined lesion. The overlying squamous mucosa is unremarkable. There is no evidence of atypia or malignancy in the material examined.

In the next stage, the surgical periodontal procedure was performed for the patient over 6 appointments, spaced 3 weeks apart, with one quadrant treated at a time under local anesthesia.

After full-mouth disinfection with chlorhexidine 0.12% and disinfection of the lips and surrounding area with povidone, the surgery began under aseptic and antiseptic conditions. At the buccal/lingual side of one quadrant, 2%

lidocaine with 1/80,000 epinephrine was injected as local infiltration anesthesia. The depth of the pocket and cementoenamel junction (CEJ) level were marked with a Williams probe, and the site of the primary incision was determined. Submarginal internal bevel incisions were made at the site using blade #15, followed by sulcular incisions for the removal of excessive tissue. Soft tissue debridement and removal of granulation tissue were performed using curettes.

A flap was then elevated from the attached gingiva up to the mucogingival junction in a split-thickness manner, and connective tissue overlying the bone was removed thoroughly until the bone was exposed.

After the bone exposure, a dominant osseous ledge was noted on the buccal side of the maxillary bone. To prevent renewed recurrence and improve flap adaptation, resective osseous surgery was performed, including marginal bone recontouring, osteoplasty, and osteotomy. The margin of the alveolar buccal bone was placed 3mm apically to the CEJ to maintain the final result. Additionally, residual roots were extracted during curettage to prevent recurrent abscess formation.

Subsequently, the surgical site was thoroughly irrigated with normal saline, and the flap was sutured in place using Vicryl 4-0 (Figure 5).

The same procedure was performed for the palatal area to address the patient's mastication problems, with consideration of anatomical landmarks (Figure 6).

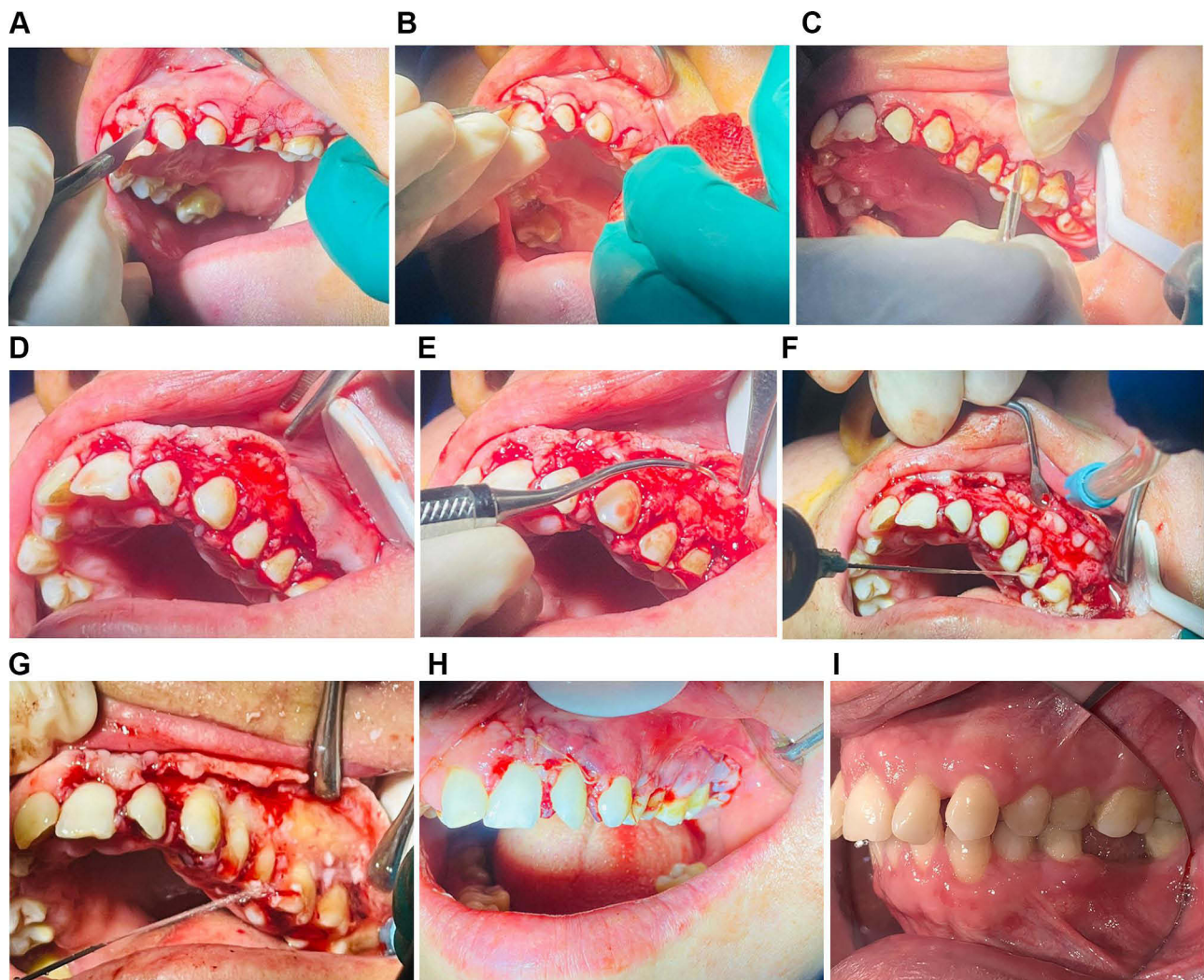

Figure 5 Step-by-step surgical procedure on the buccal side of the upper left quadrant: (A) Submarginal incisions, (B) Sulcular incisions, (C) Removal of excessive tissue, (D) Split-thickness flap elevation, (E) Removal of excessive connective tissue, (F) Exposure of several exostoses, (G) After osteotomy and osteoplasty, (H) Flap fixation, (I) One month after surgery.

The patient was scheduled for consistent follow-ups as follows: a checkup 2 days after the surgery, suture removal 2 weeks later, and then, 3 weeks after the previous surgery and once soft tissue healing of the previous operation area was achieved, we began the correction of the next quadrant.

All surgical procedures for the patient were completed within five months, and we conducted a one-year follow-up after the last periodontal surgery (Figure 7).

Follow Up and Outcomes

Following six months of surgical periodontal therapy and the maintenance phase, the patient underwent orthodontic treatment and is currently undergoing active orthodontic treatment (Figure 8).

Case 2

The primary complaint of a 20-year-old female patient in good systemic health who came to the Dentistry Teaching Hospital in Ali Abad, Kabul, Afghanistan, was widespread gingival swelling in the upper and lower jaw on both the buccal and lingual sides, persisting for 13 years and causing bad aesthetic appearance, masticatory difficulties, and phonation issues. There was no prior history of systemic illnesses in the patient such as hypertrichosis, mental retardation, blood pressure issues, or epilepsy controlled by medication. During family history assessment, gingival overgrowth was noted in the patient's cousins.

Clinical Findings

During intraoral examination, severe gingival enlargement was observed in both the mandibular and maxillary arches of the patient, with gingival overgrowth extending to cover a significant portion of the teeth crowns. Additionally, a row of deciduous teeth was visible in front of the anterior mandibular permanent teeth, causing severe malocclusion. The gingiva appeared pink in color, had a leathery consistency, and exhibited abundant stippling features (Figure 9).

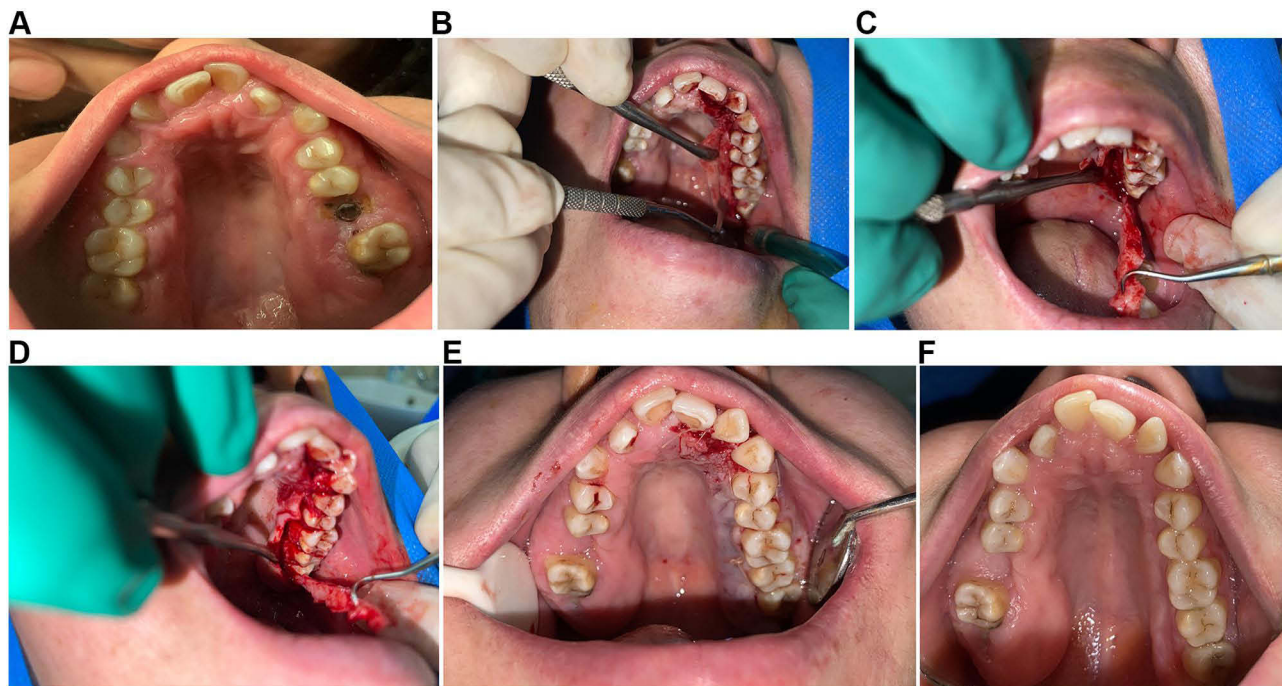


Figure 6 Surgery on the palatal side of the upper left quadrant: (A) Before surgery, showing gingival overgrowth on the palatal side, (B) Gingivectomy followed by split-thickness flap elevation, (C) Removal of excessive connective tissue, (D) Bone recontouring and flap adaptation, (E) Flap fixation, (F) One month after surgery.

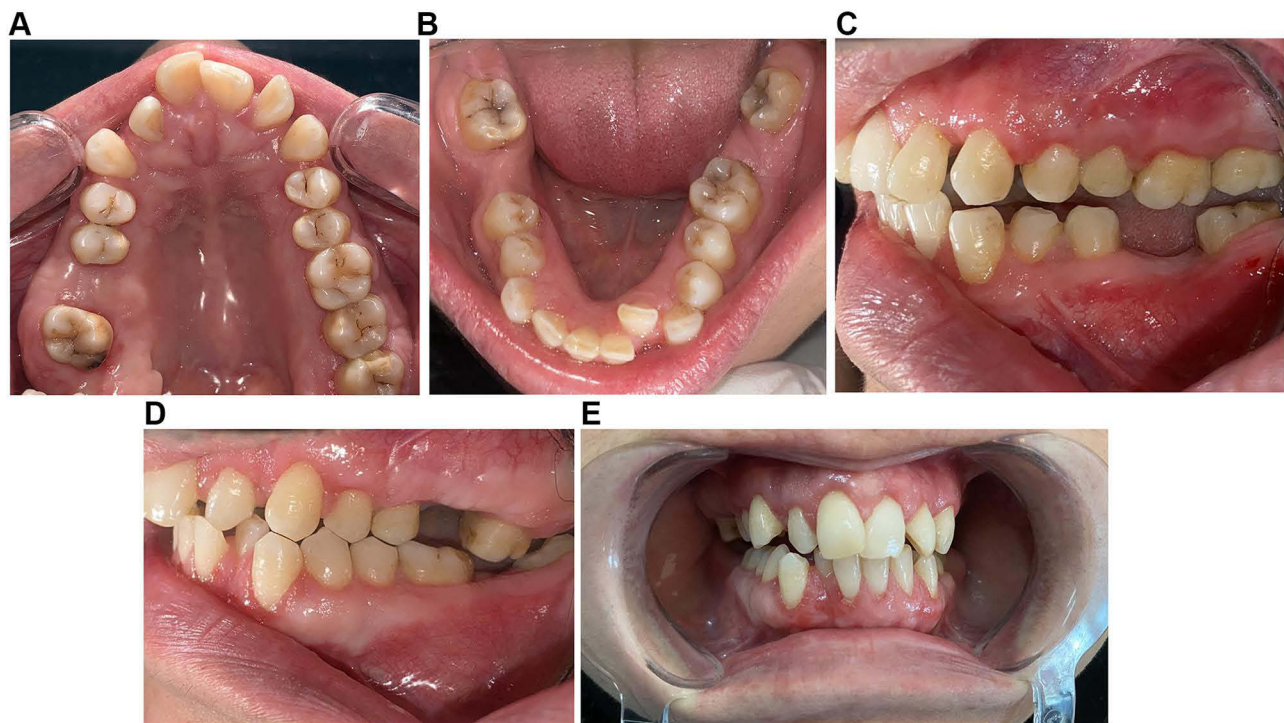


Figure 7 One year after surgery (A-E), the patient's gingiva has notably reduced in size, making the teeth more visible. The gingiva now has a more normal contour and texture, with decreased swelling and a healthier, pale pink color. The surface is smoother, and there are no signs of recurrent overgrowth. Oral function, including mastication and speech, has improved, and the aesthetic outcomes are enhanced with more natural-looking gingival tissues. Periodontal health is also better.

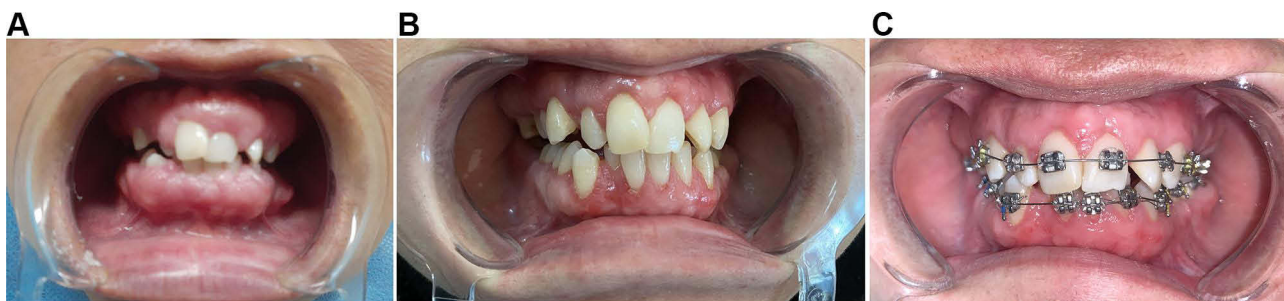

Figure 8 Frontal view: (A) Before surgery, (B) One year after surgery, (C) During orthodontic treatment.

In extra-oral examination facial asymmetry due to tooth displacement and lip incompetence was seen. The radiographic analysis, which made use of periapical and panoramic radiographs, showed that permanent teeth were present beneath the gingival tissue.

Diagnostic Assessment

Hereditary gingival fibromatosis was the diagnosis made in light of the patient's clinical presentation and family history.

Therapeutic Intervention

Our treatment includes serial basic periodontal treatment and surgical periodontal treatment. In the first month of the patient nonsurgical periodontal treatment which included scaling, and polishing with oral hygiene instruction done the patient was advised to take antibiotics (400 mg t.i.d. of metronidazole plus 500 mg of amoxicillin) for a duration of five days. In the next stage, the surgical periodontal procedure for the patient was done in 6 appointments at a distance of 3 weeks as in one appointment one quadrant of one side under local anesthesia was treated. The surgical procedure

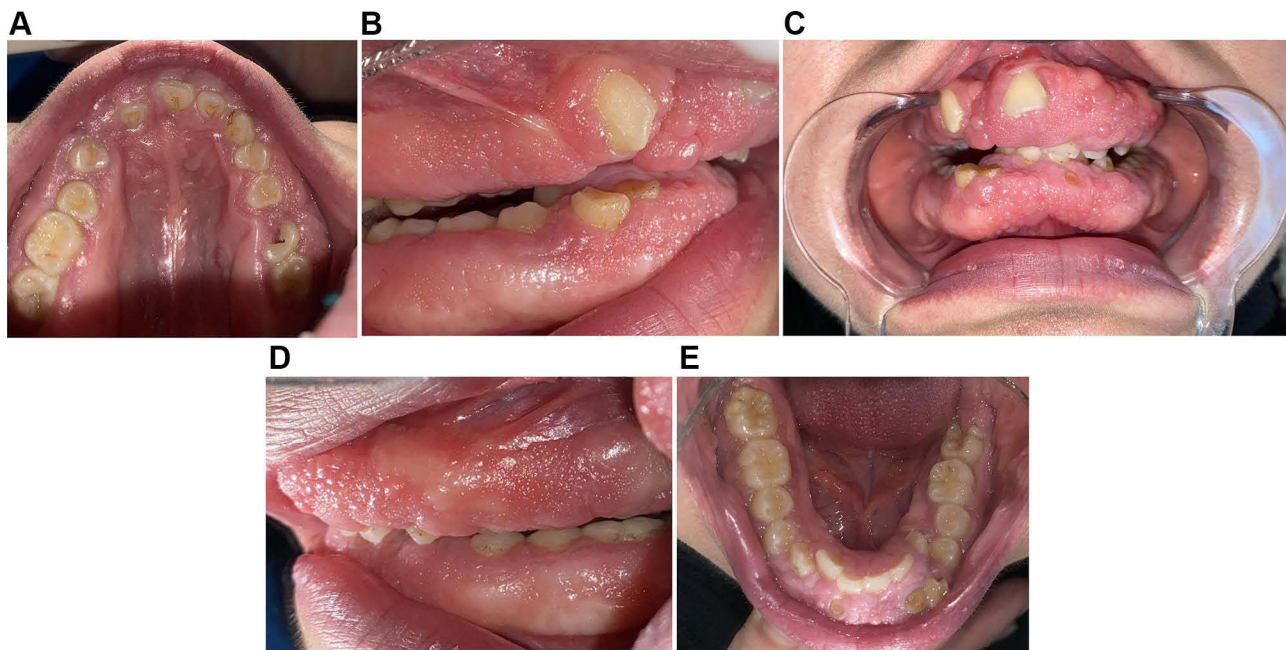


Figure 9 Intraoral views (A-E) reveal severe gingival enlargement, excessive stippling, crowding in the lower front teeth, teeth malposition, and retained primary teeth in front of the permanent mandibular teeth. These issues have significantly compromised function and aesthetics.

technique used for the patient was similar to the patient described in the above case with the addition of deciduous teeth extraction and removal of subgingival calculus which was exposed after flap elevation during surgery (Figure 10).

Follow Up and Outcome

The six month follow up of the patient shows significant improvements both in esthetics and function.

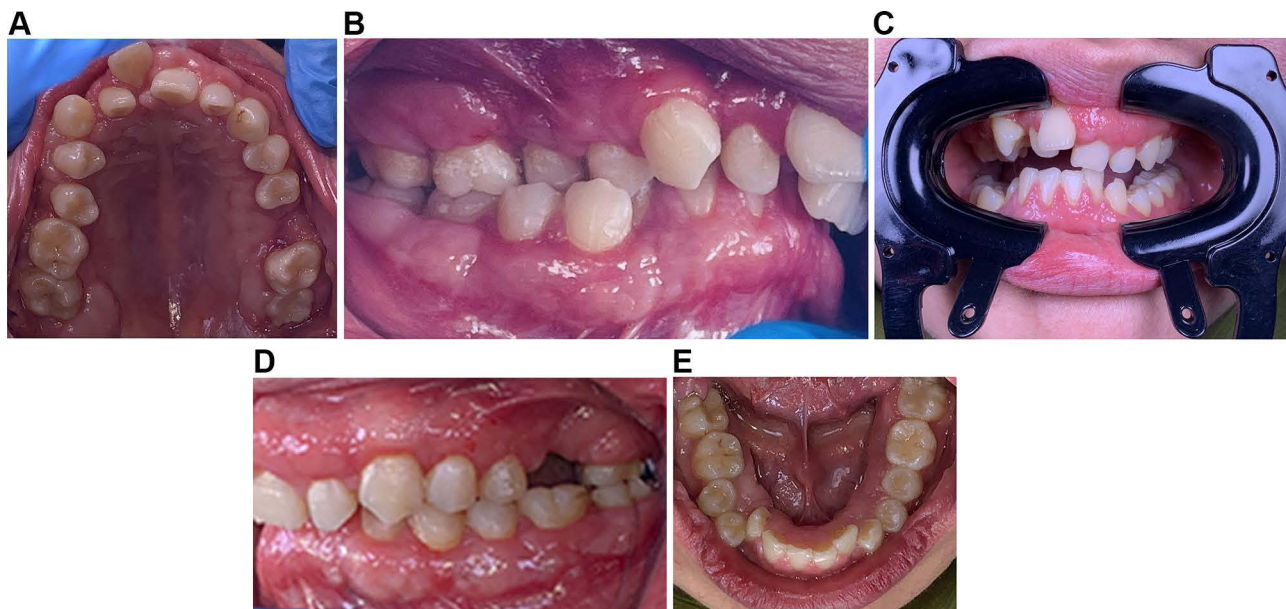


Figure 10 Intraoral views (A-E) of the patient six months after surgery show a significant decrease in gingival overgrowth. The gingival texture, contour, and color have markedly improved. While function and aesthetics related to the gingiva have improved, the misalignment of the teeth still requires orthodontic treatment.

Case 3

A 17-year-old male patient presented to the Department of Periodontics at Dentistry Teaching Hospital with the chief complaint of generalized gingival enlargement and difficulty in chewing. The patient's family history assessment revealed the presence of gingival overgrowth in the patient's sisters and elder brother. The patient did not report any systemic illness.

Clinical Findings

During the extra-oral examination, facial protrusion in the lower third part of the face was detected. Intra-oral examination revealed gingival overgrowth in both the mandible and maxilla on the buccal and lingual sides. The gingiva appeared pink in color, firm and dense in consistency, and exhibited a bead-like feature in all interdental papillae in the buccal side of the maxilla and mandible (Figure 11). Based on the family history and clinical examination, we reached a diagnosis of hereditary gingival fibromatosis (HGF).

Therapeutic Intervention

The patient was given instructions on good oral hygiene, with a focus on using mouthwash, brushing, and flossing. Local anesthetic was used to execute the surgical procedures, and gingivectomy with gingivoplasty was performed using blade No. 15 after split-thickness flap elevation and removal of excessive connective tissue. Diamond burs with spherical, fine-grained tips were used for bone recontouring.

Follow Up and Outcome

We have been visiting the patient regularly and postoperative evaluations show improvement in function and esthetics.

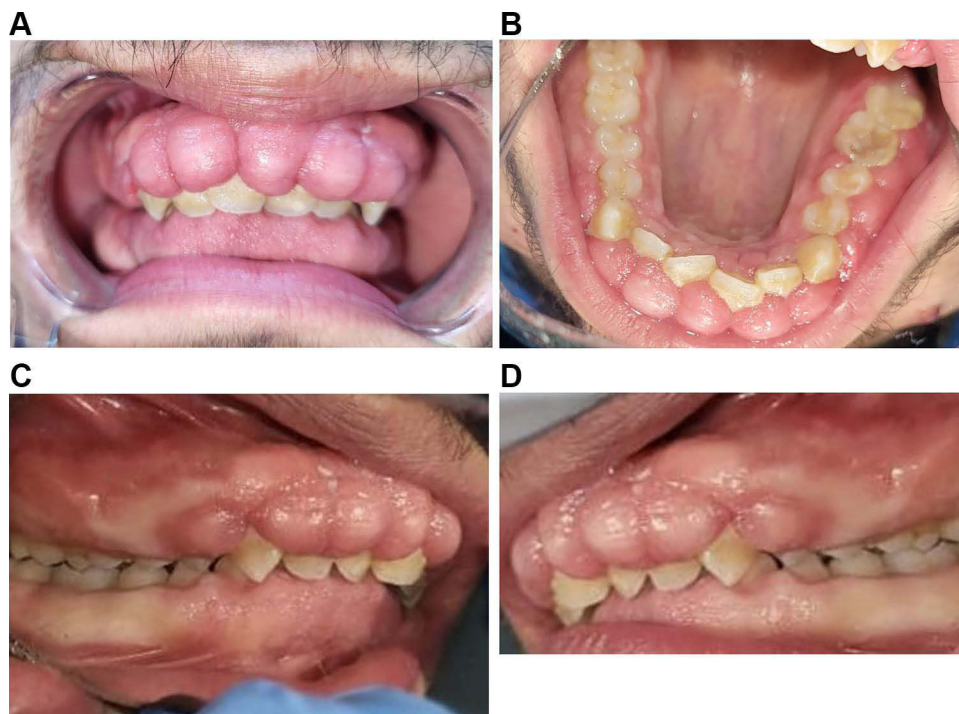


Figure 11 Intraoral views (A-D) show generalized bead-like features of the interdental papillae on the buccal side of both the maxilla and mandible, which have drastically compromised aesthetics, function, and oral hygiene.

Discussion and Conclusions

Large masses of solid, dense, robust, insensitive fibrous tissue covering the alveolar ridges¹⁷ and spreading over the teeth, resulting in vast pseudopockets, are the hallmark of hereditary gingival fibromatosis, a rare gingival disorder. It usually appears while the permanent incisors are just beginning to erupt.¹⁸ Extracellular matrix (ECM) and fibroblasts have been shown to accumulate excessively in presence of HGF, which may cause disruptions in collagen turnover or alterations in fibroblast proliferation, ultimately culminating in gingival hyperplasia. According to recent research, the genesis of HGF may be significantly influenced by a mutation in the SOS-1 (son of sevenless homolog 1) gene. The gingiva is one of the many tissues and cells that contain SOS-1. It has been detected in the arteries and fibroblasts of the gingival connective tissue, as well as in the basal and spinosum layers of the gingival epithelium.¹⁹

HGF may show up as a single illness or as a component of a syndrome,¹⁶ connected to additional clinical signs including mental retardation, hypertrichosis, epilepsy,²⁰ hearing loss,²¹ growth retardation,²² and anomalies of the extremities.²³ In all three present cases, the patients did not report any systemic disease or use of medication. The current patients are related to each other by blood, and while the patient's family history was important, it was not thought to be the only diagnostic factor for hereditary gingival fibromatosis. To reach a conclusive diagnosis, pathological testing in conjunction with radiographic analysis and sufficient clinical evaluation are necessary.³ For Case 1, the diagnosis was based on histopathological findings, clinical observations, and family history. For Cases 2 and 3, the diagnosis was based on clinical observations and family history. As seen in our cases, the enlarged gingiva may have nodules and stipples and appear typical in color and consistency.²⁴

Severe cases of hereditary gingival fibromatosis (HGF) often lead to crowding of underlying teeth, disturbances in phonation, and mastication disorders, which are consistent with our case as well.²⁵

Gingival enlargement can arise from various causes, making it important to distinguish between hereditary gingival fibromatosis and other types of gingival enlargement, including inflammatory gingival enlargement, drug-induced gingival enlargement, hormonal or nutritional factors-induced gingival enlargement, pyogenic granuloma, neoplastic gingival enlargement, and enlargement associated with systemic diseases. Developing a suitable treatment plan for each type requires determining the particular etiological cause.²⁶

Examining the patient's medication history, evaluating the site and clinical presentation, and keeping in mind that drug-induced gingival overgrowth (DIGO) is usually more noticeable in the maxillary and mandibular anterior regions are all necessary steps in differentiating between hereditary gingival fibromatosis (HGF) and DIGO. However, histological testing is necessary to differentiate HGF from hereditary illnesses linked to gingival enlargement; additional cellular, molecular, and genetic investigations are required for a thorough diagnosis.²⁷

It is possible to distinguish between inflammatory gingival enlargement and hereditary gingival fibromatosis (HGF) by looking for dental biofilm and local irritants. It is possible to differentiate gingival enlargement caused by hormonal changes by looking at the patient's age and pregnancy status. Seeing a gastroenterologist may be helpful for gingival hypertrophy related to Crohn's disease. Histopathological analysis can be used to distinguish between neoplastic gingival hypertrophy.¹⁶

The degree of gingival overgrowth frequently determines how hereditary gingival fibromatosis (HGF) is treated. There are various treatment options available, such as electrosurgery, carbon dioxide lasers, and conventional surgical techniques.¹⁶

Traditionally, surgical treatments such as external bevel gingivectomy²⁸ and gingivoplasty²⁹ are commonly used. With these methods, the excessive gingival tissue is cut away or reshaped using a scalpel. Other efficient methods for removing the swollen tissue include laser surgery and electrosurgery. Benefits of these techniques include decreased bleeding, less discomfort during surgery, and better restoration of the natural gingival contours and appearance.^{12,30}

In a research, external bevel gingivectomy was performed on the labial/buccal gingiva of the maxillary and mandibular arches, while a diode laser was utilized to remove excess tissue from the lingual/palatal sides. The use of the laser technique in this study resulted in reduced bleeding, minimized pain during and after the procedure, and a significant decrease in the amount of local anesthetic required. Additionally, the laser improved visibility, shortened chairside time, reduced operator fatigue, and enhanced patient acceptance.³¹

It is important to note that regardless of the surgical technique employed—whether traditional scalpel methods, electrosurgery, or laser techniques—long-term postoperative monitoring is crucial due to the high recurrence rate of HGF.¹²

We opted for scalpel surgery instead of using a laser due to the inaccessibility of laser equipment and the patient's financial constraints. When a carbon dioxide laser is unavailable, the traditional method, which involves using a No. 15 blade during surgery, is the most recommended approach. The surgical procedure is typically performed quadrant by quadrant. For postoperative care, a 0.2% chlorhexidine mouthwash is used for a duration of two weeks. The Following is the sequence of treatment:

Gingivectomy: A submarginal, internal bevel incision is made to expose the anatomical crowns of the teeth.

Split-thickness flap elevation: This is done to attenuate the attached gingiva and remove excessive connective tissue, ensuring better flap adaptation.

Osteoplasty and osteotomy: Recontouring of the buccal bone and removal of osseous ledge and exostosis are performed to address any bone irregularities.

Marginal bone recontouring: The margin of the alveolar buccal bone is placed 3mm apically to the cemento-enamel junction (CEJ) to reduce the chance of recurrence.

Following surgery, Hereditary Gingival Fibromatosis (HGF) frequently returns, with an approximate 35% total recurrence rate.²⁸ A number of variables, including age, the type of surgery performed, the location of the hyperplasia, and genetics, can affect the likelihood of recurrence.³² Regular follow-up for these instances is advised since maintaining good dental hygiene and regular periodontal care is critical to minimizing periodontal involvement and reducing the risk of recurrence.³³ Although these lesions often recur after surgery, the timing can vary widely, from a few months to several years. In a research, patients with good dental hygiene did not experience a recurrence of hereditary gingival fibromatosis for 14 years, whereas poor plaque control led to a minor recurrence 20 months after surgery.³⁴ Additionally, children are more likely than adults to experience recurrence.¹⁷ Considering the recurrent nature of hereditary gingival fibromatosis (HGF), long-term follow-up of patients is necessary.

After the surgical treatment of patients with hereditary gingival fibromatosis (HGF), we observed notable improvements in functional, aesthetic, and psychological aspects for the patients. These procedures led to enhanced oral function, better aesthetic outcomes, and increased patient satisfaction. During follow-up consultations, patients demonstrated a significant positive shift in attitude, appearing notably more upbeat and content with their results.

Future research should focus on evaluating the long-term effectiveness and recurrence rates of various surgical techniques for hereditary gingival fibromatosis (HGF). Comparative studies are needed to assess the outcomes of traditional versus advanced treatment modalities, such as lasers and electrosurgery.

Consent to Publication

In cases 1 and 2, the patients themselves consented to the publication, while in case 3, The father of the patient grants permission for the Dove Press Journal and Article to publish any personally identifying information, such as photograph(s), case history, and/or textual data (referred to as “Case Series”).

The Dentistry Teaching Hospital management board grants consent for the publication of identifiable patient details, including photographs, case history, and other relevant information, within the text.

Patient Perspective

Three of us are feeling really great about the results of our treatment. Our smiles are better, and chewing feels easier now. We are so thankful for our doctor's hard work and dedication to helping us feel better.

Funding

This case series did not receive any dedicated funding from public, commercial, or nonprofit entities.

Disclosure

The authors report no conflicts of interest in this work.

References

- Kather J, Salgado MA, Salgado UF, Cortelli JR, Pallos D. Clinical and histomorphometric characteristics of three different families with hereditary gingival fibromatosis. *Oral Surg, Oral Med Oral Pathol Oral Radiol Endod.* 2008;105(3):348–352. PMID: 18061489.doi:10.1016/j.tripleo.2007.06.006
- Kelekis-Cholakias A, Wiltshire WA, Birek C. Treatment and long-term follow-up of a patient with hereditary gingival fibromatosis: a case report. *J Can Dent Assoc.* 2002;68(5):290–294. PMID: 12019039.
- Almiñana-Pastor PJ, Buitrago-Vera PJ, Alpiste-Illueca FM, Catalá-Pizarro M. Hereditary gingival fibromatosis: characteristics and treatment approach. *J Clin Exp Dent.* 2017;9(4):e599–e602. PMID: 28469831; PMCID: PMC5410686.doi:10.4317/jced.53644
- Resende EP, Xavier MT, Matos S, Antunes AC, Silva HC. Nonsyndromic hereditary gingival fibromatosis: characterization of a family and review of genetic etiology. *Spec Care Dentist.* 2020;40(3):320–328. PMID: 32413193.doi:10.1111/scd.12458
- Fakir E, Roberts T, Stephen L, Beighton P. Klippel-trenaunay-weber syndrome: orodental manifestations and management considerations. *Oral Surg, Oral Med Oral Pathol Oral Radiol Endod.* 2009;107(6):754–758. PMID: 19464652.doi:10.1016/j.tripleo.2009.01.037
- Bayram Y, White JJ, Elcioglu N, et al. REST final-exon-truncating mutations cause hereditary gingival fibromatosis. *Am J Hum Genet.* 2017;101(1):149–156. PMID: 28686854; PMCID: PMC5501868. doi:10.1016/j.ajhg.2017.06.006
- Michaud PL, Patel A. Hereditary gingival fibromatosis with extreme ridge thickness and insufficient interarch distance: a clinical report of surgical and prosthetic management. *J Prosthet Dent.* 2016;116(1):15–20. PMID: 26873770.doi:10.1016/j.prosdent.2016.01.001
- Araujo CS, Graner E, Almeida OP, Sauk JJ, Coletta RD. Histomorphometric characteristics and expression of epidermal growth factor and its receptor by epithelial cells of normal gingiva and hereditary gingival fibromatosis. *J Periodontol Res.* 2003;38(3):237–241. PMID: 12753359. doi:10.1034/j.1600-0765.2003.00013.x
- Lobão DS, Silva LC, Soares RV, Cruz RA. Idiopathic gingival fibromatosis: a case report. *Quintessence Int.* 2007;38(8):699–704. PMID: 17823689.
- Shi J, Lin W, Li X, Zhang F, Hong X. Hereditary gingival fibromatosis: a three-generation case and pathogenic mechanism research on progress of the disease. *J Periodontol.* 2011;82(7):1089–1095. PMID: 21142979.doi:10.1902/jop.2010.100599
- Afonso RA, Godinho GV, Silva CA, Silva EJ, Volpato LE. Hereditary gingival fibromatosis and developmental anomalies: a case report. *Cureus.* 2022;14(4):e24219. PMID: 35602830; PMCID: PMC9117822.doi:10.7759/cureus.24219
- Aboujaoude S, Aoun G. Hereditary gingival fibromatosis: a report of a severe case. *Cureus.* 2022;14(3):e23280. PMID: 35449614; PMCID: PMC9013409.doi:10.7759/cureus.23280
- Chaurasia A. Hereditary gingival fibromatosis. *Natl J Maxillofac Surg.* 2014;5(1):42–46. PMID: 25298717; PMCID: PMC4178355.doi:10.4103/0975-5950.140171
- Doufexi A, Mina M, Ioannidou E. Gingival overgrowth in children: epidemiology, pathogenesis, and complications. A literature review. *J Periodontol.* 2005;76(1):3–10. PMID: 15830631.doi:10.1902/jop.2005.76.1.3
- Häkkinen L, Csiszar A. Hereditary gingival fibromatosis: characteristics and novel putative pathogenic mechanisms. *J Dent Res.* 2007;86(1):25–34. PMID: 17189459.doi:10.1177/154405910708600104
- Gawron K, Lazarz-Bartyzel K, Potempa J, Chomyszyn-Gajewska M. Gingival fibromatosis: clinical, molecular and therapeutic issues. *Orphanet J Rare Dis.* 2016;11(1):9. PMID: 26818898; PMCID: PMC4729029.doi:10.1186/s13023-016-0395-1
- Coletta RD, Graner E. Hereditary gingival fibromatosis: a systematic review. *J Periodontol.* 2006;77(5):753–764. PMID: 16671866.doi:10.1902/jop.2006.050379
- Ramakrishnan T, Kaur M. Multispeciality approach in the management of patient with hereditary gingival fibromatosis: 1-year followup: a case report. *Int J Dent.* 2010;2010:575979. PMID: 21234408; PMCID: PMC3014701.doi:10.1155/2010/575979
- Şahin S, Saygun NI. Hereditary Gingival Fibromatosis. *J Gazi Univ Fac Dent.* 2008;25(2):45–50.
- Anavi Y, Lerman P, Mintz S, Kiviti S. Idiopathic familial gingival fibromatosis associated with mental retardation, epilepsy and hypertrichosis. *Dev Med Child Neurol.* 1989;31(4):538–542. PMID: 2806737.doi:10.1111/j.1469-8749.1989.tb04033.x
- Hartsfield JK Jr, Bixler D, Hazen RH, Opitz JM, Reynolds JF. Gingival fibromatosis with sensorineural hearing loss: an autosomal dominant trait. *Am J Med Genet.* 1985;22(3):623–627. PMID: 4061496.doi:10.1002/ajmg.1320220323
- Bhowmick NA, Ghiassi M, Bakin A, et al. Transforming growth factor-beta1 mediates epithelial to mesenchymal transdifferentiation through a RhoA-dependent mechanism. *Mol Biol Cell.* 2001;12(1):27–36. PMID: 11160820; PMCID: PMC30565.doi:10.1091/mbc.12.1.27
- Nevin NC, Burrows D, Allen G, Kernohan DC. Aglossia-adaactylia syndrome. *J Med Genet.* 1975;12(1):89–93. PMID: 1121025; PMCID: PMC1013236.doi:10.1136/jmg.12.1.89
- He L, Ping FY. Gingival fibromatosis with multiple unusual findings: report of a rare case. *Int J Oral Sci.* 2012;4(4):221–225. PMID: 22955199; PMCID: PMC3633067.doi:10.1038/ijos.2012.53
- Gandhi M, Tandon S, Sharma M, Vijay A. Nonsyndromic gingival fibromatosis: a rare case report. *Int J Clin Pediatr Dent.* 2018;11(3):250–253. PMID: 30131651; PMCID: PMC6102439.doi:10.5005/jp-journals-10005-1521
- Morocho-Monteros D, Parise-Vasco JM, Cisneros-Boada D, Manzano-Flores S. Hereditary gingival fibromatosis: a case report. *J Oral Res.* 2021;10(3):1–6. doi:10.17126/joralres.2021.028
- Agrawal AA. Gingival enlargements: differential diagnosis and review of literature. *World J Clin Cases.* 2015;3(9):779–788. PMID: 26380825; PMCID: PMC4568527.doi:10.12998/wjcc.v3.i9.779
- Boutiou E, Ziogas IA, Giannis D, Doufexi AE. Hereditary gingival fibromatosis in children: a systematic review of the literature. *Clin Oral Investig.* 2021;25(6):3599–3607. PMID: 33188467.doi:10.1007/s00784-020-03682-x
- Huang X, Zhu W, Zhang X, Fu Y. Modified gingivoplasty for hereditary gingival fibromatosis: two case reports. *BMC Oral Health.* 2022;22(1):523. PMID: 36424563; PMCID: PMC9694548.doi:10.1186/s12903-022-02411-y
- Camilotti RS, Jasper J, Ferreira TB, Antonini F, Poli VD, Pagnoncelli RM. Resection of gingival fibromatosis with high-power laser. *J Dent Child.* 2015;82(1):47–52. PMID: 25909843.
- Devi PK, Kumar GP, Bai YD, Ammaji AD. Ipsilateral idiopathic gingival enlargement and its management using conventional gingivectomy and diode laser: a recurrent case after 15 years. *J Indian Soc Periodontol.* 2013;17(3):387–390. PMID: 24049343; PMCID: PMC3768193.doi:10.4103/0972-124X.115649

32. Gawron K, Łazarz-bartyzel K, Kowalska A, et al. Fibroblasts from recurrent fibrotic overgrowths reveal high rate of proliferation in vitro - findings from the study of hereditary and idiopathic gingival fibromatosis. *Connect Tissue Res.* 2019;60(1):29–39. PMID: 30231645.doi:10.1080/03008207.2018.1517758
33. Günhan O, Gardner DG, Bostanci H, Günhan M. Familial gingival fibromatosis with unusual histologic findings. *J Periodontol.* 1995;66(11):1008–1011. PMID: 8558390.doi:10.1902/jop.1995.66.11.1008
34. Baptista IP. Hereditary gingival fibromatosis: a case report. *J Clin Periodontol.* 2002;29(9):871–874. PMID: 12423302.doi:10.1034/j.1600-051x.2002.290913.x

Clinical, Cosmetic and Investigational Dentistry

Dovepress

Publish your work in this journal

Clinical, Cosmetic and Investigational Dentistry is an international, peer-reviewed, open access, online journal focusing on the latest clinical and experimental research in dentistry with specific emphasis on cosmetic interventions. Innovative developments in dental materials, techniques and devices that improve outcomes and patient satisfaction and preference will be highlighted. The manuscript management system is completely online and includes a very quick and fair peer-review system, which is all easy to use. Visit <http://www.dovepress.com/testimonials.php> to read real quotes from published authors.

Submit your manuscript here: <https://www.dovepress.com/clinical-cosmetic-and-investigational-dentistry-journal>