

Timing and Efficacy Evaluation of 755-nm Long Pulse Alexandrite Laser and 2% Carteolol Hydrochloride Eye Drops Co-Treatment for Thicker Superficial Infantile Hemangioma

WeiKang Shi¹, Lu Jin², AiHua Xu², Yu Gao³, Na Zhang⁴

¹Department of Dermatology, Jinhua Maternal and Child Health Care Hospital, Jinhua, Zhejiang Province, People's Republic of China; ²Department of Nursing, Jinhua Central Hospital, Jinhua, Zhejiang Province, People's Republic of China; ³Department of Dermatology, The Second Affiliated Hospital and Yuying Children's Hospital of Wenzhou Medical University, Wenzhou, Zhejiang Province, People's Republic of China; ⁴Department of Dermatology, Jinhua Central Hospital, Jinhua, Zhejiang Province, People's Republic of China

Correspondence: Na Zhang; Yu Gao, Email sallyzhang1986@163.com; gaoyu0570@163.com

Purpose: Superficial infantile hemangioma (SIH) is the most common type of IH. Some studies have shown the efficacy of 755-nm long pulse alexandrite laser (LPAL) and topical 2% carteolol hydrochloride (C-HCL) eye drops for the treatment of SIH. This article retrospectively analyzes the safety and efficacy of 755-nm LPAL combined with 2% C-HCL eye drops for treating thicker SIH, and explores the optimal treatment time for SIH.

Materials and Methods: This study included 2–5 mm thick SIH patients who received co-treatment of 755-nm LPAL and 2% C-HCL eye drops. The SIH patients were divided into 3 groups based on their age and IH growth curve: ≤ 1 month ($\leq 1M$), 1–3 months (excluding 1 month; 1–3M), and 3–12 months (excluding 3 months; 3–12M).

Results: There was no difference in efficacy between the $\leq 1M$ and the 1–3M group, and were both better than the 3–12M group. Furthermore, there was no difference in the average number of treatments between the $\leq 1M$ and 1–3M groups and were both less than the 3–12M group. There was no significant difference in the incidence of adverse reactions between the groups. Compared with the $\leq 1M$ and 1–3M groups, the 3–12M group indicated more permanent skin lesions after the treatment.

Conclusion: It was revealed that co-treatment with 755-nm LPAL and 2% C-HCL eye drops is safe and effective against thicker SIH. Compared with the 3–12M group, ≤ 3 months can achieve better efficacy, requires a shorter treatment time, less likely to leave permanent skin lesions such as scars. Moreover, patients with no proliferation can be observed to 1 month.

Keywords: infantile hemangioma, 755-nm long pulse alexandrite laser, 2% carteolol hydrochloride eye drops, treatment timing, efficacy

Introduction

Infantile hemangioma (IH) is one of the most common benign tumors in infants and has an incidence rate of about 4–5%.^{1–3} The underlying mechanism of IH has not been elucidated and its growth pattern is unique. The precursor lesions of IH can be present at birth or arise in the early life of newborns. These lesions are often mistaken for birth trauma, especially the early infant hemangioma of the lower limbs, which can be clinically confused with bright red nevus.⁴ After an incubation period of 1–3 weeks, IH starts proliferating.⁵ Furthermore, IH have similar growth curves, in the first 3 months, especially during 5–8 weeks,⁶ the proliferation of IH is rapid and at the end of this period, IH growth reaches about 80% of the final volume.⁷ The IH can grow for 9–12 months and in rare cases up to 24 months. Then, after a brief stabilization period, IH spontaneously resolves and most cases are resolved completely by the age of 4.⁸

Based on the depth, IH is of three types: superficial IH (SIH), subcutaneous IH, and mixed IH. Of these, SIH is the most common type of IH (50–60% of IH), which mainly involves the papillary layer of the dermis. It is characterized by

tense and glossy red papules, nodules, or plaques. Subcutaneous IH is presented as a blue subcutaneous mass and involves the dermal reticular layer as well as the subcutaneous tissues. Mixed IH indicates the characteristic of both other types due to the simultaneous involvement of superficial dermis and subcutaneous tissue.⁹ Although the depth of involvement varies, all IH have the same growth pattern, early rapid proliferation followed by spontaneous regression.⁷ Furthermore, since most IH resolves spontaneously, some scholars believe that a “wait-and-see” strategy can be adopted except for cases with serious complications and a risk of anatomical function.¹⁰ However, this is controversial because although most of the IH can naturally fade, the fade does not represent the disappearance. In natural fade, it is highly likely to leave local skin damage.¹¹ Furthermore, the face and neck are the parts of IH that account for 60% of the total IH cases¹² and such a high proportion of skin damage can severely affect beauty, which increases anxiety, social burden, guilt, sadness, worry, low self-esteem, and bullying by peers.⁹ Cinkara G found that the severity of residual skin lesions after IH regression was related to the final size of the hemangioma and the involvement of subcutaneous structures.¹³ Therefore, it was hypothesized that before IH grows too large and thick, its treatment may reduce the incidence of skin damage and improve the physical and social problems of parents and children.

In recent years, with increasing research, the treatment strategies for IH have also improved, including oral drugs, topical drugs, physical therapy, surgical treatment, injection therapy, which alleviates IH and promotes its regression. With the development of selective photothermal decomposition theory, laser treatment has been employed for vascular skin lesions, including IH.¹⁴ The 595-nm pulse dye laser (PDL) is the first laser instrument used in the treatment of vascular lesions. Many clinical trials have confirmed that PDL is safe and effective for treating SIH.¹⁵ However, PDL has a shorter wavelength and a shallow skin penetration range (1–1.2 mm).¹⁶ It has limited action for thicker IH. Whereas 1064-nm Nd: YAG laser can penetrate 5–6 mm deep, therefore, it is more suitable for mixed or deep sexual IH. However, its therapeutic window is narrow^{17,18} and the penetration depth is large, a little higher energy can damage the scar left in the dermis.^{19,20} For IH \leq 5 mm, 1064-nm Nd: YAG laser may cause unnecessary damage. The penetration depth of a 755-nm long pulse alexandrite laser (LPAL) is 1.5–1.75 times that of PDL. Several studies have demonstrated its safety and efficacy in the treatment of thicker IH.^{21,22} C-HCL are a topical non-selective β receptor blocker with prolonged blocking time and unique intrinsic sympathetic activity. Moreover, compared to Timolol, C-HCL does not easily cause significant adverse reactions such as heart rate drop or dyspnea and is therefore, safe for use in children. Topical 2% C-HCL eye drops also show good safety and efficacy in SIH.²³ Furthermore, it has been found that laser therapy increases the efficacy of topical drugs.²⁴ Currently, there is no clinical data on the combined use of 755-nm LPAL and C-HCL eye drops for treating thicker IH and no consensus on the laser treatment timing for IH. This article retrospectively analyzed the cases of thicker (2–5 mm) IH (SIH) co-treated with 755nm LPAL and topical 2% C-HCL eye drops to assess the safety, effectiveness, and optimized timing of this treatment strategy.

Materials and Methods

Patients

This study follows the Declaration of Helsinki and was approved by the independent ethics committee of the Second Affiliated Hospital and Yuying Children’s Hospital of Wenzhou Medical University. The SIH patients who were treated at our hospital from July 1, 2019, to July 1, 2022, were selected for this study and written informed consent was acquired from their legal guardians. Meanwhile the legal guardians of the patients provided informed consent for any images to be published. Based on the growth curve of age and IH, the patients were categorized into 3 groups, \leq 1 month (\leq 1M), 1–3 months (excluding 1 month; 1–3M), and 3–12 months (excluding 3 months; 3–12M).

Inclusion and Exclusion Criteria

Inclusion criteria: (1) Selection was based on the Chinese Guidelines for the Diagnosis and Treatment of Hemangioma and vascular malformation (2019 edition); (2) Patient with B-ultrasound data indicating the distance of 2 and 5 mm between the thickest part of IH and the epidermis; (3) Patient who came for consultation for the first time and were not treated before; (4) Patients without systemic disease such as heart disease before treatment; (5) Patients who could consult regularly; and (6) Patients who could be followed up for half a year after treatment. Exclusion criteria: (1) Patients with high-risk IH at the corners of the eyes, eyelids, and perineum, and IH on the

scalp; (2) Those who cannot seek medical treatment regularly; (3) Those who have received treatment in other hospitals; and (4) Those with abnormal electrocardiograms or systemic diseases such as asthma.

Treatment Methods

The LPAL device (Candela Laser Company, USA) with 755 nm wavelength, 3 ms pulse width, 45–55 J/cm² energy density, 8 mm spot diameter, and a dynamic cooling device (DCD) synchronous dynamic cooling system with a 20 ms spray period and 20 ms interval was employed. Before the treatment, the local skin lesion was photographed, and a B ultrasound was examined to record the changes in blood flow signal. The patients were informed about the precautions of the laser treatment and the possible adverse reactions and their signed informed consent forms were acquired. Furthermore, parameters were selected according to the lesion area, color, and thickness, and then adjusted to the immediate response. The vertical irradiation mode that turns the skin damage gray or dark purple is appropriate. Children's eyes should be protected during the treatment. After the treatment, the treated area was left for 20 minutes cooling and externally treated with fusidic acid cream (Hong Kong Bright Future, National Medicine Standard HC20150044) for about a week to prevent infection. The interval of laser treatment was 4 weeks, and the treatment time was determined according to the condition. Furthermore, 2% C-HCL eye drops (China Otsuka Pharmaceutical Co., Ltd., National Medicine Standard H10970025) of appropriate amount were added to the cotton (30–40 μL/cm²) and then applied to the dry IH surface, 3 times a day for 30 minutes each time. The cotton was kept moist and if the cotton dries, eye drops should be immediately added. Moreover, topical plastic film can be used to slow down the drug volatilization. The patient's family was asked to observe local skin changes after medication and keep a simple blood oxygen saturation detector at home. In addition, the patient's family was advised that if the heart rate reduces significantly after the medication, stop using the medications and avoid drug application on the eye or the reproductive tract. Treatment was stopped when the hemangioma disappeared completely or substantially or after 6 months of treatment.

Follow-Up and Adverse Reaction Records

Before each treatment, the patient's family was asked to record the adverse reactions after the last treatment and immediate side effects after treatment. A follow-up call was made 1, 3, and 6 months after the last treatment to inquire about the occurrence of adverse reactions, including local skin redness, swelling, blisters, scaling, erosion, ulcers, etc, as well as to inquire about IH recurrence after the treatment, incidence of any local residual scars, or other systemic adverse reactions such as hypotension, hypoglycemia, and decreased heart rate.

Efficacy Evaluation

After the last treatment, two independent double-blind dermatologists evaluated the overall regression effect of the hemangioma using Achauer's percentile quartile method and B-ultrasound. The clinical grades were: Grade IV (healed): the abnormal blood flow observed by the Color Doppler ultrasound examination basically disappeared, and the tumor volume reduced by > 75%, Grade III (marked effect): Color Doppler ultrasound shows that most abnormal blood flow signals disappeared and the tumor volume shrunk by 51% to 75%. Grade II (effective): Color Doppler ultrasound examination shows that the abnormal blood flow signal partially disappeared and the tumor volume reduced by 25 to 50%; Grade I (invalid): Color Doppler ultrasound examination showed significant blood flow signals and reduced tumor volume by < 25% (Figure 1) The efficacy rate was calculated as the total sum of cured cases and markedly effective cases divided by the total number of cases × 100%.

Statistical Methods

SPSS 26.0 was used for statistical analysis, and variance analysis to analyze efficacy, number of treatments, and incidence of adverse reactions. A *p*-value of < 0.05 was considered statistically significant.

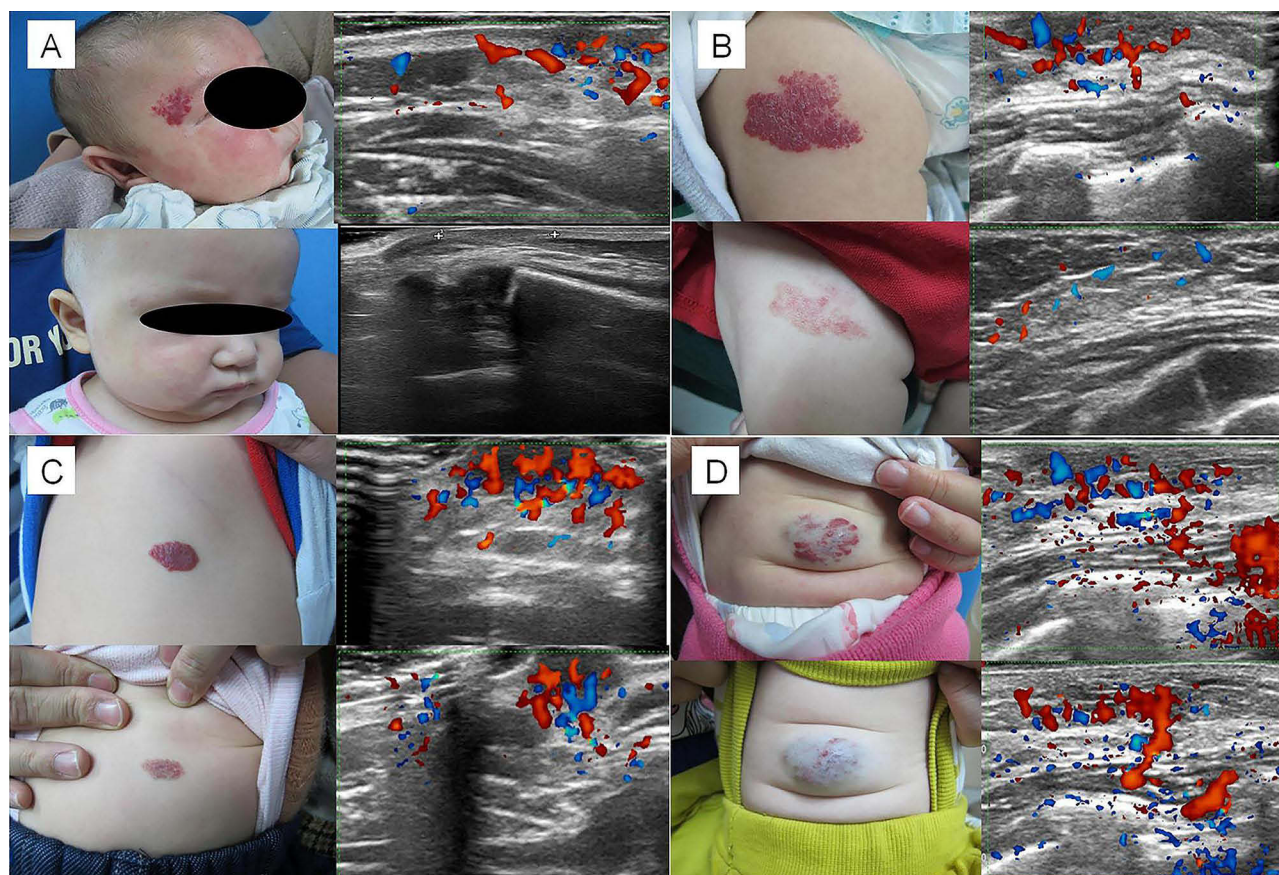


Figure 1 Images of before and after treatment and evaluation of efficacy. **(A)** Grade IV (healed): the abnormal blood flow observed by the Color Doppler ultrasound examination basically disappeared, and the tumor volume reduced by > 75%; **(B)** Grade III (marked effect): Color Doppler ultrasound shows that most abnormal blood flow signals disappeared and the tumor volume shrunk by 51% to 75%; **(C)** Grade II (effective): Color Doppler ultrasound examination shows that the abnormal blood flow signal partially disappeared and the tumor volume reduced by 25 to 50%; **(D)** Grade I (invalid): Color Doppler ultrasound examination showed significant blood flow signals and reduced tumor volume by < 25%.

Results

Clinical Characteristics

278 IH patients were included in this study, 122 (44.4%) males and 156 (55.6%) females (male to female ratio = 1:1.25). There were 30 patients (11.7%) in the $\leq 1\text{M}$ group (9 males and 21 females) with an average IH thickness of 3.47 ± 0.32 mm and an average first visit of 0.74 ± 0.06 months. The 1–3M group had 87 patients (31.3%) (38 males and 49 females). The average IH thickness was 3.90 ± 0.22 mm, and the average month of the first visit was 1.92 ± 0.13 months. Whereas, the 3–12M group had 161 patients (57.0%) (75 males and 86 females). The average thickness of IH was 4.49 ± 0.14 mm, and the average month of the first visit was 6.46 ± 0.38 months. Of 278 IH patients, 105 hemangiomas were located in the head, face, and neck, 96 were in the trunk, and 77 were in the limbs (Table 1). There was no statistical difference in patients' gender and the location of the hemangioma ($p > 0.05$), however, there was a difference in thickness between the different groups ($p < 0.001$). With the increase of age, the hemangioma gradually thickened.

Comparison of Efficacy

30 IH cases were included in the $\leq 1\text{M}$ group, including 2 cases of grade I, 1 of grade II, 5 of grade III, and 22 of grade IV, with an effective rate of 90.00%. The 1–3M group included 87 cases, including 4 cases of grade I, 8 of grade II, 14 of grade III, and 61 of grade IV, with an effective rate of 86.20%. The 3–12M group included 161 cases, including 15 cases of grade I, 20 of grade II, 45 of grade III, and 81 of grade IV, with an effective rate of 78.20%. A comparison of the therapeutic effects among the three groups showed a statistically significant difference ($p = 0.012$). The $\leq 1\text{M}$ group was

Table 1 Baseline Characteristics at Time of Inclusion

Clinical Characteristics	≤ 1M Group	1–3M Group	3–12M Group	P-Value
Sex				
Male	9	38	75	
Female	21	49	86	0.134
Location				
Head and face	11	30	64	
Trunk	11	34	51	
Limbs	8	23	46	0.931
Average thickness at first visit (mm)	3.47±0.32	3.90±0.22	4.49±0.14	<0.001
Average age at first visit (months)	0.74±0.06	1.92±0.13	6.46±0.38	<0.001

compared with the 1–3M group, $p = 0.802$, and the efficacy was not statistically significant. Furthermore, the ≤ 1M and 3–12M groups were compared ($p = 0.044$), and 1–3M and 3–12M groups were compared ($p = 0.009$), and the efficacy differences were statistically significant (Table 2). The efficacy of the ≤ 1M group was equivalent to that of the 1–3M group and both were better than that of the 3–12M group.

Comparison of Treatment Times

When the number of treatments required in each group was compared, the average number of treatments in the ≤ 1M, 1–3M, and 3–12M groups was 3.90 ± 0.54 , 4.00 ± 0.62 , and 4.84 ± 0.22 times, respectively, and the difference in the number of treatments among the three groups was statistically significant ($p < 0.001$). There was no statistically significant difference between the ≤ 1M group and the 1–3M group ($p = 0.244$). Furthermore, there was a statistically significant difference between the ≤ 1M and 3–12M groups ($p = 0.001$), as well as between the 1–3M and 3–12M groups ($p = 0.003$). (Table 3) The average number of treatments in the ≤ 1M and 1–3M groups were similar, and both were less than that in the 3–12M group.

Adverse Reactions

In the ≤ 1M group, there were 7 cases of blisters, 2 of skin pigment changes, 1 of desquamation, and no residual scars were observed. Furthermore, the adverse reaction rate was 33.33%. The 1–3M group had 22 cases of blisters, 5 of skin pigment changes, 2 of desquamation, and 1 of residual scars, with an adverse reaction rate was 34.48%. The 3–12M group had an adverse reaction rate of 34.20% with 22 cases of blisters, 17 skin pigment changes, 8 desquamation, and 8 residual scars (Table 4). No systemic adverse reactions such as cardiovascular, respiratory, and ocular were observed in the three groups. The blisters in the 3 groups were only temporary skin lesions. After 1 week of topical application of fusidic acid cream, the blisters disappeared without any concurrent infection. Moreover, most skin pigment changes and desquamation were recovered at about 2 months after the last treatment; however, 1 pigment change case in the 1–3M group did not recover at 6 months' follow-up, and 6 cases of residual pigment in the 3–12M group had not recovered at 6

Table 2 Comparison of Efficacy for Three Groups

Classify	Efficacy Rank				The Efficacy Rate	P-Value
	I	II	III	IV		
≤1M group	2	1	5	22	90.00%	0.012
1–3M group	4	8	14	61	86.20%	
3–12M group	15	20	45	81	78.20%	

Table 3 Comparison of Treatment Time for Three Groups

Number of Treatments	≤1M Group	1–3M Group	3–12M Group	P-Value
1	1	4	3	0.001
2	3	8	8	
3	12	16	29	
4	4	19	10	
5	2	10	32	
6	8	30	79	
The average number of treatments	3.90±0.54	4.00±0.62	4.84±0.22	

Table 4 Comparison of Adverse Reactions in Three Groups

Classify	Blister	Pigment Changes	Desquamation	Scar	Adverse Reaction Rate
≤1M group	7	2	1	0	33.33%
1–3M group	22	5	2	1	34.48%
3–12M group	22	17	8	8	34.20%
P-value	0.281				

months of follow-up, and the remaining skin scars did not recover during the follow-up (Figure 2). In addition, the incidence of adverse reactions among the three groups was compared ($p = 0.281$), and the difference was not statistically significant. Furthermore, based on the types of adverse reactions, there were 0 permanent and 10 cases of temporary

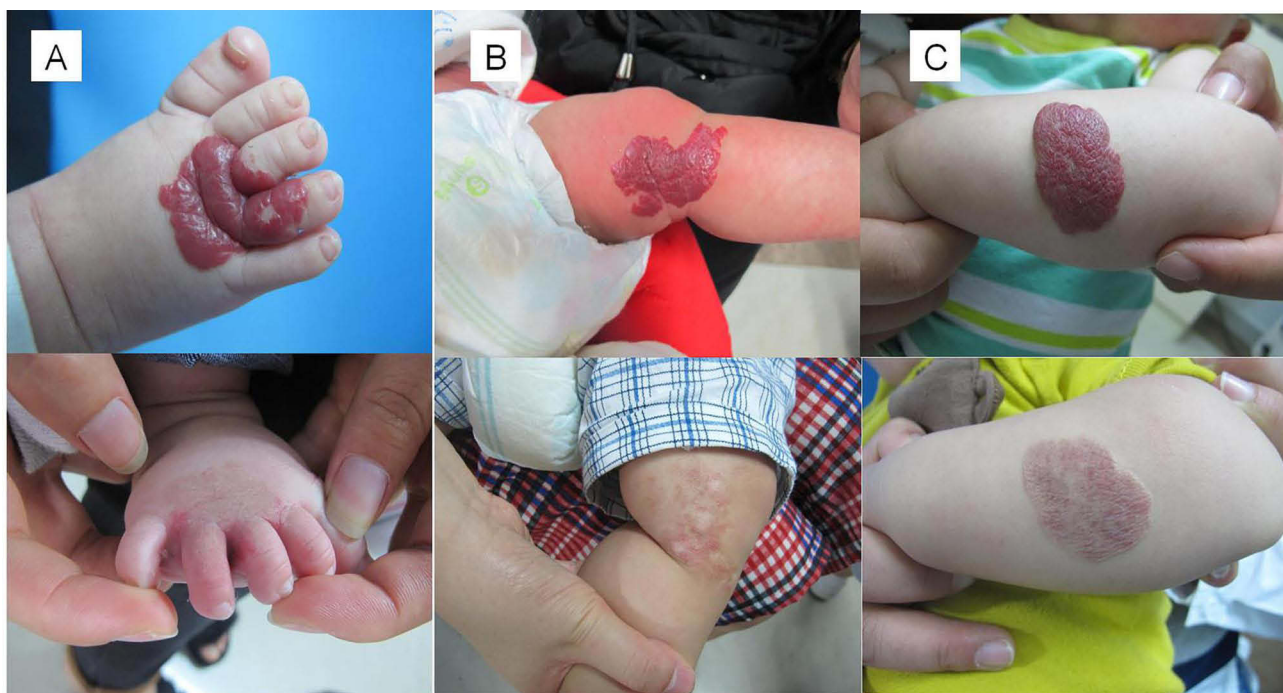

Figure 2 Images of adverse reaction before and after treatment. (A) ≤1M group, after 4 times of combination therapy, the efficacy reached grade IV with minimal hyperpigmentation and recovered at 2 months of follow-up. (B) 3–12M group, after 6 times of combination therapy, the efficacy reached grade IV with hypopigmentation and no recovery after 6 months of follow-up. (C) 3–12M group, after 6 times of combination treatment, the efficacy reached grade IV with residual scar and no recovery after 6 months of follow-up.

Table 5 Comparison of Adverse Reaction Types in Three Groups

Classify	Temporary Adverse Effects	Permanent Adverse Effects
≤1M group	10	0
1–3M group	28	2
3–12M group	41	14
P-value	0.027	

adverse reactions in the ≤ 1M group, while 2 patients with permanent adverse reactions in the 1–3M group and 28 patients had temporary adverse. In the 3–12M group, there were 14 permanent adverse reactions patients and 41 cases were temporarily adverse reactions (Table 5). The types of three group's adverse reactions were compared, $p = 0.027$. Comparison between ≤ 1M group and 1–3M groups ($p = 0.619$) indicated a non-statistically significant difference. Furthermore, there was a statistically significant difference between the ≤ 1M and 3–12M groups ($p = 0.046$), as well as between the 1–3M and 3–12M groups ($p = 0.02$). Compared with the ≤ 1M and 1–3M groups, the 3–12M group was more likely to have permanent skin lesions after treatment.

Follow-Up

For 6 times after the curative effect of grade I or II 50 patients, 12 patients chose to continue the treatment, after 8–9 treatments curative effect reached grade III, and the rest of the patients chose oral propranolol, with other laser treatment or B ultrasound sclerosis injection, skin lesions were effectively improved.

Discussion

Infant hemangioma is a benign tumor formed by vascular endothelial cell dysplasia and angiogenesis,²⁵ and SIH is the most dominant type of IH.²⁶ Currently, a “wait and see” approach is used for SIH treatment because most of them resolve spontaneously; however, this may result in permanent lesions.²⁷ Studies show that 70% of untreated SIH have posterior lesions, including telangiectasia, excessive fat accumulation, and tissue destruction scar,²⁵ especially facial lesions, which account for about 60% of cases.¹² Parents want to receive treatment at an early stage to prevent or reduce potential pathological and psychological complications, and the severity of residual lesions after spontaneous regression is related to the final size of the hemangiomas.²⁸ Therefore, some researchers have suggested that early treatment before IH grows in size is significant.²⁹ However, whether earlier treatment has better effects remains controversial.

Since 2008, when Leaute-Labreze found the beneficial effect of propranolol in IH treatment, β blockers became the preferred treatment, marking an end of glucocorticoids as the gold standard for IH treatment. Furthermore, various national guidelines recommended propranolol as the preferred drug for IH treatment.^{30,31} However, some researchers have indicated that the systemic absorption of oral propranolol can cause adverse reactions. The common side effects are sleep changes, acrocyanosis and cold limbs, gastrointestinal disorders, hypotension, hypoglycemia.³¹ Moreover, it has been indicated that oral propranolol can affect the development of the motor system.^{32,33} Oral propranolol is generally prescribed for 6 months, and the recurrence rate of IH after withdrawal is 10–15%,³⁴ therefore, for a single SIH oral propranolol may not be the best choice. Clinically, topical β receptor blockers are often used because compared with oral propranolol, it is more convenient to use and have a smaller systemic absorption dose.³⁵ The common clinically used medications include timolol eye drops, C-HCL eye drops. The exact timolol mechanism for hemangioma treatment is not clear and is believed to act by contracting blood vessels in the first 1–3 days of treatment. The medium-term effect is to block angiogenic factors, including vascular endothelial growth factors, basic fibroblast growth factors and the matrix metalloproteinase, which make hemangioma growth arrest. Moreover, the long-term effect is due to induced apoptosis of endothelial cells, which causes tumor regression.³⁶ The efficacy and safety of topical timolol for SIH have been proven.³⁷

However, in some hospitals in China, timolol eye drops are banned for use in children because of the contraindications on the packaging. In China, a clinical trial by Liu Jianzhong showed that 2% C-HCL eye drops and 0.5% timolol eye drops have equivalent efficacy and long-term use rarely causes systemic adverse reactions. A Chinese study on infants also revealed that C-HCL 2% eye drops were safe and effective for the treatment of SIH.²³ Therefore, in this study, topical 2% C-HCL eye drops were selected for the treatment of SIH. Local topical β blockers alone can reduce systemic side effects, but they may not be as rapid or effective as oral propranolol, especially for thicker, larger lesions.³⁸ Therefore, combination treatment with other methods is required to increase the efficacy. Since the use of propranolol, the need for surgery in IH has decreased significantly. Surgery is primarily performed for residual lesions after IH regression and is mostly not employed for infants³¹ because the operation requires general anesthesia, and can leave postoperative scars, which is difficult for parents to accept. Laser is a safer option than surgical treatment. The principle of laser treatment of IH is that its wavelength coincides with the absorption peak of oxyhemoglobin. Therefore, the blood vessel's oxyhemoglobin is targeted to absorb a large amount of energy, which increases vascular temperature rapidly, causing local vascular obstruction, thereby resulting in local vascular damage.³⁹ Lasers currently used in IH include a 595-nm PDL, a 755-nm LPAL, and a 1064-nm Nd: YAG laser.⁴⁰ Among them, PDL is the most widely used method and its most common side effects include purpura, swelling, skin atrophy, and hypopigment. A randomized controlled trial and retrospective study showed that 595-nm PDL with cooling function (DCD) had better treatment outcomes, less pigment, and lower risk of post-treatment skin texture changes.^{41,42} Many studies have established the efficacy of PDL, especially for treatment of SIH.^{43,44} For instance, Rozza indicated that PDL had an 81% effective rate for SIH treatment with no adverse effects such as residual scars or tissue atrophy.⁴² However, it is not very effective for deep or thick IH, and the deep components may continuously proliferate⁴⁵ because PDL's penetration depth is only 1.2 mm, perhaps only 1 / 10 of some SIH thickness.⁴⁶ Compared with PDL, although the 1064-nm laser is better for deeper IH, the incidence of adverse events was higher.⁴⁷ Moreover, in comparison with PDL and 1064-nm Nd: YAG lasers, the 755-nm LPAL has a moderate penetration degree, including DCD to reduce the thermal damage to the skin and increase the safety of treatment. Several studies have demonstrated its safety and efficacy in the treatment of thicker IH.^{21,22} Both 755 nm LPAL and topical C-HCL eye drops mono-treatments have indicated good efficacy and safety against SIH. Our previous study has also shown that combined therapy is more effective, requires a shorter treatment time, and has fewer adverse reactions in the treatment of SIH.⁴⁸ Therefore, in this study, the 755 LPAL and topical 2% C-HCL eye drops co-treatment was selected for thicker SIH.

This study revealed that the effective rate of $\leq 1M$, 1–3M, and 3–12M groups was 90%, 86.20%, and 78.20%, respectively. Furthermore, there was no significant difference in the effective rate between the $\leq 1M$ and 1–3M groups, but both groups were better than the 3–12M group. Furthermore, the average number of treatments of $\leq 1M$, 1–3M, and 3–12M groups was 3.90 ± 0.54 , 4.00 ± 0.62 , and 4.84 ± 0.22 times, respectively. There was no significant difference in the average number of treatments between the $\leq 1M$ and 1–3M groups, but the average number of treatments required was less than that in the 3–12M group. These data indicated that early intervention for IH has a better effect with fewer treatment times. Meanwhile, whether earlier treatment give better results was also assessed. The results revealed no significant difference in the efficacy or incidence of adverse reactions, and average number of treatments between the $\leq 1M$ and 1–3M groups. Therefore, the patients with no obvious proliferation can be observed to 1 month; however, if IH has early rapid proliferation, patients are suggested to see a doctor as soon as possible. Because compared with the $\leq 3M$ group, the 3–12M group's curative effect was poor and more treatment times were needed. The reason that the $\leq 1M$ group treatment was not better than the 1–3M group might be related to the growth cycle of IH. A study found that the expression of vascular endothelial growth factor (VEGF) in IH tissues of the proliferative phase was significantly higher than that in normal and subsided tissues.^{49,50} Laser treatment of IH in addition to targeted destruction of blood vessels, can reduce the VEGF.⁵¹ We speculate that most IH has not yet entered the proliferation phase at $\leq 1M$ old age. At this age, the tissue's VEGF has not increased, and the laser action sites are fewer, resulting in poor efficacy. Therefore, it was inferred that the best time for referral or treatment of IH is about 1 month, which is consistent with the conclusion of Tollefson MM.⁶ Furthermore, Jin indicated that for thicker SIH patients, the efficacy of PDL mono-treatment was only 36.1%, while 755-nm LPAL combined with 595-nm laser sequential treatment was 76.3%.⁵² The 755-nm LPAL has better efficacy in thicker SIH compared with PDL due to its deeper degree of penetration. Compared with Hunzeker, who

used PDL mono-treatment and achieved 77.3% efficacy after 5.6 treatments, Jin combined 755-nm LPAL with 595 nm laser treatment and achieved an efficacy of 76.3%.^{52,53} Here, the co-treatment of topical medication and laser treatment achieved an average efficacy of 82.0% after 4.57 treatments. Some scholars have proposed the synergistic theory for the better efficacy of topical drugs combined with laser treatment.²⁴ They believe that the effect of co-treatment is better than the mono-treatment in 3 ways: (1) laser treatment of hemangioma involves hemoglobin absorption and vascular destruction, as well as promote the absorption of timolol eye drops. Whereas β receptor blocker promote vasoconstriction, inhibit angiogenesis, and induce endothelial cell apoptosis. (2) During hemangioma treatment, the related inflammatory factors IL-2 (Interleukin-2), IL-6, and IL-10 are significantly reduced, and the reduction of these factors was even more pronounced in the combination therapy. Therefore, it was speculated that the mechanism may be related to the decreased inflammatory factors. (3) The laser treatment also significantly reduced the serum VEGF level in the patients, which further caused blood vessels and tumor atrophy, thereby promoting rapid and effective therapeutic effects.^{44,54} It was speculated that the efficacy of 755-nm LPAL combined with C-HCL eye drops is better than that of a 755-nm LPAL combined with 595-nm laser sequential treatment or a single topical β -blocker because of the same mechanism, which needs further studies.

This study revealed that the incidence of early treatment adverse reactions in the $\leq 1M$, 1–3M, and 3–12M groups was 33.33, 34.48, and 34.20%, respectively, and there was no statistical difference among the three groups, suggesting that early treatment may not reduce the incidence of adverse reactions. Furthermore, there were no permanent post-treatment adverse reactions, but 10 cases of temporary adverse reactions in the $\leq 1M$ group, while 2 permanent and 28 temporary cases of adverse reactions in the 1–3M group. Whereas, in the 3–12M group, there were 14 permanent and 41 temporary cases of adverse reactions. Compared with the 3–12M group, the adverse reactions in the $\leq 1M$ and 1–3M groups most were temporary skin changes that could be recovered, except for 2 cases of permanent skin changes. In addition, a higher incidence of post-treatment blisters was observed in early-treated children than in the late-treatment group, which might be related to the thinner and more tender skin of the newborn baby. Therefore, in the treatment of infants, the choice of energy should be as small as possible, but the energy reduction may affect the efficacy. Although most of the adverse reactions in the 3–12M treatment group recovered over time, 6 cases indicated permanent hypopigment spots and 8 cases had fibrofatty scars as well as skin sagging, which are difficult to recover by themselves. These adverse events might be associated with excessive hemangioma enlargement due to wait-and-see. However, regardless of early or late treatment, the incidence of post-treatment sequelae of hemangiomas was significantly lower than in natural regression (70%). Therefore, even for low-risk SIH, long-term waiting and observation is not a good approach.

Conclusion

In summary, 755-nm LPAL combined with 2% C-HCL eye drops is a safe and effective treatment regimen against thicker SIH. Furthermore, compared with the 3–12M group, early treatment (≤ 3 months) can achieve better efficacy and require a shorter treatment time. 755-nm LPAL combined with 2% C-HCL eye drops shows strong promise for the treatment of thicker SIH in children in the clinical setting. Moreover, although early treatment cannot reduce the incidence of adverse reactions, there are fewer permanent skin lesions such as scars compared with the 3–12M group. So patients with no obvious proliferation can be observed to about 1 month and if IH proliferates rapidly in the early stage, it is recommended that patients seek medical attention as soon as possible.

Abbreviations

IH, infantile hemangioma; SIH, superficial infantile hemangioma; LPAL, long pulse alexandrite laser; C-HCL, carteolol hydrochloride; PDL, pulse dye laser; DCDA, dynamic cooling device; VEGF, vascular endothelial growth factor; IL, Interleukin.

Funding

This study is supported by Jinhua Science and Technology Projects (grant number is 2021-4-019).

Disclosure

The authors report no conflicts of interest for this work.

References

- Anderson KR, Schoch JJ, Lohse CM, Hand JL, Davis DM, Tollefson MM. Increasing incidence of infantile hemangiomas (IH) over the past 35 years: correlation with decreasing gestational age at birth and birth weight. *J Am Acad Dermatol.* 2016;74(1):120–126. doi:10.1016/j.jaad.2015.08.024
- Kilcline C, Frieden IJ. Infantile hemangiomas: how common are they? A systematic review of the medical literature. *Pediatr Dermatol.* 2008;25(2):168–173. doi:10.1111/j.1525-1470.2008.00626.x
- Dickison P, Christou E, Wargon O. A prospective study of infantile hemangiomas with a focus on incidence and risk factors. *Pediatr Dermatol.* 2011;28(6):663–669. doi:10.1111/j.1525-1470.2011.01568.x
- Beth AD, Elizabeth AS, Ilona JF. Infantile hemangiomas: an emerging health issue linked to an increased rate of low birth weight infants. *J Pediatr.* 2008;153(5):712–715. doi:10.1016/j.jpeds.2008.05.043
- Jose MM, Sara S, Víctor G, Pilar C, Dolores R. Infantile hemangiomas with minimal or arrested growth: a retrospective case series. *Pediatr Dermatol.* 2018;36(1):125–131. doi:10.1111/pde.13695
- Tollefson MM, Frieden IJ. Early growth of infantile hemangiomas: what parents' photographs tell us. *Pediatrics.* 2012;130(2):e314–e320. doi:10.1542/peds.2011-3683
- Stockman JA. Growth characteristics of infantile hemangiomas: implications for management. In *Yearbook of Pediatrics.* 2010;2010:37–39.
- Baselga E, Roe E, Coulie J, et al. Risk Factors for Degree and Type of Sequelae After Involution of Untreated Hemangiomas of Infancy. *JAMA Dermatol.* 2016;152(11):1239–1243. doi:10.1001/jamadermatol.2016.2905
- Leaute-Labreze C, Prey S, Ezzedine K. Infantile haemangioma: part I. Pathophysiology, epidemiology, clinical features, life cycle and associated structural abnormalities. *J Eur Acad Dermatol Venereol.* 2011;25(11):1245–1253. doi:10.1111/j.1468-3083.2011.04102.x
- Hoeger PH, Harper JI, Baselga E, et al. Treatment of infantile haemangiomas: recommendations of a European expert group. *Eur J Pediatr.* 2015;174(7):855–865. doi:10.1007/s00431-015-2570-0
- Bauland CG, Luning TH, Smit JM, Zeebregts CJ, Spauwen PHM. Untreated hemangiomas: growth pattern and residual lesions. *Plast Reconstr Surg.* 2011;127(4):1643–1648. doi:10.1097/PRS.0b013e318208d2ac
- Moyakine AV, Spillekom-van Kouilil S, van der Vleuten CJM. Propranolol treatment of infantile hemangioma is not associated with psychological problems at 7 years of age. *J Am Acad Dermatol.* 2017;77(1):105–108. doi:10.1016/j.jaad.2017.01.025
- Cinkara G, Langbroek GB, van der Horst C, Wolkerstorfer A, Horbach SER, Ubbink DT. Therapeutic Strategies for Untreated Capillary Malformations of the Head and Neck Region: a Systematic Review and Meta-Analyses. *Am J Clin Dermatol.* 2021;22(5):603–614. doi:10.1007/s40257-021-00616-5
- A RR, P JA. Selective photothermolysis: precise microsurgery by selective absorption of pulsed radiation. *Science.* 1983;220(4596):524–527. doi:10.1126/science.6836297
- Chinnadurai S, Sathe NA, Surawicz T. Laser treatment of infantile hemangioma: a systematic review. *Lasers Surg Med.* 2016;48(3):221–233. doi:10.1002/lsm.22455
- Zide BM, Levine SM. Hemangioma update: pearls from 30 years of treatment. *Ann Plast Surg.* 2012;69(1):99–103. doi:10.1097/SAP.0b013e3182212881
- Hartmann F, Lockmann A, Himpel O, et al. Combination therapy of oral propranolol and combined Nd:YAG/pulsed dye laser therapy in infantile hemangiomas: a retrospective analysis of 48 treated hemangiomas in 30 children. *J Dtsch Dermatol Ges.* 2020;18(9):984–993.
- Hartmann F, Lockmann A, Gronemeyer LL, et al. Nd:YAG and pulsed dye laser therapy in infantile haemangiomas: a retrospective analysis of 271 treated haemangiomas in 149 children. *J Eur Acad Dermatol Venereol.* 2017;31(8):1372–1379. doi:10.1111/jdv.14074
- Alcántara-González J, Boixeda P, Truchuelo-Díez MT, Pérez-García B, Alonso-Castro L, Jaén Olasolo P. Infantile Hemangiomas Treated by Sequential Application of Pulsed Dye Laser and Nd:YAG Laser Radiation: a Retrospective Study. *Actas Dermosifiliogr.* 2013;104(6):504–511. doi:10.1016/j.ad.2012.12.010
- Ioannis V, Stefanos G, Eleni M, Georgios C. Treatment of hemangiomas in children using a Nd:YAG laser in conjunction with ice cooling of the epidermis: techniques and results. *BMC Pediatr.* 2003;3:1–6.
- Su W, Ke Y, Xue J. Beneficial effects of early treatment of infantile hemangiomas with a long-pulse Alexandrite laser. *Lasers Surg Med.* 2014;46(3):173–179. doi:10.1002/lsm.22221
- Wu J, Zhou F, Gao Y. Efficacy Evaluation of 755-nm Long-Pulse Alexandrite Laser Combined with 0.5% Timolol Maleate Eye Drops in the Treatment of Thicker Infantile Hemangioma. *Clin Cosmet Invest Dermatol.* 2021;14:1621–1628. doi:10.2147/CCID.S330411
- Gan LQ, Wang H, Ni SL, Tan CH. A prospective study of topical carteolol therapy in Chinese infants with superficial infantile hemangioma. *Pediatr Dermatol.* 2018;35(1):121–125. doi:10.1111/pde.13361
- Chen X, Guo Y, Wang P, et al. Efficacy and safety of adrenergic beta-antagonist combined with lasers in the treatment of infantile hemangiomas: a meta-analysis. *Pediatr Surg Int.* 2020;36(10):1135–1147. doi:10.1007/s00383-020-04711-2
- Cazeau C, Blei F, Gonzales Hermosa M, et al. Burden of Infantile Hemangioma on Family: an International Observational Cross-Sectional Study. *Pediatr Dermatol.* 2017;34(3):295–302. doi:10.1111/pde.13133
- Munden A, Butschek R, Tom WL, et al. Prospective study of infantile haemangiomas: incidence, clinical characteristics and association with placental anomalies. *Br J Dermatol.* 2014;170(4):907–913. doi:10.1111/bjd.12804
- Chelleri C, Monzani NA, Gelmetti C, et al. Residual Lesions After Pharmacological and Dye-Laser Treatment of Infantile Hemangiomas: critical Review of 432 Cases. *Lasers Surg Med.* 2020;52(7):597–603. doi:10.1002/lsm.23205
- Enjolras O, Mulliken J. The current management of vascular birthmarks. *Pediatr Dermatol.* 1993;10(4):311–313. doi:10.1111/j.1525-1470.1993.tb00393.x
- Moyakine AV, Hermans DJ, Fuijkschot J, van der Vleuten CJ. Propranolol treatment of infantile hemangiomas does not negatively affect psychomotor development. *J Am Acad Dermatol.* 2015;73(2):341–342. doi:10.1016/j.jaad.2015.04.053

30. Solman L, Glover M, Beattie PE, et al. Oral propranolol in the treatment of proliferating infantile haemangiomas: British Society for Paediatric Dermatology consensus guidelines. *Br J Dermatol*. 2018;179(3):582–589. doi:10.1111/bjd.16779
31. Krowchuk D, Frieden I, Mancini A, et al. Clinical Practice Guideline for the Management of Infantile Hemangiomas. *Pediatrics*. 2019;143(1):1. doi:10.1542/peds.2018-3475
32. Puttgen KB, Hansen LM, Lauren C, et al. Limited utility of repeated vital sign monitoring during initiation of oral propranolol for complicated infantile hemangioma. *J Am Acad Dermatol*. 2021;85(2):345–352. doi:10.1016/j.jaad.2020.04.013
33. Gonski K, Wargon O. Retrospective follow up of gross motor development in children using propranolol for treatment of infantile haemangioma at Sydney Children's Hospital. *Australas J Dermatol*. 2014;55(3):209–211. doi:10.1111/ajd.12156
34. Bagazgoitia L, Hernandez-Martin A, Torrelo A. Recurrence of infantile hemangiomas treated with propranolol. *Pediatr Dermatol*. 2011;28(6):658–662. doi:10.1111/j.1525-1470.2011.01644.x
35. Zhang W, Li F, Yang Y, Xue L, Cao M, Wang L. Hemangioma treatment with pulsed dye laser-distinct parameters used between neonatal and non-neonatal patients. *J Cosmet Laser Ther*. 2016;18(7):389–392. doi:10.1080/14764172.2016.1197402
36. Calvo M, Garcia-Millan C, Villegas C, Fueyo-Casado A, Buron I. Topical timolol for infantile hemangioma of the eyelid. *Int J Dermatol*. 2013;52(5):603–604. doi:10.1111/j.1365-4632.2011.05290.x
37. Frommelt P, Juern A, Siegel D, et al. Adverse Events in Young and Preterm Infants Receiving Topical Timolol for Infantile Hemangioma. *Pediatr Dermatol*. 2016;33(4):405–414. doi:10.1111/pde.12869
38. Chakkittakandiyil A, Phillips R, Frieden IJ, et al. Timolol maleate 0.5% or 0.1% gel-forming solution for infantile hemangiomas: a retrospective, multicenter, cohort study. *Pediatr Dermatol*. 2012;29(1):28–31. doi:10.1111/j.1525-1470.2011.01664.x
39. Batta K, Goodyear HM, Moss C, Williams HC, Hiller L, Waters R. Randomised controlled study of early pulsed dye laser treatment of uncomplicated childhood haemangiomas: results of a 1-year analysis. *Lancet*. 2002;360(9332):521–527. doi:10.1016/S0140-6736(02)09741-6
40. Jiang JC, Xu Q, Fang S, Gao Y, Jin WW. Sequelae After Involution of Superficial Infantile Hemangioma: early Intervention with 595-nm Pulsed Laser Combined with 755-nm Long-Pulsed Alexandrite Laser versus Wait-and-See. *Clin Cosmet Invest Dermatol*. 2021;14:37–43. doi:10.2147/CCID.S279140
41. Kono T, Sakurai H, Groff WF, et al. Comparison study of a traditional pulsed dye laser versus a long-pulsed dye laser in the treatment of early childhood hemangiomas. *Lasers Surg Med*. 2006;38(2):112–115. doi:10.1002/lsm.20257
42. Miller SH. Outcomes of Childhood Hemangiomas Treated with the Pulsed-Dye Laser with Dynamic Cooling: a Retrospective Chart Analysis. In *Yearbook of Plastic and Aesthetic Surgery*. 2011;2011:31–32
43. Chen W, Liu S, Yang C, Yang S. Clinical efficacy of the 595 nm pulsed dye laser in the treatment of childhood superficial hemangioma - analysis of 10-year application in Chinese patients. *J Dermatol Treat*. 2015;26(1):54–58. doi:10.3109/09546634.2013.806979
44. Ying H, Zou Y, Yu W, et al. Prospective, open-label, rater-blinded and self-controlled pilot study of the treatment of proliferating superficial infantile hemangiomas with 0.5% topical timolol cream versus 595-nm pulsed dye laser. *J Dermatol*. 2017;44(6):660–665. doi:10.1111/1346-8138.13747
45. Poetke M, Philipp C, Berlien HP. Flashlamp-pumped pulsed dye laser for hemangiomas in infancy: treatment of superficial vs mixed hemangiomas. *Arch Dermatol*. 2000;136(5):628–632. doi:10.1001/archderm.136.5.628
46. Barry MZ, Steven ML. Hemangioma update: pearls from 30 years of treatment. *Ann Plast Surg*. 2011;69(1):99–103.
47. Chen ZY, Wang QN, Zhu YH, et al. Progress in the treatment of infantile hemangioma. *Ann Transl Med*. 2019;7(22):692. doi:10.21037/atm.2019.10.47
48. Shi W, He H, Jiang J, Gao Y, Quan H. Timing and Efficacy of 595-nm Pulsed-Dye Laser Combined with 0.5% Timolol Maleate Solution in the Treatment of Superficial Infantile Hemangiomas. *Clin Cosmet Invest Dermatol*. 2021;14:1593–1599. doi:10.2147/CCID.S337850
49. Ke C, Chen C, Yang M, Chen H, Ke Y, Li L. Inhibition of infantile hemangioma growth and promotion of apoptosis via VEGF/PI3K/Akt axis by 755-nm long-pulse alexandrite laser. *Biomed J*. 2023;47(4):100675. doi:10.1016/j.bj.2023.100675.
50. Makkeyah S, Elseedawy M, Abdel-Kader H, Mokhtar G, Ragab I. Vascular endothelial growth factor response with propranolol therapy in patients with infantile hemangioma. *Pediatr Hematol Oncol*. 2022;39(3):215–224. doi:10.1080/08880018.2021.1961956
51. Yong-Kwang T, Siew-Kiang T. Treatment of infantile hemangiomas with the 595-nm pulsed dye laser using different pulse widths in an Asian population. *Lasers Surg Med*. 2012;44(2):93–96. doi:10.1002/lsm.21159
52. Jin WW, Tong Y, Wu JM, Quan HH, Gao Y. Observation on the effects of 595-nm pulsed dye laser and 755-nm long-pulsed alexandrite laser on sequential therapy of infantile hemangioma. *J Cosmet Laser Ther*. 2020;22(3):159–164. doi:10.1080/14764172.2020.1783452
53. Christopher MH, Roy GG. Treatment of superficial infantile hemangiomas of the eyelid using the 595-nm pulsed dye laser. *Dermatol Surg*. 2010;36(5):590–597. doi:10.1111/j.1524-4725.2010.01511.x
54. Park KH, Jang YH, Chung HY, Lee WJ, Kim DW, Lee SJ. Topical timolol maleate 0.5% for infantile hemangioma; it's effectiveness and/or adjunctive pulsed dye laser - single center experience of 102 cases in Korea. *J Dermatol Treat*. 2015;26(4):389–391. doi:10.3109/09546634.2014.990412

Clinical, Cosmetic and Investigational Dermatology

Dovepress

Publish your work in this journal

Clinical, Cosmetic and Investigational Dermatology is an international, peer-reviewed, open access, online journal that focuses on the latest clinical and experimental research in all aspects of skin disease and cosmetic interventions. This journal is indexed on CAS. The manuscript management system is completely online and includes a very quick and fair peer-review system, which is all easy to use. Visit <http://www.dovepress.com/testimonials.php> to read real quotes from published authors.

Submit your manuscript here: <https://www.dovepress.com/clinical-cosmetic-and-investigational-dermatology-journal>