

# Rosacea Fulminans in Pregnancy: A Case Report and Review

Qi-Hao Yao , Ze-Hu Liu

Department of Dermatology, Hangzhou Third People's Hospital, Zhejiang University School of Medicine, Hangzhou, Zhejiang, People's Republic of China

Correspondence: Ze-Hu Liu, Department of Dermatology, Hangzhou Third People's Hospital, Zhejiang University School of Medicine, West Lake Road 38, Hangzhou, Zhejiang, 310009, People's Republic of China, Tel +86-571-87827181, Email zehuliu@yahoo.com

**Abstract:** Rosacea is a common dermatosis with multiple pathogeneses, among which, rosacea fulminans may serve as a rare but severe subtype. This inflammatory disease usually presents as abrupt multiple erythema, pustules, and nodules localized on the face. Pregnancy and related changes of hormone levels may play a key role in the development and progression of the disease, although the exact mechanisms are unknown. In particular, treatment options, which includes systemic glucocorticosteroids, isotretinoin, and partial oral antibiotics, may be limited in pregnancy. Owing to the limited number of reported cases, standard diagnosis, treatment, and management guidelines remain unclear. Here, we report a case of rosacea fulminans happening in pregnancy treated successfully with oral erythromycin and short-term glucocorticosteroids, and share our review of the characteristics of RF cases during pregnancy.

**Keywords:** rosacea fulminans, erythromycin, dermatology, pregnancy, ocular involvements

## Introduction

Rosacea fulminans is a severe and rare skin disease that primarily affects the central facial region. Its manifestations include papules, pustules, nodules, intense erythema, telangiectasia, or fluctuating interconnecting sinuses that drain purulent fluid confined to the face.<sup>1</sup>

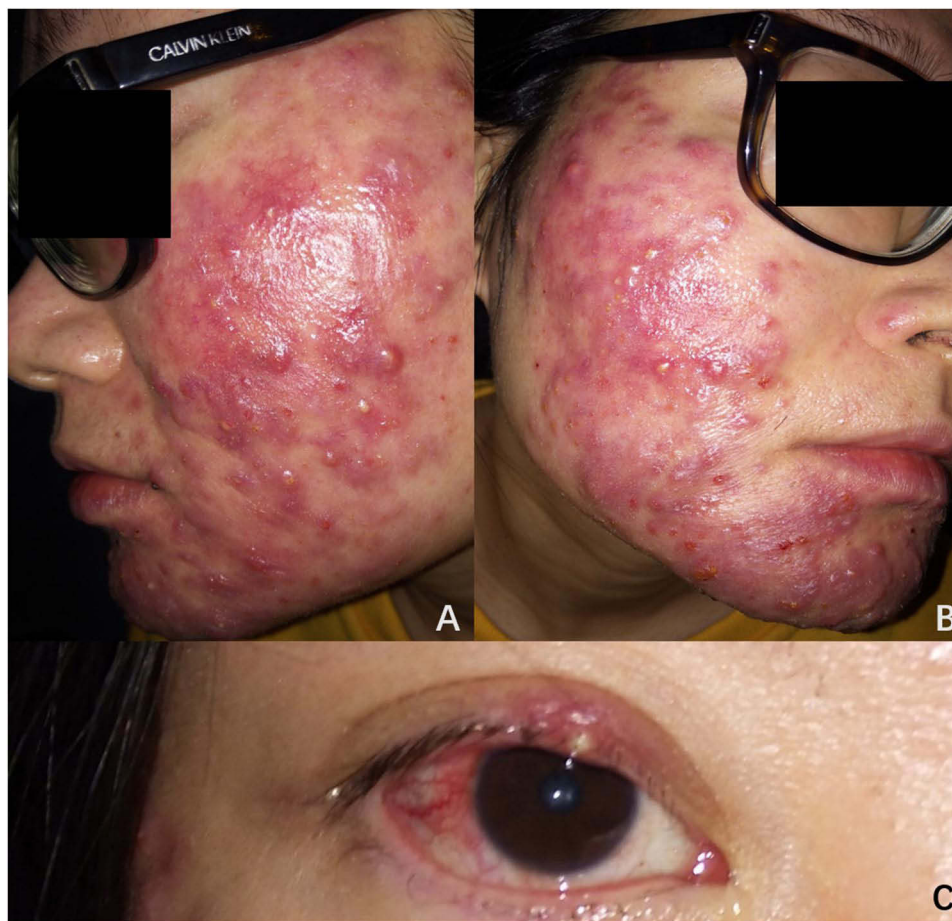
This disease was first described by O'Leary and Kierland in 1940, named as facial pyoderma.<sup>2</sup> In 1992, Plewig renamed it as RF, thinking it not a special acne conglobata but a severe variant of rosacea.<sup>3</sup> Hormone changes might explain the relationship between RF and pregnancy. Other triggers, including high doses of Vb6/Vb12, pegylated interferon, emotional stress, and oral contraceptives, have also been identified, based on limited case reports.<sup>4</sup>

Here, we report a case of rosacea fulminans during pregnancy. The patient recovered successfully with oral erythromycin, short-term glucocorticosteroids and topical lincomycin gel, with no additional drugs or serious complications.

## Case Report

A 39-year-old woman in the 21th week of pregnancy visited our clinic with a 2-week history of abrupt facial eruption and ocular discomfort. Physical examination revealed pustules, papules, nodules with edema, and flushing mainly in the lower part of the face (Figure 1A and B). Dilated vessels were observed on the surface of the bulbar conjunctiva and blepharitis glandularis on the upper eyelid (Figure 1C). Further ocular examination revealed hemangiectasis of the palpebral and bulbar conjunctiva, partial opacity at the edge of the cornea, and a clean anterior chamber. The patient had a history of acne vulgaris 3 years previously. She reported no systemic symptoms or history of oral contraceptives or other drugs.

RF was diagnosed based on clinical features and dermatoscopy results of a diffuse polygonal network of blood vessels and scattered follicular pustules on a mauve background. Advised treatment with oral retinoids, steroids, and oral antibiotics was limited considering the patient's age and pregnancy. Therefore, we chose oral erythromycin (250 mg/12



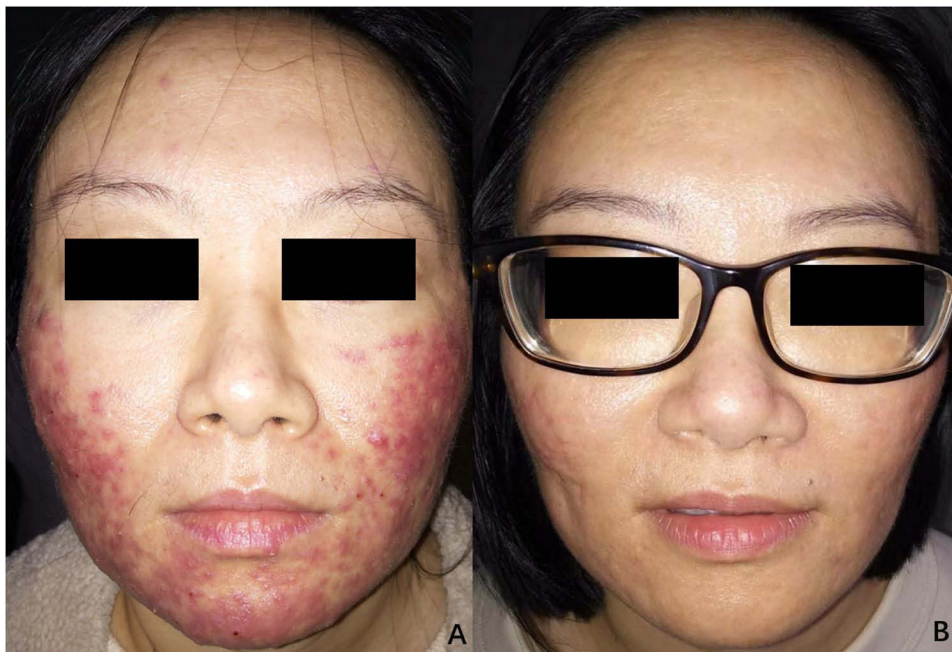**Figure 1** (A) and (B) Pustules, papules, nodules with edema and flushing mainly on the central and lower part of face. (C) Hemangiectasis on the surface of the bulbar conjunctiva and blepharitis glandularis on the upper eyelid.

h) and topical lincomycin gel as the initial treatment. The facial eruption subsided significantly after two months of treatment, but still left remaining flushing and pustules persisted in the 30th week (Figure 2A). After ruling out potential intrauterine growth retardation and gestational diabetes mellitus, additional systemic glucocorticosteroids (15 mg/12 h) and topical wet compresses with chloramphenicol borate solution were administered. Subsequent periodic prenatal examinations revealed no evidence of accident. Systemic glucocorticosteroids of this dosage lasted for two weeks until the pustules were controlled, and gradually tapered off in 2 weeks. Specifically, oral glucocorticosteroids were given 15mg/12h for 2 weeks, 10mg/12h for 1 week, 5mg/12h for 1 week, and then discontinued. Other treatments lasted for approximately seven months, in which oral erythromycin lasted for four months and topical lincomycin continued for two months after delivery, leaving slight scarring on the cheeks. During 6 months follow-up, the patient was in stable condition, with no relapse observed (Figure 2B).

## Discussion

Rosacea fulminans, which is called facial pyoderma when first described by O'Leary and Kierland in 1940, is thought to be a special acne conglobata.<sup>2</sup> It usually appears as erythematous papules, pustules, telangiectasia and nodules, typically on centrofacial regions with a tendency to fuse into plaques and interconnecting sinuses draining purulent material.<sup>1</sup> No acne-like appearances and comedones was observed. The possible differential diagnoses include seborrheic dermatitis, acne fulminans, drug eruptions, vermiform acariasis, gram-negative folliculitis, dermatomyositis, and eczema.

RF usually affects women in their 20s–40s (an average age of 31.3 years), and accounts for 92% of the reported cases.<sup>5</sup> Few children and men were included in this study. No specific infectious causes or pathological results were



**Figure 2** (A) Lesions subsided but still remaining flushing and several pustules in the 30th week. (B) During follow-up, the patient was in stable condition with slight scarring.

found about this disease since. In 1992, regarding the involved area, patients' demographic information, and out-facial symptoms, Plewig et al suggested that RF is a severe variant of rosacea rather than a kind of acne, and stated the clinical features of RF by assessing patients affected to help make the diagnosis.<sup>3</sup> These features are still used today. In 2002, the National Rosacea Society (NRS) classified rosacea into four distinct subtypes: erythematotelangiectatic, papulopustular, phymatous and ocular, pointing out that the mixed perifollicular inflammatory infiltrate in pathological examinations was not specific, but could assist in identifying the stages of process.<sup>2,3,6-8</sup> However, RF was excluded with no sufficient evidence to show it an extreme type.<sup>9</sup> Later in 2004 NRS standard diagnostic flow chart for rosacea did not include guidelines for RF, and till 2017 NRS developed a new standard for rosacea classification, downplayed the concept of subtypes and focus more on the phenotypes like centrofacial erythema in a characteristic pattern, with no more guidelines for RF as well.<sup>10</sup>

Although the etiology of RF is unknown, 135 cases of rosacea fulminans, rosacea conglobata, or pyoderma faciale reported in the literature between 1916 and 2016 showed that potential disease triggers were reported in 57 patients (42%), including pregnancy in 42% (24/57), emotional stress in 30% (17/57), and medication (high doses of Vb6/Vb12, pegylated interferon  $\alpha$ , oral contraceptives, topical steroids, herbal medications, ribavirin, azathioprine).<sup>4</sup> Hormone level may play a key role in the pathogenesis and development of RF, explaining sex differences and pregnancy as a trigger. A positive history of acne or rosacea has also been reported in some cases. However, in recent years, some authors have suggested that a history of acne may be misdiagnosed. 87% of case reports documenting acne history were published before 1992, the year when the nomenclature was changed to RF.<sup>3</sup> This may indicate a change in the understanding and classification of the disease, and also directed the formulation and optimization of therapeutic strategies.

The ocular involvement of RF is very common and accounted for more than 50% of cases.<sup>11</sup> It could happen before, during or after the skin disease, mainly as eyelid disease including meibomian gland dysfunction, blepharitis, eyelid capillaries expansion and corneal or conjunctival involvement.<sup>9</sup> Generally, the prognosis is good with proper treatment. The most severe case showed corneal perforation, which recovered after corneal transplantation.<sup>6</sup> In this case, ocular examination revealed vascular dilation and corneal opacification, which helped in the diagnosis. It should be noted that ocular involvement is also a feature of rosacea or RF that distinguishes it from other inflammatory facial diseases, such as acne and folliculitis.

Early intervention is necessary to delay disease progression and shorten their courses. A better systemic approach, first proposed by Plewig et al, involves a short course of oral glucocorticosteroids (prednisone, 0.5–1.0 mg/kg/daily, taper in 2–3 weeks) for 10–14 days, followed by oral isotretinoin for 2–4 months after glucocorticosteroids reduction.<sup>12</sup> However, this treatment option was difficult to use in this patient after evaluation due to its potential teratogenic and gestational syndromes, including intrauterine growth restriction, gestational diabetes, and hypertension, similar to those of rheumatoid disease control during pregnancy.<sup>13,14</sup>

Including our case, 27 cases of RF during pregnancy have been reported in the English literature, for which the original text is available. Two Korean cases of RF during pregnancy were excluded because the original Korean text was unavailable. Table 1 shows the basic situation of patients with RF in pregnancy. Topical treatments are varied in these cases: incision drainage, phototherapy, permethrin, metronidazole/azelaic acid or other antibiotic cream and gel.<sup>15</sup>

**Table 1** Summary of the Basic Situation of Patients with RF in Pregnancy

Case	Age	Diagnosed Weeks (Trimester)	History of Acne or Rosacea	Treatment	Outcome and/or Complications	Reference
1–5	NA	(3) or PP	4 with rosacea, 1 unknown	Oral antibiotics combined with topical benzoyl peroxide or antibiotics	NA	[32]
6	25	16(2)	Acne	Worsen with intralesional triamcinolone acetonide; erythromycin 250 mg/6h with topical 1% hydrocortisone cream and drainage, Tapered prednisone 60 mg/d; isotretinoin 40 mg/12 h PP	Recovered after delivery and use of isotretinoin	[33]
7	23	(1)	Acne	Topical erythromycin and clindamycin	NA	[3]
8	33	(3)	Acne	Topical erythromycin and clindamycin	NA	[3]
9	25	(1)	Acne	Topical erythromycin and clindamycin	NA	[3]
10	26	PP	No	Topical erythromycin and clindamycin	NA	[3]
11	35	NA	Rosacea	She had a history of RF before pregnancy, which is improved with oral tetracycline 1g /d, prednisolone 5mg/d for 3 months. This relapse was caused by pregnancy with no detailed description of treatment,	NA	[16]
12	28	4(1)	Acne and rosacea	Erythromycin 500 mg/8 h, prednisone 35 mg/d with subsequent maintenance at 20 mg/d; lymecycline 408 mg/d after miscarriage, added to 408mg/12h 2 months postpartum	New onset of gestational diabetes mellitus, oligohydramnios and intrauterine death during the use of prednisone. Improved after miscarriage with low-grade rosacea	[34]
13	31	8(1)	Acne and rosacea	Tapered methylprednisolone 40 mg/d, topical fusidic acid, 0.75%metronidazole, wet compresses and drainage	Improved well with no relapse	[35]
14	32	3(1)	No	Oral macrolide and amoxicillin with topical macrolide and metronidazole showed no improvement. Isotretinoin 0.5mg/kg/d for 3 months PP	Pregnancy was assisted by Reproductive technology. Recovered after delivery with isotretinoin used	[36]
15	35	(1)	No	Erythromycin 2 g/d and prednisone 30 mg/d before pregnancy termination; Prednisone 45 mg/d tapered in 4 weeks and isotretinoin from 20mg/d to 40 mg/d after pregnancy termination	Slight improvement and anxious-depressive disorder about RF before pregnancy termination at 12 weeks; After end of isotretinoin, no relapse but extensive facial scarring and telangiectasia on the cheeks and nose	[17]

(Continued)

Table 1 (Continued).

Case	Age	Diagnosed Weeks (Trimester)	History of Acne or Rosacea	Treatment	Outcome and/or Complications	Reference
16	31	8(1)	No (But suspected history of pustules)	Erythromycin 1 g/d with no improvement; erythromycin 2 g/d with improvement but not clearance; prednisone 20 mg/d tapered in 6 weeks and isotretinoin 40 mg/d PP	Clearance within 4 months of isotretinoin, leaving minimal residual scarring	[17]
17	26	21(2)	NA	Erythromycin 2 g/d, prednisone 40 mg/d tapered after delivery	Improved after 10 days of treatment; ocular perforation, treated with corneal transplant	[6]
18	33	11(1)	No	Azithromycin 500 mg/d for the first 3 days of every week for 1 month; 250 mg/d on the same days for 1 month; 500 mg for the first day of every week for 1 month. Topical metronidazole during oral medication; topical metronidazole and clindamycin after oral medication	Rapid response and no skin lesions by the 6 <sup>th</sup> month of pregnancy	[37]
19	38	14(2)	No	Erythromycin 500 mg/12 h	Resolution within a few months	[38]
20	37	37(3)	Acne	A small improvement with prednisone 35 mg/d, azithromycin 1 g/d, paracetamol 3g/d, artificial tears and cleansing of the eyelashes before delivery; Azithromycin 1 g/d and prednisone 25mg/d showed improvement PP; isotretinoin 25 mg/d 1 month after delivery	New onset of gestational diabetes mellitus before the use of prednisone and ocular involvement of RF. Improved significantly after delivery, leaving facial scarring;	[39]
21	22	6(1)	NA	Amoxicillin/clavulanic acid 1 g/d, topical wet compresses and fusidic acid cream	Clearance 1 month after end of treatment, leaving mild erythema and scarring	[40]
22	32	18(2)	No	Worsen with topical mupirocin for initial 3 months; Topical corticosteroid with no improvement for 16 weeks; methylprednisolone 2 mg/day before delivery; isotretinoin PP	Lesions did not improve until delivery. Resolution was achieved with isotretinoin	[41]
23	28	13(2)	Acne	Following drugs were used alone or in combination, showing no obvious effect in 2 months: oral erythromycin, amoxicillin/clavulanic acid; topical erythromycin, mupirocin, zinc oxide, metronidazole. Oral metronidazole 250mg/12h for 1 month with 30mg prednisone tapered 5% permethrin cream /12h for 6 weeks	Intrauterine growth retardation during the use of prednisone. Complete clearing by 29 <sup>th</sup> week with 5% permethrin cream. No relapse before and after delivery;	[15]
24	32	10(1)	NA	Worsen with oral cephalosporin; Partial improvement with intralesional triamcinolone 2.5 mg/cc injections and several blue light treatments; Slightly improved with prednisone 20mg/d, topical crotamiton cream, ivermectin 1% and sodium sulfacetamide cleanser. Improved with azithromycin 250 mg/d, prednisone 40mg/d (lasted for 10 weeks before taper), metronidazole cream/12 h; PP: Isotretinoin 40 mg/d for 3 months, and tapered in another 2 months	Significant Improvement with prednisone and azithromycin by 18 <sup>th</sup> week; preterm birth in 34 <sup>th</sup> week; complete clearance with isotretinoin PP;	[26]
25	20	14(2)	No	Erythromycin 500 mg/8h with topical hydrocortisone and metronidazole for 3 weeks, Topical metronidazole for 3 months	Rapid response. Complete resolution gained in 3 months	[42]

(Continued)

**Table I** (Continued).

Case	Age	Diagnosed Weeks (Trimester)	History of Acne or Rosacea	Treatment	Outcome and/or Complications	Reference
26	31	12(2)	No	Progression with amoxicillin/clavulanate 3 g/d and topical fusidic acid for 1 week. Oral azithromycin 500 mg/d in three consecutive days each week from 16 <sup>th</sup> to 21th week and prednisone 20mg/d tapered in 10 weeks. Isotretinoin 0.5mg/kg/day 3 months PP, lasting for 4 months	Improved significantly with oral azithromycin and prednisone, leaving mild erythema. Clearance with isotretinoin PP	[43]
Our patient	39	21(2)	Acne	Oral erythromycin 250mg/12h and topical lincomycin gel/d for 4 months. oral glucocorticoids 15mg/12h for 2 weeks, tapered off in another 2 weeks, with wet compresses using chloramphenicol borate solution/d for 2 months. Topical lincomycin gel/d alone for 3 months	Rapid response. Resolution gained 4 months. No relapse in 6 months after treatment	

**Abbreviations:** RF, Rosacea fulminans; NRS, National Rosacea Society; PP, postpartum.

In all cases, one recurrence of RF is caused by pregnancy.<sup>16</sup> Although the types and dosages of drugs used in different patients varied, only six patients had a clear complete improvement or clearance before delivery, not dependent on pregnancy termination or additional medications after delivery. No uncontrolled RF was observed postpartum or after termination of pregnancy. This result provides supportive evidence that pregnancy and factors including pregnancy-related hormonal changes are important in the development and progression of RF.

As the oldest patient (39 years old), our case presented ocular involvement (3/27) and was diagnosed as RF in the second trimester (8/27). In the previous 26 cases, various antibiotics were the most widely used oral and topical drugs. Among them, oral macrolides were used in 50% (13/26) of the cases because of their high safety during pregnancy. However, this approach is ineffective in some cases. The effect of antibiotic supplementation alone is limited.<sup>17</sup> In patients treated with oral macrolides with or without other therapies but without systemic glucocorticosteroids and isotretinoin, 50% (3/6) responded well with no need for further systemic corticosteroids or isotretinoin, and 50% (3/6) needed changes in treatment. In our patient, it took up to 7 months to achieve complete clearance, which may be related to the relatively low drug dosage and simple type of drug.

Other oral antibiotic treatments used in RF without pregnancy include tetracycline and dapsone, which have anti-inflammatory effects at low doses.<sup>18–22</sup> One possible dose is doxycycline 40mg/d, which has no antibacterial activity but inhibits rosacea's inflammatory response. Macrolides also play a similar anti-inflammatory role in rosacea. Several clinical trials have demonstrated that azithromycin or clarithromycin could be used as alternatives for the treatment of rosacea, showing better effects.<sup>23,24</sup>

However, the use of macrolides and similar drugs in pregnancy is different. There is a lack of review or expert consensus regarding the selection and dosages of them in RF with pregnancy. Erythromycin and azithromycin are pregnancy category B drugs, while clarithromycin is pregnancy category C drug. Only the first two oral macrolides were feasible in RF with pregnancy, and both of them are generally considered safe.

The dosage of erythromycin in moderate to severe inflammatory acne, 250–500mg, 2 to 4 times a day, can be used as a reference.<sup>25</sup> At the same time, there were differences in dosage, frequency and individual response to erythromycin in reported cases. In some cases, when erythromycin of low dosage is ineffective, the efficacy of increasing dosage alone has not been effective, and detailed comparative data for dosage are lacking. Therefore, there may be no clear advantage or disadvantage between different doses. Given the patient's relatively elder age of pregnancy and less safety data available on azithromycin compared to erythromycin, we chose erythromycin as a more reliable treatment option. Erythromycin controlled the progression of the disease at a dosage of 250mg/12h and improved the original lesions,

although it did not completely resolve. This further confirmed the anti-inflammatory effects of low doses of erythromycin.

Systemic glucocorticosteroids were administered to ten patients. Three of these 10 patients reported adverse events including intrauterine death, intrauterine growth retardation, and preterm birth. Considering that postpartum isotretinoin administration showed no serious adverse events, all treatment-related complications occurred in cases using systemic glucocorticosteroids during pregnancy. None of the literature explicitly recommends appropriate or weight-based standardized doses of glucocorticosteroids used in RF during pregnancy. Therefore, the benefits of oral glucocorticosteroids and the risks of fetal and maternal complications should be evaluated in advance.

Our summary of the cases suggests that oral glucocorticosteroids with an initial dosage of < 30mg/ day appear to be less effective.<sup>17,26</sup> In our case, systemic glucocorticoid 15 mg/12h was used for 2 weeks and tapered in another 2 weeks, with no adverse outcomes observed: compared with previous literature, this therapy was medium in dosage and shorter in duration and tapering. Fortunately, the patient's condition was successfully controlled without adverse reactions or disease recurrence even after relatively rapid withdrawal. It is possible that a minimum effective dose of less than 20 mg/ day delaying progression is relatively safe according to the recommended dosage for some autoimmune or inflammatory diseases, such as systemic lupus erythematosus or moderate to severe inflammatory acne.<sup>25,27</sup> However, this dosage may not be sufficient to control RF, especially in periods of activity or aggravation. We recommend gradually reducing the dose to avoid potential adverse reactions and obtain better therapeutic effects.

Referring to the approach proposed by Plewig et al mentioned above, we tried to give a possible plan.<sup>12</sup> An initial dosage of oral glucocorticosteroids 30mg to 40mg/ day could be given depending on the condition and the patient's weight. The cases in the table all achieved remission of different degrees at this dose. Maintenance might not exceed 2 to 3 weeks, and then consider reducing 5 to 10mg per 1 to 2 weeks. If there is no obvious aggravation during the reduction process, or the aggravation is within the acceptable range of the patient, the lowest effective dose can be continued for longer, such as 10 to 20mg/d. The addition of other drugs may be considered after delivery. This protocol is only a summary and hypothesis of previous cases and may be difficult to verify in a sufficient number of patients.

Most patients recover completely with oral or topical antibiotics with or without systemic glucocorticosteroids. However, 8 patients did not achieve resolution and required additional isotretinoin after delivery. The side effects of relevant drugs during pregnancy should be widely identified. Isotretinoin may be associated with congenital anomalies of the ears, face, heart, and thymus; tetracycline will cause discoloration of the teeth before 5 months of gestation when the deciduous teeth calcify, which is also linked to impaired bone growth.<sup>28–30</sup> Dapsone is associated with neonatal hemolysis and methaemoglobinaemia.<sup>31</sup>

## Conclusion

We report a case of RF with ocular involvement during pregnancy, demonstrating that oral erythromycin combined with short-term topical glucocorticoid treatment could serve as an efficient therapy. Future studies should focus on determining the standard dose and course of systemic glucocorticoid use in RF during pregnancy as well as the optimization of local treatment regimens. This will help to prevent disease progression and reduce the occurrence of complications.

## Declaration of Patient Consent

Written informed consent was obtained from the patient for publication of the details of their medical case and any accompanying images.

## Statement of Ethics

Ethical approval is not required for this study in accordance with local or national guidelines.

## Funding

There is no funding to report.

## Disclosure

The authors report no conflicts of interest in this work.

## References

1. Mantovani L, Zauli S, Virgili A, Bettoli V. Rosacea fulminans or acute rosacea? Report of 5 cases and review of the literature. *G Ital Dermatol Venereol*. 2016;151(5):553–557.
2. O’Leary PA, Kierland RR. Pyoderma faciale. *Arch Derm Syphilol*. 1940;41(3):451–462. doi:10.1001/archderm.1940.01490090003001
3. Plewig G, Jansen T, Kligman AM. Pyoderma faciale. A review and report of 20 additional cases: is it rosacea? *Arch Dermatol*. 1992;128(12):1611–1617. doi:10.1001/archderm.128.12.1611
4. Walsh RK, Endicott AA, Shinkai K. Diagnosis and treatment of rosacea fulminans: a comprehensive review. *Am J Clin Dermatol*. 2018;19(1):79–86. doi:10.1007/s40257-017-0310-0
5. Angileri L, Veraldi S, Barbareschi M. Rosacea fulminans: two case reports and review of the literature. *J Dermatol Treat*. 2021;32(1):110–113. doi:10.1080/09546634.2019.1628175
6. de Moraes e Silva FA, Bonassi M, Steiner D, da Cunha TV. Rosacea fulminans in pregnancy with ocular perforation. *J Dtsch Dermatol Ges*. 2011;9(7):542–543. doi:10.1111/j.1610-0387.2011.07616.x
7. Prieto Herman Reinehr C, Kalil CLPV, Bakos RM. Unusual case of rosacea fulminans after topical metronidazole application. *Int J Dermatol*. 2019;58(6):e117–e118. doi:10.1111/ijd.14420
8. Coutinho JC, Westphal DC, Lobato LC, Schettini AP, Santos M. Rosacea fulminans: unusual clinical presentation of rosacea. *An Bras Dermatol*. 2016;91(5 suppl 1):151–153. doi:10.1590/abd1806-4841.20164943
9. Wilkin J, Dahl M, Detmar M, et al. Standard classification of rosacea: report of the National Rosacea Society Expert Committee on the classification and staging of Rosacea. *J Am Acad Dermatol*. 2002;46(4):584–587. doi:10.1067/mjd.2002.120625
10. Gallo RL, Granstein RD, Kang S, et al. Standard classification and pathophysiology of rosacea: the 2017 update by the National Rosacea Society Expert Committee. *J Am Acad Dermatol*. 2018;78(1):148–155. doi:10.1016/j.jaad.2017.08.037
11. Ghanem VC, Mehra N, Wong S, Mannis MJ. The prevalence of ocular signs in acne rosacea: comparing patients from ophthalmology and dermatology clinics. *Cornea*. 2003;22(3):230–233. doi:10.1097/00003226-200304000-00009
12. Jansen T, Plewig G, Kligman AM. Diagnosis and treatment of rosacea fulminans. *Dermatology*. 1994;188(4):251–254. doi:10.1159/000247160
13. Park-Wyllie L, Mazzotta P, Pastuszak A, et al. Birth defects after maternal exposure to corticosteroids: prospective cohort study and meta-analysis of epidemiological studies. *Teratology*. 2000;62(6):385–392. doi:10.1002/1096-9926(200012)62:6<385::AID-TERA5>3.0.CO;2-Z
14. Østensen M, Khamashta M, Lockshin M, et al. Anti-inflammatory and immunosuppressive drugs and reproduction. *Arthritis Res Ther*. 2006;8(3):209. doi:10.1186/ar1957
15. Garayar Cantero M, Garabito Solovera E, Aguado GÁ, Valtueña J, Ruiz Sánchez D, Manchado López P. Use of permethrin in the treatment of rosacea fulminans during pregnancy: one case report. *Dermatol Ther*. 2020;33(3):e13436. doi:10.1111/dth.13436
16. Haugstvedt A, Bjerke JR. Rosacea fulminans with extrafacial lesions. *Acta Derm Venereol*. 1998;78(1):70–71. doi:10.1080/00015559850135922
17. Jarrett R, Gonsalves R, Anstey AV. Differing obstetric outcomes of rosacea fulminans in pregnancy: report of three cases with review of pathogenesis and management. *Clin Exp Dermatol*. 2010;35(8):888–891. doi:10.1111/j.1365-2230.2010.03846.x
18. Garrido-Mesa N, Zarzuelo A, Gálvez J. What is behind the non-antibiotic properties of minocycline? *Pharmacol Res*. 2013;67(1):18–30. doi:10.1016/j.phrs.2012.10.006
19. Sapadin AN, Fleischmajer R. Tetracyclines: nonantibiotic properties and their clinical implications. *J Am Acad Dermatol*. 2006;54(2):258–265. doi:10.1016/j.jaad.2005.10.004
20. Monk E, Shalita A, Siegel DM. Clinical applications of non-antimicrobial tetracyclines in dermatology. *Pharmacol Res*. 2011;63(2):130–145. doi:10.1016/j.phrs.2010.10.007
21. Ehmann LM, Meller S, Homey B. Erfolgreiche Therapie einer granulomatösen Rosacea mit Dapson. Successful treatment of granulomatous rosacea with dapsone. *Hautarzt*. 2013;64(4):226–228. doi:10.1007/s00105-013-2556-7
22. Bormann G, Gaber G, Fischer M, Marsch WC. Dapsone in rosacea fulminans. *J Eur Acad Dermatol Venereol*. 2010;15:467. doi:10.1046/j.1468-3083.2001.00325.x
23. Akhyani M, Ehsani AH, Ghiasi M, Jafari AK. Comparison of efficacy of azithromycin vs. doxycycline in the treatment of rosacea: a randomized open clinical trial. *Int J Dermatol*. 2010;47:284–288. doi:10.1111/j.1365-4632.2008.03445.x
24. Torresani C, Pavesi A, Manara GC. Clarithromycin versus doxycycline in the treatment of rosacea. *Int J Dermatol*. 1997;36(12):942–946. doi:10.1046/j.1365-4362.1997.00301.x
25. Chien AL, Qi J, Rainer B, Sachs DL, Helfrich YR. Treatment of Acne in Pregnancy. *J Am Board Fam Med*. 2016;29(2):254–262. doi:10.3122/jabfm.2016.02.150165
26. Ranpariya V, Baldwin H. Unexpected complications: a case of Rosacea fulminans in pregnancy. *Cutis*. 2021;108(1):51–54. doi:10.12788/cutis.0290
27. Tarter L, Bermas BL. Expert perspective on a clinical challenge: lupus and pregnancy. *Arthritis Rheumatol*. 2024;76(3):321–331. doi:10.1002/art.42756
28. Rosa FW. Teratogenicity of isotretinoin. *Lancet*. 1983;322(8348):513. doi:10.1016/s0140-6736(83)90538-x
29. Toaff R, Ravid R. Tetracyclines and the teeth. *Lancet*. 1966;288(7457):281–282. doi:10.1016/s0140-6736(66)92572-4
30. Cohlan SQ, Bevelander G, Tiamsic T. Growth inhibition of prematures receiving tetracyclines: a clinical and laboratory investigation on tetracycline-induced bone fluorescence. *Am J Dis Child*. 1963;105(5):453–461. doi:10.1001/archpedi.1963.02080040455005
31. Coleman MD. Dapsone: modes of action, toxicity and possible strategies for increasing patient tolerance. *Br J Dermatol*. 2010;129(5):507–513. doi:10.1111/j.1365-2133.1993.tb00476.x
32. Massa MC, Su WP. Pyoderma faciale: a clinical study of twenty-nine patients. *J Am Acad Dermatol*. 1982;6(1):84–91. doi:10.1016/s0190-9622(82)70008-8
33. Marks VJ, Briggaman RA. Pyoderma faciale: successful treatment with isotretinoin. *J Am Acad Dermatol*. 1987;17(6):1062–1063. doi:10.1016/s0190-9622(87)80498-x

34. Lewis VJ, Holme SA, Wright A, Anstey AV. Rosacea fulminans in pregnancy. *Br J Dermatol*. 2004;151(4):917–919. doi:10.1111/j.1365-2133.2004.06190.x
35. Ferahbas A, Utas S, Mistik S, Uksal U, Peker D. Rosacea fulminans in pregnancy: case report and review of the literature. *Am J Clin Dermatol*. 2006;7(2):141–144. doi:10.2165/00128071-200607020-00007
36. Cisse M, Maruani A, Bré C, Domart P, Jonville-Bera AP, Machet L. Rosacée fulminante au début d'une grossesse par fécondation in vitro et transfert d'embryons (FIVETE) [Rosacea fulminans in the early course of a pregnancy by in vitro fertilization with embryo transfer]. *Ann Dermatol Venerol*. 2008;135(10):675–678. doi:10.1016/j.annder.2008.04.015
37. Fuentelsaz V, Ara M, Corredera C, Lezcano V, Juberias P, Carapeto FJ. Rosacea fulminans in pregnancy: successful treatment with azithromycin. *Clin Exp Dermatol*. 2011;36(6):674–676. doi:10.1111/j.1365-2230.2011.04042.x
38. Haenen CC, Kouwenhoven ST, van Doorn R. Een zwangere vrouw met een rode uitslag in het gelaat [Rosacea fulminans in pregnancy]. *Ned Tijdschr Geneesk*. 2015;159:A8334.
39. Markou AG, Alessandrini V, Muray JM, Begon E, Fysekidis M. Rosacea fulminans during pregnancy. *Clin Exp Obstet Gynecol*. 2017;44(1):157–159. doi:10.12891/ceog3343.2017
40. Demir O, Tas IS, Gunay B, Ugurlucan FG. A rare dermatologic disease in pregnancy: rosacea fulminans- case report and review of the literature. *Open Access Maced J Med Sci*. 2018;6(8):1438–1441. doi:10.3889/oamjms.2018.267
41. Seol JE, Kim H, Park SH, Kim JU, Cho GJ, Moon SH. A case of rosacea fulminans in a pregnant woman. *Hong Kong J Dermatol Venereol*. 2018;26:122–126.
42. Altemir-Vidal A, Iglesias-Sancho M, Pérez-Muñoz N, Salleras-Redonnet M. Rosacea Fulminans in Pregnancy. *Actas Dermosifiliogr*. 2022;113(4):435–438. doi:10.1016/j.ad.2020.04.014
43. Bettolini L, Perantoni M, Mezzana S, et al. A case of rosacea fulminans during pregnancy. *J Dtsch Dermatol Ges*. 2023;21(11):1399–1403. doi:10.1111/ddg.15193

## Clinical, Cosmetic and Investigational Dermatology

Dovepress

### Publish your work in this journal

Clinical, Cosmetic and Investigational Dermatology is an international, peer-reviewed, open access, online journal that focuses on the latest clinical and experimental research in all aspects of skin disease and cosmetic interventions. This journal is indexed on CAS. The manuscript management system is completely online and includes a very quick and fair peer-review system, which is all easy to use. Visit <http://www.dovepress.com/testimonials.php> to read real quotes from published authors.

Submit your manuscript here: <https://www.dovepress.com/clinical-cosmetic-and-investigational-dermatology-journal>