


Diagnostics and Management Challenges of Nonpuerperal Uterine Inversions – Case Series

RM Sonny Sasotya, Andi Rinaldi, Eppy Darmadi Achmad, Aria Prasetya Ma'soem , Kania Praharsini, Efriyan Imantika, Fridya Wulandari, Nathania Nathania , Kevin Dominique Tjandraprawira

Department of Obstetrics and Gynecology, Faculty of Medicine, Universitas Padjadjaran – Dr. Hasan Sadikin General Hospital, Bandung, Indonesia

Correspondence: Kevin Dominique Tjandraprawira, Department of Obstetrics and Gynecology, Faculty of Medicine, Universitas Padjadjaran – Dr. Hasan Sadikin General Hospital, Jalan Pasteur No. 38, Bandung, 40161, Indonesia, Email kevin14007@mail.unpad.ac.id;

Purpose: Non-puerperal uterine inversion (NPUI) is a rare gynaecological entity with unknown actual incidence. It presents diagnostic and surgical challenges, due to its rarity and lack of clinical experience.

Methods: Case series of 5 NPUI cases.

Case Description: (1) A 44-year-old P3A0 presented with chronic profuse vaginal bleeding and a prolapsed pedunculated fibroid measuring 9x8x7 cm. In theatre, the pedunculated fibroid was extirpated. Haultain procedure was performed to reposition the uterus, followed by suturing the uterus. (2) A 65-year-old P4A0 presented with a solid vaginal mass, with brisk bleeding measuring 10x10x8 protruding from the introitus. In theatre, the mass was excised, followed by Kustner procedure and a subtotal hysterectomy. (3) A 46-year-old P1A1 presented with a large pedunculated fibroid, hypovolemic shock and loss of consciousness. Upon presentation, she was in shock and severely anaemic (Hb 1.4 gr/dL). In theatre, the fibroid was excised followed by uterine repositioning. A large left ovarian cyst (Ø 10 cm) was identified. A subtotal hysterectomy and left salpingo-oophorectomy were performed. (4) A 34-year-old P3A0 presented with an acute vaginal lump measuring 10x6x5 cm. She had delivered her infant 2 months prior. In theatre, a Huntington procedure was performed to reposition the uterus, followed by a total abdominal hysterectomy. (5) A 60-year-old P3A0 presented with vaginal mass measuring 10x10x8 cm and chronic profuse vaginal bleeding. In theatre, uterine inversion was diagnosed. A Haultain procedure was performed, followed by a total abdominal hysterectomy and bilateral salpingo-oophorectomy. All cases had presented with vaginal mass and bleeding to varying degrees. The degree of inversion required various procedures (eg, Kustner, Haultain, Huntington) and different forms of hysterectomy.

Conclusion: Non-puerperal uterine inversion is a difficult pathology. Management is always surgical with different types of hysterectomy performed. With conservative surgery, Kustner, Huntington and Haultain procedures are indicated according to the severity and uterine position.

Keywords: uterine inversion, hysterectomy, diagnosis

Introduction

Uterine inversion is a rare condition in which the uterus is turned inside out and often presents as a prolapsed mass through the cervix.^{1,2} Its severity varies, from an occult inversion in which only a small portion of the uterus is inverted into a complete prolapse in which the whole uterus is seen outside the vagina. Uterine inversion is traditionally classified into two: puerperal or obstetric uterine inversion AND non-puerperal or gynaecological inversion.³

Non-puerperal uterine inversion (NPUI) is a rare gynaecological entity with unknown actual incidence.¹ A small proportion of NPUI will present acutely, but it is generally a chronic disease worsening over time.¹ The presentation and complications vary, from a chronic mass in the vagina into a life-threatening emergency due to anaemia and/or septic complications of the inversion.¹ Whilst the definitive management is always surgery, techniques and approaches vary according to the degree of inversion, the aetiology and the clinical conditions of the patient.¹

Patients may present simultaneously with grave complications.⁴ Acute kidney injury preceded by a severe haemorrhagic shock is possible.⁴ Haematological abnormalities, including disseminated intravascular coagulation, may be difficult to manage due to prolonged bleeding and severe anaemia.⁴ Death is a constant possibility due to multiple organ failures.⁴

A large number of gynaecologists would admit of their lack of confidence in managing NPUIs due to NPUIs' rarity and complex surgical managements.¹ We present a collection of 5 cases spanning over a year at our centre. Their presentations varied in terms of age, aetiology, complexity, severity and management outcomes. Such diverse presentations should alert clinicians on how NPUI might present in clinical practice and the challenges associated with their management.

Case Description

We present 5 cases of nonpuerperal uterine inversions which presented their respective challenges in both their diagnoses and management. The reporting of each case follows the Surgical Case Report (SCARE) reporting guidelines.⁵ We have obtained written informed consent from the patients for the publication of their anonymised details and clinical documentations in this case series. Furthermore, this case series was exempt from an ethics review, as laid out by the local institutional protocol of our hospital.

Case #1

A 44-year-old P3A0 female presented to the A&E having been referred with uterine prolapse due to a large pedunculated fibroid. She had been complaining of a 3-month-long profuse vaginal bleeding, soaking 8–10 pads/day. A mass suddenly appeared from the vagina since 1 month prior.

Upon presentation, her vital signs were normal. A reddened mass was seen from the vaginal introitus, measuring 11x10x8 cm. Upon palpation, the mass was identified to have a stalk attached to the uterine wall. The cervical ring was intact. Bedside abdominal ultrasound confirmed the near-total eversion of the uterus along with the fibroid's stalk attached to the uterine fundus.

In theatre, a double approach surgery was chosen (Figure 1). First, the pedunculated fibroid was extirpated through a horizontal circular incision around the fibroid. A Haultain procedure was performed by making a posterior uterine incision until the cervical constriction ring was cut in half. The uterus was then repositioned back into the abdominal cavity through digital pressure on the uterine wall during laparotomy. Histology report subsequently confirmed that the mass was a pedunculated fibroid. The final diagnosis was non-puerperal uterine inversion due to pedunculated fibroid.

The patient was transferred to the ward and made an uneventful recovery. The patient was discharged 5 days post-surgery.

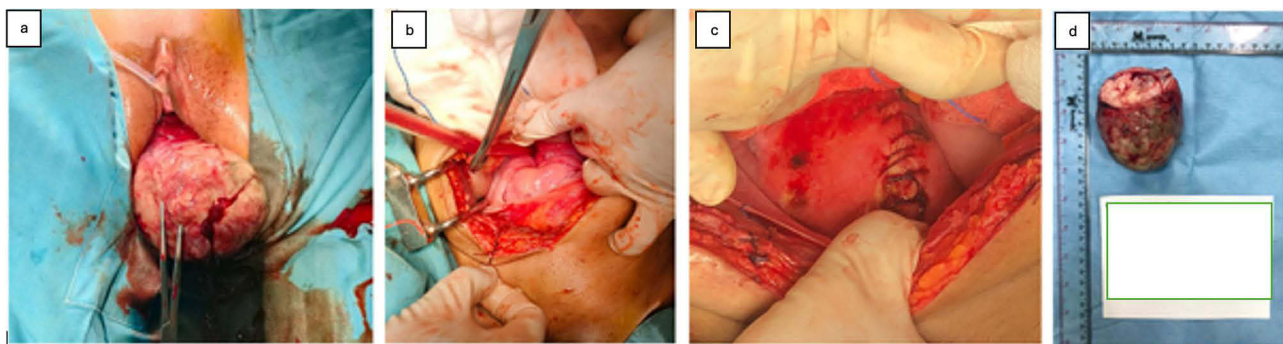


Figure 1 Surgical Details and Specimen of Case #1 (a) mass presentation at the introitus, (b and c) Pre- and post-Haultain procedure, (d) resected mass.

Case #2

A 65-year-old P4A0 presented to the A&E with a large mass from her vagina accompanied by brisk bleeding. At presentation, there was no active bleeding, and her vital signs were normal. There was a solid mass measuring 10×10×8 cm protruding from the vaginal introitus, with a palpable ring with a smooth vaginal surface. A biopsy was taken from the solid mass and the pathology report reported of non-specific inflammatory process accompanied by congestion in the prolapse uterine tissue.

She was diagnosed with non-puerperal uterine inversion due to a solid intrauterine mass. She was also notable for having hypertensive heart disease with infrequent ventricular extrasystoles due to uncontrolled stage II hypertension. A bedside echocardiography revealed dilated left atrium and left ventricle with concentric left ventricular hypertrophy, along with a diastolic dysfunction.

In theatre, the solid mass was excised and sent for frozen section, which came back for fibroid and adenomyosis (Figure 2). A Kustner procedure was performed by making a posterior incision towards the cranial portion of the uterus. A solid subserosal fibroid measuring 6 cm in diameter was identified, and myomectomy was carried out. A subtotal hysterectomy was performed, followed by the reposition of the cervical stump into the abdominal cavity. The patient was transferred to the ward and made an uneventful recovery. The patient was discharged 5 days post-surgery.

Case #3

A 46-year-old P1A1 presented to the A&E with uterine inversion and reduced consciousness since 6 hours prior. Her loss of consciousness was gradual with no limb paralysis, no projectile vomiting and no severe headache. As with her uterine inversion, her history was notable for having a protruding, lumpy vaginal mass accompanied by profuse bleeding since <24 hours prior, soaking >2 pads per day. She had been complaining of chronic abdominal pain for the past year along with difficulties in voiding. Her history was notable for having complained of a large abdominal mass that disappeared after the appearance of the vaginal mass.

Upon presentation, she was comatose, hypotensive (70/40 mmHg), tachycardic (120 bpm) and poor oxygen saturation. A large, reddish lumpy vaginal mass measuring 25×25×15 cm was present. She was severely anemic and thrombocytopenic at presentation, with a hemoglobin level of 1.4 g/dL and platelets of 35,000/uL. A bedside ultrasound

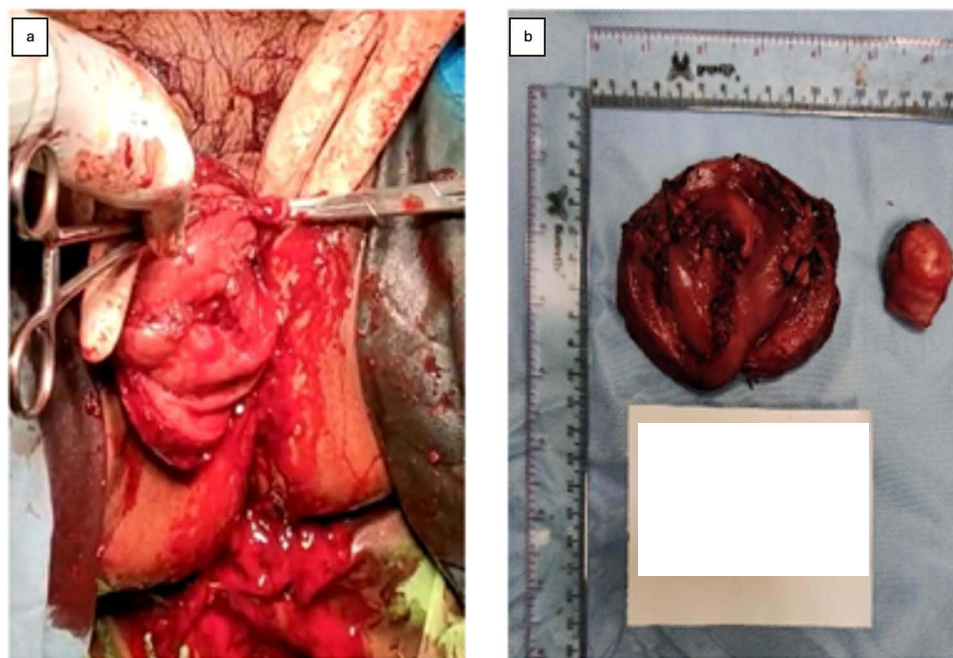

Figure 2 Surgical Detail and Specimen of Case #2. (a) presentation at the vaginal introitus, (b) resected mass (fibroid and adenomyosis).

confirmed the presence of uterus measuring 6.14×3.16 cm and a unilocular cystic ovarian mass measuring 10 cm in diameter.

She was diagnosed with hemorrhagic shock due to non-puerperal uterine inversion due to pedunculated fibroid with severe bicytopenia. She received a transfusion of 3 packed red cells. The initial plan was to operate on her after her vital signs were stable but due to profuse continuous bleeding, she underwent an emergency laparotomy. In theatre, the pedunculated fibroid was excised, and the uterus was repositioned back into the abdominal cavity (Figure 3). A laparotomy was instituted, and a large left ovarian cyst measuring 10 cm in diameter was identified. A subtotal hysterectomy and left salpingo-oophorectomy were performed. The pathology report confirmed the diagnosis of fibroid with a simple left ovarian cyst.

Unfortunately, her condition worsened in intensive care. She developed consumptive coagulopathy with subarachnoid hemorrhage. She passed away after 5 days in intensive care with a final diagnosis of multiorgan dysfunction syndrome due to disseminated intravascular coagulation and subarachnoid hemorrhage.

Case #4

A 34-year-old P3A0 presented to the A&E with a vaginal lump since 2 days prior, accompanied by profuse vaginal bleeding soaking 2 adult diapers/day. She had earlier delivered a healthy term infant weighing 3000 gram about 2 months prior. Her pregnancy and delivery were uneventful, but she confirmed that Kristeller maneuver was performed during her delivery. She denied any complaints of abdominal lumps prior to her presentation.

Upon presentation, her vital signs were normal. There was a brownish mass protruding from the vaginal introitus measuring 10×6×5 cm with no active bleeding. Her blood work was notable for anemia (Hb 8.6 gr/dL). She was diagnosed with chronic non-puerperal uterine inversion and was scheduled for a uterine repositioning surgery in the theatre.

In theatre, a non-puerperal uterine inversion was confirmed (Figure 4). The Huntington procedure was carried out by making a longitudinal incision along the posterior uterine corpus. The uterus was repositioned manually back into the abdominal cavity. A total abdominal hysterectomy was subsequently carried out. The patient was transferred to the ward and made an uneventful recovery. The patient was discharged 3 days postsurgery.

Case #5

A 60-year-old P3A0 presented to our clinic with frequent vaginal bleeding since 4 months prior, usually soaking 1–2 pads/day. She had also been complaining of a vaginal mass/lump for the past 3 years, but she had not sought treatment for it. She also had had leucorrhoea for the past 4 months.

Upon presentation, her vital signs were normal. There was a solid lump inside the vagina measuring 10x10x8 cm with no active bleeding. There was no stalk to the lump with an intact cervical ring. Her blood work revealed significant anaemia (Hb 6.6 gr/dL).

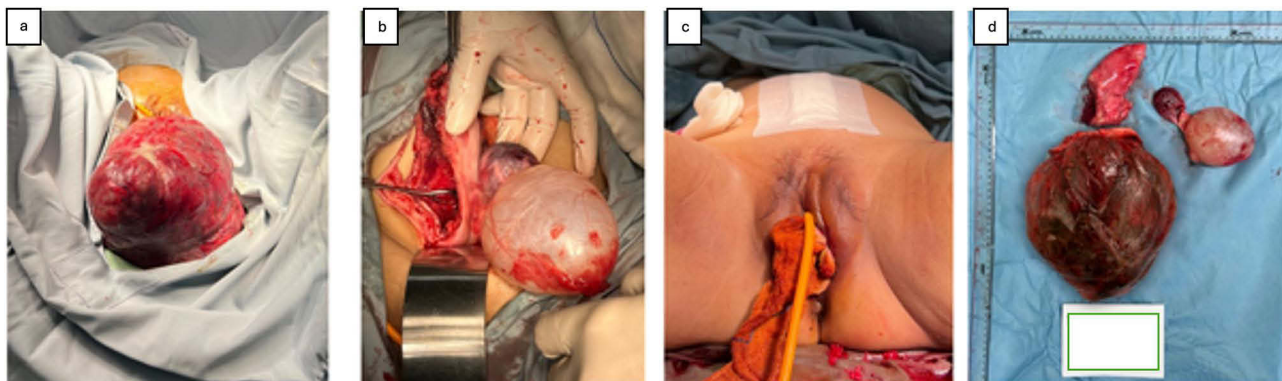


Figure 3 Surgical Detail and Specimen of Case #3, (a) large mass at the introitus, (b) ovarian cyst, (c) vaginal introitus after resection, (d) surgical specimens removed.

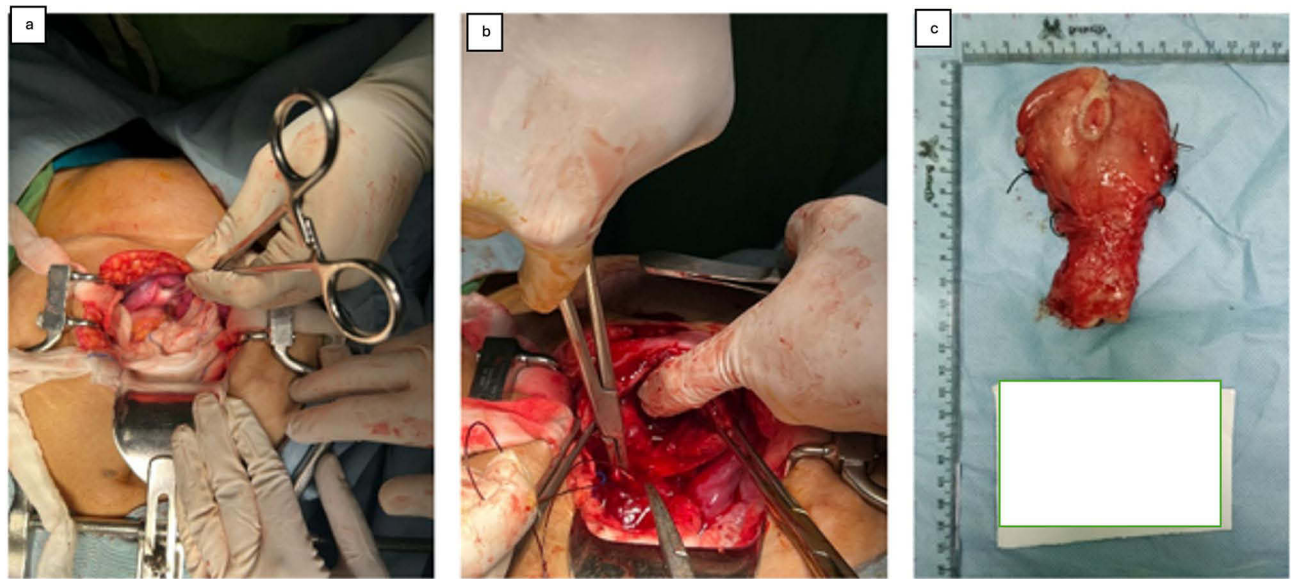


Figure 4 Surgical Detail and Specimen of Case #4. (a) The flower-vase appearance, describing an inverted uterus, (b) Huntington procedure performed, (c) uterus after hysterectomy.

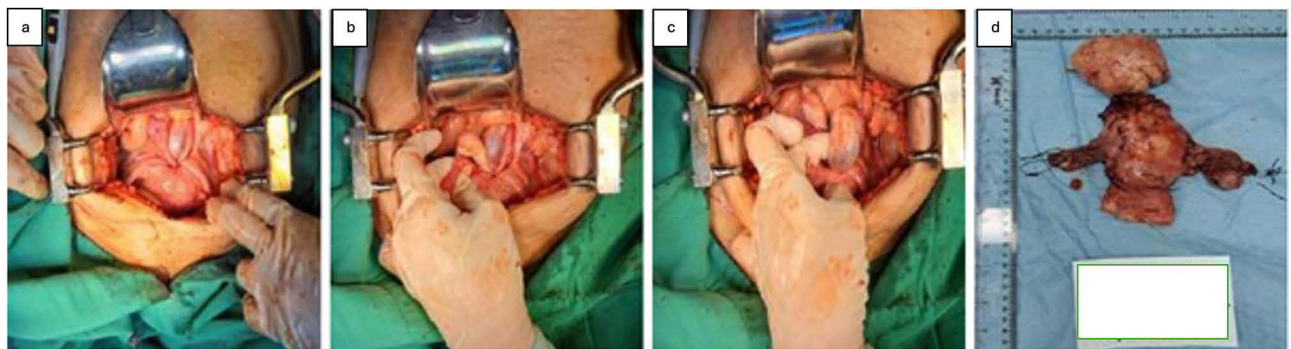


Figure 5 Surgical Details and Specimen of Case #5. (a) The flower-vase appearance at laparotomy, characteristic of inverted uterus, (b and c) Right and left ovaries were normal, (d) Fibroid (top) with uterus and bilateral adnexae (bottom).

Her ultrasound revealed a solid, well-circumscribed mass with whorl-like patterns inside the vagina. We could not identify a stalk or a feeding artery into the mass. Thus, she was diagnosed with a chronic non-puerperal uterine inversion due to suspected uterine fibroid.

In theatre, uterine inversion was confirmed through the appearance of ovaries and tubes projecting out of the indented uterine fundus (the “flower vase appearance”) (Figure 5). A Haultain incision was made on the posterior uterine corpus to allow a manual repositioning of the uterus back into the abdominal cavity. To ease the procedure, myomectomy was then performed prior to resorting to a total abdominal hysterectomy and bilateral salpingo-oophorectomy. The patient was transferred to the ward and made an uneventful recovery. The patient was discharged 3 days postsurgery.

Discussion

Uterine inversion is divided into two major classifications: puerperal and non-puerperal.³ Non-puerperal uterine inversion (NPUI) is a rare gynecological entity with unknown incidence. Establishing a timely diagnosis and proper management may be challenging as described by the various presentations and their different severity levels.

In terms of their history and clinical presentation, most patients presented to our center with a history of vaginal bleeding, which varied from acute to chronic (4 months prior) bleeding. The sudden onset of profuse vaginal bleeding

can cause an immediate blood loss and stimulate a parasympathetic stimulation. One such patient presented with refractory hypovolemic shock and severe anaemia (Hb: 1.4 gr/dL) due to profuse vaginal bleeding in the past 24 hours. Our patients' presentations fit with the current literature on NPUI, with bleeding as one of the most common findings in presentation. It also fits the literature in which the bleeding might have been brisk but could also be profuse and life-threatening. Unfortunately, our case was not unique in that Singh et al also reported a similar case with a hypovolemic shock due to a stage 2 uterine inversion.⁶

Another common complaint we observed was a solid protruding vaginal mass, with the mass averaging 10 cm in diameter. From the literature search over the past 13 years, the largest vaginal mass was from Indonesia in 2023. Kurniawati et al reported a woman with a 20×20 cm mass protruding from vagina and was diagnosed with a chronic uterine inversion due to leiomyoma.⁷ As in our case, such large mass may be mistaken for a pedunculated fibroid during a vaginal examination. Whilst a definitive diagnosis may have to wait until surgery, suspicion towards NPUI may be raised when an abdominal palpation along with ultrasound cannot locate a uterine body in its normal position. All of our patients' clinical presentations were a combination of a protruding vaginal mass along with the inability to locate the uterine fundus through abdominal palpation.

Lower abdominal pain was also described as another complaint in NPUI. One such patient came with a complaint of intermittent abdominal pain for the past year and difficulty urinating. The abdominal discomfort may be caused by the urinary retention, and patients may require periodic catheterisation. Dysmenorrhoea and dyspareunia were also found but were less common.⁸

Herath et al have classified NPUI into four groups according to the degree of the inversion (Table 1). All of our presented cases were stages 3 and 4. A summary of our patients is presented in Table 2.

We performed a literature review of the published case reports on NPUI over the past decade (Table 3).^{6,7,9–26} We searched through PubMed(MEDLINE) and Google Scholar using the advanced search method combining the following keywords: “hysterectomy”; “uterine inversion”; “nonpuerperal” and “case report”. We used the Boolean operators “OR”

Table 1 Stages of Uterine inversion¹

Stage	Description
1	Inversion of the uterus is intrauterine or incomplete. e fundus remains within the cavity
2	A complete inversion of the uterine fundus through the fibromuscular ring of the cervix.
3	Total inversion, whereby the fundus protrude through the vulva
4	The vagina is also involved with complete inversion through the vulva along with the inverted uterus

Table 2 Resumé of Cases

No	Age	Parity	Presentation	Mass size (cm)	Surgical approach	Histopathological result
1	44	P3	Vaginal bleeding	9×8×7	Haultain	Pedunculated fibroid
2	65	P4	Vaginal bleeding	10×10×8	Kustner, followed subtotal HT	Fibroid and adenomyosis
3	46	P1	Hypovolemic shock, vaginal bleeding	10 cm large left ovarian cyst	Excised pedunculated fibroid, uterine repositioning, subtotal hysterectomy and left SO	Pedunculated fibroid
4	34	P3	Vaginal bleeding	10×6×5	Huntington, followed by TAH	Pedunculated fibroid
5	60	P3	Vaginal bleeding	10×10×8	Haultain, TAH BSO	Fibroid and adenomyosis

Table 3 Summary of the Literature

No	References	Age (years)	Parity	Presentation	Mass size (cm)	Surgical approach	Histopathological result
1	Kurniawati et al ⁷	65	P3	Vaginal bleeding, vaginal mass	20 cm	Spinelli procedure followed by an abdominal hysterectomy	Leiomyoma with myxoid degeneration
2	Asefa et al ⁹	54	P2	Painless, enlarged vaginal mass	7 cm	Abdominal hysterectomy	N/A
3	Tolcha et al ¹⁰	28	P1	Vaginal bleeding	N/A	Haultain procedure	N/A
4	Li et Al ¹¹	27	P0	Vaginal bleeding, urinary retention, large necrotic vaginal mass, foul vaginal discharge	N/A	Haultain procedure	Embryonal rhabdomyosarcoma with positive immunostaining for myogenin and myogenic differentiation 1 (Myo-D1). D
5	Kesrouani et al ¹²	47	P4	Vaginal bleeding	7 cm	Hysterectomy	Leiomyoma
6	Modares et al ¹³	48	P2	Vaginal bleeding	17 cm	Hysterectomy	Leiomyoma
7	Singh et al ⁶	35	P3	Vaginal bleeding, vaginal mass	6 cm	Haultain procedure	N/A
8	Garg et al ¹⁴	22	P1	Vaginal bleeding, painless mass	5 cm	Haultain procedure	N/A
9	Merviel et al ¹⁵	38	P1	Vaginal mass, vaginal bleeding	6.5 cm	Huntington procedure	Adenomyosis
10	Al Qahtani et al ¹⁶	31	P0	Vaginal bleeding	12 cm	Fibroid extirpation	N/A
11	Lima et al ¹⁷	53	P2	Irregular vaginal bleeding	6 cm	Huntington procedure followed by total abdominal hysterectomy bilateral salpingo-oophorectomy (TAH BSO)	Leiomyoma
12	Sujanendra Mishra ¹⁸	36	P5A2	Lower abdominal pain, severe vaginal bleeding	N/A	Haultain procedure followed by TAH	Chorionic villi with degeneration and necrosis
13	Arpita et al ¹⁹	38	P4	Acute urinary retention, lower abdominal pain and vaginal bleeding	7 cm	Huntington procedure, followed by TAH	N/A
14	Chawla et al ²⁰	56	Post menopausal	Intermittent vaginal bleeding and vaginal discharge 4 years	7 cm	Huntington procedure, followed by TAH BSO	Adenofibroma of the uterus
15	Birge et al ²¹	17	P1	Abdominal pain, vaginal bleeding	N/A	Haultain procedure	N/A
16	Shivanagappa et al ²²	28	P0	Vaginal bleeding	12 cm	Total abdominal hysterectomy	Leiomyoma
17	Umeononihu et al ²³	51	P7	Vaginal bleeding, foul vaginal discharge	N/A	Total abdominal hysterectomy	Leiomyoma
18	Minakshi et al ²⁴	21	P1	Vaginal bleeding	10 cm	Haultain procedure	N/A
19	Kilpatrick et al ²⁵	56	P3	Vaginal mass, vaginal bleeding	10 cm	Haultain procedure followed by TAH BSO	Leiomyoma
20	Dr Chris Opoku Fofie ²⁶	42	P4	Vaginal bleeding, vaginal mass, abdominal pain	N/A	Total abdominal hysterectomy	N/A

and “AND” to combine the above keywords in our search, which was limited between 1 January 2014 and 31 March 2024. Furthermore, we also explored the reference list of previous publications to discover additional case reports and/or publications. In summary, the presentation was diverse. The ages at presentation ranged from 17 to 65 and whilst the majority were parous, 3 patients were nulliparous. Most patients presented with a vaginal bleeding and/or a vaginal mass, which fits the current literature. Whilst the description of the mass was not present in a number of cases, of the available records they described masses ranging from 5 cm up to 20 cm in diameter. A number of surgical approaches were used, with the Haultain procedure being the most common. Finally, the histopathology report came back mostly with leiomyoma, again fitting with the current literature.

In terms of etiology and diagnosis, the commonest known cause of NPUI is leiomyoma, followed by polyp, pelvic tumor and malignancy.^{1,27} The diagnosis of NPUI is determined with comprehensive history taking, careful inspection and effective imaging modalities. Lima et al suggest that even though physical examination is important, the right imaging modalities play a crucial role in determining the surgical approach.¹⁷ Ultrasonography (USG), Magnetic Resonance Imaging (MRI), and Computed Tomography (CT Scan) are the options for imaging modalities to provide an accurate diagnosis. In our case series, most patients were diagnosed by physical examination and ultrasonography. Ultrasound examination should be the initial modality chosen to investigate the diagnosis due to its availability and simplicity. The findings in ultrasound exam were different according to the stages of uterine inversion. In incomplete uterine inversion (stage 1–2), the characteristic finding is a “Y”-shaped uterine cavity, while a “U”-shaped cavity is found in complete uterine inversion (stage 3–4).¹ MRI may provide accurate imaging as to determine if an emergency evacuation of the mass is required. Qahtani et al successfully used MRI to solve this conundrum.¹⁶ When ultrasound findings are inconclusive or uncharacteristic, MRI is considered superior in diagnosis of NPUI. In cases of NPUI due to a pedunculated fibroid, a sagittal view in MRI may conclusively demonstrate the location of the fibroid pedicle. In cases of malignancy, MRI assists with lymph node imaging. Conflicting opinions are present with regard to CT Scan benefits in NPUI. Herath et al said that CT Scan has not been very useful in the diagnosis of NPUI. Meanwhile, Modares et al mentioned that CT Scan accurately confirmed the diagnosis NPUI.¹³ To prevent a misdiagnosis, good clinical examination supplemented with the correct imaging modalities should be more than adequate.

Previously, the gold-standard for NPUI diagnosis was through diagnostic laparoscopy. During laparoscopy, the characteristic flower vase pattern would be observed (Figure 6). Arpita et al stated that laparoscopy would be useful for the diagnosis, but no longer a prerequisite.¹⁹ In our case series, the flower vase appearance was observed in theatre (Figure 7). Flower vase pattern was an appearance of both round ligaments and bilateral tubes projecting inside the uterine fundus and both ovaries touching each other.^{1,19}

The priority in managing NPUI is the primary survey when the patients come. Resuscitation and transfusion are necessary for some patients with hypovolemic shock or severe anemia. Giving pain relief and antibiotics is required as clinically indicated. After the patients are hemodynamically stable, the next important thing is investigating the etiology, diagnosis and determining the appropriate approach.^{1,16,19}

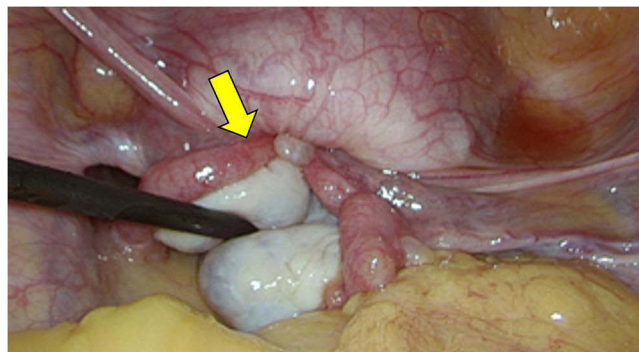


Figure 6 Flower vase pattern during laparoscopic. (reproduced from Arpita et al.¹⁸)

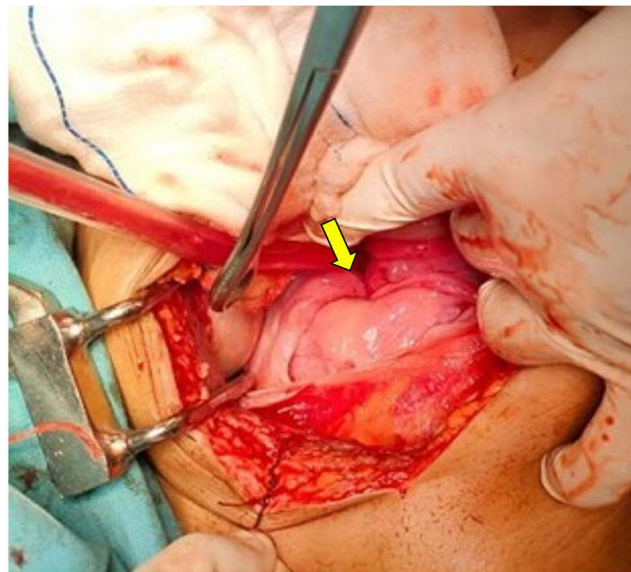


Figure 7 Flower vase pattern during abdominal laparotomy (authors' personal collection).

Surgery is the mainstay management of NPUI. The surgery may be through an abdominal, vaginal or a combination of both approaches. About 24 (8%) surgeons choose vaginal approach, 65 (48.8%) surgeons choose abdominal approach, and 36 (27.1%) surgeons choose combined approach. There are 8 (6%) surgeons that prefer laparoscopic approach.¹ Surgeries method with vaginal approach are Spinelli and Kustner's methods. In Spinelli's operation, the cervix is incised in the middle and followed in the anterior wall of the inverted uterus. The uterus then was repositioned, and the vagina and cervix were repaired. Similar to Spinelli's operation, in Kustner's operation the inverted uterus was incised in the posterior wall. Surgeries method with abdominal approach are Huntington and Haultain. Huntington technique is used to reposition the uterus by gently tracting the round ligaments with Allis or Babcock's forceps to pull the inverted uterine fundus. Gentle pressure vaginally can be done to help correct the inversion. In a case where the uterus was tightly inverted, Huntington technique may fail, and Haultain technique can be considered. In Haultain technique, the constriction ring is sagittally cut on the posterior side, followed by gradual traction on the inverted tissues. The posterior side is then repaired.^{1,19} However, a preference for either approach may not be possible as clinically indicated. The advantages of abdominal technique are minimum incision of the uterus and the convenience in suturing and controlling the bleeding during operation. The surgery varies from conservative to radical management. The candidates for conservative surgery are a patient with stable hemodynamic and whose mass can be manually reduced. One of the conservative surgeries is repositioning the uterus (malignancies are excluded for this action). If repositioning is failed, the last option is hysterectomy (except in women who desire fertility).^{1,27}

In this case series, we used more than one technique to treat NPUI. In case one and five, we used Haultain procedure to reposition the uterus. In case two, we used Kustner procedure followed by a subtotal hysterectomy. In case three, we performed a subtotal hysterectomy and left salpingo-oophorectomy due to a large left ovarian cyst. In case four, we used a Huntington procedure followed by a total abdominal hysterectomy. Despite our cases presenting somewhat similarly to a protruding vaginal mass, individualized surgical plan necessitated different approaches and different techniques dictated by individual cases. In addition, the consideration of abdominal and vaginal approach or a combination of both depends on some factors, including the operators' skill, the patient's condition, the type of uterus and the presence of other underlying diseases. The risk and benefit of each approach should be weighed carefully. Some challenges persist in managing NPUI. They are rare, therefore the exposure of gynecologists to such cases is less common. There is no widely accepted diagnostic criteria available as well as the treatment approaches. Some gynecologists refer the patients to a center with urogynecologist which can cause delays in the treatment or worsening patient's condition. Another

challenges will arise when the conservative management is not possible and radical method, as in hysterectomy, is required.

The challenges described above are most pertinent to patient #3. She had presented late with loss of consciousness due to severe anemia and refractory shock. She had complained of chronic pain for the past year but had not undergone any consultation. At presentation, the vaginal mass was large in excess of 25 cm in diameter. Her presentation was both severe and delayed. Despite aggressive fluid resuscitation and blood transfusion along with aggressive surgical management, her prolonged anemia led to multiple organ dysfunction and refractory hematological abnormalities.²⁸ This was evident from her consumptive coagulopathy (disseminated intravascular coagulation) that could not be corrected postoperatively.²⁸ This was a terminal event, eventually culminating in her death.²⁸

Conclusion

Non-puerperal uterine inversion is a complicated and difficult pathology. A vaginal lump with a sudden onset of vaginal bleeding is one of the most common presentations. Outcome depends on vigilant clinical judgment and aggressive initial management. Definite management is always surgical with different types of hysterectomy subsequently performed. If fertility preservation is indicated, Kustner, Huntington and/or Haultain procedures are indicated according to the severity and uterine position.

Take Home Message

- Non-puerperal uterine inversion (NPUI) is a rare and difficult gynaecological problem
- Etiology of NPUI should be established, most often a pedunculated fibroid
- Management is always surgical with a variety of approaches, including Haultain, Kustner and Spinelli employed
- Hysterectomy is often required

Acknowledgments

The authors wish to thank the brilliant operating theatre team for their assistance in managing the patients.

Disclosure

The authors report no conflicts of interest in this work.

References

1. Herath RP, Patabendige M, Rashid M, Wijesinghe PS. Nonpuerperal Uterine Inversion: what the Gynaecologists Need to Know? *Obstet Gynecol Int.* 2020;2020:8625186. doi:10.1155/2020/8625186
2. Gowri V. Uterine inversion and corpus malignancies: a historical review. *Obstet Gynecol Surv.* 2000;55(11):703–707. doi:10.1097/00006254-200011000-00022
3. Jones HW Jr. Non-puerperal inversion of the uterus. *Am J Surg.* 1951;81(5):492–495. doi:10.1016/0002-9610(51)90268-1
4. Thakur M, Thakur A. Uterine Inversion. 2022. In: *StatPearls [Internet]*. Treasure Island (FL): StatPearls Publishing.
5. Agha RA, Franchi T, Sohrabi C, et al. The SCARE 2020 Guideline: updating Consensus Surgical CAse REport (SCARE) Guidelines. *Int j Surg.* 2020;84:226–230. doi:10.1016/j.ijsu.2020.10.034
6. Singh A, Ghimire R. A Rare Case of Chronic Uterine Inversion Secondary to Submucosal Fibroid Managed in the Province Hospital of Nepal. *Case Repo Obstetr Gynecol.* 2020;2020:6837961. doi:10.1155/2020/6837961
7. Kurniawati E, Masteryanto HM, Hardianto G, Paraton H, Hadi THS. A 63-Year-Old Postmenopausal Woman with Uterine Inversion Associated with a Submucosal Geburt Fibroid Successfully Treated by Surgical Reversal Using the Spinelli Procedure. *Am J Case Rep.* 2023;24:e938390.
8. Uomoto M, Tokinaga-Uchiyama A, Kobayashi N, Okuda M. Uterine perforation during uterine repositioning on nonpuerperal uterine inversion by delivery of a large fibroid: a case report. *Clin Case Rep.* 2023;11(8):e7810. doi:10.1002/ccr3.7810
9. Asefa E, Abdulhay F, Dhugasa D. Chronic Uterine Inversion in 54 Year Old Woman: case Report. *Int Med Case Rep J.* 2023;16(null):627–631. doi:10.2147/IMCRJ.S411300
10. Tolcha FD, Dale TB, Anbessie TT. Chronic uterine inversion presenting with severe anemia 7 years after a home delivery and the subsequent successful pregnancy: a case report. *J Med Case Rep.* 2023;17(1):278. doi:10.1186/s13256-023-04012-x
11. Li K, Davis G, Wittenberg C, Abidi A. Rhabdomyosarcoma-Induced Uterine Inversion. *Case Rep Obstet Gynecol.* 2022;2022:1361803. doi:10.1155/2022/1361803
12. Kesrouani A, Cortbaoui E, Khaddage A, Ghossein M, Nemr E. Characteristics and Outcome in Non-Puerperal Uterine Inversion. *Cureus.* 2021;13(2):e13345. doi:10.7759/cureus.13345
13. Modares M, Sarrazin J. Nonpuerperal vaginal hemorrhage secondary to complete uterine inversion: a case report. *Radiol Case Rep.* 2021;16(3):543–546. doi:10.1016/j.radcr.2020.12.045

14. Garg P, Bansal R. Unusual and delayed presentation of chronic uterine inversion in a young woman as a result of negligence by an untrained birth attendant: a case report. *J Med Case Rep.* 2020;14(1):143. doi:10.1186/s13256-020-02466-x
15. Merviel P, Guilbert S, Abou Hassan C, et al. Nonpuerperal uterine inversion due to adenomyosis: a case report and a literature review. *Clin Case Rep.* 2019;7(12):2420–2424. doi:10.1002/ccr3.2530
16. Al Qahtani NH. Chronic incomplete non-puerperal uterine inversion due to huge submucous fibroid: diagnosis and management. *BMJ Case Rep.* 2018;2018. doi:10.1136/bcr-2017-223901
17. Lima T, Sousa R, Pinheiro A, Almeida A. Chronic non-puerperal uterine inversion in an asymptomatic woman. *J Obstet Gynaecol.* 2018;38(6):880–881. doi:10.1080/01443615.2017.1399113
18. Mishra S. Chronic Uterine Inversion Following Mid-Trimester Abortion. *J Obstet Gynaecol India.* 2018;68(4):320–322. doi:10.1007/s13224-017-1040-1
19. De A, Nigam A, Jain A, Gupta N, Tripathi R. Laparoscopic Management of Nonpuerperal Uterine Inversion. *J Minim Invasive Gynecol.* 2019;26(5):981–985. doi:10.1016/j.jmig.2018.12.014
20. Chawla L, Vatsa R, Roy KK, et al. Uterine Adenofibroma: an Unusual Cause of Nonpuerperal Uterine Inversion in Postmenopausal Female. *J Midlife Health.* 2017;8(2):95–97. doi:10.4103/jmh.JMH_27_17
21. Birge O, Tekin B, Merdin A, Coban O, Arslan D. Chronic Total Uterine Inversion in a Young Adult Patient. *Am J Case Rep.* 2015;16:756–759. doi:10.12659/AJCR.894264
22. Shivanagappa M, Bhandiwad A, Mahesh M. A case of acute on chronic uterine inversion with fibroid polyp. *J Clin Diagn Res.* 2013;7(11):2587–2588. doi:10.7860/JCDR/2013/6516.3622
23. Umeononihu OS, Adinma JI, Obiechina NJ, et al. Uterine leiomyoma associated non-puerperal uterine inversion misdiagnosed as advanced cervical cancer: a case report. *Int J Surg Case Rep.* 2013;4(11):1000–1003. doi:10.1016/j.ijscr.2013.08.011
24. Minakshi S, Shivani A, Arshad A. Neglected puerperal inversion of the uterus: ignorance makes acute a chronic form. *Pan Afr Med J.* 2012;12:89.
25. Kilpatrick CC, Chohan L, Maier RC. Chronic nonpuerperal uterine inversion and necrosis: a case report. *J Med Case Rep.* 2010;4:381. doi:10.1186/1752-1947-4-381
26. Fofie CO, Baffoe P. Non-puerperal uterine inversion: a case report. *Ghana Med J.* 2010;44(2):79–81. doi:10.4314/gmj.v44i2.68889
27. Shasindran R, Dharshini N, Aruku N, Sasikala AJC Exploring Non-puerperal Uterine Inversion: a Case Series. 2024.
28. Costello RA, Leslie SW, Nehring SM. Disseminated Intravascular Coagulation. 2024. In: *StatPearls [Internet]*. Treasure Island (FL): StatPearls Publishing.

International Journal of Women's Health

Dovepress

Publish your work in this journal

The International Journal of Women's Health is an international, peer-reviewed open-access journal publishing original research, reports, editorials, reviews and commentaries on all aspects of women's healthcare including gynecology, obstetrics, and breast cancer. The manuscript management system is completely online and includes a very quick and fair peer-review system, which is all easy to use. Visit <http://www.dovepress.com/testimonials.php> to read real quotes from published authors.

Submit your manuscript here: <https://www.dovepress.com/international-journal-of-womens-health-journal>