

# Lung and Cutaneous Abscesses in a Patient with Ulcerative Colitis: A Case Report and Literature Review

Jing Ren<sup>1,\*</sup>, Jiahua Zhou<sup>2,\*</sup>, Qinhui Wang<sup>1,\*</sup>, Linna Liu<sup>1</sup>, Wei Liu<sup>3</sup>, Shan Wang<sup>4</sup>, Yao Zheng<sup>1</sup>, Li Luo<sup>1</sup>, Qi Yang<sup>1</sup>

<sup>1</sup>Department of Pharmacy, The Second Affiliated Hospital of Air Force Medical University, Xi'an, Shaanxi, People's Republic of China; <sup>2</sup>Department of Neurosurgery, The Second Affiliated Hospital of Air Force Medical University, Xi'an, Shaanxi, People's Republic of China; <sup>3</sup>Department of Orthopedics, The Second Affiliated Hospital of Air Force Medical University, Xi'an, Shaanxi, People's Republic of China; <sup>4</sup>Department of Pharmacy, New York University Langone Hospital – Long Island, Mineola, NY, USA

\*These authors contributed equally to this work

Correspondence: Qi Yang; Li Luo, Department of Pharmacy, The Second Affiliated Hospital of Air Force Medical University, Xi'an, Shaanxi, 710038, People's Republic of China, Tel +86 15829673096, Fax +86 029-84777154, Email 376230719@qq.com; luolixueshu@163.com

**Abstract:** Aseptic abscess (AA) syndrome is a rare inflammatory disorder often associated with inflammatory bowel disease (IBD). Cases of IBD-associated AA have been reported in Japan, India, and Canada, but rarely in China. Herein, we present the case of a Chinese patient with IBD-associated AAs and review the literature on AA with underlying IBD. We report the case of a 48-year-old male patient with multiple AAs on his left hand and lungs who was successfully treated with prednisone. He had undergone cutaneous abscess incision and drainage twice in the previous 2 years. The patient presented to our hospital with ulcerative colitis and pain in the dorsum of the left hand. Pus from his hand and blood cultures revealed sterile cutaneous abscesses. Chest computed tomography examination during hospitalization revealed a lung abscess. The AA was unresponsive to cefotiam or cefoperazone-sulbactam. The patient's left hand and lung conditions did not improve until prednisone was administered. The patient was followed up as an outpatient for 3 months and recovered without any clinical symptoms. We retrieved 17 cases of IBD-associated AA from the literature. None of the patients showed evidence of infection and failed antibiotic treatment, and all improved with corticosteroid use. AA may be an extra-intestinal manifestation of IBD. Effective medications include corticosteroids and immunosuppressive agents. This case may increase the awareness of AA and aid in early identification.

**Keywords:** aseptic abscess, inflammatory bowel disease, ulcerative colitis, extra-intestinal manifestation

## Introduction

Abscesses are usually caused by a bacterial infection associated with a previous trauma or surgery or may be secondary to bloodstream infection. Aseptic abscesses (AA) are characterized by deep, sterile lesions comprising neutrophils that develop because of systemic inflammatory diseases.<sup>1</sup> AA is an extra-intestinal manifestation (EIM) of inflammatory bowel disease (IBD), including Crohn's disease (CD) and ulcerative colitis (UC).<sup>2</sup> AA shares a similar pathological picture with neutrophilic dermatosis, showing polymorphonuclear leukocyte infiltrates and sterile abscesses. Diagnosis is based on the presence of deep abscesses with negative cultures, serological tests, and failure of antibiotic therapy. AAs are mostly found in the liver, spleen, and skin, and steroid treatments are generally effective.<sup>3</sup> IBD-associated AAs are rare conditions, reported largely in European literature.<sup>4</sup> In this study, we present the case of a Chinese patient with multiple AAs on his left hand and lungs and review the literature on AA with underlying UC. This study aims to raise awareness of the association between AA and inflammatory bowel disease (IBD).

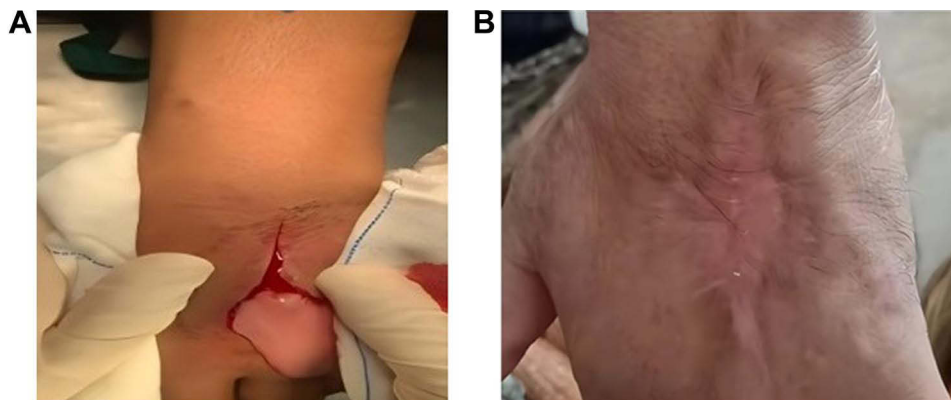
## Case Presentation

A 48-year-old man with a 10-day history of pain in the dorsum of the left hand was referred to our hospital. The patient's family history was unremarkable. He had a 16-year history of pan-colonic UC and was irregularly treated with mesalazine (3.6 g/day). The patient's condition was unstable, with occasional abdominal pain and bloody diarrhea (partial Mayo score, 5). Two years prior, the patient underwent abscess incision drainage due to dermapostasis in the lower segment of the sternum. Two months prior, abscess incision and drainage were performed because of a cutaneous abscess in his left leg. The patient recovered postoperatively.

Physical examination on admission was unremarkable, except for dorsal pain in the left hand, edema, and redness. A round swollen bulge of  $5.0 \times 6.2 \times 3.2$  cm was seen on the back of the left hand. Laboratory findings showed an elevated white blood cell (WBC) count of  $14.43 \times 10^3/\mu\text{L}$  (normal range,  $3.2\text{--}9.7 \times 10^3/\mu\text{L}$ ), with counts of neutrophils at  $10,830/\mu\text{L}$ , lymphocytes at  $1440/\mu\text{L}$ , monocytes at  $1.6 \times 10^3/\mu\text{L}$ , elevated levels of C-reactive protein (CRP) at  $84.06$  mg/dL (normal range,  $<10$  mg/dL), and elevated levels of erythrocyte sedimentation Rate (ESR) at  $98$  mm/hr.

The patient underwent an incision of the cutaneous abscess on the left dorsal hand on the first night of admission. A creamy pink liquid outflow was observed when the abscess was incised (Figure 1A). Cefotiam (2 g, intravenous [IV], every 8 h) was administered. Five days after the operation, the patient developed a fever Doppler ultrasonography revealed an abscess in the left hand and soft tissue formation in the palm. Two days later, re-debridement suture-vacuum sealing drainage-vacuum aspiration suction was performed after dorsal left-hand abscess surgery. Nine days after the second operation, the patient's fever persisted ( $t_{\text{max}}$   $39^\circ\text{C}$ ), and pus-like discharge persisted from his left-hand ulcer. Chest computed tomography (CT) revealed a mass-like hyperdense shadow of  $3.7 \times 2.5$  cm in the lower lobe of the right lung; this was considered to be a lung abscess. Pus and blood cultures were negative. Cefotiam was changed to cefoperazone-sulbactam (3 g, IV, every 12 h), which has a broader antimicrobial spectrum. The patient simultaneously presented with abdominal pain and diarrhea. A stool routine test revealed positive occult blood. Further, white blood cells, red blood cells, and pus cells were noted in the stool. A multidisciplinary evaluation was conducted, and the gastroenterologist confirmed active UC. Mesalazine (4 g/day), *Saccharomyces boulardii* (500 mg, per os [p.o.], every 12 h), and compound glutamine enteric capsules (two capsules, p.o., every 12 h) were added after multidisciplinary consultation. Twelve days after the second surgery, purulent secretions were still present on the wound, and two small cutaneous abscesses developed on his right leg. Repeated cultures of the blood, pus, and secretions were negative for aerobic and anaerobic bacteria, fungi, and mycobacteria. The patient was diagnosed with UC-associated AAs after a multidisciplinary consultation.

On the 26th day after admission, prednisone acetate (40 mg, p.o., qd) was initiated, and cefoperazone-sulbactam was discontinued. The patient's temperature gradually returned to normal, and the wound exudate was significantly reduced. Levels of C-reactive protein (CRP) and erythrocyte sedimentation rate (ESR) decreased gradually. On the 31st day after admission, levels of CRP decreased to the normal range (Table 1). Thirteen days after oral administration of prednisone acetate, the left surgical area was completely dry. The skin defects on the dorsum of the left hand were approximately 3–4 cm



**Figure 1** Photographs of the dorsum of the left hand. (A) Left hand of the patient during the operation on the first day of admission. (B) Left hand of the patient 3 months after discharge.

**Table 1** Changes in Inflammatory Indicators: CRP and ESR

Day	CRP (mg/L)	ESR (mm/hr)
d2	84.06	98
d13	111.71	97
d20	149.98	93
d29	17.7	91
d31	6.11	39

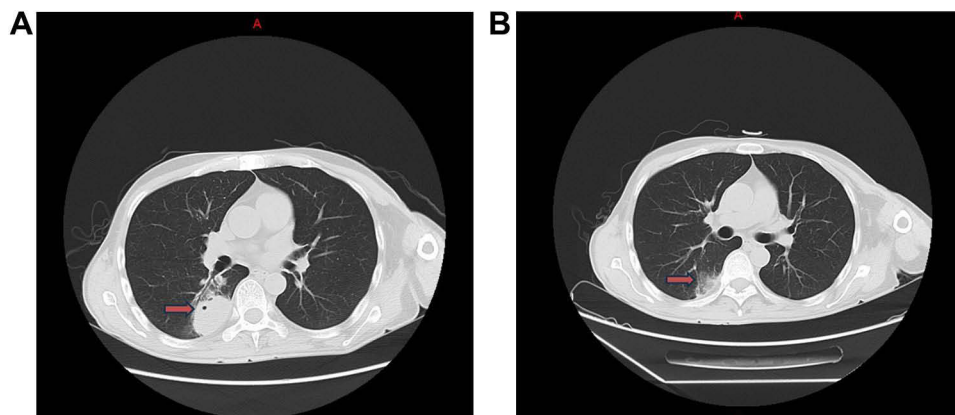
**Abbreviations:** CRP, C-reactive protein; ESR, erythrocyte sedimentation rate.

in size. Repeated chest CT suggested that the lesion in the lower lobe of the right lung was smaller than that observed previously (Figures 2A and B). The patient was then discharged. The prednisone acetate dose was tapered and withdrawn after 3 months. The patient was followed up as an outpatient and was free of any clinical symptoms 3 months after discharge (Figure 1B).

## Literature Review

An online database search of PubMed, Embase, and Web of Science and checking of the reference lists of all retrieved articles were performed for articles published between 2010 and 2023. The search terms were “sterile abscess”, “ulcerative colitis”, “aseptic abscess”, and “inflammatory bowel disease”. Full-text articles were retrieved if available. Non-English articles for which translations could not be acquired were excluded from the literature review. Sixteen articles describing 17 cases of IBD-associated abscesses were identified during the literature search. The clinical characteristics of the patients are summarized in Table 1. Of the 17 patients, approximately 58% (n=10) were female and 42% (n=7) were male. The mean age of patients with AA at the time of diagnosis was 41 years, which was higher than the ages reported previously.<sup>5</sup> IBD preceded AA diagnosis in 70% (n=12) of the patients, was concomitant in 23% (n=4), and subsequently occurred in 6% (n=1). With respect to the IBD type, 53% had underlying UC, 41% had underlying CD, and 6% had indeterminate IBD. Regarding initial symptoms, 76% of the patients presented with fever (n=13), 53% with abdominal pain (n=9), and 29% with weight loss (n=5). The most common AA locations were the spleen (n=8), liver (n=4), nasal septal (n=2), lung (n=2), renal (n=1), pancreas (n=1), arm (n=1), muscle (n=1), hand (n=1), ankle (n=1), subconjunctival (n=1), sternum (n=1), and renal (n=1). Multiple abscesses were found in seven patients. In our case, the patient developed an abscess in the left hand, lung, and right leg.

Regarding treatment, 41% of the patients (n=7) underwent abscess incision, 23% (n=4) underwent splenectomy, and (n=6) did not receive surgical treatment. Regarding medication, 88% of the patients received antibiotics (n=15), all of



**Figure 2** Chest CT examination. (A) Chest CT image 16 days after admission. (B) Chest CT image 11 days after receiving oral prednisone. **Abbreviation:** CT, computed tomography.

whom were unresponsive. Approximately 88% of the patients responded to corticosteroids (n=15), and 41% (n=7) received additional immunosuppressive therapy with infliximab (n=5), rituximab (n=1), and adalimumab (n=1). One patient received only infliximab, and the others received only ustekinumab without corticosteroids. Relapse was reported in 17% (n=3) of the patients because of inappropriate treatment or discontinuation of the effective drug. None of the patients experienced a relapse with prednisone or immunosuppressive maintenance therapy during the observation period (Table 2). In our case, the patient came to our hospital for a left-hand abscess, and he developed a lung abscess during hospitalization. This case suggests that active or uncontrolled IBD may result in abscess formation, unlike what was previously reported.

No previous report compared the changes in indicators of inflammation before and after corticosteroid treatment. In our case, we found that CRP and ESR levels dropped rapidly after corticosteroid treatment. Therefore, these two indicators may reflect the therapeutic effects of AA.

## Discussion

Herein, we report a case of aseptic left hand and lung abscesses, a rare EIM of IBD. Before admission, the patient had undergone abscess incision and drainage twice over the past two years for sternal and leg abscesses. This time, the patient was admitted to our hospital because of an abscess on the back of his left hand. Abscess incision, drainage, and antibacterial treatments had no effect. The patient's condition improved after corticosteroid treatment.

## Clinical Diagnosis

No standard diagnostic criterion is available for AA. Some experts have reported several diagnostic clues for AAs: (1) deep abscess with neutrophilic features; (2) negative serological tests for bacteria and fungi and cultures of blood and aspirate; (3) failure of broad-spectrum antibiotic therapy, including anti-tuberculosis therapy; and (4) rapid clinical improvement following corticosteroid therapy and subsequent radiologic evidence of abscess resolution.<sup>3</sup> Using this definition, our patient met all criteria. However, the process of confirming the diagnosis is lengthy. Abscesses are usually caused by a bacterial infection. Based on the patient's presentation on arrival at our hospital, we believe that the abscess was infectious. The patient underwent two surgeries and received antibiotic treatment with no effect. Subsequently, his doctor considered a diagnosis of AA, and the patient's condition improved rapidly with corticosteroid therapy. Sterile abscesses were reported on various body parts including the face, spleen, nasal septum, and kidneys. This is the first case of AA located on the hand and lung reported in China. The mechanism of AA is unclear; however, it is suspected to involve vasculitis, T-cell-mediated neutrophilic activation, or antibody and complement-initiated mechanisms.

## Pathology

The pathogenesis of AAs has not yet been elucidated; however, it is speculated to belong to a spectrum of systemic inflammatory disorders. AA shares a pathological picture with neutrophilic dermatosis, with sterile abscesses and polymorphonuclear leukocyte infiltrates.<sup>11</sup> Aseptic neutrophilic abscesses typically exhibit visceral involvement. In many cases, superficial lesions have also been discovered, such as pyoderma gangrenosum or Sweet syndrome.<sup>21,22</sup> Cutaneous aseptic abscesses result from the deepest anatomical form of neutrophilic dermatosis. In our case, the patient developed neutrophilic dermatosis in his left leg during hospitalization.

## Association with IBD

AAs are rare but serious EIMs associated with IBD. The most common underlying IBDs are UC and CD. Approximately 53% and 41% of the patients have been reported to have underlying UC and CD, respectively. In other cases, the underlying disease may be another type of inflammatory disease, such as rheumatoid arthritis or rheumatoid nodules.<sup>23,24</sup> According to previous reports, AA can occur before, during, and after IBD diagnosis. After focusing on these reports, we found that some patients had clinical manifestations of IBD before developing AA. Therefore, diagnosis of IBD may be delayed. In our literature review, all patients who had IBD after AA were diagnosed concomitantly.

The association between IBD disease severity and manifestation of AA is unclear. Multi-site aseptic abscesses may reoccur before the patient receives appropriate medication. In our case, the patient's diagnosis of AA was delayed after

**Table 2** Summary of IBD-Associated AA Cases from the Literature and a Case from Our Institution

Publication Year/ Authors/ Country	IBD phenotype (CD/ UC/Temporal Relation to Diagnosis)	Age/ Sex	Clinical Sign	Location of AA	Elevated WBC Count ( $\mu\text{L}$ )	Operation Treatment	Antibiotic Treatment	Responded Medication	Outcome
2011/Yılmaz et al/Turkey <sup>6</sup>	UC/before	34/F	Nasal ache, difficulty with nasal breathing, fever, abdominal pain	Nasal septal	NR	Abscess drainage	Yes	Prednisone	Resolved after 7 days of steroid therapy
2012/Ito et al/ Japan <sup>7</sup>	IBD/Concomitant	24/F	Recurrent fever, abdominal pain	Spleen	12,900	Splenectomy	No	Prednisone and infliximab	Resolved immediately
2014/Brooks et al/ Caucasian <sup>8</sup>	CD/concomitant	19/F	Abdominal pain	Ankle spleen	15,100	No	Yes	Corticosteroids	Resolution of splenic lesions within 6 months
2015/Sakharpe et al/India <sup>9</sup>	CD/before	48/F	Fever, weakness, loss of appetite, coughing, chest pain	Liver	14,000	Abscess drainage	Yes	Corticosteroids	Resolution of the abscess 3 weeks later
2015/Boschetti et al <sup>10</sup>	CD/before	40/F	Fever, abdominal pain	Spleen, pancreas	NR	No	Yes	Corticosteroids and adalimumab	Clinical remission with a 6-month follow-up
2017/Bollegala/ Canada <sup>11</sup>	UC/before	Case1 33/M	Fever, abdominal pain, weight loss	Spleen	18,000	Abscess drainage	Yes	steroids and infliximab	Resolution of the abscess 6 months later
	UC/before	Case2 27/F	Fever, oral ulcers, abdominal pain, chest pain, weight loss	Spleen	21,100	Splenectomy	No	Prednisone and infliximab	Her dermatologic and rheumatologic symptoms rapidly resolved
2017/Yang et al/ China <sup>12</sup>	CD/before	24/F	Fever, abdominal pain, weakness, poor appetite	Liver	NR	Abscess drainage	Yes	Infliximab	Resolved
2018/ Herskovitz et al/USA <sup>13</sup>	UC/before	54/M	Back pain, lower extremity numbness, weakness	Bilateral shins, upper arms	NR	No	Yes	Corticosteroid	Completely resolved

(Continued)

Table 2 (Continued).

Publication Year/ Authors/ Country	IBD phenotype (CD/ UC/Temporal Relation to Diagnosis)	Age/ Sex	Clinical Sign	Location of AA	Elevated WBC Count (/μL)	Operation Treatment	Antibiotic Treatment	Responded Medication	Outcome
2019/Bavaro et al/Italy <sup>14</sup>	CD/concomitant	21/F	Fever, left flank abdominal pain, sweating, fatigue	Spleen	NR	Splenectomy	Yes	Corticosteroids	Discharged at home in good clinical condition
2020/Soffer et al/Israel <sup>15</sup>	CD/concomitant	26/M	Fever, night sweats, weight loss	Renal	NR	No	Yes	Corticosteroid	Resolved 8 months later
2021/ Yamaguchi et al/Japan <sup>16</sup>	UC/before	45/M	Fever, epigastric pain, weight loss	Spleen	15,300	Splenectomy	Yes	Infliximab	Resolved several months later
2021/ Kukimoto et al/ Japan <sup>17</sup>	UC/before	25/M	Acute panuveitis, decreased vision in the right eye	Subconjunctival, liver, lung, Spleen	11,700	Abscess drainage	Yes	Corticosteroid and infliximab	Improved dramatically
2022/Ishikawa et al/Japan <sup>5</sup>	UC/before	27/F	Fever, pain in the middle forehead	Nasal septal	11,190	Abscess drainage	Yes	Methylprednisolone and rituximab	Resolved
2022/Dai et al/ China <sup>18</sup>	CD/before	64/M	Fever, abdominal pain	Liver	12,660	Abscess drainage	Yes	Ustekinumab	Gradually improved
2022/ Ozek et al/Japan <sup>19</sup>	UC/before	76M	Buttock pain, abdominal pain	Subgluteus maximus, pectineus	NR	No	Yes	Corticosteroid	Resolved both abscesses
2023/ Toba et al/Japan <sup>20</sup>	UC/before	69/F	Fever, pain in the extremities, back pain, anterior chest pain	Sternum, ribs, thoracolumbar spine	11,000	No	Yes	Prednisone and infliximab	Resolved after infliximab administration
Present case	UC/before	48/M	Left-hand backache	Left hand, lung	14,430	Abscess drainage	Yes	Corticosteroid	Resolved several months later

**Abbreviations:** NR, not reported; UC, ulcerative colitis; CD, Crohn's disease; IBD, inflammatory bowel disease; WBC, white blood cell; F, female; M, male; AA, aseptic abscess; USA, United States of America.

the second surgery. He developed a new abscess on his lung because of active UC. His condition improved rapidly with corticosteroid therapy. Therefore, early diagnosis of AA is crucial. Doctors should raise awareness of IBD-associated AA to avoid unnecessary medication or surgery.

## Treatment

Abscesses are typically caused by bacterial infections. Before an AA diagnosis is made, incision, drainage, and antibiotic therapy are the primary considerations. Surgery plays a limited role in the treatment of splenic abscesses and is performed on a case-by-case basis. In our case, the patient underwent two surgeries for his left-hand abscess; however, his condition did not improve. Corticosteroids are necessary for almost all patients with AA. In some cases, azathioprine, cyclophosphamide, infliximab, and adalimumab may elicit improvement.<sup>11</sup> Splenectomy has been reported for splenic abscesses when steroids are ineffective. In this case, the patient's condition did not improve until steroids were administered.

Clinicians should be vigilant when encountering an abscess without an obvious cause and consider the possibility of IBD-associated AA. Clinicians should be vigilant when encountering an abscess without an obvious cause and consider the possibility of IBD-associated AA. Steroids should be administered once the diagnosis of AA is established to avoid unnecessary surgery or incision.

## Conclusion

The diagnosis of IBD-associated AAs may be challenging initially. Fever, weight loss, abdominal pain, and elevated WBC and neutrophil counts are the most frequent clinical presentations. We believe that checking for these aspects would help clinicians make earlier diagnoses if they are aware of the possibility of an aseptic abscess in a patient with IBD. The spleen is the target organ; however, many other organs may also be involved. AA is sensitive to corticosteroids. The case described in this study highlights the importance of identifying IBD-associated AA to avoid iterative surgical procedures. AAs are considered extra-intestinal manifestations of IBD; nevertheless, the specific type of IBD patients who may experience such complication is unknown. Further studies are warranted to explore high-risk factors of AAs in patients with IBD and the pathophysiology of aseptic abscesses.

## Abbreviations

AA, Aseptic Abscess; CT, Computed tomography; CD, Crohn's Disease; EIM, Extra-intestinal manifestation; IBD, Inflammatory Bowel Disease; UC, Ulcerative Colitis; WBC, White Blood Cell.

## Ethics Approval and Informed Consent

This study was approved by the Ethics Committee of the Second Affiliated Hospital of the Air Force Medical University, Shaanxi, China.

## Consent for Publication

Written informed consent was obtained from the patient for the publication of the case details and accompanying images.

## Acknowledgments

We are grateful for the useful comments and suggestions provided by the anonymous referees.

## Funding

The research received no external funding.

## Disclosure

The authors report no conflicts of interest in this work.

## References

1. Trefond L, Frances C, Costedoat-Chalumeau N, et al. Aseptic abscess syndrome: clinical characteristics, associated diseases, and up to 30 years' evolution data on a 71-patient series. *J Clin Med*. 2022;11(13):3669. doi:10.3390/jcm11133669
2. Seyedian SS, Nokhostin F, Malamir MD. A review of the diagnosis, prevention, and treatment methods of inflammatory bowel disease. *J Med Life*. 2019;12(2):113–122. doi:10.25122/jml-2018-0075
3. André MFJ, Piette JC, Kémény JL, et al. Aseptic abscesses: a study of 30 patients with or without inflammatory bowel disease and review of the literature. *Med*. 2007;86(3):145–161. doi:10.1097/md.0b013e18064f9f3
4. Card TR, Langan SM, Chu TPC. Extra-gastrointestinal manifestations of inflammatory bowel disease may be less common than previously reported. *Dig Dis Sci*. 2016;61(9):2619–2626. doi:10.1007/s10620-016-4195-1
5. Ishikawa T, Suzuki J, Shirai T, et al. Presence of phlebitis in aseptic nasal septal abscess complicated with ulcerative colitis; possible association with granulomatosis with polyangiitis: a case report. *Tohoku J Exp Med*. 2022;258(1):29–34. doi:10.1620/tjem.2022.J053
6. Yılmaz B, Yüksel O, Coban S, Cakmak I, Başar O, Ekiz F. Rare complication of ulcerative colitis: aseptic nasal septal abscess. *Inflamm Bowel Dis*. 2011;17(7):E71. doi:10.1002/ibd.21732
7. Ito T, Sato N, Yamazaki H, Koike T, Emura I, Saeki T. A case of aseptic abscesses syndrome treated with corticosteroids and TNF-alpha blockade. *Mod Rheumatol*. 2013;23(1):195–199. doi:10.3109/s10165-012-0640-y
8. Brooks J, Ghaffari G. Aseptic splenic abscess as precursory extraintestinal manifestation of inflammatory bowel disease. *Case Rep Med*. 2014;2014:684231. doi:10.1155/2014/684231
9. Sakharpe AK, Sakharpe AK, Mirmanesh M, et al. A case and review of aseptic liver abscess in Crohn's disease. *Int J Colorectal Dis*. 2016;31(3):787–788. doi:10.1007/s00384-015-2288-5
10. Boschetti G, Assaad S, Balme B, Boyer S, Flourié B, Nancey S. A challenging case of multiple splenic and pancreatic lesions in a patient with Crohn's disease. *Gut*. 2016;65(2):295–312. doi:10.1136/gutjnl-2015-310130
11. Bollegala N, Khan R, Scaffidi MA, et al. Aseptic abscesses and inflammatory bowel disease: two cases and review of literature. *Can J Gastroenterol Hepatol*. 2017;2017:5124354. doi:10.1155/2017/5124354
12. Yang Y, Chen D. Treatment of Aseptic Liver Abscess Due to Crohn's Disease Using Infliximab. *Clin Gastroenterol Hepatol*. 2017;15(12):A27–A28. doi:10.1016/j.cgh.2017.06.033
13. Herskovitz I, Maderal AD, Alonso-Llamazares J. Caseating granulomas manifesting as aseptic abscesses in the setting of ulcerative colitis. *Int J Dermatol*. 2018;57(4):475–476. doi:10.1111/ijd.13886
14. Bavaro DF, Ingravallo G, Signorile F, et al. Splenic abscesses as a first manifestation of Crohn's disease: a case report. *BMC Gastroenterol*. 2019;19(1):144. doi:10.1186/s12876-019-1066-1
15. Soffer S, Dahan S, Maklakovski M, Dagan A. A case of aseptic renal abscesses associated with IBD. *Inflamm Bowel Dis*. 2021;27(3):e28–e29. doi:10.1093/ibd/izaa284
16. Yamaguchi Y, Nakagawa M, Nakagawa S, et al. Rapidly progressing aseptic abscesses in a patient with ulcerative colitis. *Intern Med*. 2021;60(5):725–730. doi:10.2169/internalmedicine.5733-20
17. Kukimoto N, Honda N, Yokogawa N, Ohno-Tanaka A. Sterile subconjunctival abscess in an HLA-B51-positive patient with ulcerative colitis. *Am J Ophthalmol Case Rep*. 2021;22:101033. doi:10.1016/j.ajoc.2021.101033
18. Dai C, Huang YH. Successful treatment of Crohn's disease, aseptic liver abscess and psoriasis with ustekinumab. *Rev Esp Enferm Dig*. 2023;115(3):155–156. doi:10.17235/reed.2022.9155/2022
19. Ozeki K, Tanida S, Kataoka H. Aseptic abscess syndrome with ulcerative colitis and pyoderma gangrenosum. *Clin Gastroenterol Hepatol*. 2022;20(10):A27. doi:10.1016/j.cgh.2022.04.040
20. Toba T, Ikegami R, Nogami A, et al. Multiple ulcerative colitis-associated aseptic abscesses successfully treated with infliximab: a case report. *Clin J Gastroenterol*. 2023;16(4):537–542. doi:10.1007/s12328-023-01807-9
21. Callen JP. Pyoderma gangrenosum. *Lancet*. 1998;351(9102):581–585. doi:10.1016/S0140-6736(97)10187-8
22. Fett DL, Gibson LE, Su WPD. Sweet's syndrome: systemic signs and symptoms and associated disorders. *Mayo Clin Proc*. 1995;70(3):234–240. doi:10.4065/70.3.234
23. Owczarczyk-Saczonek A, Kasprowicz-Furmańczyk M, Kuna J, Klimek P, Krajewska-Włodarczyk M. Aseptic abscess syndrome in rheumatoid arthritis patient. *Medicina*. 2022;58(10):1354. doi:10.3390/medicina58101354
24. Holstein A, Egberts EH, Von Herbay A. Rheumatoid-like nodules in the spleen: new extraintestinal manifestation of Crohn's disease? *J Gastroenterol Hepatol*. 2006;21(1 Pt 2):295–298. doi:10.1111/j.1440-1746.2006.04001.x

Infection and Drug Resistance

Dovepress

Publish your work in this journal

Infection and Drug Resistance is an international, peer-reviewed open-access journal that focuses on the optimal treatment of infection (bacterial, fungal and viral) and the development and institution of preventive strategies to minimize the development and spread of resistance. The journal is specifically concerned with the epidemiology of antibiotic resistance and the mechanisms of resistance development and diffusion in both hospitals and the community. The manuscript management system is completely online and includes a very quick and fair peer-review system, which is all easy to use. Visit <http://www.dovepress.com/testimonials.php> to read real quotes from published authors.

Submit your manuscript here: <https://www.dovepress.com/infection-and-drug-resistance-journal>