

# Progression of Uterine Artery Pseudoaneurysm Documented by Ultrasonography: A Case Report

Kun-Kun Qiang<sup>1,2</sup>, Qing-Yun Song<sup>1,2</sup>

<sup>1</sup>Department of Diagnostic Ultrasound, West China Second University Hospital, Sichuan University, Chengdu, People's Republic of China; <sup>2</sup>Key Laboratory of Obstetric & Gynecologic and Pediatric Diseases and Birth Defects of Ministry of Education, Chengdu, People's Republic of China

Correspondence: Qing-Yun Song, Department of Diagnostic Ultrasound, West China Second University Hospital, Sichuan University, Chengdu, Sichuan Province, 610041, People's Republic of China, Email huaxi2chaoshengsqy@163.com

**Introduction:** Uterine artery pseudoaneurysm (UAP) is a rare cause of late postpartum hemorrhage. Insufficient understanding of this condition among clinicians may result in delayed diagnosis and treatment, potentially leading to incorrect interventions and poor prognosis, including fatal hemorrhage and even necessitating hysterectomy in severe cases.

**Case Report:** The patient, a 41-year-old woman with a history of three pregnancies and two deliveries, underwent cesarean section and subsequently experienced persistent small amounts of vaginal bleeding for a duration of two months. Transvaginal ultrasonography revealed a hypochoic mass in the cervix that was initially misdiagnosed as a cervical fibroid. Approximately 12 h prior to admission, she experienced an episode of acute vaginal bleeding of significant intensity. Emergency transvaginal ultrasound demonstrated an intrauterine mass located in the posterior wall of the cervix with swirling blood flow, exhibiting a to-and-fro pattern. The mass was connected to the left uterine artery adjacent to the cervix through a tear measuring approximately 0.5 cm in diameter. Emergency bilateral uterine artery embolization was performed. After a follow-up period of ten months, there was no recurrence of abnormal vaginal bleeding, and subsequent ultrasound examination confirmed the complete resolution of the cervical lesions.

**Conclusion:** The findings of this case suggest that the UAP undergoes a dynamic process. In the early stages, the lesion may manifest as a small hypochoic or anechoic area within the myometrium. Color Doppler imaging might not reveal blood flow signals within the lesion, potentially leading to misdiagnosis as other common uterine lesions such as fibroids or cysts. However, considering the close association between UAP and the uterine artery, meticulous observation of the relationship between the uterine artery and its branches is crucial for identifying myometrial lesions to facilitate early detection of UAP and minimize misdiagnosis.

**Keywords:** uterine artery, pseudoaneurysm, postpartum hemorrhage, ultrasound, uterine artery embolization

## Introduction

A pseudoaneurysm (PSA) refers to a hematoma that arises from blood extravasation within the arterial cavity, resulting in an arterial wall defect surrounded by adjacent tissue.<sup>1</sup> Unlike true aneurysms, which consist of intact layers of arterial intima, media, and adventitia, the wall of a PSA often comprises predominantly loose connective tissue. The PSA cavity is connected to the artery through a narrow neck, leading to turbulence formation and gradual enlargement of the cavity with increased vulnerability to rupture.<sup>2</sup> Uterine artery pseudoaneurysm (UAP) refers to the occurrence of PSA in the uterine artery and is a rare complication that can arise from various obstetric and gynecological procedures. However, inadequate awareness and delayed diagnosis often result in fatal hemorrhage.<sup>3</sup>

The exact etiology of UAP remains uncertain and is commonly believed to have a strong association with uterine artery injury; however, there are cases in which patients present with no previous history of such injuries.<sup>4,5</sup> Existing literature in the field of obstetrics and gynecology encompasses various procedures related to UAP, including cesarean section, laparoscopic myomectomy, laparoscopy-assisted myomectomy, laparoscopic deep endometriosis resection, transabdominal myomectomy, total hysterectomy, cervical conization, uterine artery embolization, curettage, vaginal delivery, and induced abortion.<sup>2-4,6</sup>

The clinical manifestations of UAP are non-specific and closely associated with pathogenic factors, timing of diagnosis, lesion location, and whether the lesion communicates with the uterine cavity. In cases in which the early UAP remains unruptured, there may be an absence of evident clinical symptoms; however, upon rupture, it can result in significant hemorrhage or intermittent irregular bleeding due to surrounding tissue encapsulation and thrombosis. Communication between the UAP and uterine cavities may lead to vaginal bleeding, whereas communication with the abdominal cavity often presents as intra-abdominal hemorrhage accompanied by abdominal pain.<sup>7</sup>

The diagnostic modalities for UAP include ultrasound, computed tomography (CT), magnetic resonance imaging (MRI), and digital subtraction angiography (DSA). Ultrasound currently serves as the primary method for diagnosing UAP because of its real-time, rapid, accurate, and non-invasive nature. However, there are still instances in which atypical ultrasound imaging performance can lead to missed or misdiagnosed cases of UAP. In this case report, a patient developed UAP following a cesarean section but was initially misdiagnosed during an early ultrasound examination. We retrospectively analyzed the changes in ultrasound images and identified the causes of misdiagnosis.

## Case Presentation

A 41-year-old woman with a history of two previous pregnancies and deliveries experienced a persistent small amount of vaginal bleeding for 2 months following a cesarean section procedure. The patient had a medical history of myomectomy. The transvaginal ultrasound images at 42 days postpartum showed a heterogeneous weak echo mass with a size of about 3.2×2.8×3.4 cm in the cervix (Figure 1a), with clear boundary, regular shape, and blood flow signals detected around (Figure 1b), which was diagnosed as cervical fibroid.

The patient presented with profuse vaginal bleeding (>500 mL) and dizziness 12 hours prior to admission. Upon emergency examination, transvaginal ultrasound revealed a heterogeneous echogenic mass measuring approximately 3.6×2.9×3.3 cm in the posterior cervix (Figure 1c). Color Doppler imaging revealed swirling blood flow exhibiting a to-and-fro pattern within the mass, which was connected to the left uterine artery adjacent to the cervix through a tear measuring approximately 0.5 cm in diameter (Figure 1d, Video S1). Therefore, the diagnosis of UAP was considered.

Following admission, persistent vaginal bleeding was observed, and examination revealed Human Chorionic Gonadotropin (HCG) levels below 2mIU/mL and a hemoglobin level of 90 g/L. Emergency bilateral uterine artery embolization was performed. Intraoperative angiography demonstrated exudation of contrast agent in the left ascending branch of the uterine artery, resulting in pseudoaneurysmal changes (Figure 2a, Video S2). Post-embolization angiography revealed no evidence of extravasation of the contrast agent (Figure 2b, Video S3).

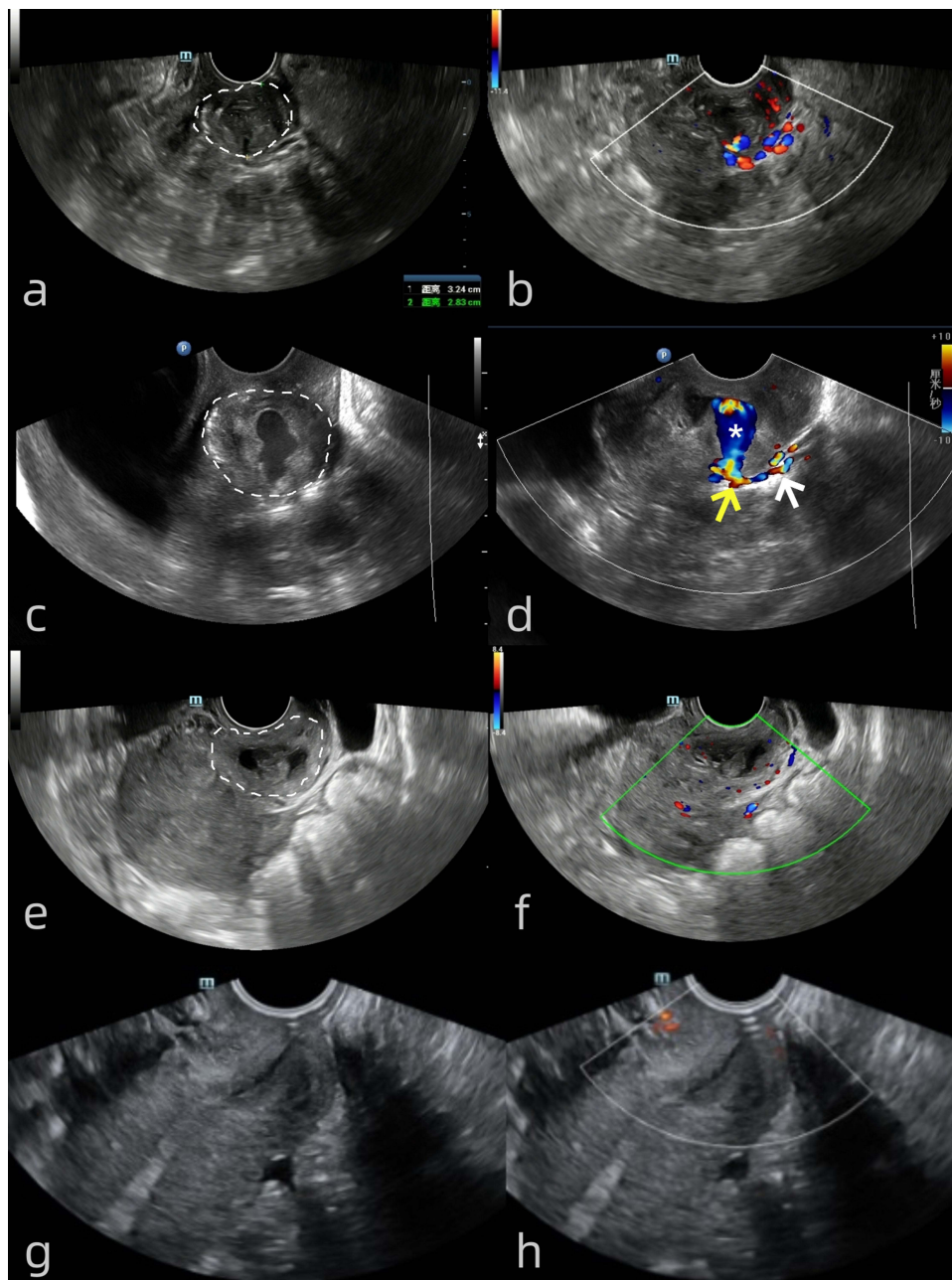
Two weeks post-operation, transvaginal ultrasound revealed heterogeneous echoes measuring 2.8×2.2×2.8 cm in the posterior cervical wall (Figure 1e), with no detectable blood flow signal within the lesion and absence of any connection to the uterine artery (Figure 1f). At the 10-months follow-up, transvaginal ultrasound demonstrated no evidence of cervical occupancy (Figure 1g) or abnormal blood flow signals (Figure 1h).

## Discussion and Conclusions

We conducted a systematic review to report on cases of UAP following Cesarean Section, with the aim of evaluating our management strategies. We searched PubMed using the terms (((pseudoaneurysm uterus) OR (False aneurysm uterus)) OR (pseudoaneurysm uterine)) OR (False aneurysm uterine)) AND (cesarean section [Title/Abstract]). As of July 2024, we retrieved a total of 54 literature articles. Two reviewers independently assessed all articles, with inclusion criteria being UAP occurring after cesarean section and exclusion criteria being non-English literature, review articles, and UAP not related to cesarean section. Ultimately, we identified and reviewed 24 cases.

The age range of the patients was 21 to 41 years, with an average age of 30.25±5.83 years. Among the 24 patients, nine had a history of one cesarean section, while fifteen had a history of two cesarean sections. The sizes of UAPs ranged from approximately 0.5 cm to 4.9 cm, with an average size of 2.15 ± 1.03 cm. The clinical characteristics of UAP are comprehensively delineated in Table 1.

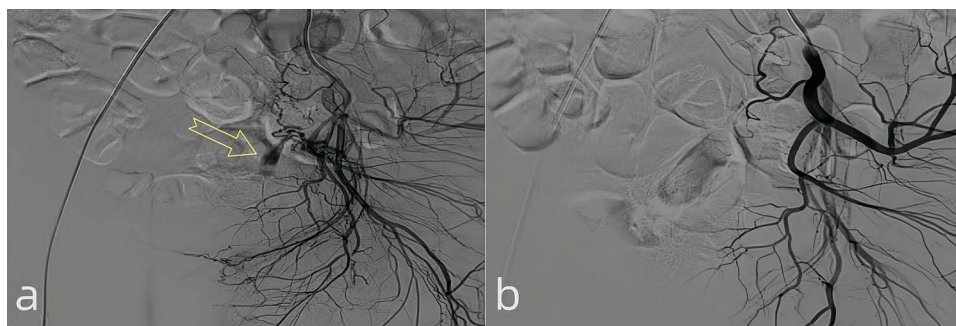
The most common symptom among patients was vaginal bleeding with a prevalence of 79.17% (19 cases), followed by abdominal pain in 16.7% of cases (4 cases). Hypovolemic shock occurred in 8.3% of cases (2 cases), while nausea



**Figure 1** The ultrasound images at 42 days postpartum showed an heterogeneous weak echo mass in the cervix (a), and blood flow signals detected around (b). The ultrasound images 12 hours prior to admission revealed a heterogeneous echoic mass in the posterior cervix (c), Color Doppler imaging revealed the presence of swirling blood flow (\*) exhibiting a to-and-fro pattern within the mass, which was observed to be connected to the left uterine artery (white arrow) adjacent to the cervix through a tear (yellow arrow) measuring approximately 0.5 cm in diameter (d). Two weeks post-operation, ultrasound revealed heterogeneous echoes in the posterior cervical wall (e), with no detectable blood flow signal within the lesion and absence of any connection to the uterine artery (f). At ten months follow-up, ultrasound demonstrated no evidence of cervical occupancy (g) and absence of abnormal blood flow signal (h).

and vomiting, dizziness, anemia and hematuria each accounted for only one case or a prevalence of approximately 4.17%. Additionally, two patients were asymptomatic with lesions detected during routine examinations.

UAP mainly occurred in the uterine body (12 cases, 50%), with other locations including uterine cavity (4 cases, 16.7%), cervix uterus (4 cases, 16.7%), and parauterine area (4 cases, 16.7%). Nineteen UAP originated from the left uterine artery and five originated from the right uterine artery.



**Figure 2** Emergency bilateral uterine artery embolization was performed. Intraoperative angiography demonstrated exudation of contrast agent in the left ascending branch of the uterine artery, resulting in pseudoaneurysmal changes (a, arrow). Post-embolization angiography review showed no evidence of contrast agent extravasation (b).

The most frequently employed diagnostic techniques include Color Doppler transvaginal ultrasound (18 cases, 75.0%), Angiography (13 cases, 54.2%), and Computed Tomography (CT) (13 cases, 54.2%). The most frequently utilized treatment modality was selective transcatheter arterial embolization, accounting for 17 cases (70.8%).

**Table 1** Clinical Characteristics of Uterine Artery Pseudoaneurysm Following Cesarean Section

Variable	No. of Cases (Percentage)
<b>Clinical signs and symptoms</b>	
Vaginal bleeding	19 (79.17%)
Abdominal pain	4 (16.7%)
Hypovolemic shock	2 (8.33%)
Nausea and vomiting	1 (4.17%)
Dizziness	1 (4.17%)
Anaemia	1 (4.17%)
Hematuria	1 (4.17%)
No symptom	2 (8.33%)
<b>Location of UAP</b>	
Uterine body	12 (50%)
Cervix uterus	4 (16.7%)
Parauterine area	4 (16.7%)
Uterine cavity	4 (16.7%)
<b>Origin</b>	
Left uterine artery	19 (79.2%)
Right uterine artery	5 (20.8%)
<b>Diagnostic tools</b>	
Color Doppler transvaginal ultrasound	18 (75.0%)
Angiography	13 (54.2%)
CT	13 (54.2%)
DSA	3 (12.5%)
MRI or MR angiography	1 (4.17%)
<b>Treatment methods</b>	
Selective transcatheter arterial embolization	17 (70.8%)
Injection of thrombin	3 (12.5%)
Uterectomy	2 (8.33%)
Ligation of internal iliac artery	1 (4.17%)
Conservative treatment	1 (4.17%)

**Abbreviations:** CT, computed tomography; MR, magnetic resonance; MRI, magnetic resonance imaging; DSA, digital subtraction angiography.

Two patients underwent hysterectomy due to persistent heavy bleeding, while the lesions resolved and exhibited a favorable prognosis following treatment in other patients. Among them, one patient with UAP received conservative management, and subsequent follow-up revealed thrombosis formation within the UAP leading to gradual spontaneous resolution of the lesion.

In our case, considering the patient's medical history of myomectomy and cesarean section, it was hypothesized that these procedures might be associated with uterine artery injury and subsequent formation of UAP. The clinical manifestation was a persistent small amount of vaginal bleeding, which suddenly changed into an acute large amount of vaginal bleeding, suggesting the possibility of a sudden rupture of the UAP. The ultrasound images of the patient also changed with the development of the UAP.

Ultrasonography is the most commonly used modality for postpartum evaluations. On grayscale ultrasound, UAP typically presents as a pulsatile hypoechoic or isoechoic mass connected to the stenotic neck by a feeding vessel.<sup>1</sup> Color Doppler ultrasound enables further visualization of high-velocity blood flow consistent with UAP, along with the presence of turbulence forming the characteristic “to-and-fro” or “yin-yang” sign, thereby enhancing diagnostic accuracy.<sup>4,8</sup> In this case, upon transvaginal ultrasound examination following acute massive hemorrhage, clear visualization of the pulsatile mass connected to the uterine artery and turbulence-induced “to-and-fro” sign were observed. Consequently, a definitive diagnosis was established. However, atypical imaging findings were noted during previous ultrasound examinations, leading to misdiagnosis by the examining physician, who erroneously identified it as a cervical fibroid, resulting in treatment delay.

The reasons for misdiagnosis may be attributed to the following factors. First, the examiner's lack of experience in identifying atypical ultrasound findings of UAP. In the early stages of the lesion, the blood flow signal within the mass was not clearly visible (Figure 1a), possibly because of its small size and minimal blood leakage from the tear. Ultrasound findings typically reveal a well-defined heterogeneous weak-echo mass, leading to the misinterpretation of cervical fibroids. Second, insufficient attention was given by the examiner to differentiate between the blood flow signals originating from the cervical muscle wall and those supplied by the adjacent uterine arteries near the cervix. Consequently, it was mistakenly assumed that these blood supplies were associated with the fibroids. However, retrospective analysis of ultrasound images during patient examination revealed a close correlation between blood supply and parauterine vessels (Figure 1b). Following interventional treatment (Figure 1f), there was a significant reduction in the blood flow signal surrounding the lesion, along with disappearance of the connection with the parauterine vessels.

Transvaginal ultrasound images may exhibit varying characteristics at different stages of the UAP. Therefore, enhancing the understanding of ultrasound performance in atypical UAP is beneficial for early detection, treatment, and prevention of severe complications. The examiner should maintain a high level of vigilance towards the UAP. For patients with high-risk factors and persistent clinical symptoms, careful examination should be conducted to identify space-occupying lesions within the uterine muscle walls and their connections with the uterine artery. When identification becomes challenging, other imaging examinations, such as CT and MRI, can be employed to further confirm the diagnosis of UAP, while excluding other related diseases.<sup>1,2</sup>

DSA is considered the gold standard for diagnosing UAP and can provide direct guidance for embolization treatment.<sup>1,3,9</sup> DSA enables the visualization of blood flow in the UAP and identification of feeding arteries; contrast agent overflow can be observed.<sup>5</sup> However, negative results may occur when thrombosis terminates bleeding in the UAP.<sup>5,10</sup> Pregnancy-related UAP lesions may contain surviving villi that form new collateral vessels after selective arterial embolization, and feed into the lesion, resulting in treatment failure. Therefore, some scholars have suggested the simultaneous monitoring of human chorionic gonadotropin (HCG) during the diagnosis and treatment of UAP.<sup>3,7</sup>

Takahashi et al reported three instances of spontaneous resolution and proposed that cases with minimal or no symptoms and small-sized UAP may possess the potential for natural resolution.<sup>11</sup> However, Wu et al discovered that the masses in the four cases of ruptured UAP were not larger than those in the unruptured ones. Moreover, rupture could potentially result in a reduction in mass size, suggesting a possible absence of direct correlation between mass size and risk of rupture.<sup>12</sup> Baba et al conducted a study and discovered that the rupture of UAP might be influenced by the equilibrium between intra-UAP blood flow/pressure and UAP wall strength. They also suggested that the absence of diastolic flow could potentially indicate spontaneous resolution of UAP.<sup>13</sup> Further research is needed to investigate

whether factors such as blood flow, pressure, and UAP wall strength, rather than solely focusing on the size of the UAP, can serve as potential indicators for predicting the UAP resolution.<sup>12</sup>

In conclusion, although UAP is a rare gynecological complication, it is imperative to consider the possibility of UAP in cases of unexplained vaginal bleeding. The primary reason for missed diagnoses in clinical settings stems from an inadequate understanding of the disease. Ultrasound images depicting UAP may exhibit diverse manifestations at different stages, necessitating examiners to enhance their comprehension of atypical ultrasound presentations associated with UAP.

## Abbreviations

UAP, uterine artery pseudoaneurysm; PSA, pseudoaneurysm; CT, computed tomography; MR, magnetic resonance; MRI, magnetic resonance imaging; DSA, digital subtraction angiography; HCG, Human Chorionic Gonadotropin.

## Data Sharing Statement

All data generated or analysed during this study are included in this published article.

## Ethics Approval and Consent to Participate

The need for approval was waived and written consent was obtained.

## Consent for Publication

Written consent for publication was obtained from the patient. There are no identifying images or other personal or clinical details of the patient that compromise anonymity in this manuscript.

## Author Contributions

All authors made a significant contribution to the work reported, whether that is in the conception, study design, execution, acquisition of data, analysis, and interpretation, or in all these areas, took part in drafting, revising, or critically reviewing the article; gave final approval of the version to be published; have agreed on the journal to which the article has been submitted; and agree to be accountable for all aspects of the work.

## Funding

There is no funding to report.

## Disclosure

The authors declare that they have no competing interests in this work.

---

## References

1. Yun SY, Lee DH, Cho KH, Lee HM, Choi YH. Delayed postpartum hemorrhage resulting from uterine artery pseudoaneurysm rupture. *J Emerg Med.* 2012;42(1):e11–e14. doi:10.1016/j.jemermed.2011.03.005
2. Bhatt A, Odujebi O, Bhatt S, Houry D. Uterine artery pseudoaneurysm rupture: a life-threatening presentation of vaginal bleeding. *Ann Emerg Med.* 2010;55(5):460–463. doi:10.1016/j.annemergmed.2010.01.026
3. Isono W, Tsutsumi R, Wada-Hiraike O, et al. Uterine artery pseudoaneurysm after cesarean section: case report and literature review. *J Minim Invasive Gynecol.* 2010;17(6):687–691. doi:10.1016/j.jmig.2010.06.004
4. Matsubara S, Takahashi Y, Usui R, Nakata M, Kuwata T, Suzuki M. Uterine artery pseudoaneurysm manifesting as postpartum hemorrhage after uneventful second-trimester pregnancy termination. *J Obstet Gynaecol Res.* 2010;36(4):856–860. doi:10.1111/j.1447-0756.2010.01190.x
5. Padavala SM, Ahluwalia A. Post-abortion bleeding due to uterine artery pseudoaneurysm. *J Obstet Gynaecol.* 2004;24(7):834–835. doi:10.1080/01443610400009675
6. Ferrero S, Bogliolo S, Rossi UG, et al. Unusual complication of excision of pelvic endometriosis: pseudoaneurysm of the left uterine artery. *Fertil Steril.* 2010;93(1):264–266. doi:10.1016/j.fertnstert.2009.02.002
7. Kuwata T, Matsubara S, Kaneko Y, Izumi A, Nakata M, Suzuki M. Asymptomatic uterine artery pseudoaneurysm after cesarean section. *J Obstet Gynaecol Res.* 2010;36(2):405–410. doi:10.1111/j.1447-0756.2009.01134.x
8. Butori N, Coulange L, Filipuzzi L, Krausé D, Loffroy R. Pseudoaneurysm of the uterine artery after cesarean delivery: management with superselective arterial embolization. *Obstet Gynecol.* 2009;113(2 Pt 2):540–543. doi:10.1097/AOG.0b013e318190a43a

9. Alboni C, Rosati F, Sansavini S, et al. Three-dimensional power Doppler imaging of uterine artery pseudoaneurysm treated unsuccessfully with selective embolization. *Ultrasound Obstet Gynecol.* 2009;33(5):614–616. doi:10.1002/uog.6388
10. Yahyayev A, Guven K, Bulakci M, Ucar A, Aghayev A, Yekeler E. Spontaneous thrombosis of uterine artery pseudoaneurysm: follow-up with Doppler ultrasonography and interventional management. *J Clin Ultrasound.* 2011;39(7):408–409. doi:10.1002/jcu.20842
11. Takahashi H, Baba Y, Usui R, Ohkuchi A, Kijima S, Matsubara S. Spontaneous resolution of post-delivery or post-abortion uterine artery pseudoaneurysm: a report of three cases. *J Obstet Gynaecol Res.* 2016;42(6):730–733. doi:10.1111/jog.12983
12. Wu T, Lin B, Li K, Ye J, Wu R. Diagnosis and treatment of uterine artery pseudoaneurysm: case series and literature review. *Medicine.* 2021;100(51):e28093. doi:10.1097/MD.00000000000028093
13. Baba Y, Takahashi H, Morisawa H, et al. A potentially useful addition to predict spontaneous resolution of uterine artery pseudoaneurysm: absence of diastolic flow. *Case Rep Obstet Gynecol.* 2018;2018:2158248. doi:10.1155/2018/2158248

International Journal of Women's Health

Dovepress

### Publish your work in this journal

The International Journal of Women's Health is an international, peer-reviewed open-access journal publishing original research, reports, editorials, reviews and commentaries on all aspects of women's healthcare including gynecology, obstetrics, and breast cancer. The manuscript management system is completely online and includes a very quick and fair peer-review system, which is all easy to use. Visit <http://www.dovepress.com/testimonials.php> to read real quotes from published authors.

Submit your manuscript here: <https://www.dovepress.com/international-journal-of-womens-health-journal>