

A Case Report of Pathologically Complete Response of a Huge Lymph Node Metastasis of Colorectal Cancer After Treatment with Intratumoral Oncolytic Virus H101 and Capecitabine

Yaqin Wang, Tianxiao Wang, Yuewei Zhang 

Hepatobiliary Pancreatic Center Department, Beijing Tsinghua Changgung Hospital Affiliated to Tsinghua University, Beijing, 102218, People's Republic of China

Correspondence: Yuewei Zhang, Hepatobiliary Pancreatic Center Department, Beijing Tsinghua Changgung Hospital Affiliated to Tsinghua University, Beijing, 102218, People's Republic of China, Email zywa01618@btch.edu.cn

Abstract: Unresectable recurrent lymph node metastasis of colorectal cancer (CRC) is considered as an incurable disease clinically and has a very poor prognosis. Here, we report a male KRAS wild-type CRC case with a huge abdominal lymph node metastasis (12 cm in diameter) after CRC surgery. After three intratumoral injections of oncolytic virus (H101) combined with four cycles of low-dose oral capecitabine, the size of the metastatic lymph node shrank remarkably in response to the anticancer drug and a complete response (CR) was achieved with progression-free survival (PFS) of 19 months. The main adverse reaction was mild fever, which was relieved after physical cooling. The patient is in a general good condition now without any relapse of abdominal lymph node for over a year. On this basis, we propose that the combination therapy of oncolytic virus and capecitabine could be a promising clinical therapeutic strategy for unresectable recurrent lymph node metastasis in CRC patients.

Keywords: colorectal cancer, recurrent lymph node metastasis, oncolytic virus, capecitabine

Introduction

Colorectal cancer (CRC) ranks as the third most prevalent malignancy globally and the second leading cause of cancer-associated mortality, accounting for approximately 10% of all cancer cases and fatalities. At initial diagnosis, about 20% of CRC patients are found with metastatic disease, and nearly 50% of those with localized disease are likely to develop metastases later.¹ Despite progress in various treatment modalities, including surgical excision, systemic therapy encompassing cytotoxic chemotherapy, biological therapy, immunotherapy, and their combinations, the prognosis for metastatic CRC is grim, with a 5-year survival rate remaining under 20%.² In particular, patients with unresectable metastatic CRC have a median overall survival of merely 6–8 months without treatment, which can be extended to 20–25 months with the implementation of chemotherapy.³

Oncolytic viruses (OVs) represent an innovative therapeutic avenue in the field of oncology, capitalizing on their unique anti-tumour mechanisms. These not only can directly induce tumor cell lysis but regulate the tumor microenvironment via release of tumour-associated antigens (TAAs), leading to activation of anti-tumour immunity (Figure 1).^{4,5} Generally, OVs can be used as monotherapies or combined with chemotherapy, radiation, targeted therapy and immunotherapy to improve the efficacy of both drugs.⁶ Capecitabine, the first-line chemotherapeutic agent for CRC, has been shown to change the tumour microenvironment into an “immune-hot” subtype in patients, improve the antitumor effect of NK cells, and reduce myeloid-derived suppressor cells (MDSCs) (Figure 1).^{7,8}

Recombinant human adenovirus type 5 (H101, also known as Oncorine), a genetically modified oncolytic adenovirus, has demonstrated clinical efficacy for treating various malignancies.^{9–11} Huang et al,¹² confirmed that H101 ameliorated

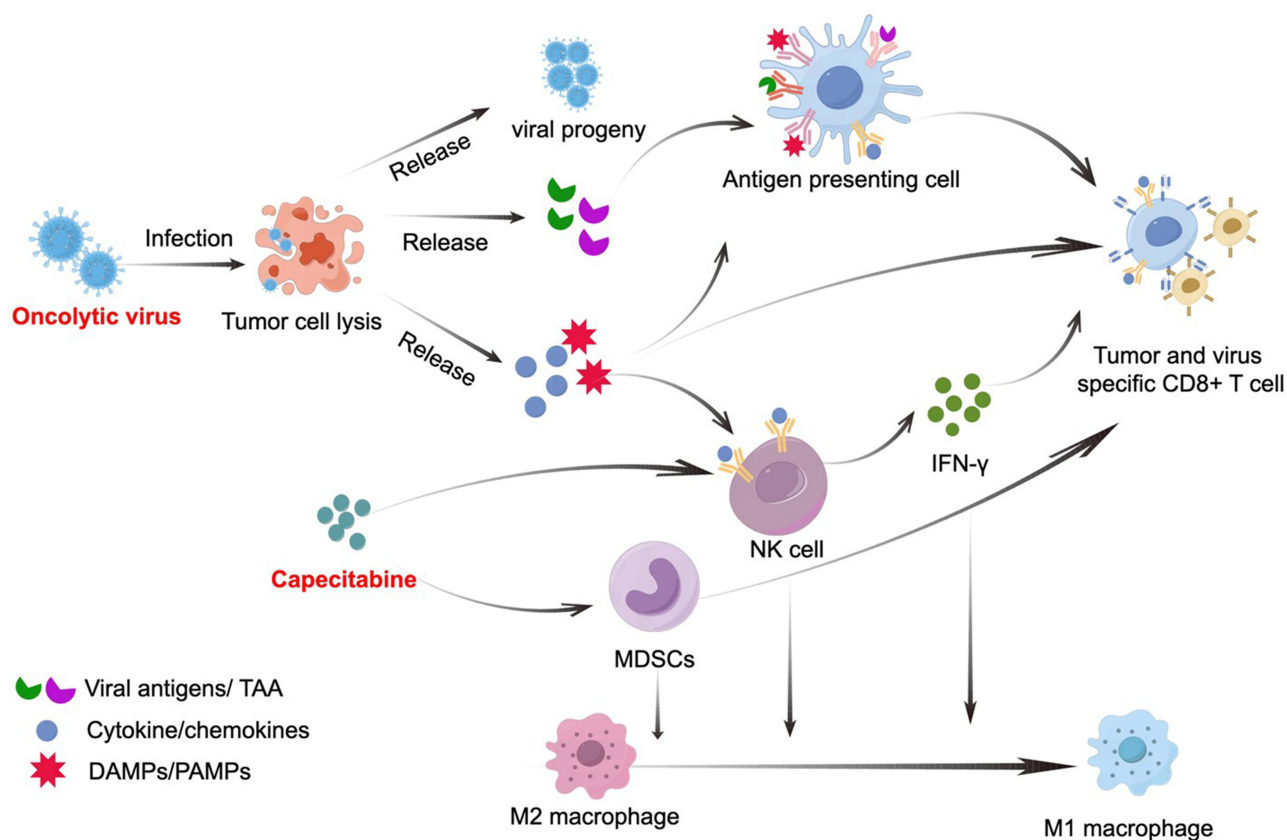


Figure 1 Augmentation of Immune Response through Oncolytic Viruses and Capecitabine Co-Therapy.

Notes: this figure delineates the synergistic immune modulation by oncolytic viruses (OVs) and Capecitabine. Upon infection, OVs proliferate within tumour cells, inducing apoptosis and subsequent release of viral progeny, damage-associated molecular patterns (DAMPs), pathogen-associated molecular patterns (PAMPs), tumour-associated antigens (TAAs) and pro-inflammatory cytokine/chemokines. This release not only facilitates further infection of neighboring tumour cells by the viral progeny but also triggers a cascade of immune activation. Antigen presenting cells (APCs), natural killer (NK) cells, as well as tumour and virus-specific CD8+ T cells, were activated successively. Capecitabine also stimulates NK cells and reduces myeloid-derived suppressor cells (MDSCs) levels. Both OVs and capecitabine prompt conversion of tumour-supportive M2 macrophages toward proinflammatory M1 macrophages.

the efficacy of anti-PD-1 monotherapy in CRC. Herein, this report details a case of substantial abdominal lymph node metastasis, measuring 12 cm in diameter, following CRC surgery. Remarkable shrinkage of the metastatic lymph node was noted, culminating in a complete response (CR) after three sessions of intratumoral injections of H101 in conjunction with four cycles of low-dose oral capecitabine.

Case

Disease Progression and Treatment

A patient >50 years old underwent surgical resection for right-sided colon cancer in November 2020. Histopathological examination revealed an ulcerative, moderately differentiated adenocarcinoma of the colon, with extensive infiltration into the deep muscle layer and adjacent adipose tissue. However, no neural invasion or lymph node metastasis was detected. Subsequent postoperative genetic profiling of the neoplasm identified it as KRAS wild-type and characterized by a high tumour mutational burden (H-TMB) and significant microsatellite instability (H-MSI). Due to the patient's apprehensions regarding potential adverse effects, no adjuvant targeted therapy, immunotherapy, or systemic chemotherapy was pursued postoperatively. Amidst the COVID-19 pandemic, the patient's November 2021 evaluation did not demonstrate any enlargement of abdominal lymph nodes. However, commencing in February 2022, he presented with symptoms indicative of systemic disease, including weight loss, fatigue, abdominal pain, and reduced appetite. Subsequent diagnostic imaging was delayed, possibly owing to the COVID-19 pandemic's logistical challenges or personal factors, until June 2022. At that time, contrast-enhanced computed tomography (CT) revealed a substantial

abdominal lymph node mass, measuring 12 cm in diameter. Ultrasound-guided biopsy puncture and pathological analysis confirmed the recurrence as metastatic intestinal adenocarcinoma. Following comprehensive discussions among the multidisciplinary treatment team, a bespoke treatment strategy for the patient was devised. Considering the extensive nature of the current abdominal tumour, characterized by its invasion into surrounding tissues, surgical excision was not prioritized as the foremost treatment modality. Instead, a systemic therapeutic approach was proposed as the initial intervention. It was collectively determined that the prospect of surgical resection would be revisited contingent upon a substantial reduction in tumour volume.

Despite the outlined plan, the patient voiced considerable concerns about potential grave side effects stemming from systemic pharmacotherapy, encompassing both chemotherapy and immunologically targeted therapy. In light of these concerns and prioritizing treatment safety, a consensus was reached to administer localized intratumoral injections of the oncolytic virus H101 in concert with a regimen of low-dose oral capecitabine.

The treatment initiation took place in July 2022. Utilizing ultrasound guidance, the patient received intratumoral injections of 1.5×10^{12} viral particles (three vials) directly into the neoplastic tissue on July 18, 2022, July 28, 2022, and August 8, 2022.

Concomitantly, the patient commenced a course of oral capecitabine on July 21, 2022, which concluded on November 13, 2022. This regimen comprised four cycles, each spanning three weeks. Specifically, each cycle included a two-week medication phase, during which the patient ingested 1.5 g of capecitabine in the morning and 1.0 g in the afternoon, followed by a one-week cessation period (Figure 2A).

Outcome and Follow-Up

Symptomatic relief, evidenced by the alleviation of abdominal pain and the patient's forced posture, was achieved within 3–5 days following the initial intratumoral injection of H101. By the time of the second H101 injection, the texture of the lymph node tumour had palpably softened. Three weeks post-injection, on 8 August 2022, CT examination showed a significant tumour shrinkage with the tumour diameter from 12 cm to 4.5 cm (Figure 2B). The tumour continued its regression throughout the course of treatment, ultimately becoming barely discernible by the 18th week of therapy (29 November 2022). The last follow-up was conducted in February 2024. There was no evidence of tumour recurrence, and the progression-free survival (PFS) was 19 months.

In addition, serum carcinoembryonic antigen (CEA) and carbohydrate antigen 19–9 (Ca19-9) levels were dropped from 90.7 ng/mL and 66.77 U/mL to 11.25 ng/mL and 13.49 U/mL, respectively, after 3 weeks of the H101 injection, and remained within the normal range (<5.1 ng/mL for CEA and <27 U/mL for Ca19-9) during the subsequent treatment and follow-up period (Figure 2C). According to the response evaluation criteria in solid tumours (RECIST v.1.1), the patient achieved a complete response (CR).

The principal adverse event encountered was a transient, which occurred within 8–24 hours following the first two OV injections and within 4–8 hours after the third injection, peaking at a temperature of 39°C. This fever abated following physical cooling interventions. As of December 2022, five months after the initial H101 injection, the patient expressed satisfaction with the treatment outcomes and reported a general sense of well-being.

Discussion

Lymph node is one of the most frequent metastatic destinations for CRC, and lymph node metastasis significantly contributes to the poor prognosis observed in CRC patients. The management of recurrent lymph node metastasis following CRC resection is influenced by various factors, including patient age, body habitus, the site and size of the original resected CRC, the postoperative treatment of CRC resection, the location and size of the current recurrent lymph node metastasis, as well as the doctor's treatment experience. For patients with unresectable recurrent lymph node metastases from CRC, clinical intervention poses a significant challenge. Therapeutic objectives are predominantly centered on achieving tumour regression, halting the progression of metastasis, and thereby striving to prolong survival and palliate symptoms.

In the presented case, the patient was afflicted with a huge abdominal lymph node metastasis, resulting in physical and psychological distress. Given the patient's poor physical condition currently, the potential for severe adverse

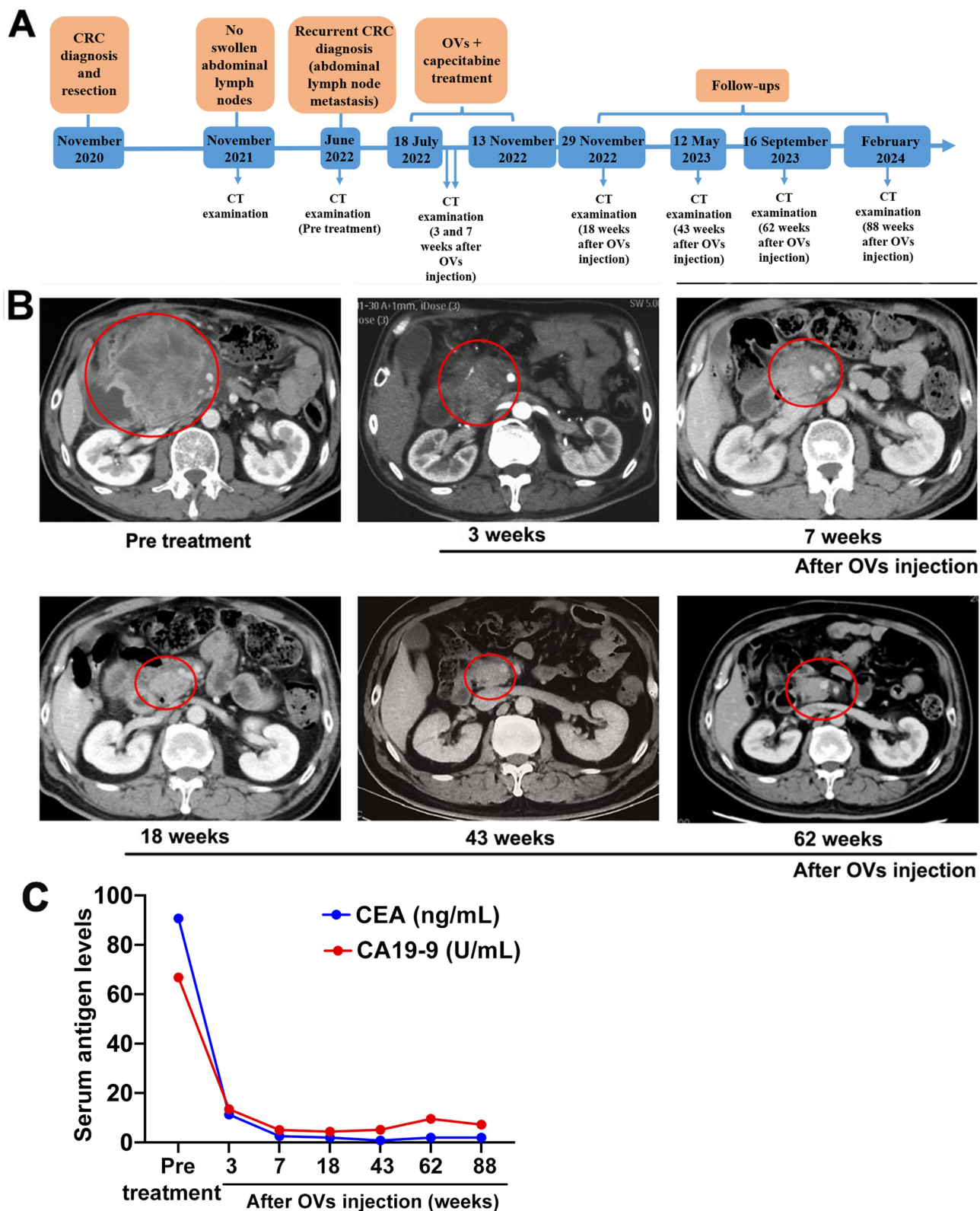


Figure 2 Disease progression, treatment and outcome of the patient. (A) Timeline of the disease progression and relevant treatments of the patient. (B) The CT gram of the patient during the treatment and follow-ups. (C) Serum carcinoembryonic antigen (CEA) and carbohydrate antigen 19–9 (CA19-9) levels of the patient during the treatment and follow-ups.

reactions due to the non-selectivity of systemic chemotherapy and targeted immunotherapy, alongside the preferences of the patient and the patient's family, precision-guided administration of OV into the sizeable abdominal lymph node metastasis was considered a viable treatment option.

H101, a recombinant oncolytic adenovirus harboring deletions within the E1B-55 kDa and a segment of the E3 region, received approval from the National Medical Products Administration (NMPA) of China in 2005 for the treatment of nasopharyngeal carcinoma. It targets tumour cells by interacting with the coxsackievirus and adenovirus receptor (CAR) on the cell membrane and selectively replicates it in tumour cells with Rb-p53 pathway dysfunction. Additionally, the strategic deletion of the E3 segment amplifies its antineoplastic efficacy by enhancing antigen presentation, increasing peptide antigens, and boosting the lytic activity of cytotoxic T-lymphocytes (CTLs) along with the activation of NK cells.¹³ As a first-line chemotherapeutic agent for CRC, capecitabine exerts anti-tumour effect not only via inhibiting tumour cell proliferation but by modulating the tumour immune microenvironment.¹⁴

Previous studies have highlighted the synergistic potential of combining chemotherapy with H101 as a novel approach to cancer immunotherapy.¹¹ The compelling clinical outcome observed in the present case—rapid reduction of a sizable abdominal lymph node metastasis achieving CR after three H101 intratumoral injections and four cycles of low-dose oral capecitabine—affirm the safety and efficacy of this combinatorial approach for managing unresectable recurrent lymph node metastasis in CRC. Recently, a multi-center, observational, real-world study revealed the reliability, safety, and feasibility of H101-based therapy in patients with malignant tumors, including those with malignant pleural effusion and ascites.¹⁵

Moving forward, the onus rests on expansive, multi-center, single-arm or randomized controlled trials to validate the therapeutic potency and safety of the H101 and capecitabine amalgamation for CRC metastases. In recent years, immunotherapy has made remarkable progress for CRC treatment. CRC patients with H-MSI and H-MSI are sensitive to immunotherapy.^{16,17} In this instance, genetic profiling, delineates a KRAS-wild type with H-TMB and H-MSI, which may be the key reason for the treatment outcome and may shed light on selecting the most responsive patient cohort for this treatment modality. The prognostic value of these genetic and immunological markers as predictors for the ideal recipients of this combined therapy warrants further investigational scrutiny.

Data Sharing Statement

All data generated or analyzed during this study are included in this article.

Ethics Approval and Consent to Participate

The study was conducted in accordance with the Declaration of Helsinki. This is a care report. The Ethics Committee of Beijing Tsinghua Changgung Hospital Affiliated to Tsinghua University confirmed that the case report does not require registration or approval.

Consent for Publication

Written informed consent has been obtained from the patient to publish this paper.

Acknowledgments

We are grateful to the patient and the patient's family.

Funding

This research did not receive any specific grants from funding agencies in the public, commercial, or not-for-profit sectors.

Disclosure

The authors report no conflicts of interest in this work.

References

1. Ciardiello F, Ciardiello D, Martini G, Napolitano S, Tabernero J, Cervantes A. Clinical management of metastatic colorectal cancer in the era of precision medicine. *CA Cancer J Clin.* 2022;72(4):372–401. doi:10.3322/caac.21728
2. Biller LH, Schrag D. Diagnosis and treatment of metastatic colorectal cancer: a review. *JAMA.* 2021;325(7):669–685. doi:10.1001/jama.2021.0106
3. Kawai S, Takeshima N, Hayasaka Y, et al. Comparison of irinotecan and oxaliplatin as the first-line therapies for metastatic colorectal cancer: a meta-analysis. *BMC Cancer.* 2021;21(1):116. doi:10.1186/s12885-021-07823-7
4. Shalhout SZ, Miller DM, Emerick KS, Kaufman HL. Therapy with oncolytic viruses: progress and challenges. *Nat Rev Clin Oncol.* 2023;20(3):160–177. doi:10.1038/s41571-022-00719-w
5. Kim TK, Vandsemb EN, Herbst RS, Chen L. Adaptive immune resistance at the tumour site: mechanisms and therapeutic opportunities. *Nat Rev Drug Discov.* 2022;21(7):529–540. doi:10.1038/s41573-022-00493-5
6. Butterfield LH, Kaufman HL, Marincola FM. *Cancer Immunotherapy Principles and Practice.* Springer Publishing Company; 2021.
7. Ghazvinian Z, Abdolahi S, Ahmadvand M, et al. Chemo-immune cell therapy by intratumoral injection of adoptive NK cells with capecitabine in gastric cancer xenograft model. *BioImpacts.* 2023;13(5):383–392. doi:10.34172/bi.2022.26386
8. Peereboom DM, Alban TJ, Grabowski MM, et al. Metronomic capecitabine as an immune modulator in glioblastoma patients reduces myeloid-derived suppressor cells. *JCI Insight.* 2019;4(22):e130748. doi:10.1172/jci.insight.130748
9. Zhang J, Zhang Q, Liu Z, et al. Efficacy and safety of recombinant human adenovirus type 5 (H101) in persistent, recurrent, or metastatic gynecologic malignancies: a retrospective study. *Front Oncol.* 2022;12:877155. doi:10.3389/fonc.2022.877155
10. Zhang Q, Zhang J, Liu Z, et al. Recombinant human adenovirus type 5 (H101) intra-tumor therapy in patients with persistent, recurrent, or metastatic cervical cancer: genomic profiling relating to clinical efficacy. *Drug Des Devel Ther.* 2023;17:3507–3522. doi:10.2147/ddt.S429180
11. Zhang R, Cui Y, Guan X, Jiang X. A recombinant human adenovirus type 5 (H101) combined with chemotherapy for advanced gastric carcinoma: a retrospective cohort study. *Front Oncol.* 2021;11:752504. doi:10.3389/fonc.2021.752504
12. Huang L, Zhao H, Shan M, et al. Oncolytic adenovirus H101 ameliorate the efficacy of anti-PD-1 monotherapy in colorectal cancer. *Cancer Med.* 2022;11(23):4575–4587. doi:10.1002/cam4.4845
13. Wang Y, Hallden G, Hill R, et al. E3 gene manipulations affect oncolytic adenovirus activity in immunocompetent tumor models. *Nat Biotechnol.* 2003;21(11):1328–1335. doi:10.1038/nbt887
14. Derakhshani A, Hashemzadeh S, Asadzadeh Z, et al. Cytotoxic T-Lymphocyte Antigen-4 in colorectal cancer: another therapeutic side of capecitabine. *Cancers (Basel).* 2021;13(10):2414. doi:10.3390/cancers13102414
15. Wang B, Zhong C, Liao Z, et al. Effectiveness and safety of human type 5 recombinant adenovirus (H101) in malignant tumor with malignant pleural effusion and ascites: a multicenter, observational, real-world study. *Thorac Cancer.* 2023;14(30):3051–3057. doi:10.1111/1759-7714.15101
16. Niu CG, Zhang J, Rao AV, Joshi U, Okolo P. Comparative effectiveness of immunotherapy and chemotherapy in patients with metastatic colorectal cancer stratified by microsatellite instability status. *World J Clin Oncol.* 2024;15(4):540–547. doi:10.5306/wjco.v15.i4.540
17. Wang L, Zhang T, Zheng Y, et al. Combination of irinotecan silicasome nanoparticles with radiation therapy sensitizes immunotherapy by modulating the activation of the cgas/sting pathway for colorectal cancer. *Mater Today Bio.* 2023;23:100809. doi:10.1016/j.mtbio.2023.100809

ImmunoTargets and Therapy

Dovepress

Publish your work in this journal

ImmunoTargets and Therapy is an international, peer-reviewed open access journal focusing on the immunological basis of diseases, potential targets for immune based therapy and treatment protocols employed to improve patient management. Basic immunology and physiology of the immune system in health, and disease will be also covered. In addition, the journal will focus on the impact of management programs and new therapeutic agents and protocols on patient perspectives such as quality of life, adherence and satisfaction. The manuscript management system is completely online and includes a very quick and fair peer-review system, which is all easy to use. Visit <http://www.dovepress.com/testimonials.php> to read real quotes from published authors.

Submit your manuscript here: <http://www.dovepress.com/immunotargets-and-therapy-journal>