

Infantile Bullous Pemphigoid: A Case Report

Nouf F Bin Rubaian¹, Omar Mohammed Alakloby¹, Deemah S Alhuraish², Nasser Alzoabi¹, Jamal Alqahtani¹, Sara Omar AlAkloby¹, Fatma A Aljindan³

¹Dermatology Department, Imam Abdulrahman Bin Faisal University, King Fahad Hospital of the University, Khobar, Saudi Arabia; ²College of Medicine, Imam Abdulrahman Bin Faisal University, Khobar, Saudi Arabia; ³Pathology Department, Imam Abdulrahman Bin Faisal University, King Fahad University Hospital, Khobar, Saudi Arabia

Correspondence: Deemah S Alhuraish, Email Deemahalhuraish@gmail.com

Background: Infantile bullous pemphigoid (IBP) is an exceptionally rare acquired autoimmune subepidermal bullous disorder characterized by vesicles, bullae, and additional manifestations, such as urticarial and infiltrated papules, plaques, or eczematous lesions. These skin lesions can lead to eroded and crusted regions after healing, and in some cases, rapid blister rupturing causes extensively eroded areas. Reporting these rare cases is crucial to improving our understanding, diagnosis, and treatment of IBP.

Case Presentation: In this report, we present the clinical case of a 4-month-old male infant with generalized tense bullae causing irritability and sleeplessness. This case highlights the distinctive clinical features of IBP, including the development of multiple generalized tense bullae over 2 weeks. The pathological examination findings confirmed the diagnosis of IBP.

Conclusion: This case emphasizes the significance of early identification and proper management of IBP. Our thorough assessment, which incorporates pathological verification and therapeutic interventions, has advanced our understanding of IBP. Additionally, this case underscores the vital need for timely diagnosis and personalized treatment approaches for affected infants.

Keywords: direct immunofluorescence, immunoglobulin G, complement factor C3, blistering skin lesions, Infant, Pemphigoid

Introduction

Infantile bullous pemphigoid (IBP) represents the clinical specificities of an acquired autoimmune subepidermal bullous disorder known as bullous pemphigoid in children. IBP is characterized by circulating autoantibodies against BP180 and BP230 antigens, which are components of hemidesmosomes of the basement membrane zone.¹ The prevalence of bullous pemphigoid is higher among older individuals, and its occurrence in childhood, particularly infancy, is rare. Epidemiological data on IBP prevalence and incidence remain largely unknown, underscoring the need for further research in this area.^{2,3}

IBP is characterized by the development of numerous vesicles and bullae on the skin, which may manifest on seemingly unaffected and erythematous skin. Urticarial and infiltrated papules, plaques, or eczematous lesions may also be observed. The blisters exhibit a tense quality with a diameter of 1–3 cm or potentially larger. They also contain a transparent exudate and may endure for a prolonged duration, resulting in eroded and crusted regions after healing.³ In some cases, the blisters rupture rapidly, promoting extensive eroded areas.³

The diagnosis of IBP primarily relies on direct immunofluorescence (DIF), which reveals a linear deposition of immunoglobulin (IgG) and/or complement factor C3 at the dermo-epidermal junction. The prognosis of IBP is generally favorable, as indicated by the potential for spontaneous remission and infrequent relapses triggered by infections or gradual tapering of corticosteroid therapy. The efficacy of systemic corticosteroids at a dosage of 1–2 mg/kg as an initial treatment course, which is gradually tapered subsequently to mitigate the risk of rebound effects, has been reported in large case series.³

Case Report

The patient, a 4-month-old Saudi male infant, was brought to the hospital by his family owing to generalized multiple tense bullae on an erythematous base. The bullae initially appeared on his feet and soles a month prior but progressed to

the trunk and extremities over 2 weeks. The bullae were large, soft, and often surrounded by erythematous skin. The infant's caregivers reported that the bullae caused significant discomfort, leading to increased irritability and difficulty sleeping.

Regarding perinatal history, the infant's mother received regular antenatal care and had no history of any drug use. The infant was born vaginally at full term without any complications, and the mother adhered to the recommended supplementation regimen. The infant had been exclusively breastfed. The infant's immunization history was up to date, and there were no known adverse reactions to vaccines or any personal or family history of cutaneous or autoimmune diseases.

During the examination, the infant appeared well and exhibited normal vital signs. Clinical examination of the skin revealed several tense bullae on an erythematous base distributed across the scalp, face, trunk, and extremities. In addition, crusts and annular erythematous urticarial plaques with superficial vesicles were observed on the trunk and extremities. No mucosal lesions were observed (Figure 1).

Based on a comprehensive assessment, the laboratory findings indicated leukocytosis (leukocytes: $51.3 \text{ K}/\mu\text{L}$, reference range: $5\text{--}15 \text{ K}/\mu\text{L}$), eosinophilia (eosinophils: $55 \times 10^3/\mu\text{L}$, reference range: $0\text{--}5 \times 10^3/\mu\text{L}$), and thrombocytosis (platelets: $847 \times 10^3/\mu\text{L}$, reference range: $150\text{--}450 \times 10^3/\mu\text{L}$) in the patient. Histopathological examination of a skin punch biopsy specimen revealed a subepidermal bulla with spongiosis and a pseudovacuolar interface change in the epidermis. In addition, a superficial perivascular mixed inflammatory infiltrate with eosinophils and mild fibrosis were observed in the dermis (Figure 2). DIF analysis revealed a linear deposition of complement factor C3 and IgG along the dermo-epidermal junction (Figure 3). Salt-split skin analysis was not performed. These findings provide valuable insights into the histopathological and immunological characteristics of IBP, supporting its diagnosis and emphasizing the need for further investigation into the mechanisms underlying the disease development.

Considering the clinical presentation and laboratory and pathological results, the diagnosis of IBP was established. The patient was treated with oral prednisolone ($1 \text{ mg}/\text{kg}$) for 4 months and showed partial improvement. As the child developed new blisters and a few urticarial plaques over the trunk and extremities, topical steroid mometasone was additionally administered ($1.5 \text{ fingertip units}$) twice daily. Subsequently, as the infant exhibited weight gain (90th percentile) and a blood pressure of $131/81$

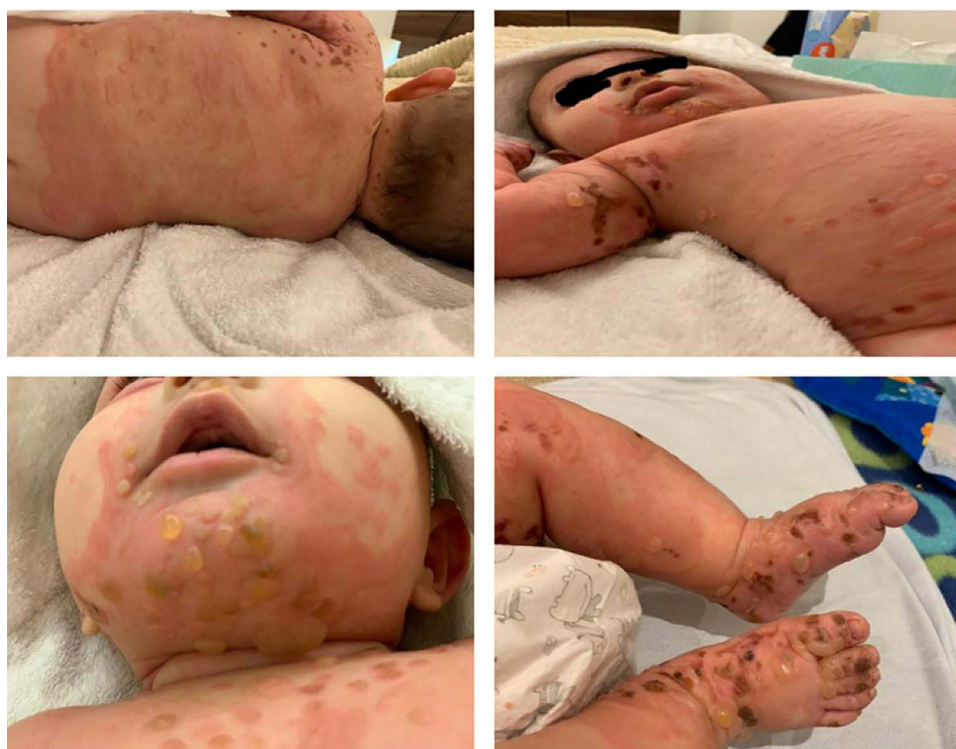

Figure 1 Multiple widespread tense bullae over the entire body, with crusted erosion on the lower limbs.

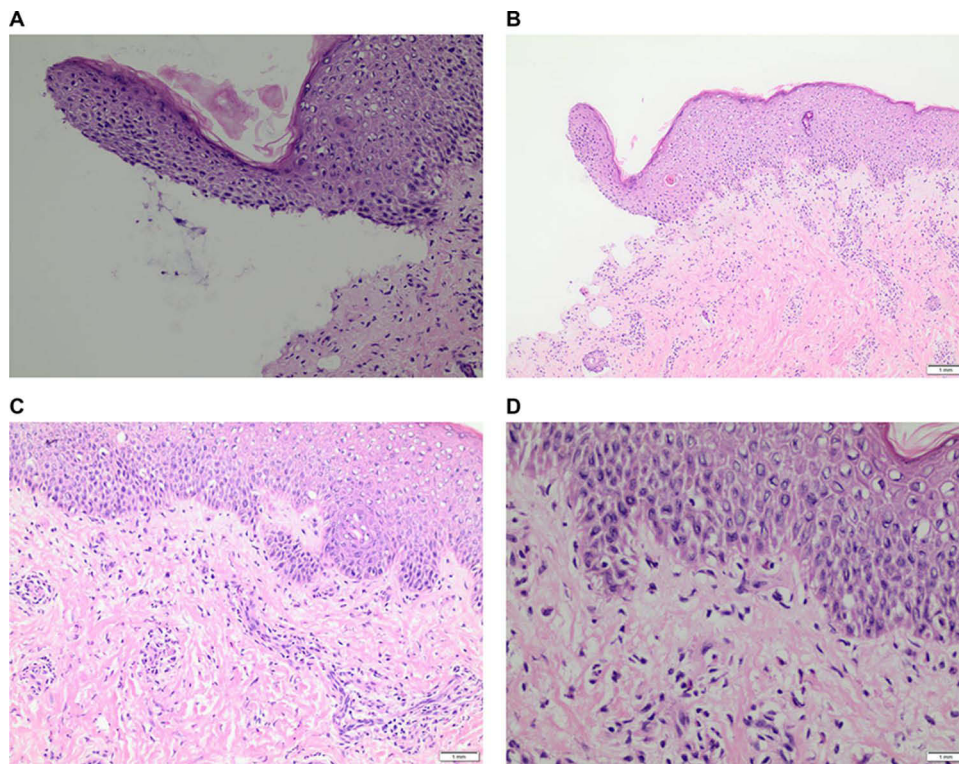


Figure 2 Skin punch biopsy specimen reveals a subepidermal blister (A) with spongiosis (B) and pseudovacuolar changes in the epidermis (C). Superficial perivascular mixed inflammatory infiltrate with eosinophils (D) and mild fibrosis are observed in the dermis.

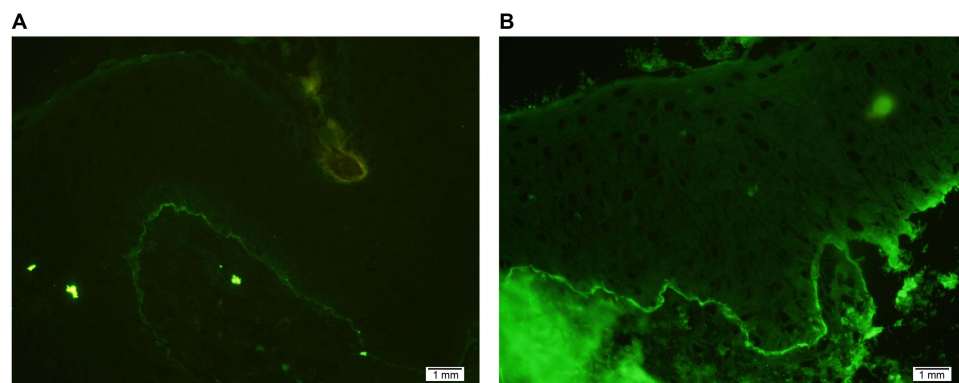


Figure 3 Direct immunofluorescence of the skin specimen shows a linear deposition of complement C3 and immunoglobulin G along the dermo-epidermal junction (A and B).

mmHg (90th percentile), 2 mg/kg dapsone (20 mg) was additionally administered as a steroid-sparing agent. Then, prednisolone was gradually tapered and discontinued over 4 months, with a maximum of 1–2 new bullae observed monthly, except in the last month before prednisolone discontinuation. The patient did not develop any new lesions. Dapsone was continued for 4 months after prednisolone discontinuation, and all lesions resolved. After 1 year of treatment, the patient discontinued dapsone and has not presented with any lesions since then. In addition, his weight and blood pressure returned to normal.

Discussion

The precise incidence of IBP is unknown.² The first confirmed case of IBP, as determined using immunofluorescence, was published in 1970. Since then, there has been a significant increase in the number of documented and published cases.⁴

IBP typically manifests between the ages of 3 and 5 months, with no sex-related differences. The clinical characteristics of the disease vary between infants and older children. In infants aged <1 year, bullous pemphigoid is characterized by the presence of blisters on the palms, soles, and face, whereas these characteristics are observed in only a few older children. Additionally, genital involvement is less common in infants with bullous pemphigoid, whereas it is present in approximately 50% of older children with bullous pemphigoid. This difference in genital involvement suggests that the distribution of lesions in cases of bullous pemphigoid may change as children age.²⁻⁵

In cases of pediatric bullous pemphigoid, large tense bullae are primarily observed in specific areas, such as the inner thighs, groin, abdomen, forearms, axillae, palms, soles, and mucous membranes.⁵ However, in cases of IBP, the clinical lesions tend to be more widespread with less involvement of the mucous membranes and a predilection for acral areas (such as palms and soles). Conversely, in cases of pediatric bullous pemphigoid, the disease is more severe and less uniform, with the possibility of localized lesions in the genital area. Therefore, the presence of palmoplantar lesions can serve as a diagnostic predictor of IBP.²⁻⁶

The etiology of IBP remains unknown; however, several triggering factors have been reported, including nonspecific maternal antibodies and foreign antigens, such as infectious agents, drugs, and vaccines.⁷ The implicated vaccines include diphtheria, tetanus, pertussis, poliomyelitis, influenza, hepatitis B, meningococcal C, pneumococcus, bacille Calmette-Guérin, and rotavirus vaccines.⁷ The onset of the disease typically occurs within a latent period of 1 day to 4 weeks after vaccination. Notably, most cases of IBP have been observed following the administration of the first vaccination dose. Vaccination is considered to unmask subclinical bullous pemphigoid by stimulating an autoimmune response in individuals already predisposed to immunological reactions.^{5,6,8}

The clinical presentation of bullous pemphigoid can mimic that of various dermatoses, making it challenging to distinguish it from other bullous diseases affecting children, such as dermatitis herpetiformis, acquired epidermolysis bullosa, bullous systemic lupus erythematosus, or linear IgA bullous dermatosis. In addition to considering the patient's medical history, performing a thorough physical examination, and analyzing histopathological samples, diagnostic tests such as immunofluorescence, indirect immunofluorescence (using the salt-split skin technique), immunoblotting, and enzyme-linked immunosorbent assay are used to improve diagnosis.^{4,5}

The prognosis of IBP is generally favorable, with the possibility of spontaneous remission and infrequent relapses triggered by infections or corticosteroid tapering. The primary treatment strategy involves administering steroids at a dosage of 1–2 mg/kg, with gradual tapering to prevent rebound effects. Regarding patients requiring alternative treatments, such as sparing agents, further investigation is warranted to determine the effectiveness of these treatments. Potential treatment options include dapsone, intravenous Ig (IVIG), mycophenolate mofetil, erythromycin, methotrexate, cyclophosphamide, azathioprine, rituximab, omalizumab, and dupilumab, as recently reported in a case study, particularly in refractory or severe cases.^{4,5,8,9}

Infants and children with bullous pemphigoid generally respond well to treatment, often achieving remission within several weeks to a few months. It is crucial not to withhold treatment in cases of generalized bullous pemphigoid to avoid the risk of significant morbidity and mortality. Infantile patients typically exhibit a swift response, ranging from a few days to several months, and relapses are rare in this population. Conversely, lower and slower response and higher relapse rates are observed in adults treated with corticosteroids, dapsone, IVIG, or combinations of these treatments.^{4,5,8}

Conclusion

IBP is a rare but critical condition that significantly affects affected infants. A combination of clinical, laboratory, and histopathological assessments, particularly DIF, is required for an accurate diagnosis. Managing IBP can be challenging, with systemic corticosteroids administered as the recommended initial treatment, which may need to be supplemented with other therapies, such as dapsone or IVIG, in refractory cases.

Despite the difficulties in treatment, the prognosis of IBP is generally favorable. Infants and children with IBP often respond well to appropriate management, achieving remission within weeks to months. Timely and proper treatment is essential to prevent significant morbidity and mortality associated with generalized bullous pemphigoid in this population.

Ethics Approval and Consent for Publication

Prior to the publication of this case report, written informed consent was obtained from the patient's parents, who granted permission for the use of photographs and medical data. Additionally, institutional ethical approval was obtained from the Institutional Review Board of Imam Abdulrahman Bin Faisal University.

Acknowledgments

The authors thank all the colleagues in the department who contributed to this case study.

Author Contributions

All authors have made substantial contributions to the work presented in this article, including the conception, study design, execution, data acquisition, analysis, and interpretation. They have actively participated in the drafting, revision, and critical review of the manuscript. Each author has approved the final version to be published, agreed on the journal of submission, and accepted responsibility for all aspects of the work.

Disclosure

The authors declare that they have no competing interests in this work.

References

1. Moro F, Fania L, Sinagra JLM, Salemme A, Di Zenzo G. Bullous pemphigoid: trigger and predisposing factors. *Biomolecules*. 2020;10(10):1432. PMID: 33050407, PMCID: PMC7600534. doi:10.3390/biom10101432
2. Schwieger-Briel A, Moellmann C, Mattulat B, et al. Bullous pemphigoid in infants: characteristics, diagnosis and treatment. *Orphanet J Rare Dis*. 2014;9(1):185. PMID: 25491396, PMCID: PMC4302581. doi:10.1186/s13023-014-0185-6
3. Di Zenzo G, Della Torre R, Zambruno G, Borradori L. Bullous pemphigoid: from the clinic to the bench. *Clin Dermatol*. 2012;30(1):3–16. PMID: 22137222. doi:10.1016/j.clindermatol.2011.03.005
4. Reis-Filho EG, Silva Tde A, Aguirre LH, Reis CM. Bullous pemphigoid in a 3-month-old infant: case report and literature review of this dermatosis in childhood. *An Bras Dermatol*. 2013. 88(6):961–965. Erratum in: *An Bras Dermatol*. 2014;89(5):854. Dosage error in article text. PMID: 24474106, PMCID: PMC3900348. doi:10.1590/abd1806-4841.20132378
5. Bisherwal K, Pandhi D, Singal A, Sharma S. Infantile bullous pemphigoid following vaccination. *Indian Pediatr*. 2016;53(5):425–426. PMID: 27254056. doi:10.1007/s13312-016-0867-3
6. Pankakoski A, Panelius J, Salava A, Kluger N. Bullous pemphigoid in three paediatric patients in Finland. *Acta Derm Venereol*. 2020;100(6):adv00086. PMID: 32157316, PMCID: PMC9128883. doi:10.2340/00015555-3445
7. Neri I, Greco A, Bassi A, et al. Bullous pemphigoid in infant post vaccination: myth or reality? *Int J Immunopathol Pharmacol*. 2016;29(2):295–299. PMID: 26684642, PMCID: PMC5806709. doi:10.1177/0394632015603796
8. Waisbourd-Zinman O, Ben-Amitai D, Cohen AD, et al. Bullous pemphigoid in infancy: clinical and epidemiologic characteristics. *J Am Acad Dermatol*. 2008;58(1):41–48. PMID: 17945382. doi:10.1016/j.jaad.2007.08.010
9. Zhang Y, Xu Q, Chen L, et al. Efficacy and safety of dupilumab in moderate-to-severe bullous pemphigoid. *Front Immunol*. 2021;12:738907. doi:10.3389/fimmu.2021.738907

Clinical, Cosmetic and Investigational Dermatology

Dovepress

Publish your work in this journal

Clinical, Cosmetic and Investigational Dermatology is an international, peer-reviewed, open access, online journal that focuses on the latest clinical and experimental research in all aspects of skin disease and cosmetic interventions. This journal is indexed on CAS. The manuscript management system is completely online and includes a very quick and fair peer-review system, which is all easy to use. Visit <http://www.dovepress.com/testimonials.php> to read real quotes from published authors.

Submit your manuscript here: <https://www.dovepress.com/clinical-cosmetic-and-investigational-dermatology-journal>