

Use of fMRI to predict psychiatric adverse effects of interferon treatment for Hepatitis C – preliminary report

Donald H Marks^{1,2}
 Mehdi Adineh²
 Binqun Wang²
 Sudeepa Gupta²

¹Department of Medicine, Cooper Green Mercy Hospital, Birmingham, Alabama, USA; ²Research Associate, Wallace Kettering Neuroscience Institute, Kettering, Ohio, USA

Abstract: Interferon alfa2 (IFN- α 2) is a parenterally administered cytokine used to treat patients with Hepatitis C and B, and malignancy. Interferon (INF) has a relatively high rate of central nervous system (CNS) adverse effects, including agitation, depression, fatigue, cognitive dysfunction, suicidal thought and drug craving. Using functional magnetic resonance imaging (fMRI) we studied patients with Hepatitis C virus (HCV) infection who were not more than mildly clinically depressed at baseline for their CNS reaction to IFN- α 2. During fMRI, patients underwent visual stimulation with pictures designed to induce feelings of depression. In the two patients who became clinically depressed or markedly anxious while on treatment with interferon, but not in patients who did not experience these effects, there was a significant activation in specific areas of the brain known to be involved with depression, along with an increase above baseline in the Beck Depression Scale for the patient who developed INF-induced depression. The activation pattern differed from that previously observed for endogenous depression, indicating that INF-induced depression may differ in its underlying neuropathology. Functional magnetic resonance imaging can be an important tool in understanding and monitoring for (INF and other) medication-induced CNS effects, and response to treatment.

Keywords: fMRI, interferon, depression, anxiety, agitation, assay, SSRI, antidepressant

Introduction

Although the number of Americans with HCV infection has declined about ten-fold from the 1980s to 2001, estimates (McQuillan 2004) show that as many as four million persons have been infected with HCV. No vaccine is available to prevent Hepatitis C, unlike for Hepatitis A and B, and carriers can transmit the disease (via blood and body fluids) throughout the remainder of their life. Hepatitis C has an enormous effect on morbidity and mortality. Perhaps eighty percent of infected people in the United States show signs of chronic infection, which over a period of 5–20 years may lead to liver cirrhosis (20%) and or liver cancer (Pagliaro 1999). Approximately 25% of patients with cirrhosis will die from hepatic failure or require liver transplantation; HCV is responsible for about one-third of all liver transplants in the United States.

Interferons are a family of cytokines – biologic mediators produced by leukocytes that have therapeutic application for a wide spectrum of disease states, including cancer and infectious diseases such as Hepatitis C and B. Interferon alpha 2 (IFN- α 2) is a cytokine which is endogenously produced by leukocytes upon viral infection, explaining why IFN- α 2 has proven therapeutic effectiveness against chronic Hepatitis C and B infection.

Many patients receiving INF experience flu-like symptoms early in treatment, but these symptoms typically diminish with continued treatment. Patients also can experience GI disturbances, arthralgias, and injection site reactions (Prescribing Information).

Correspondence: Donald H Marks
 9340 Helena Road, Suite F-414, Hoover,
 Alabama 35244, USA
 Tel/Fax +1 603 372 4813
 Email dhmarks@yahoo.com

Interferon alpha 2 has been shown to have a wide range of neuromodulatory properties in the CNS. These include the regulation of endocrine systems such as upregulation of the hypothalamic-pituitary-adrenal axis. Interferon alpha 2 can modulate behavior, brain activity, temperature, feeding pattern and endogenous opioid activity. Neuropsychiatric effects from IFN- α 2 can include apathy, anxiety, cognitive changes, irritability, depression, suicidal thoughts, drug craving and mania (Prescribing Information; Onyike 2004).

Although not all patients with HCV develop neuropsychiatric symptoms when treated with INF, investigators have reported that between 10% and 40% of patients experience depressive symptoms. Overall, interferon dosage must be reduced in many patients and discontinued in as many as 40% of patients because of severe side effects. Other than avoiding use of INF in individuals with significant underlying depression, there is currently no way to predict whether an individual will respond to interferon by developing adverse neuropsychiatric effects. It will therefore be of immense value to be able to predict and monitor in a quantifiable manner a clinically significant depressive response to interferon (and other therapeutic modalities) in patients prior to the initiation of treatment. The purpose of this ongoing study is to apply an imaging methodology using fMRI to detect and monitor neuropsychiatric adverse effects of interferon (and other drugs) treatment for HCV (and other diseases), and monitor the response to interventions to treat these neuropsychiatric adverse effects.

Methodology

Patients with Hepatitis C infection, and who were candidates for therapy with INF- α 2 were screened. Those subjects without excluding medical history or disqualifying medical exam were explained the study purpose and design, risks and benefits, and asked to give informed consent for participation in the Institutional Review Board (IRB)-approved protocol: Use of fMRI to Predict Neurologic Adverse Effects of Interferon Used to Treat Patients with Hepatitis C and HIV-Infected Patients Treated with Sustiva. Patients received interferon and other treatment as part of their usual care for Hepatitis C. Patients did not automatically receive a new prescription for antidepressants as a prophylactic action prior to therapy with INF.

Data acquisition

Testing (Beck Depression Scale, medical history, fMRI) was performed at baseline (prior to INF treatment), and at six weeks of therapy, or sooner if the patient developed clinically

significant psychiatric symptoms. The Beck was the only psychiatric rating scale used, and structured interviews were not used to generate psychiatric diagnoses.

Patients were seen routinely at 2, 4, 6, 8 weeks of treatment, and monthly thereafter, unless their medical condition required otherwise. At each visit, patients were interviewed, questioned about anxiety, depression, insomnia, agitation, suicidal thoughts, drug craving and other psychiatric symptoms, and a subjective assessment of the onset of mood disorders was made.

To perform functional magnetic resonance imaging, each test subject lay within a GE Cigna 3-T Signa 11X Excite MRI scanner, wearing a phased array whole head coil, mounted with a 45 degree mirror. This arrangement allowed test subjects to see images displayed onto a rear projection screen positioned by their feet. Functional MR imaging was performed while viewing of the test stimuli in order to capture functional data (Marks 2006). A short localizer MRI scan was performed to verify that the field of view was within the skull, and that there were no "ghost" images. A high-resolution full volume structural MRI scan was then obtained for each subject, using fast SPGR imaging (146, 1.0-mm thick axial slices, no spaces, TR = 8, TE = 3.2, FOV = 24 cm, 256 \times 256 matrix). These T1-weighted images provided detailed anatomical information for registration and 3-D normalization to a standard atlas.

Changes in the blood oxygen level dependent MRI signal were measured using a gradient-echo echoplanar sequence. Continuous functional Neuroimaging (fMRI) scans lasted 110 seconds each. EPI parameters were: TE 35, TR 2000, multiphase screen, 55 phases per location, interleaved, flip angle 90, delay after acquisition-minimum. Using a visual stimulus package, color photographs were presented in a mini-block design while Neuroimaging was performed. In a typical session, after a 4 second lead-in time, a blank screen was displayed for 4 seconds, then the picture of interest for 4 seconds, and this was repeated for the scan time.

Test stimuli

Visual stimuli (four pictures of a depressing nature, Figures 1–4) were generated by PC using PowerPoint (Microsoft). The pictures were projected onto a rear projection screen placed at the foot of the test subject, who viewed the screen by means of a mirror system mounted on the head coil.

Data analysis

The fMRI scan volumes were motion-corrected and spatially smoothed in-plane, normalized and analyzed using MedX,



Figures 1



Figure 2



Figure 3



Figure 4

as described elsewhere (Marks et al 2006). The data was analyzed for the presence of neuroimaging activation that has been shown to correspond to depression.

Results

Two of the four HCV patients (AA and BB) imaged (Table 1), did not experience clinical depression nor was there an increase observed in the Beck Depression scores at six weeks of treatment when compared to baseline. For these persons, the baseline fMRI (Figure 5) did not differ in the number of activation areas from that seen at six weeks of treatment with interferon (Figure 6). This indicated that INF itself does not cause an activation of the brain which was detectable using our system.

One individual (CC) did experience significant depression while receiving interferon, with a corresponding increase (17–29)

in Beck Depression Scale (Table 1). She had experienced depression in the past, although those episodes were not as severe as the depression that occurred during interferon treatment. Her sisters have also experienced depression. Patient CC had a hysterectomy 24 years previously and was on hormone replacement therapy.

Another patient (DD) experienced significant agitation without depression from treatment with INF, and did not have a change (20–16) in Beck Depression Scale (Table 1). Patient DD had an oophorectomy 3 years before this study and her last menstrual period was a year before entering treatment with interferon. She did not have a past history of clinically significant depression or agitation, and there was no family history of psychiatric illness.

The fMRI activation map for patient CC (who developed depression), after only two weeks of therapy with INF,

Table 1 Demographic characteristics of study subjects

	Subject Initials			
	AA	BB	CC	DD
Age	67	64	47	42
Sex	M	F	F	F
CNS-active meds	No	No	No	No
H/O IVDU	Yes	No	Yes	Yes
Suicidal thoughts	No	No	No	No
Initial Hep C Viral load	283,000	11,000,000	3,750,000	3,270,000
Previous H/O any psychiatric illness	No	No	Yes	No
H/O substance abuse	Yes	No	Yes	Yes
F/H psych illness	N	N	Sisters	N
Interferon	Peg-Intron	Pegasys	Peg-Intron	Pegasys
BDS before INF	2	14	17	20
BDS on INF	5	13	29	16
Mood disorder	No	No	Depression	Anxiety/agitation
Reversible	n/a	n/a	Yes	Yes

Abbreviations: BDS, Beck Depression scale, before and after onset of clinical depression; CNS-active drugs, amphetamine, cocaine, antidepressants, others; f/h, family history; h/o, history of; IVDU, intravenous drug abuse.

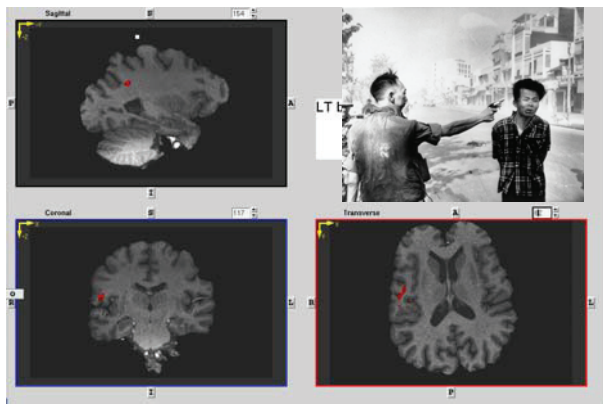


Figure 5 Functional MRI at baseline. A representative section of the baseline brain MRI of one (AA) of the test subjects who did not develop any CNS symptoms after six weeks of interferon therapy. Visual stimulus #2 (Figure 2) was used to generate this scan. There are only a few areas of activation (red). This pattern of lack of activation was seen in all test subjects who did not develop clinical depression while on treatment with INF.

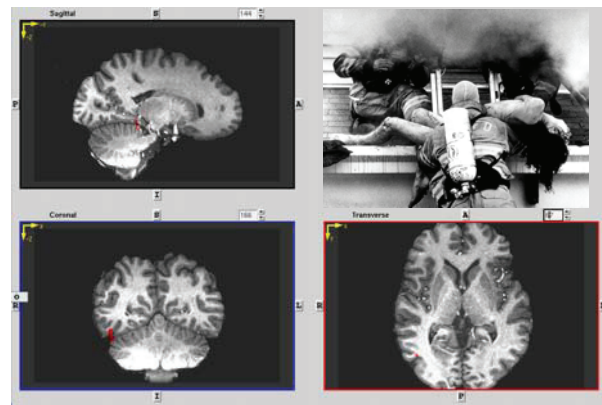


Figure 7 Baseline functional MRI of patient patient CC, who developed interferon-induced depression after two weeks of treatment. A representative section of the baseline brain MRI of one (CC) of the initial test subjects who did develop CNS symptoms (clinically significant depression) after only two weeks of interferon therapy. Visual stimulus #4 (Figure 4) was used to generate this scan. The lack of significant activation is consistent with that of individuals who did not experience depression at baseline (Figure 5) or after interferon treatment (Figure 6).

showed significant increase in areas of activation (Figure 8, and Table 2) when compared to baseline (Figure 7). The activation map (not shown) for patient DD, who developed significant anxiety but no depression, showed also increased areas of activation (Table 2). A limitation of the study was the use of only the Beck psychiatric rating scale and not utilizing a structured interview to generate psychiatric diagnoses. We will incorporate these additional techniques in our follow-up studies.

Those individuals who did not become depressed during INF use had less than a five-point rise of the Beck Depression

Scale (BDS) during INF use. The patient (CC) who developed significant depression on INF had mild depression at baseline (Beck score 17) and experienced significant and incapacitating depression (Beck 29) during INF use, requiring a reduction in INF dose. After the dose reduction, the symptoms of depression resolved, and use of antidepressants was not required. A second person (DD) experienced significant increased in agitation/anxiety from INF therapy, but not depression on questioning. There was no increase in the Beck Depression Scale, but there was a change in fMRI response that correlated with CNS symptoms. This patient

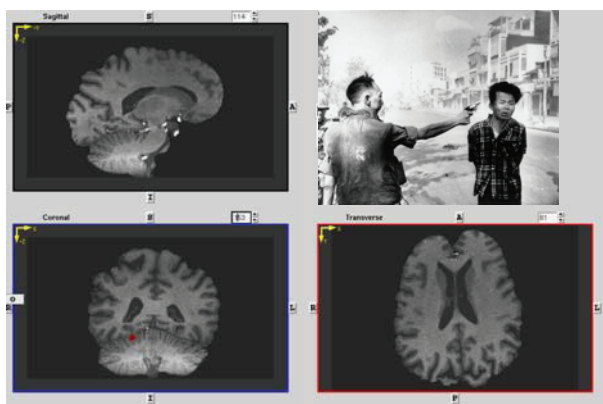


Figure 6 Functional MRI after six weeks of interferon in a representative subject who did not show interferon-induced activation. A representative section of the brain MRI at six weeks of one (AA) of the test subjects who did not develop any CNS symptoms after six weeks of interferon therapy. Visual stimulus #2 (Figure 2) was used to generate this scan. There are no significant areas of brain activation (red) over baseline (Figure 5). There was no significant change in the Beck Depression scale. This lack of activation was seen in all subjects who did not develop clinical depression while on treatment with INF.

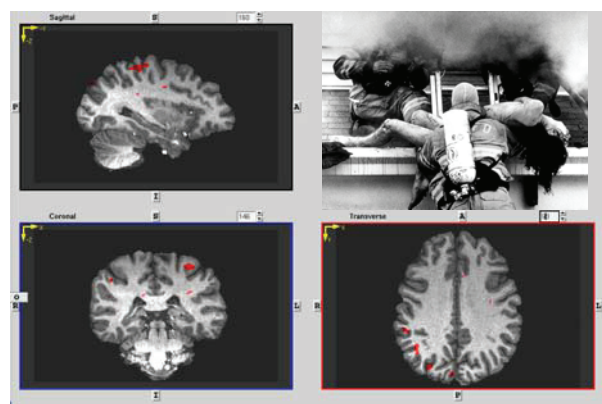


Figure 8 Functional MRI for patient CC at 2 weeks of therapy, showing multiple areas of interferon-induced CNS activation. A representative section of the brain MRI of one of the subjects (CC) who did develop CNS symptoms (clinically significant depression) after interferon therapy, in this case after only two weeks of INF. Visual stimulus #4 (Figure 4) was used to generate this scan. There is a significant increase in multiple activation areas (red areas) over baseline (Figure 9, Table 2). There was also a significant increase in the Beck Depression Scale (Table 1) over baseline.

Table 2 Activation areas for patients who developed clinically significant depression (CC) or agitation (DD) while on INF therapy, compared to patients with MDD (Fu et al 2004, Table 2)

Broadman Area	Brain Region	patient	CC	CC	CC	DD	DD	Fu (Table 2)
		Visual stimulus	2	3	4	4	1	
1								
2								
3								
4	precentral gyrus							
5								
6	premotor cortex							
7	precuneus							
8	sup frontal gyrus							
9								
10	L MID FRONTAL GYRUS							
11								
12								
13	L insula							
14								
15								
16								
17								
18	sup frontal gyrus							
19								
20								
21	LMiddle temporal gyrus							
22	L Superior temporal gyrus							
23	mid cingulate gyrus							
24	ant, mid and post cingulate gyrus							
25								

(Continue)

Table 2 (Continued)

26								
27	parahippocampal gyrus							
28								
29								
30	parahippocampal gyrus							
31	post cingulate gyrus							
32								
33	ant cingulate guryys							
34								
35								
36								
37	inf temp cortex							
38								
39	L superior temporal gyrus							
40	L inf parietal cortex							
41								
42								
43								
44								
45	R inferior frontal							
46	R mid frontal cortex							
47	L Inferior frontal gyrus							

Activation areas with fMRI from two patients who developed clinically significant and reversible depression (CC) and agitation/anxiety (DD) from interferon, compare to those with endogenous MDD studied Fu et al (2004, Table 2). Patients viewed photos of a depressing nature (Figures 1–4) during fMRI

responded to an anxiolytic medication, but did not require a reduction in dosage of INF.

Discussion

Even though we present preliminary data on a limited number of subjects, several points are of interest:

1. The data indicate that it is possible to detect clinically significant medication-induced depression and anxiety with a fMRI assay,
2. The MRI scan verifies that patients who did not develop clinical depression/anxiety as determined by the Beck Depression Scale and physician assessment, also did not develop activation of those areas of the brain known to correlate with clinical depression,
3. This preliminary data supports not giving prophylactic medications (selective serotonin reuptake inhibitors (SSRI)) to all patients who are going to receive interferon therapy.

In pharmaceutical development and in clinical practice, it is important to study the potential for medication-induced neurologic adverse effects. There have been a very limited number of studies using MRI on the effects of drugs on the brain. Functional MRI studies can be used to identify areas in the brain with increased metabolic responses, indicating increased activity. One example has been the effect of levodopa in drug-naïve Parkinsons patients (Buhmann 2003).

Apart from its antiviral activity, IFN has been shown to have a wide range of neuromodulatory properties in CNS. For example, studies in experimental animals have shown that IFN- α decreases dopamine in the brain (Shuto 1997). INF are known (Prescribing Information) to be related to a wide range of neurologic adverse effects including aggressive behavior, apathy, anxiety, cognitive changes, depression, irritability, and in some individuals, suicidal thought/ideation, suicide, homicidal ideation, drug craving, psychoses, hallucinations, bipolar disorders, and mania. Although not all patients with HCV develop neuropsychiatric symptoms, most published references cite an incidence of depression of 10% and 40% (Prescribing Information; Meyers 1991; Pavol 1995). Pegylate IFN- α used in the treatment of chronic Hepatitis C has itself been associated with a significantly lower incidence of depression in comparison to unmodified IFN- α (Fried, Shiffman, Reddy et al 2002). Russo et al (2005) found that irritability in patients with HCV being treated with interferon was associated with decreased plasma tryptophan levels which may lead to attenuated peripheral and central serotonergic neurotransmission.

High dose IFN- α 2 can cause neuropsychological deficits, with slowing of cognitive processes, diminished executive skills and memory difficulties (Capuron 2005). An “adynamic state” may occur, with loss of cognitive, verbal, and motor spontaneity, incentive, and interest (Meyers 1991; Pavol 1995). These symptoms are consistent with a frontal-subcortical dysfunction, an area found by Fu et al (2004) to be favorably affected by antidepressants.

Peripherally given IFN- α 2 has significant effects on cerebral glucose metabolism in human subjects, which predominate in the prefrontal cortex and co-vary along with depression scores (Juengling 2000). In fact, the changes in prefrontal cortical activity might be interpreted as a “vulnerability factor” for the development of depressive symptomatology in patients treated with IFN- α 2.

Several risk factors are thought to increase the probability of emergent psychiatric comorbidity during IFN- α treatment (Edlin 2001; Fried 2002; Dieperink 2003). Those

factors include: a previous history of any psychiatric illness, a history of substance abuse, a family history of psychiatric illnesses, and a history of suicidal ideation, and these risk factors were monitored for in our patients population. Applying these criteria for the four persons reported herein (Table 1), there appeared to have been a low risk for developing psychiatric adverse effects from use of INF, yet two patients did!

Various researchers (Douglas 2005; Raison 2005) have observed that individuals who experienced significant increases in depressive symptoms during peginterferon (IFN)-a/ribavirin therapy were less likely to clear hepatitis C from the blood. Specifically, failure to clear virus at 24 weeks of therapy was associated with a 20-point or greater increase in depressive symptoms, with viral genotype Type 1, and with ribavirin dose assignment. This presents another impetus to better understand the role of CNS adverse effects from INF.

Functional MRI

Functional magnetic resonance imaging (fMRI) studies can be used to identify areas in the brain with increased metabolic responses, indicating increased neural activity. The purpose of this pilot study was to evaluate the use of fMRI as a clinical predictive tool which can observe the neuropsychiatric effects of interferon, and to correlate these MRI-identified changes with symptoms of depression.

Table 3 Areas of common activation: Fu et al (2004) (MDD, major depressive disorder) and INF-induced depression and agitation

Broadman Area	
3	
5	
6	premotor cortex
21	L Middle temporal gyrus
22	L Superior temporal gyrus
23	mid cingulate gyrus
24	ant, mid and post cingulate gyrus
39	L superior temporal gyrus

Researchers have shown that functional neuroimaging provides the potential of identification and treatment of Hepatitis C patients who develop neuropsychiatric symptoms upon interferon treatment (Matthews 2004; Weissenborn 2004). One area of possible difficulty in data analysis when studying the effects of pharmacological agents with fMRI is that various medications (including that under study, and concurrent meds), may interfere with the very mechanisms that give rise to the fMRI signal (Salmeron 2002). This could occur if a medication altered the coupling of neural activity with regional cerebral blood flow and/or the extraction of oxygen from blood, or caused local or global vascular changes unrelated to neural activity.

The mood disorders induced in our two patients more likely were due to a physiologic effect of INF, rather than due just to the presence of INF alone. The activation seen on fMRI after treatment in two patients (CC and DD) with INF was not present at baseline. The symptoms reversed upon dose reduction (CC, depression) or addition of an anxiolytic (DD, anxiety). Two other patients (AA and BB) reported in this paper who were treated with INF (and in fact most of our patients at the clinic), did not develop complaints of a mood disorder, did not show changes in their Beck Depression scale, did not show increased activation in this fMRI study, and did not show signs of a mood or affect change on their regularly scheduled visits while undergoing treatment with INF. Further, because we were not able to discern activation by fMRI in our patients with no complaints (of depression, anxiety, agitation, insomnia, suicidal thought or drug craving), the lack of complaint (indicator of a mood disorder) may be equivalent to the absence of even sub-clinical INF-induced brain activation.

Previous studies of fatigue and depressive symptoms in various medical and psychiatric conditions by functional neuroimaging suggest future directions for research that may increase understanding of the specific neural substrates of neuropsychiatric side effects associated with HCV and interferon treatment. Functional brain imaging techniques have contributed greatly to the general understanding of the brain circuits that may be disrupted when neuropsychiatric symptoms are experienced by patients with major depressive disorder, multiple sclerosis, and chronic fatigue syndrome. The anterior cingulate cortex and the prefrontal cortex have been implicated frequently in the development of fatigue and depressive symptoms in various medical and psychiatric conditions. The dorsal anterior cingulate is intimately involved in cognitive processes such as response inhibition and error processing, and is also involved in modulation of the auto-

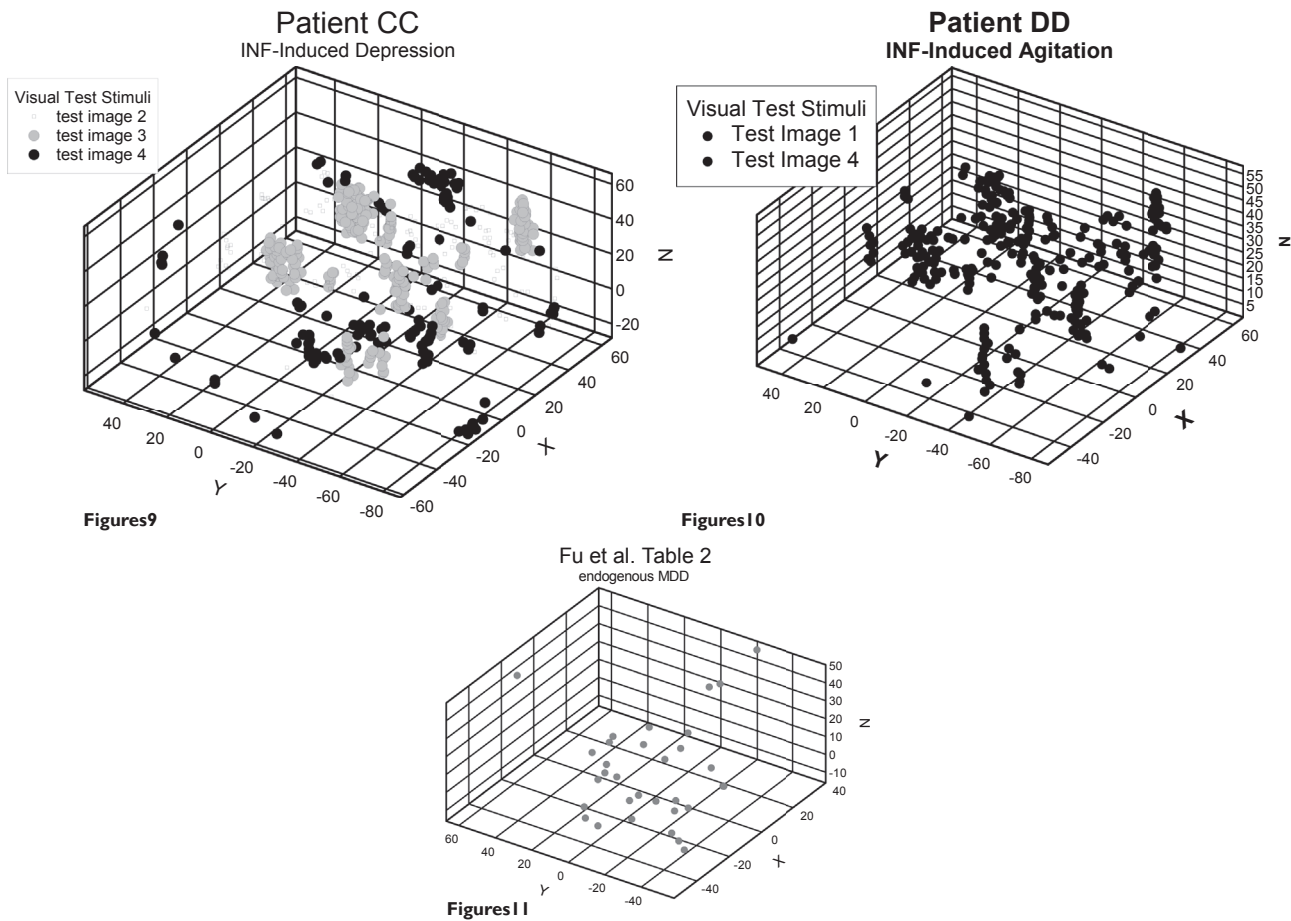
nomic nervous system (Capuron 2005). Dysfunction of the anterior cingulate cortex has been associated with the development of neuro-psychiatric symptoms in several psychiatric and medical conditions. Functional subdivisions have also been identified within the prefrontal cortex, a structure that is critically involved in the regulation of mood and affect.

Evidence from functional neuroimaging studies supports the role of the prefrontal cortex in mediating fatigue and depressive symptoms in various conditions. Many functional neuroimaging studies of major depressive disorder (MDD) used PET or fMRI (Juengling 2000) and have described altered brain activation in the dorsolateral prefrontal cortex and the dorsal anterior cingulate cortex. Hyperactivation of these structures have been consistently demonstrated in major depressive disorder. Functional MRI studies are needed to further investigate the identified role of the anterior cingulate cortex in interferon-induced depression (Capuron 2005). Hyperactivation in the ventral anterior cingulate cortex has been shown to predict future antidepressant treatment response in MDD. Specific investigation of this structure in subjects who are taking interferon may allow prospective identification of patients at risk for interferon-induced depression and initiation of prophylactic treatment for these patients.

In addition to the clinical elements detailed above, depression can be associated with interpersonal difficulties related to abnormalities in affective facial processing. Using this marker, Fu et al (2004) studied using fMRI those brain systems known to be activated by sad facial affect processing in patients with depression. They note that neurocognitive systems involved in identifying affective facial expressions in healthy individuals include:

1. The fusiform face area in the ventral occipitotemporal cortex, which shows a selective response for faces;
2. The superior temporal sulcus, which is responsive to mouth and eye movements involved in facial expressions; and
3. The amygdala (usually the left amygdala), which shows a selective response to emotional facial expressions such as fear, sadness, anger, and disgust.

In their study, Fu et al (2004) identified nineteen medication-free, acutely symptomatic patients satisfying DSM-IV criteria for unipolar major depressive disorder by age, sex, and IQ. These subjects were matched with 19 healthy volunteers. After the baseline assessment, patients received the SSRI antidepressant, fluoxetine hydrochloride, 20 mg/d, for eight weeks. Average activation and differential response to variable affective intensity were estimated in each fMRI time series. Brain regions were identified by



Figures 9, 10, 11 Three dimensional bubble plots of combined areas of activation prepared for test subjects CC (Figures 9) and DD (Figure 10). For comparison, Figure 11 presents endogenous depression activation areas from Fu et al (2004). Distinct patterns of activation were seen for drug-induced (Figure 9) and endogenous (Figure 11) depression and for agitation (Figure 10).

fMRI which demonstrated a main effect of group (depressed vs healthy subjects) and a group-time interaction (attributable to antidepressant treatment). The average activation (capacity) and differential response to variable affective intensity (dynamic range) were estimated in each fMRI time series. Brain regions were identified that demonstrated a main effect of group (depressed vs. healthy subjects) and a group-time interaction (attributable to antidepressant treatment).

Fu et al (2004) found:

1. An enhanced sad facial affect-processing capacity in the left medial temporal, ventral striatal, and insular regions,
2. Enhanced capacity for activation in patients compared with healthy volunteers at baseline, which normalizes in the course of eight weeks of antidepressant treatment, and
3. Attenuated capacity of activation at eight weeks compared with baseline.

There was increased capacity in the patients compared with the healthy comparison subjects in the following regions of the left brain:

1. Hippocampus extending to amygdala and parahippocampal gyrus, and

Table 4 Areas of non-overlap. Fu et al (2004) (MDD) yes, INF no

Broadman Area	
21	L Middle temporal gyrus
26	
32	
33	ant cingulated gyrus
36	
38	

Table 5 Areas of non-overlap. INF yes, Fu et al (2004) no.

Broadman Area	
7	Precuneus
8	sup frontal gyrus
9	
10	L mid frontal gyrus
17	
18	sup frontal gyrus
19	
31	post cingulated gyrus
40	L inferior parietal cortex
42	
44	
45	R inferior frontal
46	R mid frontal cortex

- Hypothalamus, ventral striatum (putamen/globus pallidus), insula, caudate nucleus, thalamus, dorsal cingulate gyrus, and inferior parietal cortex.

A negative correlation existed between antidepressant exposure-related changes in facial affect-processing capacity and the dynamic range of response. The overall capacity for sad facial affect processing was reduced and the dynamic range of response in prefrontal cortex was increased. Overall, Fu et al (2004) concluded that:

- Antidepressant treatment reduces left limbic, subcortical, and neocortical capacity for activation in depressed

subjects and increases the dynamic range of the left prefrontal cortex.

- Changes in anterior cingulated function were associated with symptomatic improvement,
- fMRI may be a useful surrogate marker of antidepressant treatment response.

Three dimensional bubble plots of combined areas of activation were prepared for test subjects, as shown in Figures 9 and 10. For comparison, Figure 11 presents depression activation areas from Fu et al (2004). Distinct patterns of activation were seen for depression and for agitation. We also did not find comparative activation areas between INF-induced depression (Figure 9) and endogenous MDD (Figure 11).

The differences in areas of the brain activated may point to significant differences between depression which is endogenous in nature from medication-induced depression.

We identified in our system several anatomic areas of brain activation in the two patients in our preliminary studies who developed significant depression or anxiety during INF therapy. Although we identified areas of overlap (Table 2), in general the activation pattern we observed does not correspond well to those noted by Fu et al (2004, their Table 2) in their study of the treatment of non-medication induced endogenous MDD. Table 3 lists areas of the brain showing common activation in our model and that of Fu et al (2004).

On the other hand, there were significant areas of non-overlap, with activation noted by Fu et al (2004) but not in our model (Table 4).

There were also significant areas of non-overlap (Table 5), with activation in our model, but not that of Fu et al (2004).

The model we have developed for INF-induced depression/anxiety has wide application, and we are planning on extending our studies in INF, and apply the techniques to other medications, including the antidepressants and the amphetamine-like drugs used to treat attention deficit

Table 6 Activation across images Patient CC showed brain activation above baseline while viewing visual stimulations 2,3,4, while patient DD showed activation with pictures 1 and 4




					
Patient CC	Depression		X	X	X
Patient DD	Anxiety	X			X

Table 7 Similarity between two patients in areas of brain activation while viewing visual stimulation #4

Broadman Area	Brain Region	patient	CC	DD
		Visual stimulus	4	4
1				
2				
3				
4	precentral gyrus			
5				
6	premotor cortex			
7	precuneus			
8	sup frontal gyrus			
9				
10	L MID FRONTAL GYRUS			
11				
12				
13	L insula			
14				
15				
16				
17				
18	sup frontal gyrus			
19				
20				
21	LMiddle temporal gyrus			
22	L Superior temporal gyrus			
23	mid cingulate gyrus			
24	ant, mid and post cingulate gyrus			
25				
26				
27				
28				
29				



(Continue)

Table 7 (Continued)

30	parahippocampal gyrus			
31	post cingulate gyrus			
32				
33	ant cingulate guryys			
34				
35				
36				
37	inf temp cortex			
38				
39	L superior temporal gyrus			
40	L inf parietal cortex			
41				
42				
43				
44				
45	R inferior frontal			
46	R mid frontal cortex			
47	L Inferior frontal gyrus			

hyperactivity disorder (ADHD). Of interest, the patient (DD) who developed clinically significant anxiety did not show a corresponding increase in Beck Depression Scale, but did show significant activation in several brain regions above that seen at baseline. This indicates that fMRI can be more sensitive in detecting clinically significant CNS adverse effects of medication than a written instrument such as the Beck Depression Scale. We are investigating further the relationship between written measures of CNS adverse effects of medication and corresponding physiologic (fMRI) brain activation. Another area we are exploring is the relationship between the intensity of the CNS adverse effect of medication which is experienced, and the intensity, pattern, persistence and response to therapy (dose modification, use of SSRI and other medications) as measured by fMRI.

These preliminary data indicate that drug-induced depression may be fundamentally different in terms of areas of brain activation from that of endogenous depression. In fact, when one considers the potential psychopathology in patients with HCV under treatment with INF, it is a wonder that the

observed rate of depression in patients infected with HCV is not higher than that reported. Some of the over 280 patients in our clinic with HCV have an underlying depressive or anxiety disorder, and are former illicit drug users (IV or others, including cocaine). As a group, they are often symptomatic of their underlying infection (weak, nauseous, abdominal pain, decreased appetite ...) probably from ongoing liver inflammation, and CNS effects of chronic HCV infection itself. On top of all this, their exposure to INF creates another layer of brain activation, as illustrated in our research, heightening the risk for depression. Because INF-associated depression may be different in actual psychopathology from endogenous depression, the optimal prophylaxis and treatment may differ in many ways (including use of SSRI) from that for MDD.

One of our patients (CC) experienced INF-induced depression, while the other (DD) developed INF-induced agitation/anxiety. There was a great deal of overlap of the areas of the brain activated in these two patients (Figures 9, 10, and Table 2), not allowing for distinguishing by activation pattern. All patients viewed the same four sets of visual stimuli (Figures 1–4), but did not show activation with all pictures (Table 6). Patient CC

(depression) did not have activation for image 1, and patient DD (anxiety) did not have activation for images 2 and 3. This difference may be due to the nature of their underlying adverse reaction to INF (depression for CC and agitation/anxiety for DD), or due to a number of other factors, including individual-specific perceptions of these affective photographs. The differences may disappear or become more understandable as we increase the number of individuals enrolled in the protocol and tested.

Table 7 shows that there was fair agreement on areas of brain activation for the one picture (test image #4) that stimulated both patients who developed clinically significant mood disorder, although there were areas that uniquely stimulated either patient CC or patient DD. Whether this is disease (depression vs. agitation) dependent, related more to the test subject, or other variables will hopefully be better understood as we increase the numbers of persons imaged.

At each office visit, we routinely ask all patients in the HCV clinic about the presence of agitation, aggression, depression, drug seeking, headache, insomnia, suicidal ideation and other symptoms. Reports indicate that between 10% and 40% of patients on INF experience depressive symptoms, and that interferon dosage must be reduced in many of these of patients and discontinued in 5%–15% because of severe side effects (Meyers et al 1991; Pavol et al 1995; Roche PI 2007). Our own observation in a patient population of over 280, with 110 patients under treatment with INF for HCV is that approximately 5%–10% experience INF-induced depression. We are analyzing our patient data to try and account for this apparently milder depressive profile in our clinic.

Our data extends the application of fMRI as a monitoring tool for medication-induced depression. Building on these initial encouraging results, we plan to image more HCV patients receiving INF to increase the data sets. We are investigating the dose-response of interferon to fMRI indices of clinical depression, and studying the therapeutic response of SSRI meds and INF dose reductions as treatment of INF-induced depression.

Acknowledgments

We are grateful to St. Vincent's Hospital in Birmingham, Alabama for the generous use of their 3T MRI imaging time, and Cooper Green Mercy Hospital for use of their clinical facilities.

References

Buhmann C, Glauche V, Sturenburg HJ, et al. 2003. Pharmacologically modulated fMRI-cortical responsiveness to levodopa in drug-naïve hemiparkinsonian patients. *Brain*, 126:451–61.

Capuron L, Pagnoni G, Demetrashvili M, et al. 2005. Anterior Cingulate activation and error processing during interferon-alpha treatment. *Biol Psychiatry*, 58:90–6.

Dieperink E, Ho SB, Thuras P, et al. 2003. A prospective study of neuropsychiatric symptoms associated with interferon-alpha-2b and ribavirin therapy for patients with chronic hepatitis C. *Psychosomatics*, 44:104–12.

Douglas SD. 2005. Hepatitis C, depressive symptoms, viral load, and therapy: interactions and reactions. *Brain, Behavior, and Immunity*, 19:20–2.

Edlin BR, Seal KH, Lorvick J, et al. 2001. Is it justifiable to withhold treatment for hepatitis C from illicit-drug users? *N Engl J Med*, 345:211–14.

Fried MW. 2002. Side effects of therapy of hepatitis C and their management. *Hepatology*, 36(Suppl 1):S237–44.

Fried MW, Shiffman ML, Reddy KR, et al. 2002. Peginterferon alfa-2a plus ribavirin for chronic hepatitis C virus infection. *N Engl J Med*, 347:975–82.

Fu CHY, Williams SC, Cleare AJ, et al. 2004. Attenuation of the neural response to sad faces in major depression by antidepressant treatment. *Arch Gen Psychiatry*, 61:877–89.

Juengling FD, Ebert D, Gut O, et al. 2000. Prefrontal cortical hypometabolism during low-dose interferon alpha treatment. *Psychopharmacology*, 152:383–9.

Marks DH, Adineh M, Gupta S. 2006. Determination of truth from deception using functional MRI and cognitive engrams. The Internet Journal of Radiology [peer-reviewed serial on the Internet]. Volume 5 Number 1. URL: <http://www.ispub.com/ostia/index.php?xmlFilePath=journals/ijra/vol5n1/engram.xml>

Matthews SC, Paulus MP, Dimsdale JE. 2004. Contribution of functional neuroimaging to understanding neuropsychiatric side effects of interferon in Hepatitis C. *Psychosomatics*, 45:4, July–August 281.

McQuillan GM, Kruszon-Moran D, Kottiri BJ, et al. 2004. Racial and ethnic differences in the seroprevalence of 6 infectious diseases in the United States: Data from NHANES III, 1988–1994. *Am J Public Health*, 94:1952–8.

Meyers CA, Scheibel RS, Forman AD. 1991. Persistent neurotoxicity of systemically administered interferon-alpha. *Neurology*, 41:672–6.

Onyike CU, Bonner JO, Lyketsos CG, et al. 2004. Mania during treatment of chronic hepatitis C with pegylated interferon and ribavirin (clin case conf). *Am J Psychiatry*, 161:429–35.

Pagliari L, Peri V, Linea C, et al. 1999. Natural history of chronic hepatitis C. *Ital J Gastroenterol Hepatol*, 31:28–44.

Pavol MA, Meyers CA, Rexer JL, et al. 1995. Pattern of neurobehavioral deficits associated with interferon alfa therapy for leukemia. *Neurology*, 45:947–50.

Prescribing Information, Peg-intron (Schering) and Pegasys (Roche).

Raison CL, Broadwell SD, Borisov AS, et al. 2005. Depressive symptoms and viral clearance in patients receiving interferon-alpha and ribavirin for hepatitis C. *Brain Behav Immun*, 19:23–7.

Russo S, Kema IP, Haagsma EB, et al. 2005. Irritability rather than depression during interferon treatment is linked to increased tryptophan catabolism. *Psychosom Med*, 67:773–7.

Salmeron BJ, Stein EA. 2002. Pharmacological applications of magnetic resonance imaging. *Psychopharmacol Bull*, 36:102–29.

Shuto H, Kataoka Y, Horikawa T, et al. 1997. Repeated interferon-alpha administration inhibits dopaminergic neural activity in the mouse brain. *Brain Res*, 747:348–51.

Weissenborn K, Krause J, Bokemeyer M, et al. 2004. Hepatitis C virus infection affects the brain – evidence from psychometric studies and magnetic resonance spectroscopy. *Journal of Hepatology*, 41:845–51.

