

Abnormal position of lymph nodes in a freemartin sheep

Angela M Gonella-Díaza
Luz Zoraya Duarte
Sergio Dominguez
Pedro A Salazar

Clínica de Grandes Animales,
Facultad de Medicina Veterinaria y de
Zootecnia, Universidad Cooperativa
de Colombia, Bucaramanga, Santander,
Colombia

Abstract: In this freemartin case report the authors present the clinical and morphological findings of a freemartin ewe with an abnormal position of two lymph nodes. Freemartins, infertile females from mixed-sex twin pregnancies, are chimeras, having two cell populations: one of their own (XX DNA) and one from their male twin (XY DNA). Freemartins can have varying degrees of phenotypic masculinization, including, in some cases, having active male gonads and exhibiting male behaviors such as heat detection and aggressiveness. During the clinical examination of the freemartin ewe, a morphological abnormality of the vulva, the presence of scrotal sacs, and a lack of mammary tissue development were noted. On inspection of the vaginal channel, an extremely enlarged clitoris, resembling a penis, was found. The clinical evidence suggested freemartinism. After the karyotyping diagnosis confirmation, a necropsy was performed and samples were taken for histology and immunohistochemistry. There were two structures found in the scrotal sacs; however, these were found to be lymph nodes, not testicles, and this was confirmed by CD3 lymph protein coloration. On histological study, the phallic structure showed corpus cavernosum and tunica albuginea. The testicles were found retained inside the abdominal cavity, with the presence of atrophic seminiferous tubules. Although the position of the testicles in freemartins has been reported as highly variable, this is the first time, to the best of the authors' knowledge, that a case has been reported where lymph nodes have been found inside the scrotal sacs. It is possible that these were the inguinal lymph nodes, trapped inside the scrotum during fetal growth and development.

Keywords: freemartinism, chimera, ewe, vulva, testes

Introduction

In mixed-sex twin pregnancies an anastomosis of the placental blood vessels can occur, resulting in a common fetal circulation.¹ This situation allows the anti-Müllerian hormone of the male embryo to reach the female embryo and promote atrophy of the paramesonephric duct (Müllerian duct), as well as promoting virilization of the structures derived from the mesonephric duct. This causes the freemartin condition in the female embryo. Freemartins are chimeras, having two cell populations: one of their own (XX DNA) and one from their male twin (XY DNA). Freemartins are infertile and they can have varying degrees of phenotypic masculinization; characteristics include narrowing of the vaginal channel, clitoris hypertrophy, mammary tissue hypoplasia, and, in some cases, presence of active male gonads and exhibition of male behaviors such as heat detection and aggressiveness.² There is a high incidence of freemartinism in bovines, with the condition occurring in 92% of mixed-sex twin pregnancies.^{1,2} The incidence of

Correspondence: Angela María Gonella-Díaza
Clínica de Grandes Animales, Facultad
de Medicina Veterinaria y de Zootecnia,
Universidad Cooperativa de Colombia,
Calle 30a #33-51, Oficina 603,
Bucaramanga, Santander, Colombia
Tel/fax +57 7635 6624
Email angelamvz@gmail.com; angela.gonella@campusucc.edu.co

freemartinism is much lower in sheep: 1%–6.8% in Booroola Merino³ and 4.35% in Rideau Arcott sheep.¹

The most common morphological finding in freemartin ewes is vulval abnormalities and a narrow vaginal channel. However, there have been some reports of the presence of inguinal scrotal sacs with or without testicular content (without because in some cases the testicles were retained in the abdominal cavity or in the inguinal ring). In the current case, the two structures found in the scrotal sacs suggested testicular content. However, after morphological and histological identification, it was determined that these structures were lymph nodes and that the testes were retained in the abdominal cavity. To the best of the authors' knowledge, this is the first time a case has been reported where lymph nodes have been found inside the scrotal sacs. In this freemartin case report, the authors present the clinical and morphological findings of a freemartin ewe with an abnormal position of two lymph nodes.

Case report

Clinical findings

A Pelibüey ewe about a year and a half old was referred to the Large Animal Hospital. Because a sheepfold had only recently acquired the ewe, there were no records of its precedence, its birth, or whether it had come from a mixed-sex twin pregnancy. The owner reported that the ewe had a very small vagina that made it impossible to position a progesterone-impregnated sponge. During the clinical examination a morphological abnormality of the vulva, the presence of scrotal sacs, and a lack of mammary tissue development were noted (Figure 1). On further inspection it was noted that the vaginal channel was very short and narrow (less than 3 cm), and there was an extremely enlarged clitoris (about 2.5 cm in length), which resembled a penis (Figure 2A). In addition, the ewe showed typical male behaviors such as mounting females in heat and being aggressive toward the operator when entering the shed. The clinical evidence was suggestive of freemartinism.

Diagnosis of freemartinism by karyotype test

A blood sample from the jugular vein was taken in a vacutainer tube with 14 IU of heparin. Peripheral blood lymphocytes were cultured under sterile conditions, using standard methodologies. In addition, a karyotype analysis was performed using conventional Giemsa stain to color the chromosomes. A total of 126 metaphases from the cultured lymphocytes were analyzed, and freemartinism

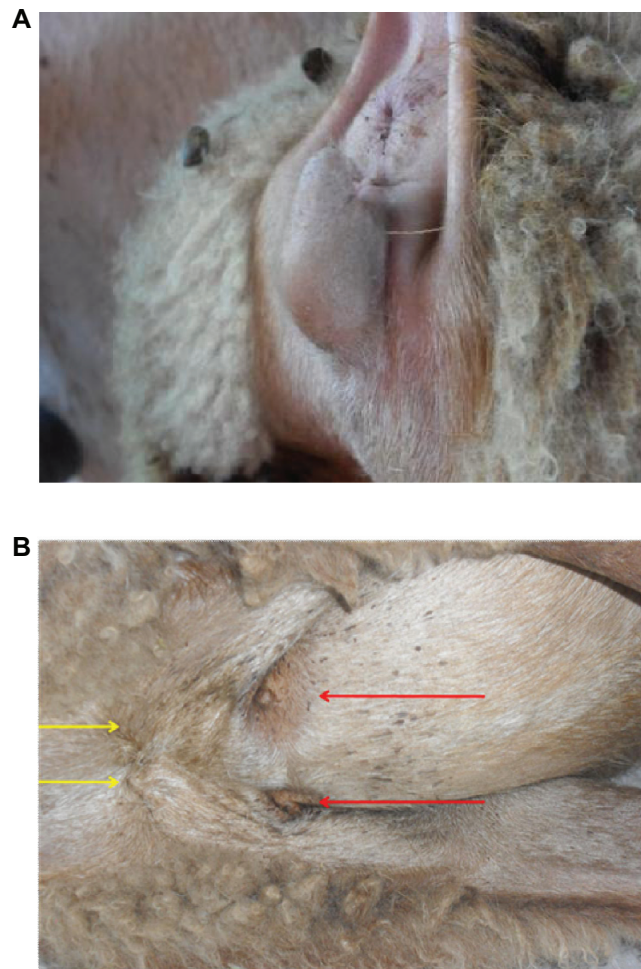


Figure 1 Phenotypic examination of the freemartin ewe: (A) appearance of the external genitalia, (note the significantly enlarged vulva); (B) the yellow arrows indicate the scrotal sacs and the red arrows indicate the poorly developed mammary glands.

was confirmed by the presence of two cell lines: 54XX (82/126 = 65%) and 54XY (44/126 = 35%).

Necropsy findings

The necropsy was performed on June 10, 2011. All the morphometric measurements of the internal organs were normal. When skin and annexes were inspected, a pendulous skin fold at the inguinal region was found. This skin had characteristics compatible with a scrotum. Inside these scrotal sacs, there were two ovoid structures, with diameters of 2.4 and 2.8 cm. The location of these structures within the scrotal sacs was suggestive of male gonads, but their external and internal appearance was not consistent with testicles (Figure 3A). Additionally, the longitudinal dissection of the vulva further revealed the phallic structure noted during the clinical examination. There was a serous

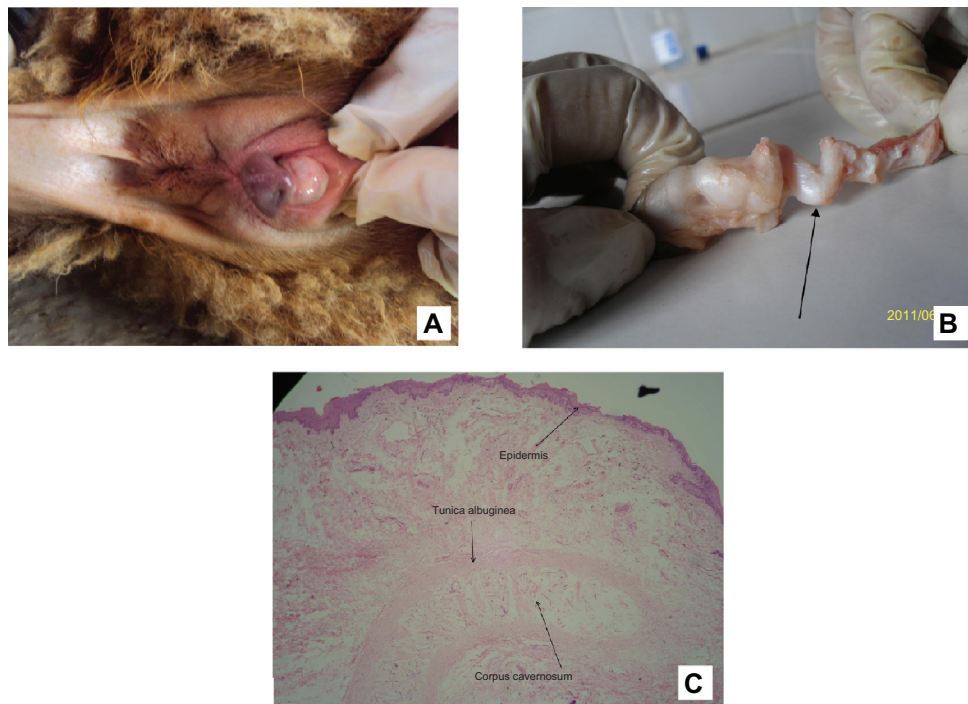


Figure 2 (A) Vulvar meatus with the projection of an enlarged clitoris resembling a penis; (B) dissection of the previously described structure (note the irregular form that looks like the sigmoid flexure of a ruminant's penis, indicated by the black arrow); (C) photomicrograph with hematoxylin and eosin stain shows the corpus cavernosum, tunica albuginea, and epidermis (10× magnification).

fold (similar to the glans penis) in the cranial portion of this structure, continued by a body of penis (3.2 cm in length) and an irregular tract similar to the sigmoid flexure of a ruminant's penis (Figure 2B). When the abdominal cavity was explored, two vascularized structures with the appearance of male gonads were found (Figure 4A). The right structure was 2.2 cm in diameter; the left one was only 0.9 cm in length and it was apparently atrophic (Figure 4B). When those structures were cut, a trabecular zone that converges to a medullary region was found. A tubular body resembling the epididymis was present on the surface of both structures. This body was continued with a vascular and sinuous structure that appeared to be the spermatic cord. The male gonadal structures were joined to the penis (penile urethra) across a series of ducts. By the conclusion of the necropsy it was evident there was an absence of female gonads and uterus.

Histological findings

Samples were fixed in 10% formalin, and histological sections were stained with hematoxylin and eosin. All the photos were taken with a digital camera (Lumix DMC-FS12; Panasonic, Osaka, Japan) adapted to a light microscope (Eclipse E200; Nikon, Tokyo, Japan). The cross-sections of the phallic

structure showed, from outer to inner sections, the following composition: epidermal layers consistent with foreskin, connective tissue, a smooth circular muscle structure consistent with the tunica albuginea, and a corpus cavernosum (Figure 2C). The male gonads found inside the abdominal cavity showed external connective tissue projected into the parenchyma, which is compatible with the testicular tunica albuginea (Figure 4C and D). The parenchyma consisted of atrophic seminiferous tubules coated with a poor germinal epithelium. The tubular body found on the surface of the testicles was confirmed as the epididymis (Figure 5A); this body presented simple cubic epithelia with fewer stereocilia than expected (Figure 5B and C). A large muscular layer and a simple cubic to flat epithelium, comprising the vas deferens, characterized the tubular structures linking the urethral tract to the gonads (Figure 6A and B). Histologically, the content of the scrotal sacs revealed a lymph node organization, rejecting the initial suspicion of testicular content (Figure 3B). The nodes comprised an outer cortex and an inner medulla, and a fibrous capsule, which had extended to form the trabeculae, surrounded them. Sinusoids and lymphoid aggregates were observed within the structures. An immunohistochemical analysis was performed in order to mark the CD3 lymphoid protein and to confirm the diagnosis. This was performed

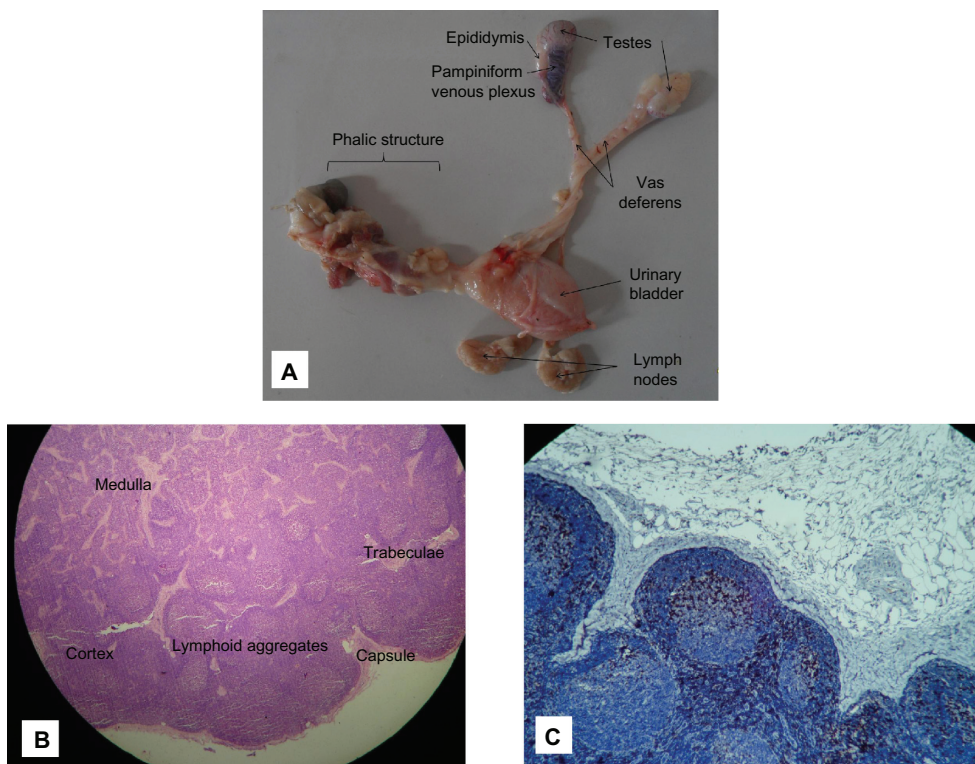


Figure 3 (A) Ex situ positioning of the freemartin ewe’s reproductive tract – note the presence of the testes (intra-abdominal) and the pair of lymph nodes (intrascrotal); (B) photomicrograph with hematoxylin and eosin stain of intrascrotal lymph nodes (40× magnification); (C) positive immunostaining for CD3 in the previously described structures.

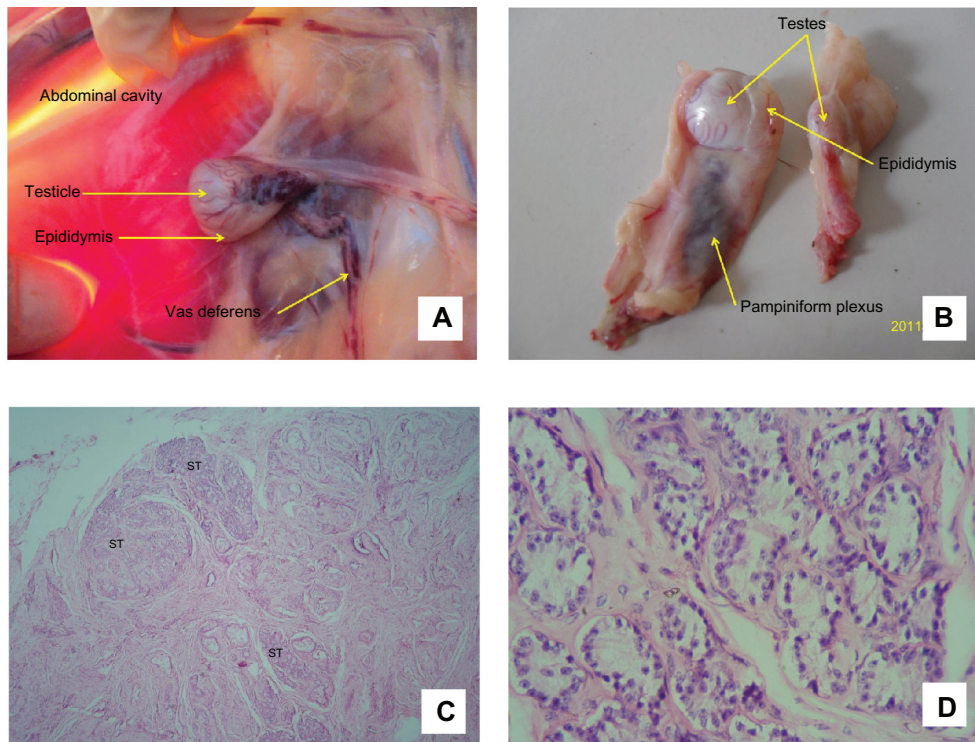


Figure 4 (A) Two structures compatible with male gonads retained inside the abdominal cavity; (B) the last structure in an ex situ position (note the vascularized tunica albuginea and the epididymis); (C) photomicrograph with hematoxylin and eosin stain (40× magnification) showing a testicular dysplasia, with a smaller proportion of seminiferous tubules (STs) than is normally expected; (D) photomicrograph with hematoxylin and eosin stain (100× magnification) showing hypoplastic seminiferous tubules (note the poor germinal epithelia).

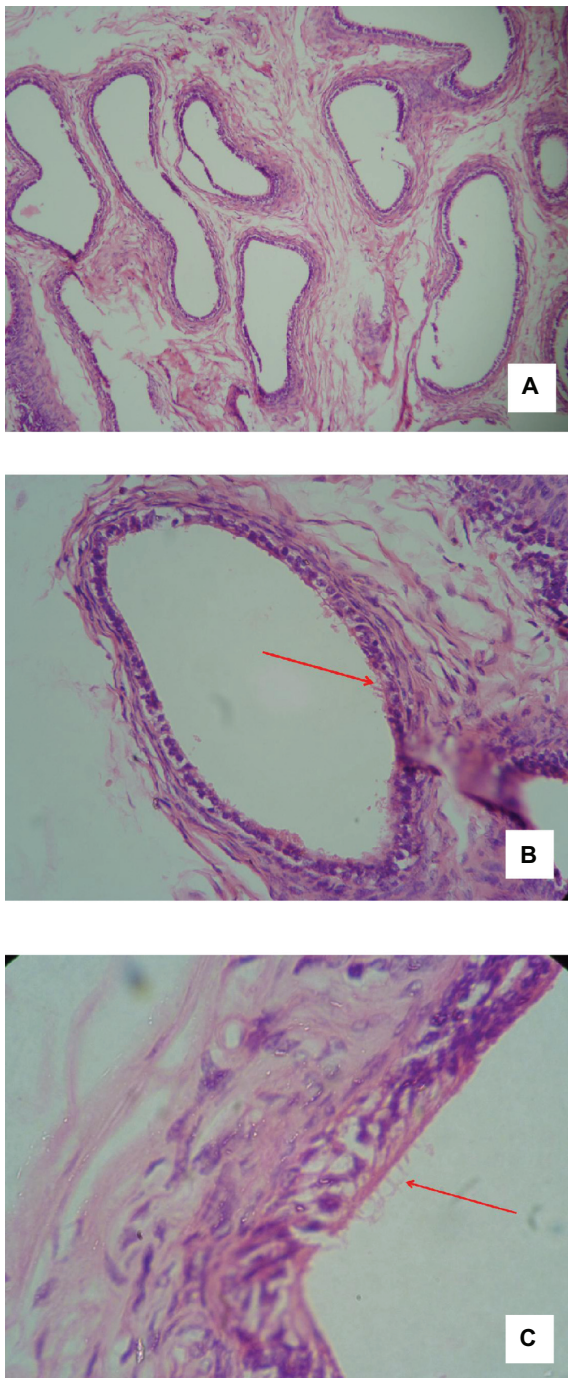


Figure 5 (A) Photomicrograph with hematoxylin and eosin stain (10× magnification) showing the epididymis and irregular tubular structures supported by interstitial connective tissue; (B) photomicrograph with hematoxylin and eosin stain (40× magnification) showing detail of the epididymal epithelia – there is an absence of pseudostratified epithelium, but a simple cubical epithelium, with some cilia, is present; (C) cilia detail (100× magnification).

using 3–5 µm tissue sections embedded in paraffin, following a standard process. To identify the CD3 protein, a monoclonal antibody was used (M7254; Dako, Glostrup, Denmark). Negative and positive controls were employed, and incubation for all assays (CD3, positive and negative control)

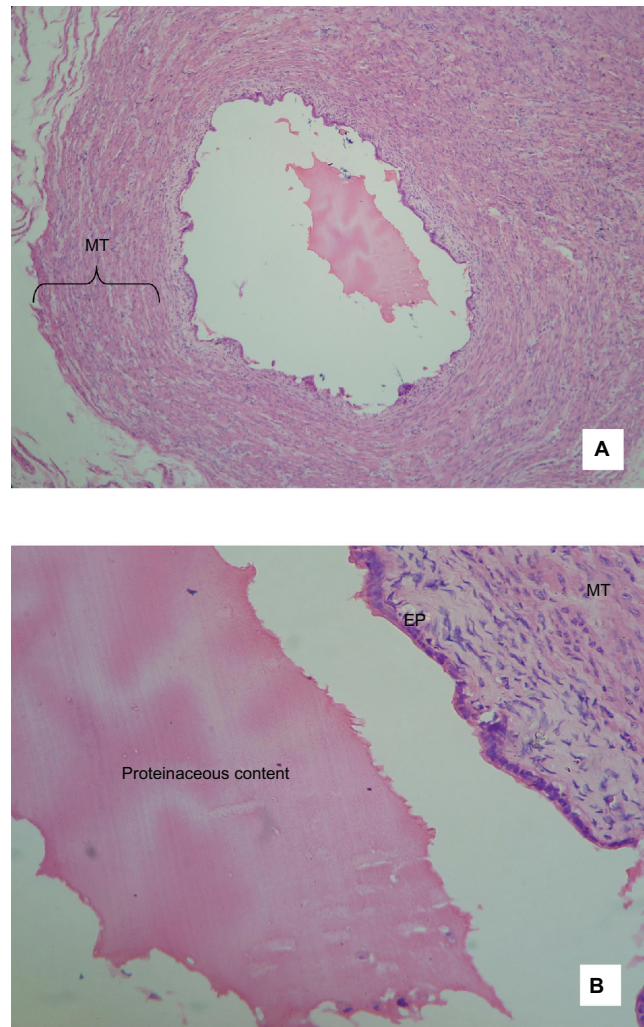


Figure 6 (A) Photomicrograph with hematoxylin and eosin stain (10× magnification) showing the vas deferens found inside the abdominal cavity (note the thickness of the muscular tunic (MT)); (B) photomicrograph with hematoxylin and eosin stain (40× magnification) showing detail of the vas deferens (note the proteinaceous content, epithelia (EP), and MT).

was carried out at room temperature for 2 hours. Stain dyes used were 3,3'-diaminobenzidine (Novocastra, Newcastle, UK) and hematoxylin. Multifocal positive immunostaining was found in both structures (Figure 3C).

Discussion

Most of the sheep breeding systems in Colombia are very low-tech, which makes it difficult to collect any productive or reproductive data. Because of this, there is no information available on twin pregnancies or the incidence of freemartinism in sheep in Colombia. Furthermore, most of the sheep producers do not measure vaginal length (less than 5 cm long indicates freemartinism) and do not perform cervical palpation.^{3,4} To date, all of the clinical reports of freemartinism made in Colombia focus on cattle.^{5,6}

The karyotype test established that the ewe was a chimera, having an XY cell line, and this confirmed the freemartin diagnosis. The necropsy findings were generally consistent with those reported by other authors. The phenotypic morphological findings for freemartins can vary, depending on the degree of masculinization. Cinzia et al⁷ evaluated nine Sarda-Lacaune backcross freemartin ewes and found different vulvar morphologies including a normal, hypoplastic, or hypertrophic vulva, with or without a hypertrophic clitoris. In contrast, the current case found a clearly enlarged and irregularly shaped vulva, with a hypertrophic clitoris similar in morphology to a penis. Additionally, Santucci et al⁸ found vaginal aplasia (1–2 cm in length), which is consistent with the findings of the current case. Other studies have also reported poor development in the mammary tissue.^{3,9}

Position of the testicles is extremely variable in freemartins: testes have been found in the scrotum, inguinal canal, abdominal cavity, and subcutaneous tissue.^{10–14} In the current case, the testes were retained in the abdominal cavity – the two structures inside the scrotum were actually lymph nodes. It is possible that these retained testicles were active, as the ewe exhibited male behaviors; however, the serum testosterone concentration was not measured, so this cannot be confirmed.

Conclusion

To the best of the authors' knowledge, this is the first time a case has been reported where lymph nodes have been found inside the scrotal sacs. It is possible that these structures were the inguinal lymph nodes, trapped inside the scrotum during fetal growth and development. Unfortunately, the likely cause of the abnormal position of the lymph nodes inside the scrotal sacs could not be determined.

Acknowledgments

The authors thank “la María” Sheepfold (Mesa de los Santos, Santander, Colombia) for kindly supplying the anatomopathological pieces required for this study, and they also thank the sheepfold owners and employees for their invaluable assistance. The authors thank the cytogenetic

laboratory of the National University of Colombia (Bogotá, DC, Colombia) for their assistance in performing the karyotype test.

Disclosure

The authors report no conflicts of interest in this work.

References

1. Brace MD, Peters O, Menzies P, King WA, Nino-Soto MI. Sex chromosome chimerism and the freemartin syndrome in Rideau Arcott sheep. *Cytogenet Genome Res.* 2008;120(1–2):132–139.
2. Ayala Valdovinos MÁ, Villagómez DAF, Schweminski Benítez SL. Cytogenetic and anatomopathologic study of the bovine freemartins syndrome (Bos Taurus) [Estudio citogenético y anatomopatológico del síndrome freemartin en bovinos (*Bos taurus*).] *Vet Mex.* 2000;31(4):315–322. [Spanish.]
3. Keszka J, Jaszczak K, Klewec J. High frequency of lymphocyte chimerism XX/XY and an analysis of hereditary occurrence of placental anastomoses in Booroola sheep. *J Anim Breed Genet.* 2001;118(2):135–140.
4. Padula AM. The freemartin syndrome: an update. *Anim Reprod Sci.* 2005;87(1–2):93–109.
5. Ghanem ME, Yoshida C, Nishibori M, Nakao T, Yamashiro H. A case of freemartin with atresia recti and ani in Japanese Black calf. *Anim Reprod Sci.* 2005;85(3–4):193–199.
6. Henao F, Quintero JC, Giraldo U, Gómez G, Sánchez JE. Histopathological findings in a case of bovine freemartinism diagnosed cytogenetically and anatomopathologically [Hallazgos histopatológicos en un caso de freemartinismo bovino diagnosticado citogenética y anatomopatológicamente.] *Revista Veterinaria y Zootecnia de Caldas.* 1998;10(1):3–6. [Spanish.]
7. Cinzia S, Iannuzzi L, Fogu G, et al. Clinical and cytogenetic studies in intersex ewes. *Caryologia.* 2006;59(1):67–74.
8. Santucci C, Iannuzzi L, Fogu G, et al. Clinical and cytogenetic studies in intersex ewes. *Caryologia.* 2006;59(1):67–74.
9. Henao FJ, Sánchez A, Gómez G. Biology of the freemartin syndrome in cattle [Biología del síndrome de freemartin en bovinos.] *Revista Veterinaria y Zootecnia de Caldas.* 2003;12(2):23–39. [Spanish.]
10. Maia Teixeira PP, Franco Oliveira ME, Comarella Lechinoski L, et al. A case of intersex in Santa Ines sheep. *Acta Veterinaria Brasileira.* 2010;4(3):199–202.
11. Palmieri C, Schiavi E, Della Salda L. Congenital and acquired pathology of ovary and tubular genital organs in ewes: a review. *Theriogenology.* 2011;75(3):393–410.
12. Ponz Mir R, Arruga Laviña MV. Diagnosis of a freemartinism case in a Rasa Aragonesa sheep [Diagnóstico de un caso de freemartinismo ovino en la raza Rasa Aragonesa.] *ITEA.* 2003;24(2):549–551. [Spanish.]
13. Smith KC, Parkinson TJ, Long SE, Barr FJ. Anatomical, cytogenetic and behavioural studies of freemartin ewes. *Vet Rec.* 2000;146(20):574–578.
14. Smith KC, Parkinson TJ, Pearson GR, Sylvester L, Long SE. Morphological, histological and histochemical studies of the gonads of ovine freemartins. *Vet Rec.* 2003;152(6):164–169.

Veterinary Medicine: Research and Reports

Publish your work in this journal

Veterinary Medicine: Research and Reports is an international, peer-reviewed, open access journal publishing original research, case reports, editorials, reviews and commentaries on all areas of veterinary medicine. The manuscript management system is completely online and includes a very quick and fair peer-review system.

Submit your manuscript here: <http://www.dovepress.com/veterinary-medicine-research-and-reports-journal>

Dovepress

Visit <http://www.dovepress.com/testimonials.php> to read real quotes from published authors.