

A Novel Ectodysplasin a Gene mutation of X-Linked Hypohidrotic Ectodermal Dysplasia

Yuan Zhuang^{1,2}, Ru Zhang^{3,4}, Miaomiao Li^{3,4}, Yaru Zou¹, Shui Jiang¹, Yanan Zhang¹, Shiguo Liu^{3,4}, Bo Yu¹

¹Dermatological Department, The Affiliated Hospital of Qingdao University, Qingdao, People's Republic of China; ²dermatological department, Women and Children's hospital, Qingdao University, Qingdao, People's Republic of China; ³Medical Genetic Department, The Affiliated Hospital of Qingdao University, Qingdao, People's Republic of China; ⁴Prenatal Diagnosis Center, The Affiliated Hospital of Qingdao University, Qingdao, People's Republic of China

Correspondence: Bo Yu, Dermatological department, The Affiliated Hospital of Qingdao University, Qingdao, People's Republic of China, Email yubo@qduhospital.cn; Shiguo Liu, Medical Genetic Department, the Affiliated Hospital of Qingdao University, Qingdao, People's Republic of China, Email liushiguo@qdu.edu.cn

Introduction: Hypohidrotic ectodermal dysplasia (HED) is a genetic disorder that influences structures of ectodermal origin, such as teeth, hair, and sweat glands. Compared with autosomal recessive and dominant modes of inheritance, the X-linked HED (XLHED) characterized by Hypodontia/Oligodontia teeth, Absent/sparse hair, Anhidrosis/hypohidrosis, and characteristic facial features, is the most frequent and its primary cause is the mutation of ectodysplasin A (EDA) gene. This research aimed to expound the clinical and molecular features of a Chinese male with XLHED and to summarize and compare several previous findings.

Methods: Genomic DNA was obtained from the peripheral blood of the proband and his family members, then Sanger sequencing was used to perform a mutational analysis of *EDA*. Real-time quantitative PCR and Western blotting were used to detect *EDA* expression. The transcriptional activity of NF- κ B was detected using a luciferase assay.

Results: The proband with XLHED was identified a novel *EDA* mutation, c.1119G>C(p.M373I), that affected the molecular analysis of transmembrane protein exon8 mutations, inherited from the mother. He showed a severe multiple-tooth loss, with over 20 permanent teeth missing and sparse hair and eyebrows, dry, thin, and itching skin. Furthermore, his sweating function was abnormal to a certain extent.

Discussion: The functional study showed that this novel mutant led to a significant decrease in the *EDA* expression level and transcriptional activity of NF- κ B. Our findings extend the range of *EDA* mutations in XLHED patients, which provides the basis and idea for further exploring the pathogenesis of XLHED.

Keywords: *EDA*, X-linked hypohidrotic ectodermal dysplasia, gene mutation

Introduction

Ectodermal dysplasia (ED) is a series of clinically and genetically heterogeneous disorders, characterised by abnormal development of the ectodermal structures, such as nails, teeth, hair, or exocrine glands¹⁻³, and with over 200 distinct clinical phenotypes. As the most common form of ED, approximately 95% Hypohidrotic ectodermal dysplasia (HED)⁴ patients have X-linked HED (XLHED),⁵ and 5% have autosomal dominant and recessive HED.^{6,7}

XLHED characterized by decreased sweating ability, hair loss or sparsity, defects in various lipid or mucous secretory glands. Abnormal or missing teeth is also an important syndrome, which is a typical feature of selective tooth hypoplasia (STA). STA can be divided into two types: tooth loss (six or more hypoplastic teeth) and tooth hypoplasia (less than six hypoplastic teeth).^{8,9} In both subtypes, the number of missing teeth does not include missing wisdom teeth, whereas central hyperthermia is the most serious complication, caused by the lack of sweat glands, which can lead to death in infants and children. Other features include a raised forehead, saddle-shaped nose, and everted lips.¹⁰ Hyperhidrotic types show hair loss, oracle bone dystrophy, and excessive keratosis on the palms and soles of the feet.^{11,12}

Although the mutations in *EDA*, ectodysplasin A receptor (EDAR), EDAR-associated death domain (EDARADD), and *WNT10a* can cause HED,¹³ the nucleotide mutation of *EDA* position in Xq12-q13.1 is the primary cause of XLHED.¹⁴ The *EDA* in the X-chromosome contains eight exons and different transcripts. The longest isomer is the foreign isomer A1 (EDA1), which has 391 amino acid residues and binds to EDAR.^{11,15–17} More than 300 growth factors (PGF), signalling molecules, and transcription factors are contained in a variety of signalling pathways, such as the NF- κ B, Sonic Hedgehog, Wnt/ β -catenin, and fibroblast growth factor pathways, which have been confirmed to take part in the growth and development of teeth and skin.^{18,19} The EDA/EDAR/NF- κ B signal pathway is indispensable for embryonic ectodermal development (EED).^{20,21} EDA is a trimeric type II transmembrane protein containing an intracellular domain,^{12,22} collagen subdomain, furin subdomain, transmembrane domain, and tumour necrosis factor (TNF) homology subdomain.²³ To be functionally active, the EDA protein is cleaved and released from the cell, where it forms a trimer that binds and activates the EDAR protein. EDA is cleaved at a particular site called the furin cleavage site.¹³

Males with XLHED are hemizygotes with *EDA* mutations, usually showing the main triple symptoms (hair loss, sweating, and sparse teeth), as well as other features, including recurrent respiratory infections, eczema, and craniofacial abnormalities, while women carrying *EDA* heterozygotes have a normal or moderate range of phenotypes, from mild HED with sparse hair and teeth to typical HED in semizygotic males.^{13,24} The identification of female XLHED carriers can be difficult because X-chromosome inactivation leads to a variety of clinical features, usually in female carriers carrying wild-type (Wt) alleles.²⁵ The phenotypic characteristics of HED patients have been proven to be awfully meaningful in clinical diagnosis, but there is no immediate relationship between mutation type and disease severity.^{7,26} Therefore, it is necessary to conduct functional studies on mutation sites and further explore the relationship between genotypes and phenotypes. To date, over 300 mutations in *EDA* have been identified, including missense, nonsense, splicing mutations, gross deletions, small indels, small insertions, small deletions, gross insertions, and complex mutations.²⁷ In this study, we reported a novel mutation in the family and introduced the results of clinical and molecular analyses of this family including those in patients with HED and female carriers, which broadens our understanding of XLHED and enables patients to receive accurate diagnoses.

Methods

Patients

The patients investigated were from a family in Qingdao, Shandong, China. The proband, a 33 year old male, was diagnosed with XLHED on the basis of associating the consequences of molecular genetic analysis with the clinical manifestations; nevertheless, none of the other family members showed analogical clinical manifestations. Peripheral blood was obtained from the proband and his relatives. We obtained the patient's written informed consent for the case details to be published.

DNA extraction

Peripheral blood was extracted from the proband. Genomic DNA was extracted by the Qiagen DNA extraction kit (QIAGEN). Whereafter the concentration of the genomic DNA was determined using a spectrophotometer (Thermo Fisher Scientific Oy Ratastie 2, FI-01620 Vantaa).

After extracted genomic DNA from all members of the family, Nanodrop 2000 (Thermo Fisher) was used to verify that the isolated genomic DNA was qualified, DNA libraries preparation was prepared by dividing qualified DNA into fragments ranging from 100 bp to 700bp with Sonication (Covaris S2, Covaris). Libraries were verified using Nanodrop 2000 and agarose gel electrophoresis (TSINGKE), and target genes were captured using biotin labeled probes and specific magnetic beads (MyGenostics). Then, the target gene was absorbed by magnetic frame (MyGenostics), washed and purified for the enrichment of the target genes. Subsequently, the qualified enriched libraries were sequenced by Illumina NextSeq 500 sequencer (Illumina) for paired-end 150 bp reads. After sequencing, low-quality variations were screened with a quality score ≥ 20 , and the filtered reads were compared with the reference human genome (hg19) using BWA. Eliminate the false positive Single nucleotide polymorphisms (SNPs) around insertions or deletions (InDels). The variation was evaluated by several bioinformatics software programs to predict their pathogenicity.

After Whole exome sequencing analysis obtained highly suspected pathogenic gene mutations, PCR for Sanger sequencing was used to amplify the upstream and downstream sequences of the mutant sites. The Primer Premier 5 software was used to design primer sequences: forward-GGTGTCTCCGGAGGCCAT and reverse-GAATCTAGGATGCAGGGGCTT for c.1119G>C/p.M373I. These PCR-amplified products were analysed using 1% agarose gel electrophoresis (TSINGKE), afterwards, the purified products were analyzed for mutation using ABI 3730 analyser (Applied Biosystems). Comparison with the National Centre for Biotechnology Information (NCBI) website (<https://www.ncbi.nlm.nih.gov/>) identified a mutation site in the proband that had not been previously identified.

Generation of expression vectors

The wild-type (WT) expression vector wild-type EDA (pCDNA3.1 (+)-Flag-EDA-Wt) marked with C-terminal FLAG was constructed. Using TRAN's Fast Mutagenesis System point mutation kit (TransGen Biotech), the mutation c.1119G>C(p.M373I) was introduced into wild-type EDA (pCDNA3.1(+)-Flag-EDA-Wt) expression vector by PCR.²⁸ For comparison, the sequence of the expression vector includes Kozak sequence signal, FLAG marker tag, junction and the coding sequence of amino acid 197–1372 of EDA. The nucleotide sequences of all vectors were confirmed by Sanger sequencing.

Generation of stable human embryonic kidney 293T (HEK293T)-EDA cells

HEK293T cells were purchased from ThermoFisher. HEK293T cells were cultured in Dulbecco's modified Eagle's medium (DMEM)(Biological Industries) supplemented with 8% foetal bovine serum (FBS), streptomycin (100µg/mL), and penicillin (100IU/mL) (Biological Industries) at 37 °C under 5% CO₂²⁹. The pCDNA3.1 (+) vector encoding the full-length EDA with a C-terminal FLAG tag was introduced into HEK293T cells. After 24h of transfection, cells stably expressing EDA were screened using puromycin. Western blotting confirmed that EDA was expressed in stable cell lines.¹⁸

Multiplex analyses using real-time quantitative PCR

HEK293T cells were inoculated in a 24-well petridish according to the manufacturer's instructions, and the empty 500ng vector (pCDNA3.1 [+]), the vector encoding EDA with a C-terminal FLAG marker, and the c. 1119G >C(p.M373I) mutant vector were introduced into HEK293T cells using LipofectamineTM3000 Reagent (Invitrogen). Twenty-four hours after transfection of the vector, the cells were harvested, and RNA was extracted using TRIzol (Vazyme) reagent. DNA was obtained by PCR reverse transcription amplification with vector-specific primers. The DNA fragment was amplified. Afterwards, the PCR-amplified products were analyzed using 1% agarose gel electrophoresis (TSINGKE) and Sanger sequencing. Real-time quantitative PCR analysis was performed. The Primer Premier 5 software was used to design primers (primer sequences: forward, CTACCTAGAGTTGCGCTCGG; reverse, AATGGCTGCTGCTTAGGTGA for EDA). GraphPad was used for statistical analysis, and a P value of <0.05 was considered statistically significant.

Western blotting

HEK293T cells were inoculated into a 12-well petridish. The empty 500ng vector (pCDNA3.1 [+]), the vector encoding EDA with a C-terminal FLAG marker, and the c. 1119G>C (p.M373I) mutant vector were introduced into HEK293T cells using LipofectamineTM3000 Reagent (Invitrogen). After 24h of transfection, the serum-free DMEM (Biological Industries) was replaced, and the cells were continuously incubated for 24h. Then the cells were lysed by the lysate (RIPA)(Beyotime) and extracted total protein. Protein concentration was surveyed by a BCA analysis kit (Vazyme). Proteins were separated using 10% SDS-PAGE and transferred to a PVDF membrane (Solarbio). The following antibodies were used: anti-EDA rabbit polyclonal antibody (Proteintech, 1:1000 dilution), anti-β-tubulin (Cell Signaling, 1:4000) and mouse anti-EDA (Cell Signaling, 1:10,000 dilution). Statistical significance was set at P value of <0.05.

Luciferase assays

In order to detect the luciferase assays of *EDA* mutations, HEK293T cells were cultured in DMEM supplemented with 8% FBS, streptomycin (100µg/mL), and penicillin (100IU/mL) (Biological Industries). The day before transfection, cells were inoculated into a 12-well culture dish. According to the manufacturer's instructions, 500ng NF-κB-TA-luc (Beyotime), PrL-TK Renilla internal reference vector (10ng) with pcDNA3.1 (+)/pCDNA3.1 (+)-FLAG-EDA /pCDNA3.1 (+)-FLAG-EDA-MT (each 500ng) were placed into each well using Lipofectamine™3000 Reagent (Invitrogen). The cells were lysed 48 h after transfection. Firefly and Renilla luciferase activities were measured by a dual luciferase assay system (Promega) on a GLOMAX (20/20 LUMINOMETER) (Promega). Firefly and Renilla luciferase activities were standardised. Each group repeated the experiment at least three times. Statistical significance was set at $P < 0.05$.

Results

Clinical and Genetic Analysis

The patient showed a severe multiple-tooth loss, with more than 20 permanent teeth missing. His hair and eyebrows were sparse, the skin was thin, dry, and itching, and his sweating function was abnormal to a certain extent. He had craniofacial abnormalities but no cleft lip, and had no ophthalmologic ailments, or intellectual problems. This patient was diagnosed with X-LHED and selective dental hypoplasia type 1. He had a missense mutation, c. 1119G>C, in exon 8 of *EDA*, which led to a change in the amino acid p.M373I (amino acid 373 changed from methionine to isoleucine). Other family members received interviews and examined, and his father and sister were asymptomatic. Sanger sequencing confirmed that this patient had a hemizygotic variation, which originated from the heterozygous variation of the mother, whereas there was no variation in the father and sister of the patient (Figure 1A and B).

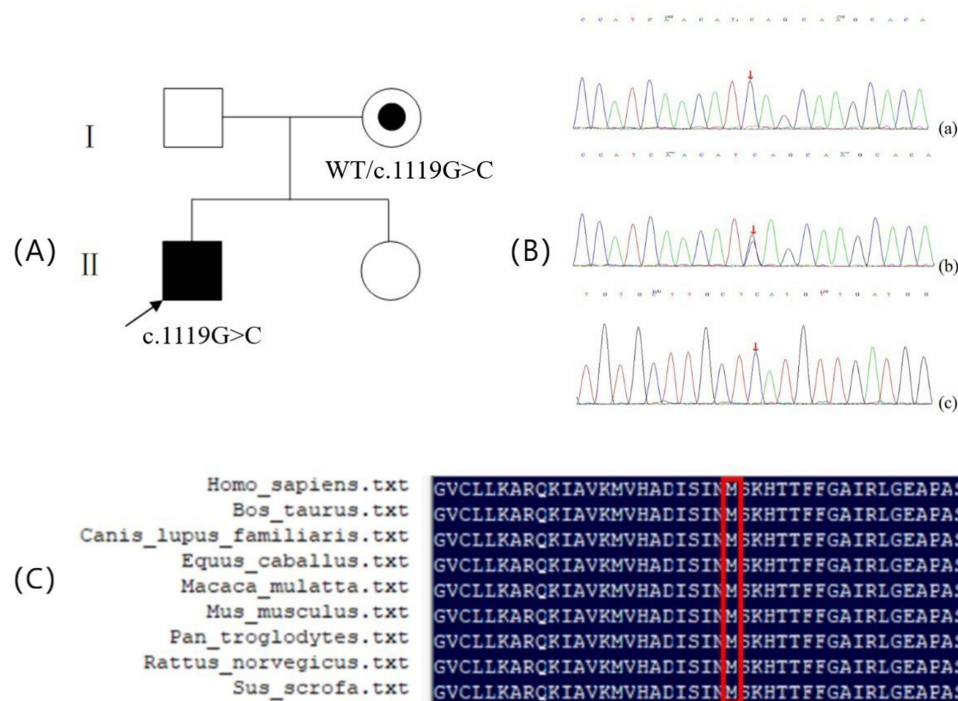


Figure 1 (A) Pedigrees and Sanger sequencing of families with *EDA* mutation: □, normal male; ○, normal female; ●, female XLHED carrier; ■, male XLHED patient; the arrow shows the proband; pedigree with those affected shown in black filled symbols. (B) Sequence chromatograms (The Red arrowhead denotes that the novel missense mutation can result in the replacement of methionine at codon 373 with isoleucine.); (a) Hemizygous mutation. (b) Heterozygous mutation. (c) Normal DNA sequence. (C) Multiple sequence alignment of *EDA* from a variety of species. The red rectangular frames indicate the locations of M373I.

Bioinformatic Analyses

According to the American College of Medical Genetics and Genomics guidelines, the mutant EDAc.1119G>C/p.M373I was initially determined to be of unknown clinical significance (uncertain). The correlation of this locus was not reported in the Human Gene Mutation Database (HGMD).

We predicted the pathogenicity of this novel *EDA* mutations and found it was predicted to be disease-causing using MutationTaster (<http://www.mutationtaster.org/>) with a score of 1, PolyPhen-2 (Polymorphism Phenotyping v2, <http://genetics.bwh.harvard.edu/pph2/>) with a score of 0.712 (possibly damaging), FATHMM (Functional Analysis through Hidden Markov Models, <http://fathmm.biocompute.org.uk/>) with a score of -3.39 (damaging), SIFT (Sorting Intolerant From Tolerant, <http://sift-dna.org>) with a score of 0 (damaging), REVEL (Rare Exome Variant Ensemble Learner, <https://sites.google.com/site/revelgenomics/>) with a score of 0.876 (damaging), LRT (Likelihood Ratio Test, http://www.genetics.wustl.edu/jflab/lrt_query.html) with a score of 0 (deleterious). GERP (Genomic Evolutionary Rate Profiling, <http://mendel.stanford.edu/SidowLab/downloads/gerp/>) with a score of 5.42 (conserved and damaging).

Protein sequences of different species, including *Homo sapiens*, *Bos taurus*, *Canis lupus familiaris*, *Equus caballus*, *Macaca mulatta*, *Mus musculus*, *Pan troglodytes*, *Rattus norvegicus*, and *Sus scrofa*, were obtained from GenBank. Multiple sequence alignment of these species using the DNAMAN software showed that p.M373 was located in the conserved position of the EDA protein (Figure 1C).

Mutant M373I EDA inhibits the expression and secretion of EDA

First, we overexpressed wild-type EDA and the C-terminal mutant M373I with a FLAG tag in HEK293T cells and performed real-time quantitative PCR for multiple analyses (Figure 2A). Compared with wild-type EDA, mutant M373I showed a lower expression level. The second step was to overexpress wild-type EDA and mutant M373I in HEK293T

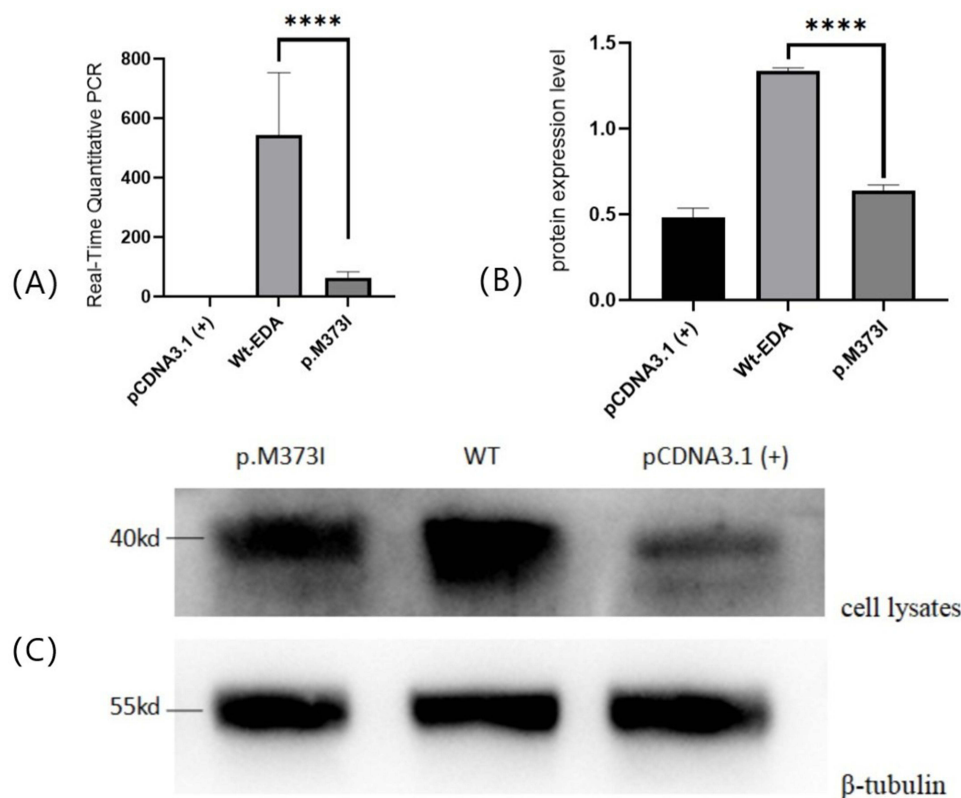


Figure 2 (A) Real-Time Quantitative PCR: Compared with wild-type EDA, the mutant EDA protein significantly inhibited the expression of EDA level. **** means $p < 0.0001$ (Student t test). (B and C) Protein expression of mutant EDA I in transfected cell. HEK293T cells were transfected with vectors encoding mutant or wild-type soluble FLAG-tagged EDA I protein, cell lysates were separately analyzed by western blotting. β -tubulin was used as a loading control. The bands showed that wild-type EDA I can produce proteins, the weaker bands of p.M373I mutations in the cell lysates showed decreased intracellular protein expression. **** means $p < 0.0001$ (Student t test).

cells, and Western blotting was used to detect EDA protein secretion in the lysates of cultured cells. The results showed that the secretion of EDA protein with the mutant M373I was significantly lower than that of the wild-type EDA protein, which further verified the pathogenicity of the mutant (Figure 2B and C).

Mutant M373I Proteins Showed Reduction in the Activation of the Downstream NF- κ B

We overexpressed wild-type EDA and mutant M373I in HEK293T cells and analysed the NF- κ B reporter. Previous studies have shown that endogenous EDA is stably expressed in HEK293T cells. It has been established that binding between EDA and its receptor induces activation of the EDA/EDAR/NF- κ B signalling pathway.⁷ To test the function of the mutant M373I, the activity of NF- κ B luciferase was determined to observe whether this mutation affect the NF- κ B pathway. The results showed that the transfection of wild-type EDA significantly increased the activity of NF- κ B. In contrast, mutant M373I weakly activated NF- κ B (Figure 3).

Discussion

ED is a series of disorders characterized by reduced sweating, sparse hair, and oligodontia with an incidence of seven cases per 10,000 live births.³⁰ XLHED is the most common type among ED and mutations in *EDA* are the major cause.^{31–33} Up till 2021, the HGMD (Professional 2021.4) has registered 364 *EDA* mutations. We show the types of mutations identified in HED patients involving this gene (Table 1). The most common type of mutation observed is missense/nonsense, which consists of a single base pair substitution in the coding region.

EDA is a TNF superfamily ligand that consists of a C-terminal TNF homologous domain, which is combined with EDAR to activate the NF- κ B pathway, and regulates the development of ectodermal organs. Many mutations can affect the receptor-binding function of the EDA protein, such as compromising the solubility and quaternary structure of the

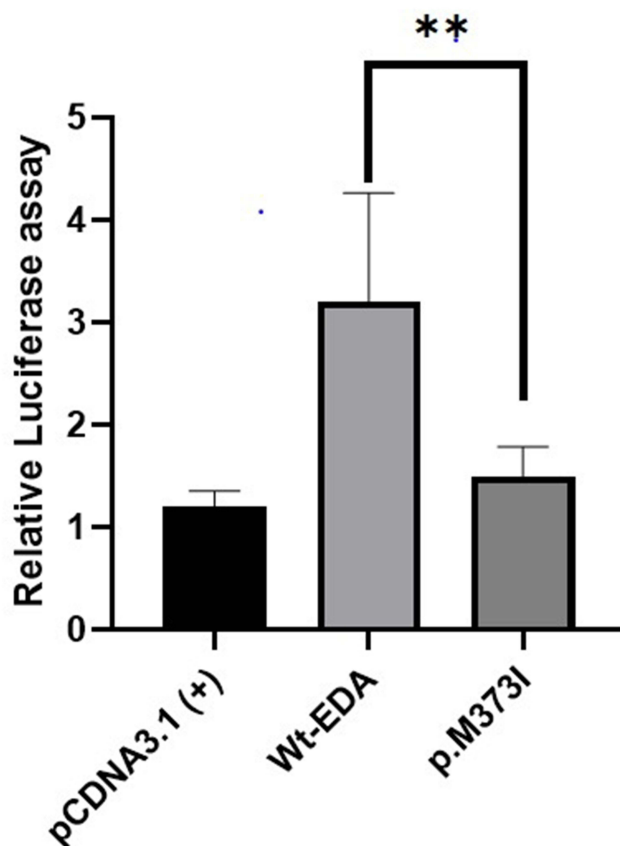


Figure 3 NF- κ B transcriptional activation of mutant EDA. The mutant EDA protein attenuated transcriptional NF- κ B activation compared to wild-type EDA. **means $p < 0.05$ (Student t test).

Table 1 EDA Gene Mutations Reported as of 2021 According to HGMD Database

Mutation type	Number of mutations reported
Missense/nonsense	203
Small deletions	57
Gross deletions	36
Splicing	32
Small insertions	23
Small indels	7
Gross insertions	5
Complex	1
Regulatory	No mutations
Repeats	No mutations

protein, or directly influencing binding to the receptor.^{12,23} NF- κ B is an essential transcription factor involved in many biological processes, including individual growth and development, inflammation, and immune responses.³⁴ As the NF- κ B pathway is a downstream effector of EDA,³⁵ damage to the EDA/EDAR/NF- κ B pathway has been shown to be a cause of ED.^{22,36,37} This signalling pathway is an essential part in embryonic ectoderm development. Gene mutations in this pathway interfere with the interaction between the underlying mesenchymal and surface epithelial cells during embryonic development, resulting in progressive changes of skin appendages, including the initiation, formation, and differentiation.⁵

In this study, we identified a novel missense mutation (c.1119G>C/p.M373I) in *EDA* based on analyses of clinical manifestations and gene sequencing. Sequence alignment for EDA protein in nine species revealed that the mutation site M373I was conserved, which may affect the stability of the homotrimer, thus affect the function of EDA protein. The molecular and cell biology experiments showed mutant M373I resulted in a significant decrease in the *EDA* expression level. Western blotting analysis also indicated that this mutant obviously affected the expression of EDA proteins. Then, we certified that the mutant M373I significantly impaired the transcriptional activation of NF- κ B compared with wild-type EDA in HEK293T cells. After this mutant overexpressed, almost no active EDA could be detected and the activation of NF- κ B pathway was significantly reduced, strongly supporting our previous inferences. In summary, *EDA* plays an indispensable role in ectoderm development, and its mutations can lead to a variety of congenital abnormalities, including dysplasia or deletion of sweat glands, hair, and teeth.

We summarised different types of *EDA* mutations identified in the last five years and their clinical features (Table 2). It is not difficult to find that most patients exhibit all the main symptoms of XLHED, namely, no or little sweating, hairless or sparse hair, few or missing teeth, and most patients have more than six missing teeth. Most patients present with craniofacial abnormalities, such as a raised forehead, a saddle-shaped nose, and everted lip. Ophthalmologic ailments include dry eye syndrome, but no significant corneal damage has been described; other eye manifestations include conjunctivitis and photophobia, skin lesion such as dry skin, atopic dermatitis/eczema, and pigmentation islands. Only a minority of the patients experience mental retardation.

Males with XLHED generally have sparse teeth, reduced sweating, or hyperhidrosis. Male patients have very dry skin and often experience eczema, dry eyes, and recurrent respiratory infections. The inability to sweat can expose patients to life-threatening high temperatures, particularly in early infancy. The severity of this disease ranges from relatively mild to very serious, and sometimes even life-threatening. Missing or nail-shaped teeth are clinically relevant because they can lead to masticatory problems and reduced nutritional intake. Stunting has been observed in many affected boys.³⁸ Due to the negative psychosocial consequences of XLHED, sparse hair can also have a significant impact on patients with XLHED from young adulthood. Therefore, novel or improved treatments for sweat gland hypoplasia and sparse hair may significantly improve the lives of patients with XLHED.³⁹ In the past 20 years, with the continuous progress of gene

Table 2 Summary of the Clinical Features and Genetic Data of Our Cases and Reported Cases in the Last Five Years

Reference	Variants	Gender	Ethnicity	Hypodontia/ Oligodontia/teeth	Anhidrosis/ Hypohidrosis	Absent/ sparse hair	AD/ eczema	Dry skin	Ophthalmologic ailments	Mental retardation	Craniofacial abnormalities
Our study	c.1119G>C	Male	Chinese	+	+	+	-	+	-	-	+
doi:10.7717/peerj.3691	c.172-173CA>GG	Male	Chinese	+	+	+	-	-	-	-	Unregistered
doi:10.1111/odi.12376	c.852T>G	Male	Chinese	+	+	+	-	-	-	-	Unregistered
	c.467G>A	Male	Chinese	+	+	+	-	-	-	-	+
	c.776C>A	Male	Chinese	+	-	+	-	-	-	-	Unregistered
	c.871G>A	Male	Chinese	+	+	+	-	-	-	-	Unregistered
doi:10.1159/000500214	c.687delT	Male	Korean	+	+	+	-	-	+	-	+
	c.1133C>A	Male	Korean	+	+	+	+	+	+	-	-
	c.871G>A	Male	Korean	+	+	+	-	+	-	-	+
	c.712delG	Male	Korean	+	+	+	-	+	+	-	+
	c.217G>T	Male	Korean	+	+	+	-	-	+	-	+
	c.463C>T	Female	Korean	+	+	+	-	+	-	+	+
	c.965T>C	Male	Korean	+	+	+	+	+	+	-	-
	c.1045G>A	Male	Korean	+	+	+	+	+	-	-	+
	c.751G>A	Male	Korean	+	-	+	+	-	-	-	-
doi:10.1016/j.archoralbio.2019.104507	c.913A> C	Male	Chinese	+	+	+	-	+	-	-	+
doi:10.3389/fgene.2022.934395	c.924+7A> G	Male	German	+	+	+	+	+	+	-	Unregistered
	c.527G>T	Male	German	+	+	+	+	+	+	-	Unregistered
	c.374C>G	Male	German	+	+	-	+	+	+	-	unregistered
	c.1174T>C	Male	German	+	+	+	-	+	+	-	unregistered

doi:10.1097/ MD.00000000000019244	c.1046C>T	Male	Chinese	+	+	+	-	+	-	-	+
	c.146T>A	Male	Chinese	+	+	+	-	+	-	-	+
	c.457C>T	Male	Chinese	+	+	+	-	+	-	-	+
doi:10.3760/cma.j.cn112144- 20,210,513-00229	c.2T>C	Male	Chinese	+	+	+	-	+	-	-	+
	c.161A>G	Male	Chinese	+	+	+	+	+	-	-	+
doi:10.1016/j. ymgmr.2021.100796	c.337C>T	Female	American	+	+	+	-	+	-	-	-
doi:10.1089/gtmb.2018.0100	c.466C>T	Male	Chinese	+	+	+	-	+	-	-	+
	c.895G>A	Male	Chinese	+	+	+	-	+	-	-	+
	c.682_683delCCinA	Male	Chinese	+	+	+	-	+	-	-	+
doi:10.3390/ diagnostics12102300	c.588_606del19bp	Female	Chinese	+	+	+	-	+	+	-	+
	c.837G>A	Female	Chinese	+	+	+	-	+	+	-	-
doi:10.1186/s13223-021- 00510-z	c.766C>T	Male	Italian	+	+	+	+	+	+	-	-
		Female	Italian	+	+	-	-	-	-	-	-
doi:10.1111/odi.12874	c.526+1G>A	Male	Chinese	+	+	+	-	+	+	-	+
doi:10.1111/1346- 8138.14252	c.646_681del	Male	Japanese	+	+	+	+	+	+	-	+
doi:10.1002/jcla.22593	c.302_303delCC	Male	Chinese	+	+	+	-	+	-	-	+
doi:10.1111/1346- 8138.14978	c.381_382delinsG	Male	Chinese	+	+	+	+	+	+	-	+
		Female	Chinese	+	+	+	+	+	-	-	+
doi:10.4103/ijid.ijd_406_21	c.924+8C>G	Male	Indian	+	-	+	+	+	-	-	+
	c.760C>T	Male	Indian	+	+	+	+	+	-	-	+

(Continued)

Table 2 (Continued).

Reference	Variants	Gender	Ethnicity	Hypodontia/ Oligodontia/teeth	Anhidrosis/ Hypohidrosis	Absent/ sparse hair	AD/ eczema	Dry skin	Ophthal mologic ailments	Mental retardation	Craniofacial abnormalities
doi:10.24875/ BMHIM.19000209	c.466C>T	Male	Mexican	+	+	+	-	+	-	-	+
doi:10.1186/s13052-021- 01078-5	c.1142G>C	Male	Italian	+	+	+	+	+	+	-	+
doi:10.1186/s11658-019- 0174-9	c.898_924 +8del35ins4CTTA	Male	Iranian	+	+	+	-	+	-	+	+
doi:10.1016/j. annder.2019.09.619	c.466C>T	Female	French	+	+	+	-	+	+	-	+
	c.467G<A	Female	French	+	+	+	-	+	-	-	+
doi:10.1111/jdv.14874	c.648_683del36	Male	Chinese	+	+	+	-	+	-	-	+
	c.925-2A>G	Female	Chinese	+	+	+	-	+	-	-	+
	c.916C>A	Male	Chinese	+	+	+	-	+	+	-	+
doi:10.1111/1346- 8138.14606	c.511A>T	Male	Japanese	+	+	+	+	+	-	-	+
	c.5delG	Male	Japanese	+	+	+	+	+	-	-	+
	c.915_922del	Male	Japanese	+	+	+	-	+	-	-	+

Notes: +: The patient has this clinical manifestation; -: The patient had no such clinical manifestations.

sequencing technology, the genetic origin of hereditary skin diseases has been well-described. As a result, these diseases are quickly identified in suspected cases, thus opening up the possibility of early genetic and therapeutic intervention for specific genetic diseases. During the past several years, prenatal disease possible using DNA testing on the embryo.³⁶ More studies are needed to promote its outstanding strengths. Early understanding of its basic characteristics, molecular diagnosis, and genetic counselling is necessary to avoid potentially life-threatening complications in infancy. With the development of new disease-correcting drugs, the need for genetic counselling and prenatal diagnosis for high-risk family members cannot be overemphasised.¹³

With continuous progress in medical research, increasing attention has been paid to HED. In recent years, considerable research has been conducted on HED and some progress has been made in its treatment. However, the signalling pathways and molecular mechanisms have not been fully elucidated. In consequence, we should collect more cases, expand the gene mutation database, and conduct experiments to further study the pathogenesis and involved pathways. Patients with a family history are actively encouraged to undergo prenatal diagnosis to reduce the possibility of disease onset. Treatment methods for the disease should be further developed to help patients eliminate the physical and mental pain and stress caused by the disease. The findings of this study aid genetic counselling and prenatal diagnosis in these families, whereas the novel mutations also extend the mutation spectrum of *EDA* in XLHED.

Abbreviations

DMEM, Dulbecco's modified Eagle's medium; ED, Ectodermal dysplasia; HED, Hypohidrotic ectodermal dysplasia; STA, selective tooth hypoplasia; EDA, ectodysplasinA; EDAR, ectodysplasin A receptor; EDARADD, EDAR-associated death domain; NF- κ B, nuclear factor- κ B; EED, embryonic ectodermal development; WES, Whole exome sequencing analysis; SNPs, Single nucleotide polymorphisms; InDels, insertions or deletions; FBS, Foetal bovine serum; DMEM, Dulbecco's modified Eagle's medium; HGMD, Human Gene Mutation Database; NCBI, National Centre for Biotechnology Information; TNF, Tumour necrosis factor; HEK293T cells, human embryonic kidney 293T cells; WT, wild-type.

Data Sharing Statement

The data analyzed in this study are available from the appropriate authors upon reasonable request.

Research Ethics and Consent

We confirm that we obtained the informed consent of the study participants and complied with the guidelines outlined in the Declaration of Helsinki. This study was approved by the Affiliated Medical Ethics Committee of Qingdao University.

Acknowledgments

We thank the proband and contributors for their participation. This work was supported in part by the National Key Research and Development Program of China under Grant no. 2016YFC1000306, National Natural Science Foundation of China under Grant no. 82071683. We thank Dr. Liu and Dr. Yu (the Affiliated Hospital of Qingdao University) for providing us with equipment and technical support.

Author Contributions

All authors contributed to data analysis, drafting or revising the article, have agreed that the article will be submitted to Clinical, Cosmetic and Investigational Dermatology, given final approval of the version to be published, and agreed to be accountable for all aspects of the work.

Funding

This work was supported by the the National Key Research and Development Program of China under Grant no. 2016YFC1000306, National Natural Science Foundation of China under Grant no. 82071683.

Disclosure

The authors report no conflicts of interest in this work.

References

1. Modi BP, Del Bel KL, Lin S, et al. Exome sequencing enables diagnosis of X-linked hypohidrotic ectodermal dysplasia in patient with eosinophilic esophagitis and severe atopy. *All Asthma Clin Imm.* 2021;17(1):9. doi:10.1186/s13223-021-00510-z
2. Zeng B, Lu H, Xiao X, et al. Novel EDA mutation in X-linked hypohidrotic ectodermal dysplasia and genotype-phenotype correlation. *Oral Dis.* 2015;21(8):994–1000. doi:10.1111/odi.12376
3. Dall'Oca S, Ceppi E, Pompa G, Polimeni A. X-linked hypohidrotic ectodermal dysplasia: a ten-year case report and clinical considerations. *Eur J Paediatric Dent.* 2008;9:14–18.
4. Nguyen-Nielsen M, Skovbo S, Svaneby D, Pedersen L, Fryzek J. The prevalence of X-linked hypohidrotic ectodermal dysplasia (XLHED) in Denmark, 1995–2010. *Eur J Med Genet.* 2013;56(5):236–242. doi:10.1016/j.ejmg.2013.01.012
5. Schneider H, Faschingbauer F, Schuepbach-Mallepell S, et al. Prenatal Correction of X-Linked Hypohidrotic Ectodermal Dysplasia. *New Engl J Med.* 2018;378(17):1604–1610. doi:10.1056/NEJMoa1714322
6. Reyes-Realí J, Mendoza-Ramos M, Garrido-Guerrero E, Méndez-Catalá C, Méndez-Cruz A, Pozo-Molina G. Hypohidrotic ectodermal dysplasia: clinical and molecular review. *Int J Dermatol.* 2018;57(8):965–972. doi:10.1111/ijd.14048
7. Wang X, Zhang Z, Yuan S, et al. A novel EDA1 missense mutation in X-linked hypohidrotic ectodermal dysplasia. *Med.* 2020;99(11):e19244. doi:10.1097/md.00000000000019244
8. Polder B, Van't Hof M, Van der Linden F, Kuijpers-Jagtman A. A meta-analysis of the prevalence of dental agenesis of permanent teeth. *Comm Dentist Oral Epid.* 2004;32(3):217–226. doi:10.1111/j.1600-0528.2004.00158.x
9. Williams M, Letra A. The Changing Landscape in the Genetic Etiology of Human Tooth Agenesis. *Genes.* 2018;9(5):255. doi:10.3390/genes9050255
10. Blüschke G, Nüsken K, Schneider H. Prevalence and prevention of severe complications of hypohidrotic ectodermal dysplasia in infancy. *Early Human Dev.* 2010;86(7):397–399. doi:10.1016/j.earlhumdev.2010.04.008
11. Lin Y, Yin W, Bian Z. Mutation detection and prenatal diagnosis of XLHED pedigree. *PeerJ.* 2017;5:e3691. doi:10.7717/peerj.3691
12. Liu G, Wang X, Qin M, Sun L, Zhu J. A novel missense mutation p.S305R of EDA gene causes XLHED in a Chinese family. *Arch Oral Biol.* 2019;107:104507. doi:10.1016/j.archoralbio.2019.104507
13. Park J, Ko J, Chae J. Novel and private eda mutations and clinical phenotypes of Korean patients with X-Linked hypohidrotic ectodermal dysplasia. *Cytogen Genome Res.* 2019;158(1):1–9. doi:10.1159/000500214
14. Liu G, Wang X, Qin M, Sun L, Zhu J. A novel splicing mutation of ectodysplasin A gene responsible for hypohidrotic ectodermal dysplasia. *Oral Dis.* 2018;24(6):1101–1106. doi:10.1186/s13223-021-00510-z
15. Yu K, Shen Y, Jiang C, Huang W, Wang F, Wu Y. Two novel ectodysplasin A gene mutations and prenatal diagnosis of X-linked hypohidrotic ectodermal dysplasia. *Mol Gen Genomic Med.* 2021;9(11):e1824. doi:10.1002/mgg3.1824
16. Döffinger R, Smahi A, Bessia C, et al. X-linked anhidrotic ectodermal dysplasia with immunodeficiency is caused by impaired NF-kappaB signaling. *Nature Genet.* 2001;27(3):277–285. doi:10.1038/85837
17. Headon D, Emmal S, Ferguson B, et al. Gene defect in ectodermal dysplasia implicates a death domain adapter in development. *Nature.* 2001;414(6866):913–916. doi:10.1038/414913a
18. Zhao K, Lian M, Zou D, et al. Novel mutations identified in patients with tooth agenesis by whole-exome sequencing. *Oral Dis.* 2019;25(2):523–534. doi:10.1111/odi.13002
19. Thesleff I. The genetic basis of tooth development and dental defects. *Am J Med Genet A.* 2006;140(23):2530–2535. doi:10.1002/ajmg.a.31360
20. Cluzeau C, Hadj-Rabia S, Jambou M, et al. Only four genes (EDA1, EDAR, EDARADD, and WNT10A) account for 90% of hypohidrotic/anhidrotic ectodermal dysplasia cases. *Human Mutation.* 2011;32(1):70–72. doi:10.1002/humu.21384
21. Koppinen P, Pispä J, Laurikkala J, Thesleff I, Mikkola M. Signaling and subcellular localization of the TNF receptor Edar. *Exp Cell Res.* 2001;269(2):180–192. doi:10.1006/excr.2001.5331
22. Kere J, Srivastava A, Montonen O, et al. X-linked anhidrotic (hypohidrotic) ectodermal dysplasia is caused by mutation in a novel transmembrane protein. *Nature Genet.* 1996;13(4):409–416. doi:10.1038/ng0895-409
23. Schneider P, Street S, Gaide O, et al. Mutations leading to X-linked hypohidrotic ectodermal dysplasia affect three major functional domains in the tumor necrosis factor family member ectodysplasin-A. *J Biol Chem.* 2001;276(22):18819–18827. doi:10.1074/jbc.M101280200
24. Gunadi MK, Ohta M, Sugano A, et al. Two novel mutations in the ED1 gene in Japanese families with X-linked hypohidrotic ectodermal dysplasia. *Pediatr Res.* 2009;65(4):453–457. doi:10.1203/PDR.0b013e3181991229
25. Rahbaran M, Hassani Doabsari M, Salavitarab S, Mokhberian N, Morovvati Z, Morovvati S. EDAA novel frameshift mutation in the gene in an Iranian patient affected by X-linked hypohidrotic ectodermal dysplasia. *Cell Mol Biol Lett.* 2019;24:54. doi:10.1186/s11658-019-0174-9
26. Zhang J, Han D, Song S, et al. Correlation between the phenotypes and genotypes of X-linked hypohidrotic ectodermal dysplasia and non-syndromic hypodontia caused by ectodysplasin-A mutations. *Eur J Med Genet.* 2011;54(4):e377–82. doi:10.1016/j.ejmg.2011.03.005
27. Trzeciak W, Koczorowski R. Molecular basis of hypohidrotic ectodermal dysplasia: an update. *J Appl Genet.* 2016;57(1):51–61. doi:10.1007/s13353-015-0307-4
28. Wohlfart S, Söder S, Smahi A, Schneider H. A novel missense mutation in the gene EDARADD associated with an unusual phenotype of hypohidrotic ectodermal dysplasia. *Am J Med Genet A.* 2016;(1):249–253. doi:10.1002/ajmg.a.37412
29. Elomaa O, Pulkkinen K, Hannelius U, Mikkola M, Saarialho-Kere U, Kere J. Ectodysplasin is released by proteolytic shedding and binds to the EDAR protein. *Human Mol Genet.* 2001;10(9):953–962. doi:10.1093/hmg/10.9.953
30. D'Assante R, Fusco A, Palamaro L, et al. Unraveling the link between ectodermal disorders and primary Immunodeficiencies. *Inter rev Immunol.* 2016;35(1):25–38. doi:10.3109/08830185.2015.1010724
31. Priolo M, Laganà C. Ectodermal dysplasias: a new clinical-genetic classification. *J Med Genet.* 2001;38(9):579–585. doi:10.1136/jmg.38.9.579

32. Anboubia G, Carmany E, Natoli J. The characterization of hypodontia, hypohidrosis, and hypotrichosis associated with X-linked hypohidrotic ectodermal dysplasia: a systematic review. *Am J Med Genet A*. 2020;182(4):831–841. doi:10.1002/ajmg.a.61493
33. Sun J, Chen L, Han S, et al. Characterization of a novel gross deletion and insertion mutation in EDA gene causing hypohidrotic ectodermal dysplasia. *J Dermatol*. 2021;48(1):e29–e30. doi:10.1111/1346-8138.15653
34. Silverberg N. Emerging therapies in genodermatoses. *Clin Dermatol*. 2020;38(4):462–466. doi:10.1016/j.clindermatol.2020.03.006
35. Mikkola M. Molecular aspects of hypohidrotic ectodermal dysplasia. *Am J Med Genet A*. 2009;(9):2031–2036. doi:10.1002/ajmg.a.32855
36. Rigolet M, Grégoire A, Lefort G, et al. Early prenatal diagnosis of ICF syndrome by mutation detection. *Prenatal Diagnosis*. 2007;27(11):1075–1078. doi:10.1002/pd.1826
37. Fusco F, Pescatore A, Conte M, et al. EDA-ID and IP, two faces of the same coin: how the same IKBKG/NEMO mutation affecting the NF-κB pathway can cause immunodeficiency and/or inflammation. *Inter rev Immun*. 2015;34(6):445–459. doi:10.3109/08830185.2015.1055331
38. Motil K, Fete T, Fraley J, et al. Growth characteristics of children with ectodermal dysplasia syndromes. *Pediatrics*. 2005;116(2):e229–34. doi:10.1542/peds.2004-2830
39. Jones K, Goodwin A, Landan M, et al. Characterization of X-linked hypohidrotic ectodermal dysplasia (XL-HED) hair and sweat gland phenotypes using phototrichogram analysis and live confocal imaging. *Am J Med Genet A*. 2013;(7):1585–1593. doi:10.1002/ajmg.a.35959

Clinical, Cosmetic and Investigational Dermatology

Dovepress

Publish your work in this journal

Clinical, Cosmetic and Investigational Dermatology is an international, peer-reviewed, open access, online journal that focuses on the latest clinical and experimental research in all aspects of skin disease and cosmetic interventions. This journal is indexed on CAS. The manuscript management system is completely online and includes a very quick and fair peer-review system, which is all easy to use. Visit <http://www.dovepress.com/testimonials.php> to read real quotes from published authors.

Submit your manuscript here: <https://www.dovepress.com/clinical-cosmetic-and-investigational-dermatology-journal>