

Endoscopy-Intravascular Treatment Combination for Duodenal Ulcer Hemorrhages Caused by Small Hepatic Pseudoaneurysms: A Case Report

Peiguang Xiao¹, Maodong Guo¹, Lujian Zhu^{1,2}

¹Department of Gastroenterology, Affiliated Jinhua Hospital, Zhejiang University School of Medicine, Jinhua, People's Republic of China; ²Department of Infectious Diseases, Affiliated Jinhua Hospital, Zhejiang University School of Medicine, Jinhua, People's Republic of China

Correspondence: Lujian Zhu, Department of Infectious Diseases, Affiliated Jinhua Hospital, Zhejiang University School of Medicine, Jinhua, People's Republic of China, Email zhulj_brave@163.com

Aim: Significant gastrointestinal hemorrhages, resulting from long-term compression of the duodenum by a hepatic pseudoaneurysm (HAPA), is an extremely rare condition. In fact, when the pseudoaneurysm is small in diameter, diagnosis can be particularly challenging. Timely and effective diagnosis and treatment is therefore of great significance, and in this case, endoscopy, combined with intravascular therapy, can provide an effective approach, especially since it removes the need for surgery while yielding favorable outcomes.

Case Summary: A 75-year-old old man presented to the hospital's emergency department with hematemesis and black stool. Despite conservative treatments such as "acid suppression, fluid resupply, hemostasis and blood transfusion", no significant improvement was noted. Emergency gastroscopy subsequently revealed an ulcer in the duodenal bulb (Figure 1), with an exposed thrombotic head and active bleeding on the surface. In addition, abdominal computed tomography (Figure 2) showed no obvious HAPA manifestations. After unsuccessful endoscopic hemostasis, angiography was performed (Figure 3) and a pseudotumor-like dilatation measuring 5.56 mm in diameter was found at the distal end of the proximal branch vessel of the common hepatic artery. Following spring coil embolization (Figure 4), the patient's condition improved and he was discharged from the hospital, with a follow-up after six months showing no signs of recurrence or complications.

Conclusion: Duodenal ulcer hemorrhages due to small hepatic pseudoaneurysms are very rare, with endoscopic intervention being effective for such cases.

Keywords: hepatic artery pseudoaneurysm, endovascular treatment, gastroscopy, duodenal ulcer, bleeding, case report

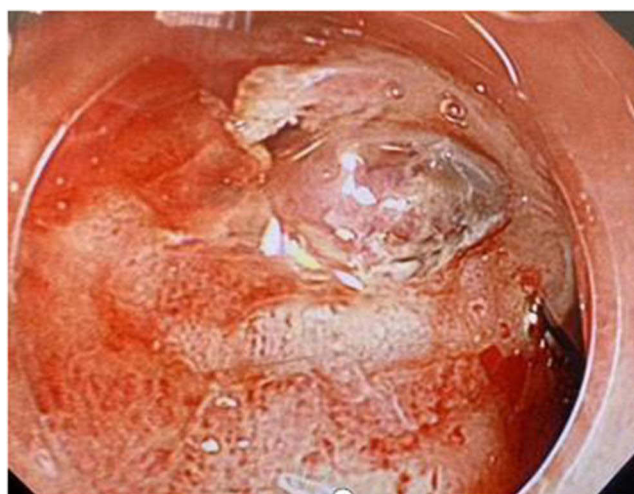

Figure 1 Picture of the duodenal bulb showing an ulcer with a central naked thrombus head and active bleeding on the surface.

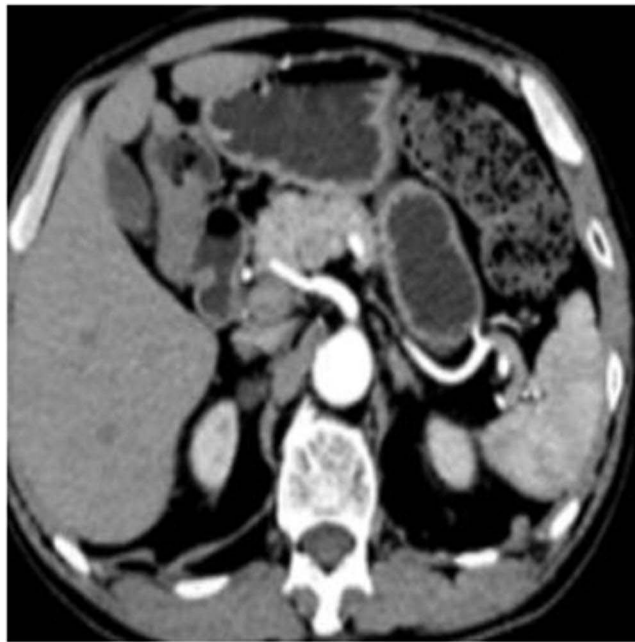

Figure 2 Initial computed tomography image showing no abnormalities in the abdomen.

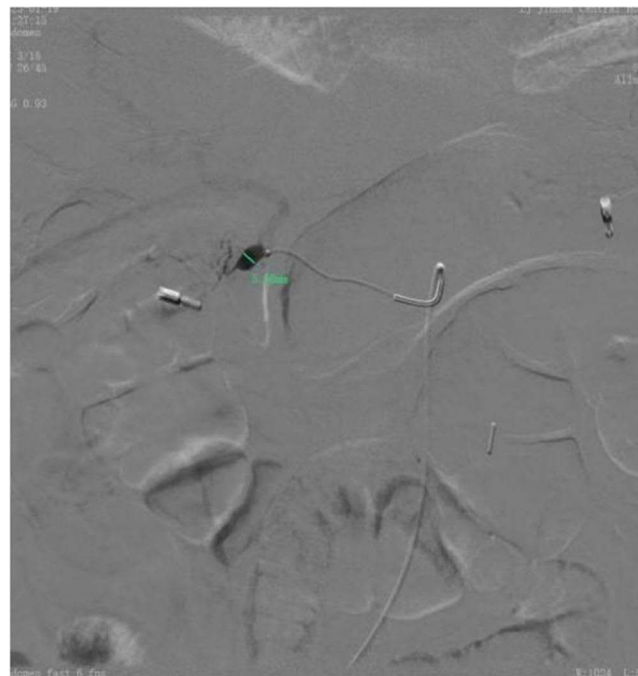

Figure 3 Angiography showing the presence of a distal tumor dilatation at the proximal branch of the common hepatic artery.

Introduction

Hepatic aneurysms are mainly caused by trauma, inflammatory injuries or degenerative changes and structural abnormalities in the hepatic artery wall. Various factors, including an abnormal accumulation of the extracellular matrix, inflammatory responses, damage to vascular endothelial cells as well as an abnormal expression or excessive release of vascular growth factors, can promote pathological changes in artery walls, thereby leading to the formation of liver aneurysms. In fact, among visceral aneurysms, hepatic ones are the second most common,¹ with the majority being

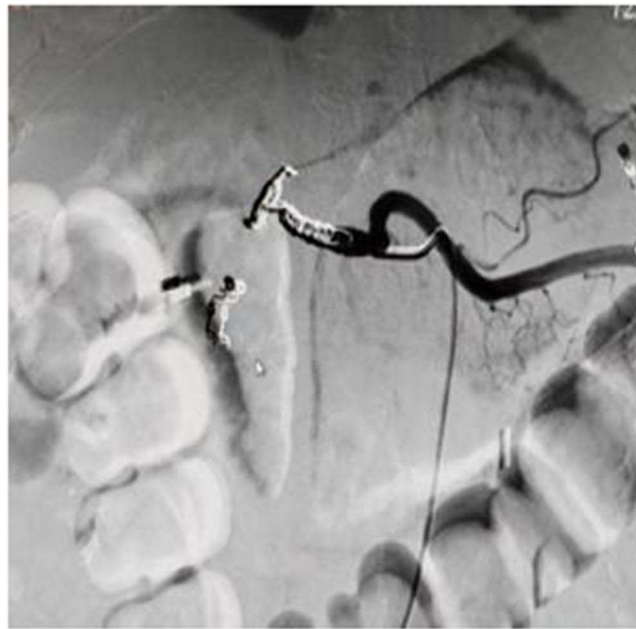


Figure 4 Image showing the embolization of the common hepatic artery.

extrahepatic and 77% occurring in the proximal part of the liver.² In these cases, the common hepatic artery is the most frequently affected, followed by the right and left hepatic arteries. The onset of hepatic aneurysms typically occurs between the ages of 50 and 60,³ and although single occurrences are most common, multiple ones may sometimes be present. Aneurysms, which are usually small in size, asymptomatic and grow slowly over time, are often incidentally discovered during routine physical examinations. However, as they get larger, they can cause gastrointestinal bleeding or abdominal hemorrhages, thus highlighting the need for timely diagnosis and treatment.

Current invasive treatments for hepatic aneurysms include surgery and endovascular therapy. Interventional approaches are less invasive and are associated with shorter recovery times than open procedures; these typically include fill-embolization techniques, isolated embolization, and stenting.⁴ The tamponade embolization technique (or direct embolization technique) is performed by filling the aneurysm sac with a coil or insertion of a liquid preparation device into the arterial sac, and a bare stent can be placed in the artery to prevent dislodging of the spring coils from the aneurysm sac; however, this can result in artifacts that make detection of potential complications (eg, arteriovenous fistulae) during subsequent imaging follow-up challenging. Isolated embolization, in which a device, such as a spring coil, is used to embolize the artery completely at the outflow break and inflow end of the aneurysm sac, is similar to surgical ligation, with the disadvantage that patency of the treated arterial segment is not guaranteed. Stent placement utilizes a cover or shunt to ensure blood perfusion to the distal hepatic branch vessels, but is usually limited by the location and anatomy of the aneurysm and is not indicated for HAPA and ruptured hepatic aneurysms.

Open surgery is usually used for large or severe hepatic aneurysms.⁵ When the aneurysm is located in the hepatic artery itself, surgical ligation is possible due to the presence of collateral vessels. However, if the aneurysm is located distal to the gastroduodenal artery, alternative surgical approaches such as endoaneurysm plasty or end-to-end anastomosis are recommended to ensure hepatic perfusion. In conclusion, the choice of a specific treatment modality should be based on a comprehensive consideration of factors, such as aneurysm location, anatomy, hemodynamics, and bleeding risk.

Since massive bleeding of duodenal ulcers due to small HAPA tend to be highly uncommon, this can lead to misdiagnosis or missed diagnosis. As such, timely diagnosis and treatment are of great significance, with a combination of endoscopy and intravascular therapy proving to be effective for this purpose. In this context, the current report describes the diagnosis and treatment of a rare, small-diameter HAPA-induced hemorrhagic shock (Figure 5). It is expected that a summary of the experiences can serve as reference to guide clinicians.

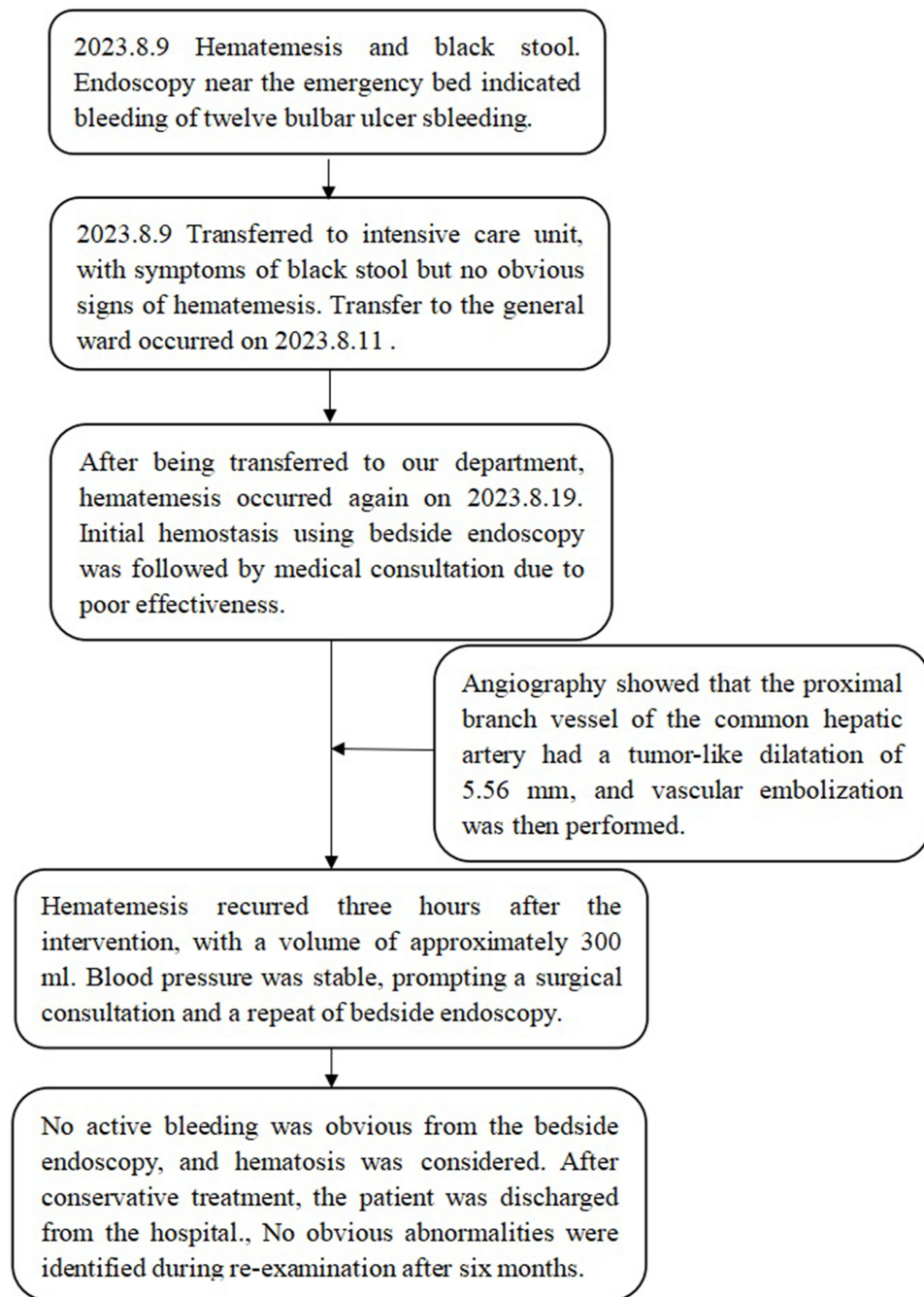


Figure 5 Disease diagnosis and treatment procedure.

Case Presentation

A 75-year-old man was admitted to the emergency room with a complaint of “hematemesis and black stool for the past three hours”. Three hours prior to admission, the patient experienced hematemesis once without an apparent trigger, and this involved a blood loss of around 500–700 mL. In addition, he passed a significant amount of tarry stool which was accompanied by abdominal distension, dizziness, weakness, pallor, sweating, cold limbs, chest tightness and other manifestations indicative of acute hypovolemic shock. In the past, the patient underwent a “right lower limb foreign body drainage operation”. In 2022 to 12, he also underwent a “left hemicolectomy and intestinal adhesion lysis” due to “reducing colon cancer”. The patient had been smoking for 20 years before quitting 30 years ago. He also had a 50-year

history of alcohol consumption which involved one glass of white wine twice a day. There were no significant family medical history details. The abdomen was flat and soft, with no obvious signs of tenderness or rebound pain. There was also no palpable pulsating mass. His blood pressure was 45/25 mmHg, while the pulse rate, temperature and respiratory rate were 110 beats/min, 36.7 °C and 18 breaths/min, respectively. The hemoglobin level was found to be 47 g/L, while fecal occult blood was detected at 3+. Other test results did not indicate significant abnormalities. Gastroscopy revealed an ulcer in the duodenal bulb with an exposed, central thrombotic head and active bleeding on the surface. Abdominal computed tomography showed no significant abnormalities. After giving the patient conservative treatments including “fasting, fluid supplementation, acid inhibition, hemostasis and blood transfusion” in the emergency rescue center of the hospital, no significant improvement was observed, and hence, bedside gastroscopy was performed. The examination revealed an ulcer with an exposed central thrombotic head and active surface bleeding in the duodenal bulb. Multiple injections of epinephrine-saline were then administered to the surrounding mucosa, and after performing electrocoagulation with hemostatic forceps, titanium clips were used to seal the bleeding spot. A subsequent abdominal computed tomography scan showed no signs of a liver aneurysm. The patient was transferred to the intensive care unit for further treatment during which there were no further occurrences of hematemesis or black stool. A follow-up examination further showed that the blood hemoglobin was 66 g/L, and that the vital signs remained stable for three days. The patient was therefore transferred to the general ward to continue drug treatment.

One week after treatment in the general ward, the patient experienced sudden hematemesis in the early morning, with approximately 500 mL of bright red blood lost. His hemoglobin level was 76 g/L, while the blood pressure was 105/75 mmHg. Recognizing the presence of active bleeding, gastroscopy was again performed, with the examination revealing the bleeding to be in the duodenal bulb. The suspected bleeding points were therefore treated by electrocoagulation. Due to the sub-optimal outcome of endoscopic hemostasis, an interventional consultation was also requested. An emergency angiography was performed, and the subsequent identification of a 5.56-mm tumor dilatation in the distal branch of the common hepatic artery prompted distal vascular embolization of the common hepatic artery.

Three hours after the above intervention, the patient again experienced hematemesis, with a loss of around 300 mL of dark red blood. At this point, his blood pressure and hemoglobin level were 95/65 mmHg and 68 g/L, respectively. Gastroscopy was performed for the third time, and a surgical consultation was concurrently requested to consider performing laparotomy if required. The examination showed the presence of dark red blood clot, but no apparent bleeding was observed after saline irrigation. The patient remained under observation for one week, during which there were no further occurrences of bleeding. Another review of the hemoglobin level showed that it had increased to 80 g/L, and hence, the patient was discharged after his improved condition. The final diagnosis was a rupture of the pseudoaneurysm rupture and subsequent hemorrhage at the proximal end of the common hepatic artery. After a six-months follow-up period, there were no signs of complications. Reexamination by gastroscopy (Figure 6) revealed scarring changes in the duodenal bulbar ulcer, while an abdominal computed tomography scan (Figure 7) showed postoperative changes in the proximal branch aneurysms of the common hepatic artery.

Discussion

The incidence of visceral aneurysms is relatively low at only about 0.2%.⁶ Hepatic aneurysms can be categorized as true aneurysms, false aneurysms or dissected ones based on their characteristics. A true aneurysm is generally defined as a permanent local dilation of all three layers of the artery wall by at least 1.5 times the normal diameter. Conversely, pseudoaneurysms represent localized damage to only the inner two layers of the artery wall as a result of various injuries or trauma. In addition, their incidence varies between 0.3% and 3% after liver transplantation, while the mortality rate can be as high as 80%.⁷ Unlike true aneurysms, false aneurysms do not involve a true blood vessel wall, but instead are composed of outer wall tissues (such as blood clots, inflammatory tissue, etc). Finally, a dissecting aneurysm involves a slit in the inner and outer layers of the artery wall, thereby allowing blood to penetrate and form a hematoma. It is generally less common in an artery outside the aorta.⁸ Due to an increasing number of surgical procedures involving the liver and biliary tract,^{9,10} cases of liver aneurysms have been gradually on the rise.

The mortality rate following a ruptured visceral aneurysm exceeds 10%,¹¹ with patients presenting HAPA being at a higher risk of a rupture. On the other hand, small HAPAs can remain asymptomatic for a long time, but those with

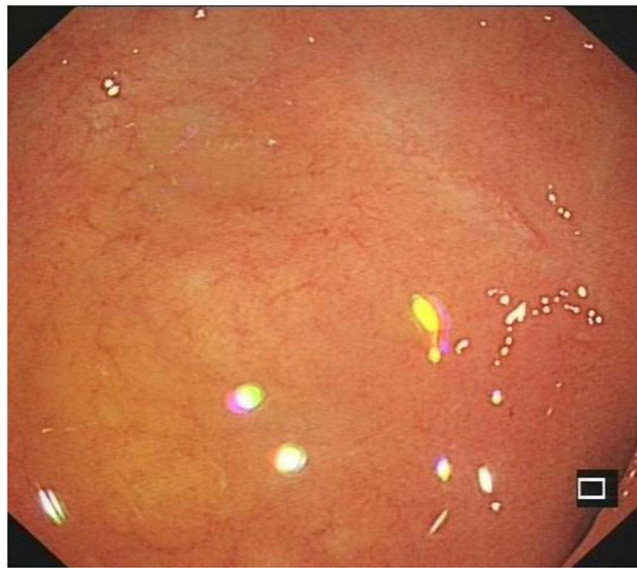


Figure 6 A follow-up gastroscopic examination after six months showed scarring changes in the duodenal bulbar ulcer.

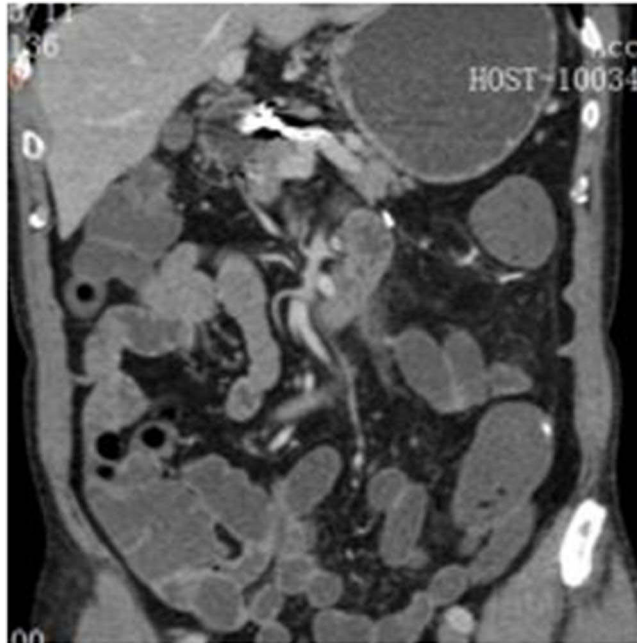


Figure 7 Reexamination based on an abdominal computed tomography scan showed postoperative changes in the proximal branch aneurysms of the common hepatic artery.

a diameter exceeding 2 cm have a rupture rate of 44% and are, thus, at a higher risk of bleeding.¹² The presentation of Quinke's triad, consisting of abdominal pain, jaundice and gastrointestinal bleeding, is typical after a rupture. Hemorrhages from duodenal ulcers due to HAPA compression is relatively rare,¹³ especially in the case of small-diameter HAPAs. Nevertheless, prolonged pressure may progress to fistula formation.¹⁴

A delayed onset increases the risk of bleeding and death,¹⁵ Currently, the main diagnostic methods for HAPA include ultrasound, computed tomography CT and angiography, with each method being relatively simple to use and having its own advantages. For instance, ultrasonography helps to visualize pulsation or turbulence, but it can be less sensitive to small aneurysms due to factors such as gas or obesity.⁸ Similarly, a CT scan is a non-invasive method that can provide comprehensive

images of liver aneurysms, but it may be less accurate than angiography for small-diameter arterial branches. In fact, angiography serves as the gold standard for the diagnosis of hepatic aneurysms. However, it represents an invasive approach that involves injecting a contrast agent into the artery to observe the morphology and function of the blood vessels, the size, shape and position of the aneurysm or even to determine the condition of the hepatic aneurysm.

In accordance with guidelines,¹² it is recommended to repair symptomatic hepatic aneurysms having a tumor size exceeding 2 cm as well as an annual tumor size greater than 0.5 cm. For other patients with hepatic aneurysms, complicated by vasculitis or positive blood cultures, repair should be undertaken irrespective of the tumor size. Open surgery is suitable for patients having hepatic aneurysms with severe complications and a tumor diameter exceeding 5.0 cm. Intervention should be considered as early as possible for symptomatic patients or those with risk factors such as multiple hepatic aneurysms and aneurysms of non-atherosclerotic origins.⁶

If anatomically feasible, endovascular treatment tends to be the preferred option for all hepatic aneurysms, and it includes endovascular techniques such as percutaneous embolization or stent graft placement. These approaches involve the introduction of drugs or embolizing agents into the supplying artery of the hepatic aneurysm via a catheter to block the blood supply and inducing tumor shrinkage or necrosis. For aneurysms located within the liver, embolization with spring coils is recommended, while for cases of aneurysms located outside the liver, open surgery or interventional techniques may be required for repair. Such surgical treatment may include excision, anastomosis, ligation, aneurysmal plasty and bypass. However, if the aneurysm is significantly large in size, the affected liver lobe or tumor also needs to be removed. At the same time, any blood supply destroyed by the tumor needs to be reconstructed to avoid severe liver ischemia. Compared with traditional open surgery, endovascular therapy showed no significant differences in mortality, although it may lead to shorter hospital stays as well as lower complication rates.¹⁶ Therefore, surgical treatment may be a viable, effective and safe alternative to endovascular treatment for splanchnic aneurysms.¹¹

Although gastrointestinal bleeding due to HAPA has been previously reported,^{13,14} the reports mostly involved those that were large in diameter (greater than 2 cm) and therefore, easily detected. In contrast, massive bleeding of duodenal ulcers caused by minor HAPA remains rare and is more challenging to detect based on conventional imaging. In this case, endovascular angiography provides a better diagnosis and treatment approach. In addition, endoscopic treatment can be used as an emergency measure for patients experiencing significant bleeding in the digestive tract. In the current report, the patient showed no significant medical history, with whole-abdominal enhanced CT scans revealing no obvious abnormalities. Initially, the bleeding, attributed to the bulboduodenal ulcer, was significant in volume, and occurred alongside hypovolemic shock and other critical manifestations. At the same time, repeated endoscopic attempts at hemostasis yielded poor outcomes. This prompted consideration of potential extravascular lesions. Emergency angiography proved to be effective in the diagnosis and treatment of such conditions, especially in achieving immediate hemostasis. Furthermore, in the long-term, follow-up examinations showed that patients with such conditions had a good prognosis.

Conclusion

When conventional gastroscopy was ineffective in achieving hemostasis of the duodenal ulcer hemorrhage, the possibility of vascular lesions cannot be disregarded even in cases where abdominal imaging results are negative. Angiography is a valuable diagnostic and treatment tool, especially for the detection of small vascular diseases that can be easily missed during routine examinations. Combining endoscopic treatment causes less trauma and leads to better outcomes than surgical methods. In addition, as noted in the current report, delayed bleeding occurred again one week after routine endoscopic hemostasis, hence suggesting that bleeding related to such conditions might require a more extended period of observation. In Conclusion, in the event of life-threatening gastrointestinal bleeding with negative imaging, endoscopic emergency hemostasis provides an adjunctive time window for further diagnosis and treatment using endovascular therapy, which is both minimally invasive and effective, providing timely and effective diagnostic and therapeutic measures for unexplained gastrointestinal bleeding in the clinical setting. It is expected that the above diagnosis and treatment process can provide a reference to guide the management of acute gastrointestinal bleeding with unknown clinical causes.

Ethical Approval and Informed Consent

All procedures were approved by the Medical Ethics Committee of Jinhua Hospital Affiliated to Zhejiang University School of Medicine (protocol number: (2024) Lun Audit No. (60)). It has been confirmed that the patient has provided written informed consent for the publication of the case report and images.

Author Contributions

All authors made a significant contribution to the work reported, whether that is in the conception, study design, execution and interpretation, or in all these areas; took part in drafting, revising or critically reviewing the article; gave final approval of the version to be published; have agreed on the journal to which the article has been submitted; and agree to be accountable for all aspects of the work.

Funding

This case was supported by Jinhua Municipal Science and Technology Bureau Key Project (No. 2023-3-091) and Jinhua Municipal Central Hospital Science and Technology Project (No. JY2022-1-04, JY2023-1-04).

Disclosure

The authors have no conflicts of interest to declare for this work.

References

1. Pulli R, Dorigo W, Troisi N, Pratesi G, Innocenti AA, Pratesi C. Surgical treatment of visceral artery aneurysms: a 25-year experience. *J Vascular Surg.* 2008;48(2):334–342. doi:10.1016/j.jvs.2008.03.043
2. Berceci SA. Hepatic and splenic artery aneurysms. *Semin Vascul Surg.* 2005;18(4):196–201. doi:10.1053/j.semvascsurg.2005.09.005
3. Huang YK, Hsieh HC, Tsai FC, Chang SH, Lu MS, Ko PJ. Visceral artery aneurysm: risk factor analysis and therapeutic opinion. *Europ J Vascul Endovasc Surg.* 2007;33(3):293–301. doi:10.1016/j.ejvs.2006.09.016
4. Melissano G, Mascia D, Atique Gabriel S, et al. Hepatic artery aneurysms: open and endovascular repair. *J Cardiovascul Surg.* 2018;59(1):95–100. doi:10.23736/S0021-9509.16.09220-X
5. Erben Y, De Martino RR, Bjarnason H, et al. Operative management of hepatic artery aneurysms. *J Vascular Surg.* 2015;62(3):610–615. doi:10.1016/j.jvs.2015.03.077
6. Abbas MA, Fowl RJ, Stone WM, et al. Hepatic artery aneurysm: factors that predict complications. *J Vascular Surg.* 2003;38(1):41–45. doi:10.1016/S0741-5214(03)00090-9
7. Piardi T, Lhuair M, Bruno O, et al. Vascular complications following liver transplantation: a literature review of advances in 2015. *World J Hepatol.* 2016;8(1):36–57. doi:10.4254/wjh.v8.i1.36
8. Pasha SF, Gloviczki P, Stanson AW, Kamath PS. Splanchnic artery aneurysms. *Mayo Clin Proc.* 2007;82(4):472–479. doi:10.4065/82.4.472
9. Lerut AV, Pirenne J, Sainz-Barriga M, Blondeel J, Maleux G, Monbaliu D. Case report: immediate revascularization for symptomatic hepatic artery pseudoaneurysm after orthotopic liver transplantation? A case series and literature review. *Front Surg.* 2023;10:1169556. doi:10.3389/fsurg.2023.1169556
10. Frenzel F, Fries P, Buecker A, Massmann A. Iatrogenic arterio-biliary fistula and peripheral hepatic artery pseudoaneurysm after transjugular liver biopsy: complication management using a microvascular plug. *Diagn Interventional Radiol.* 2022;28(4):383–386. doi:10.5152/dir.2022.20994
11. Lin YC, Liao TC, Lin CT, et al. Salvage surgeries for splanchnic artery aneurysms after failed endovascular therapy: case series. *Internat J Surg.* 2023;109(7):1842–1851. doi:10.1097/JS9.0000000000000442
12. Chaer RA, Abularrage CJ, Coleman DM, et al. The society for vascular surgery clinical practice guidelines on the management of visceral aneurysms. *J Vascular Surg.* 2020;72(1s):3s–39s. doi:10.1016/j.jvs.2020.01.039
13. Kim YJ, Satapathy SK, Law L, et al. Hematemesis from ruptured aberrant right hepatic artery aneurysm eroding through the duodenal wall. *Endoscopy.* 2011;43:E323–324. doi:10.1055/s-0030-1256736
14. Zhang H, Wang Z, Cao D. False aneurysm of the common hepatic artery ruptured into the duodenum. *Am J Gastroenterol.* 2016;111(7):922. doi:10.1038/ajg.2016.265
15. Doğan R, Yildirim E, Göktürk S. Gastrointestinal hemorrhage caused by rupture of a pseudoaneurysm of the hepatic artery. *Turkish J Gastroenterol.* 2012;23(2):160–164. doi:10.4318/tjg.2012.0460
16. Barrionuevo P, Malas MB, Nejim B, et al. A systematic review and meta-analysis of the management of visceral artery aneurysms. *J Vascular Surg.* 2019;70(5):1694–1699. doi:10.1016/j.jvs.2019.02.024

Journal of Inflammation Research

Dovepress

Publish your work in this journal

The Journal of Inflammation Research is an international, peer-reviewed open-access journal that welcomes laboratory and clinical findings on the molecular basis, cell biology and pharmacology of inflammation including original research, reviews, symposium reports, hypothesis formation and commentaries on: acute/chronic inflammation; mediators of inflammation; cellular processes; molecular mechanisms; pharmacology and novel anti-inflammatory drugs; clinical conditions involving inflammation. The manuscript management system is completely online and includes a very quick and fair peer-review system. Visit <http://www.dovepress.com/testimonials.php> to read real quotes from published authors.

Submit your manuscript here: <https://www.dovepress.com/journal-of-inflammation-research-journal>