

Objective Evaluation of Stellate Ganglion Block Effects Using Ultrasound Wave Intensity Technology: A Study on Hemodynamics

Yayun Gan¹, Jian Chen¹, Lini Xian², Yuan Shi²

¹Department of Ultrasound, The First Hospital of Kunming City, The Affiliated Hospital of Kunming Medical University, Kunming, Yunnan Province, 650011, People's Republic of China; ²Department of Ultrasound, Yanan Hospital of Kunming City, The Affiliated Hospital of Kunming Medical University, Kunming, Yunnan Province, 650051, People's Republic of China

Correspondence: Jian Chen, The First Hospital of Kunming City, The Affiliated Hospital of Kunming Medical University, Kunming, Yunnan Province, 650011, People's Republic of China, Email chenjian6@kmmu.edu.cn

Purpose: Emerging evidence suggests that although Horner's syndrome manifests observable facial changes, it may not comprehensively evaluate the hemodynamic alterations associated with stellate ganglion block (SGB). This study endeavors to systematically evaluate the influence of SGB on the elasticity and flow velocity of the common carotid artery (CCA) and brachial artery utilizing ultrasound wave intensity analysis (usWIA). Particularly, it focuses on patients necessitating monitoring for its effects on specific organs or regions.

Methods: Totally, we selected 33 patients, where only 31 patients (comprising 15 males and 16 females) were included between September 2020 to January 2022 after screening patients who require SGB treatment for painful disorders. The side on which the SGB was administered depended on the patient's painful side, 13 cases underwent left stellate ganglion block (LSGB), and 18 cases underwent right stellate ganglion block (RSGB). Wave intensity (WI) data were collected by usWIA on the CCA and brachial artery before the administration of SGB and after the manifestation of Horner's syndrome. We then compared the changes in these data pre- and post-SGB using SPSS 26.0.

Results: The results showed an increase in arterial compliance (AC) of the CCA and brachial artery on the blocked side after SGB ($P < 0.05$). In contrast, pressure-strain elastic modulus (EP) and arterial stiffness pulse wave velocity (PWV β) decreased (for all $P < 0.05$). Furthermore, the minimum velocity (Vmin) of the CCA exhibited a significant increase ($P < 0.01$), while wave intensity pulse wave velocity (PWVwi) was significantly reduced ($P < 0.01$). In contrast, on the contralateral side of the CCA, EP and PWV β increased after SGB (for all $P < 0.05$), while AC decreased ($P < 0.05$).

Conclusion: SGB has been observed to enhance the elasticity and blood flow velocity of arteries within its innervated areas. In clinical practice, usWIA can serve as an objective measurement tool for assessing the impact of SGB on arterial elasticity and flow velocity in specific organs or regions. Furthermore, unilateral SGB has been noted to diminish the arterial elasticity of the CCA on the contralateral side.

The plain language summary: Question: How to accurately and objectively evaluate the hemodynamic changes of SGB on targeted organs or regions?

Findings: SGB increased the elasticity and blood flow velocity of the arteries on the blocked side by usWIA.

Meaning: The usWIA could serve as an objective measurement tool for assessing the effects of SGB on arterial elasticity and blood flow velocity, especially for patients needing evaluation of its impact on the upper limbs.

Keywords: ultrasound wave intensity analysis, stellate ganglion block, hemodynamics, arterial elasticity

Introduction

Stellate ganglion block (SGB) is a medical procedure that blocks abnormal sympathetic nervous system (SNS) excitation, thereby restoring stability to the SNS.¹ According to the latest research, SGB is being increasingly utilized in clinical

practice for its effectiveness in treating both painful and non-painful disorders² within the sympathetic innervation area of the stellate ganglion (SG), encompassing the head and upper extremities. Previously, successful SGB was confirmed by observing the occurrence of facial Horner's syndrome on the blocked side. Symptoms of Horner's syndrome include facial flushing, drooping eyelids, conjunctival congestion, and pupillary constriction.³ As research in this field progresses, some researchers have observed that the occurrence of Horner's syndrome is not 100% in patients undergoing the block procedure.⁴ Furthermore, the absence of quantitative indicators for objectively assessing hemodynamic changes in SGB, especially for patients needing to monitor its impact on specific organs or regions. Therefore, this has led to the development of new methods for objectively evaluating the effects of SGB beyond traditional indicators. Previous studies have put forward methods to assess the effect of SGB by observing the extension of pulse transit time (PuTT)⁵ or changes in pupil size.⁴ However, these methods have been found to have some limitations that may prevent convenient and accurate observation of the effect of SGB on specific targeted organs or regions.

The concept of wave intensity (WI) was initially introduced in 1990,⁶ and the wave intensity analysis (WIA) examines hemodynamic information pertaining to blood flow velocity, blood vessel elasticity, and some heart function at a specific point.⁷ Ultrasound wave intensity analysis (usWIA) is non-invasive and convenient, as it only necessitates the detection of peripheral vessels to acquire valuable hemodynamic data. In the early stages of research, it was noted that SGB has a vasodilatory effect, and Gopal et al⁸ proposed that left stellate ganglion block (LSGB) could serve as an alternative to vasodilators. The majority of studies have primarily focused on examining alterations in vessel diameter and blood flow velocity by SGB. To our knowledge, there are few studies that have focused on the effect of SGB on arterial elasticity. Our study conducted using usWIA demonstrated for the first time that SGB enhances the elasticity of the common carotid artery (CCA) and brachial arteries on the blocked side. This finding contributes to our understanding of hemodynamic alterations and clinical practices related to SGB.

Material and Methods

Patient Selection

Thirty-one patients (15 males and 16 females) with an average age of 55.68 ± 14.23 years were included between September 2020 to January 2022 at Yanan Hospital of Kunming City after screening patients who require SGB treatment for herpes zoster neuralgia of the head and neck, cervical spondylosis, headache, facial neuritis, Raynaud's syndrome, complex pain syndrome, and butterfly-palate neuralgia. The side on which the SGB was administered depended on the patient's painful side; 13 patients received LSGB, and 18 received right stellate ganglion block (RSGB). Exclusion criteria were those with various organic heart diseases (LVEF < 50%), arrhythmias preventing the acquisition of normal waveforms for five consecutive cardiac cycles, and severe arterial diseases such as arteritis and aneurysms.

Ethical approval for this study was provided by the Ethical Committee of Yanan Hospital of Kunming City. Patients signed informed consent forms before participating. Meanwhile, this study has complied with the Declaration of Helsinki and followed the STROBE Statement.

Ultrasound-Guided Stellate Ganglion Block

Ultrasound-guided stellate ganglion block (usSGB) was performed using a Samsung WS80A ultrasonic diagnostic instrument with a 5–13 MHz linear array probe (Samsung, Seoul, South Korea) for guidance. The patient was positioned with a pillow behind their shoulder and the head turned to the contralateral side to expose the neck as much as possible. After disinfecting the area and placing a towel, Chassaignac's node of C6 was identified using ultrasound as the localization point. The needle was inserted under ultrasound guidance to avoid important structures such as the trachea, esophagus, peripheral nerves, and blood vessels. The needle tip was placed on the deep surface of the CCA and the fascial surface of the longus colli muscle (L.col). Next, 6 mL of 1% lidocaine (Shanghai Hefeng Pharmaceutical Co., Ltd, Shanghai, China) was slowly injected to infiltrate the stellate ganglion, after which the needle was removed, its surface disinfected again, and the patient was advised to rest for 30 minutes. The success of SGB is confirmed by observing the occurrence of Horner's syndrome (facial flushing, drooping eyelids, conjunctival congestion, or pupillary constriction) on the affected side. The SGB was performed by same two

experienced doctors. These two doctors and the data collector compared changes between the patient's blocked and contralateral facial sides to confirm the presence of Horner's syndrome.

Wave Intensity (WI) Data Collection

A Prosound $\alpha 10$ ultrasonic diagnostic instrument with a 5–13 MHz linear array probe (Aloka Co., Ltd, Tokyo, Japan) was used to collect WI data. All data were collected with the patient in the supine position. Firstly, HR and brachial BP were measured and recorded twice from the right brachial artery. Secondly, the measurement site for usWIA was 2 cm proximal to the bifurcation of the CCA and 2–4 cm proximal to the medial epicondyle of the humerus, avoiding plaques. The thoracic lead electrocardiogram (ECG) was connected, and the linear array probe was placed on the measurement site in B-mode after modifying the structure of the measurement site for clarity. The WI function was then started, and the tracking volume gate was adjusted to the center of the artery and maintained perpendicular to the vessel wall. The M-speed was set to 200 mm/s, and the blood flow angle was maintained below 60° . Patients were instructed to hold their breath to stabilize the image. We collected more than seven cardiac cycle images to ensure they met the analysis requirements (Figure 1A). Thirdly, we advanced to the analysis phase by manually inputting the brachial blood pressure measurements, recorded twice, into the system for subsequent calculation and analysis of the WI data. The collected WI data included negative area (NA), arterial compliance (AC), arterial stiffness pulse wave velocity (PWV β), wave intensity pulse wave velocity (PWVwi), arterial stiffness (β), pressure-strain elastic modulus (Ep), and blood velocity of flow (Vmax, Vmin) (Figure 1B). Subsequent to these steps, the WI data were collected on both sides of the CCA and brachial artery. The data were obtained before implementing SGB and after the development of Horner's syndrome. Throughout the procedure, our study data were collected by the same researcher using the same methodology.

Statistic Analysis

SPSS 26.0 (IBM Corp, NY, USA) was used for this statistical analysis. The Shapiro–Wilk test was utilized to evaluate the adherence of continuous variables to a normal distribution. Categorical variables were expressed as the number of patients (proportion), while continuous variables were expressed as mean \pm SD for normally distributed data or median (IQR, P25, P75) for non-normally distributed data. The paired *t*-test for normally distributed data and the Wilcoxon rank sum test for non-normally distributed data to calculate differences in the WI data before and after SGB. A *P*-value <0.05 was defined as statistically significant, and *P* < 0.01 was defined as very statistically significant.

Results

A total of 33 patients who underwent unilateral SGB treatment were initially collected for the study. However, one patient was excluded due to old myocardial infarction (LVEF $<50\%$), another patient was excluded due to a high number

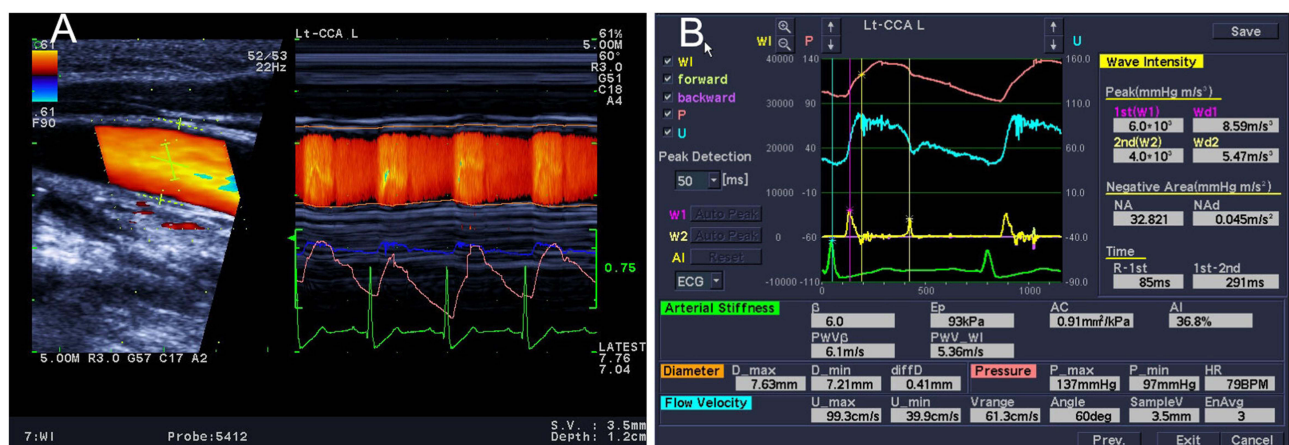


Figure 1 Wave intensity (WI) data collection. (A) Illustrates the WI data collection process, (B) presents the WI data analysis results.

of carotid plaques, which prevented the acquisition of ultrasound images consistent with image analysis. As a result, only 31 patients were included in this study. The final statistics included 31 cases with an average age of 55.68 ± 14.23 years, including 15 males (48.39%) and 16 females (51.61%). Thirteen cases received LSGB, and 18 cases received RSGB for various conditions, including herpes zoster neuralgia in the head and neck, cervical spondylosis, headache, facial neuritis, Raynaud's syndrome, complex pain syndrome, and pterygopalatine neuralgia (Table 1). Table 2 compares the changes in basic vital signs, including HR and BP (systolic and diastolic pressure) of the research subjects before and after SGB. Tables 3 and 4 show the results of the blocked side CCA and brachial artery before and after SGB (after observing Horner's syndrome), while Table 5 shows the results of the contralateral side CCA.

Table 1 Baseline [n=31, n (%)]

	LSGB	RSGB	Total
Female	8 (25.81%)	8 (25.81%)	16 (51.62%)
Age(y)	55.67 ± 13.67	55.69 ± 13.64	55.68 ± 14.23
Herpes zoster neuralgia	4 (12.90%)	9 (29.03%)	13 (41.93%)
Cervical spondylosis	3 (9.68%)	4 (12.90%)	7 (22.58%)
Headache	3 (9.68%)	2 (6.45%)	5 (16.13%)
Facial neuritis	2 (6.45%)	1 (3.23%)	3 (9.68%)
Raynaud's syndrome	0	1 (3.23%)	1 (3.23%)
Complex pain syndrome	0	1 (3.23%)	1 (3.23%)
Butterfly-palate neuralgia	1 (3.23%)	0	1 (3.23%)

Notes: Table 1 presents the demographic characteristics and blocking side selection of the 31 participants.

Abbreviations: LSGB, left stellate ganglion block; RSGB, right stellate ganglion block.

Table 2 The Comparison of HR and Brachial BP Pre- and Post-SGB

	Pre-SGB	Post-SGB	P
SBP (mmHg)	138.03 ± 17.68	142.74 ± 21.89	0.061
DBP (mmHg)	85.26 ± 11.04	86.29 ± 14.68	0.504
HR (times/minute)	75.13 ± 9.52	75.52 ± 10.23	0.510

Notes: $P > 0.05$: no statistically significant.

Abbreviations: SBP, systolic blood pressure (mmHg); DBP, diastolic blood pressure (mmHg); HR, heart rate (times/minute).

Table 3 The WI Data of the Blocked Side CCA Pre- and Post-SGB

	Pre-SGB	Post-SGB	P
NA (mmHg m/s ³)	69.299 (50.81, 111.39)	59.912 (38.52, 85.54)	0.15
β	9.90 ± 4.30	8.40 ± 4.00	0.10
Ep (kPa)	141 (108, 168)	127 (93, 163)	0.03 [#]
AC (mm ² /kPa)	0.52 (0.36, 0.81)	0.67 (0.47, 0.82)	0.03 [#]
PWV β (m/s)	7.60 ± 2.20	6.70 ± 1.70	0.01 [#]
PWVwi (m/s)	4.52 ± 2.23	3.48 ± 1.71	<0.01*
Vmax (cm/s)	76.40 ± 22.10	78.50 ± 21.00	0.53
Vmin(cm/s)	9.00 ± 7.50	14.70 ± 11.80	<0.01*

Notes: [#]: $P < 0.05$; *: $P < 0.01$.

Abbreviations: AC, Arterial compliance (mm²/kPa); Ep, pressure-strain elastic modulus (kPa); NA, Negative area (mmHg m/s³); PWVwi, wave intensity pulse wave velocity (m/s); PWV β , arterial stiffness pulse wave velocity (m/s); Vmax, maximum velocity (cm/s); Vmin, minimum velocity (cm/s); β , arterial stiffness.

Table 4 The WI Data of the Blocked Side Brachial Artery Pre- and Post-SGB

	Pre-SGB	Post-SGB	P
NA (mmHg m/s ³)	63.843 (41.36, 95.12)	52.252 (36.99, 96.56)	0.12
β	21.10 ± 10.60	19.30 ± 13.30	0.47
Ep (kPa)	310 (18, 41)	239 (17, 36)	0.04 [#]
AC (mm ² /kPa)	0.14 ± 0.07	0.18 ± 0.12	0.01 [#]
PWVβ (m/s)	10.70 (9.10, 12.70)	9.50 (7.20, 11.30)	0.04 [#]
PWVwi (m/s)	4.45 ± 2.08	4.24 ± 2.06	0.60

Notes: [#], $P < 0.05$.

Abbreviations: AC, Arterial compliance (mm²/kPa); Ep, pressure-strain elastic modulus (kPa); NA, Negative area (mmHg m/s³); PWVwi, wave intensity pulse wave velocity (m/s); PWVβ, arterial stiffness pulse wave velocity (m/s); Vmax, maximum velocity (cm/s); Vmin, minimum velocity (cm/s); β, arterial stiffness.

Table 5 The WI Data of the Contralateral Side CCA Pre- and Post-SGB

	Pre-SGB	Post-SGB	P
NA (mmHg m/s ³)	66.59 (49.48, 121.76)	93.09 (59.11, 196.98)	0.46
β	9.60 ± 9.20	10.00 ± 6.10	0.36
Ep (kPa)	101 (76, 153)	158 (102, 208)	0.02 [#]
AC (mm ² /kPa)	0.75 (0.51, 1.05)	0.64 (0.39, 0.88)	0.01 [#]
PWVβ (m/s)	6.90 ± 2.50	7.90 ± 2.30	0.01 [#]
PWVwi (m/s)	4.00 ± 2.18	4.09 ± 2.09	0.80
Vmax (cm/s)	75.10 ± 20.40	74.70 ± 20.60	0.90
Vmin(cm/s)	9.00 ± 6.10	10.30 ± 7.50	0.18

Notes: [#], $P < 0.05$.

Abbreviations: AC, Arterial compliance (mm²/kPa); Ep, pressure-strain elastic modulus (kPa); NA, Negative area (mmHg m/s³); PWVwi, wave intensity pulse wave velocity (m/s); PWVβ, arterial stiffness pulse wave velocity (m/s); Vmax, maximum velocity (cm/s); Vmin, minimum velocity (cm/s); β, arterial stiffness.

Traditional methods were employed to confirm the success of SGB through observation of Horner's syndrome on the affected side. Firstly, we compared the changes in HR, SBP and DBP before and after SGB, none of these changes were statistically significant (for all $P > 0.05$, Table 2). According to our study, the most notable changes observed on the blocked side CCA (Table 3) were a significant increase in Vmin ($P < 0.01$), as well as increases in AC ($P = 0.03$). There was a significant decline in PWVwi ($P < 0.01$), Ep and PWVβ also decline after SGB (for all $P < 0.05$). These same changes were observed in the blocked side brachial artery (Table 4). Specifically, there was an increase in AC ($P = 0.013$) and decreases in Ep and PWVβ (for all $P < 0.05$). The alterations identified in the WI data suggest that SGB enhances the elasticity and flow of both the CCA and brachial artery on the side where the block was administered. In contrast, the changes observed in the contralateral side CCA were opposite to those in the blocked side (Table 5). There was a statistically increase in Ep and PWVβ compared to before SGB (for all $P < 0.05$), as well as a decline in AC before and after SGB ($P = 0.011$). This implies that SGB was responsible for the reduced elasticity observed on the contralateral side of the CCA. However, there was no noteworthy variance in CCA blood flow velocity on the contralateral side.

Discussion

In clinical practice, SGB is widely used in pain management,⁹ anesthesia,¹⁰ vasospasm,¹¹ ventricular arrhythmias,¹² pulmonary arterial hypertension,¹³ and immune inflammation.¹⁴ Traditionally, the confirmation of block occurrence relied on Horner's syndrome, which only identified the presence of the block without providing further insights for clinical decision-making. While research on SGB is still in an exploratory stage, further research is needed to fully understand the duration,¹⁵ the necessity for repeated or ongoing SGB,¹⁶ and whether there are differences in the effects of

LSGB and RSGB on the heart¹⁷ and best block selection.⁹ Therefore, there is an urgent need to effectively and conveniently assess the effects of SGB. Ultrasound technology is non-invasive, easy to operate, and repeatable. By monitoring hemodynamic changes in target organs or regions, it precisely meets this requirement.

Hajime et al¹⁸ demonstrated that observing the rise in the perfusion index (PI) can determine the efficacy of SGB. Young et al⁵ suggested that PuTT could serve as an objective indicator, while Eugene et al⁴ proposed measuring pupil size to assess the effect of SGB. However, these assessment tools and methods have limitations due to the patient's position and environment, they cannot provide a quick, accurate, and repeatable method for obtaining the effects of SGB on different sites. With the advent of convenient ultrasound technology, the usSGB has emerged as a safer and more effective approach, particularly for patients who have limited mobility.¹⁹ This development opens up the possibility of using ultrasound techniques to serve as an objective measurement tool for assessing the hemodynamic effects of SGB. In 2003, Celiktas et al²⁰ used color duplex ultrasound to demonstrate that SGB results in dilatation of the artery and a reduction in resistive and pulsatility indices (RI, PI). In 2018, Min et al²¹ increased the sample size of the study to 52 cases and suggested that the pulse Doppler would be more valuable as an objective evaluation indicator. Furthermore, it has been noted that ultrasonic alterations exhibit greater sensitivity compared to changes in temperature.

Currently, WIA focuses on assessing left ventricular function and arterial elasticity in clinical practice. In 2018, ESC/ESH Guidelines²² recommended utilizing pulse wave velocity (PWV) as a pivotal indicator of arterial elasticity, characterizes arterial stiffness as arterial stiffness pulse wave velocity (PWV β), wave intensity pulse wave velocity (PWVwi), and other parameters related to arterial elasticity have garnered growing attention and application among clinical practitioners. Arterial WIA can be performed by both pressure-velocity and diameter-velocity methods, both of which provide reliable hemodynamic results.²³ Compared to invasive pressure-velocity methods, the usWIA offers a non-invasive and convenient means of measuring hemodynamic changes of the elasticity and flow velocity associated with the SGB. The SG is an integral part of the SNS, with its preganglionic and postganglionic fibers connecting to the brachial plexus and the cervical sympathetic nervous system chain, among others.²⁴ SGB can cause changes in head hemodynamics, previous studies have also shown that SGB can induce alterations in the upper extremity.^{20,21} The precise mechanism underlying SGB's effects on hemodynamics remains incompletely understood. Some researchers suggest that SGB may be associated with the blockade of afferent pathways of the SNS, leading to reduced levels of nerve growth factor (NGF), sympathetic excitation, and norepinephrine (NE).²⁵ As a result, SGB can effectively alleviate vasospasm, dilate blood vessels, and promote vascular elasticity and blood flow.

Previous researches have primarily examined arterial flow velocity, RI, and PI in relation to SGB. Our study builds upon these researches by utilizing the usWIA to endeavors to systematically evaluate the elasticity and flow velocity of specific blood vessels in its innervated areas (the CCA and brachial artery), which could provide more useful monitoring data for clinic. Initially, the success of SGB was confirmed through the traditional method of observing the occurrence of Horner's syndrome on the affected side. We found that unilateral SGB effectively increased arterial blood flow velocity on the blocked side, as evidenced by the increase in Vmin on the blocked side of the CCA, which aligns with previous studies.^{20,21,26} We also observed that unilateral SGB increases AC and decreases Ep, PWVwi, PWV β in the CCA and brachial artery on the blocked side. This provides direct evidence that SGB enhances arterial elasticity in its innervated areas, offering more valuable insights for its clinical application. The basic vital signs (HR, SBP and DBP) showed no significant changes. This not only confirms the clinical safety of SGB but also highlights the advantages of arterial elasticity and blood flow velocity in evaluating hemodynamic changes during SGB.

In certain cases, it is necessary to simply observe facial Horner's syndrome to confirm the success of SGB, but also to monitor the efficacy of SGB on specific organs or regions, particularly in patients undergoing upper extremity treatment. The usWIA offers advantages over other measurement tools due to its non-invasiveness, ease of operation, and repeatability. Furthermore, it can provide arterial elasticity data in addition to measuring blood flow velocity. Through comparing the changes in Vmin, AC, Ep, PWVwi and PWV β at targeted organs or regions, we can gain further insight into the impact of SGB in its innervated areas. In the future, the usWIA could serve as an accurate, objective, and efficient tool for evaluating the changes of elasticity and flow velocity during SGB, thereby contributing to clinical decision-making and enhancing our understanding of the underlying mechanisms behind SGB.

This study also discovered an increase in Ep, PWV β , and a decrease in AC, showing that unilateral SGB makes the contralateral side of the CCA less elastic. Current studies on the hemodynamics of the contralateral side of the SGB are controversial. Some studies suggest that SGB does not affect the hemodynamics of the contralateral side.^{15,26,27} Some believe that blood flow on the contralateral side is also increased.²⁸ There are also studies consistent with the results of our study,^{29,30} where the reduced elasticity may be related to the redistribution of blood flow from the contralateral side to the blocking side by unilateral SGB. It has previously been noted that this redistribution is mainly involved in peripheral tissue blood flow and does not affect the vital visceral blood supply.²⁹ HR, BP and the blood flow velocity of contralateral CCA no statistically significant differences were observed during this study, which suggests that the effects of unilateral SGB on the contralateral side are not sufficient to produce dramatic adverse effects.³¹ Presently, empirical evidence indicating additional adverse effects on patients due to changes in contralateral artery elasticity and hemodynamics post-SGB is lacking. Nevertheless, the potential impact and clinical relevance warrant further investigation.

While there are undoubted advantages to using usWIA for SGB, there are also limitations that need to be considered. Firstly, the age range of the study subjects was wide (55.68 ± 14.23 years), and several studies have noted that the results may differ when WIA is applied to different age groups.³¹ Therefore, age classification should be implemented when using usWIA to ensure accurate results. Secondly, this study only included patients with LVEF $\geq 50\%$. Future studies should aim to increase the sample size and include echocardiographic data from patients with varying levels of LVEF.

Conclusion

Overall, this study demonstrated that SGB enhanced the elasticity and blood flow velocity of the arteries on the blocked side by usWIA. The use of usWIA as an objective measurement tool for assessing the hemodynamic changes of SGB on target organs or site in clinical practice is also a valuable contribution of this study. Moreover, the study's assessment of the contralateral side of the CCA suggested that unilateral SGB diminishes arterial elasticity on the contralateral side.

Ethics Approval and Informed Consent

Ethical approval for this study was provided by the Ethical Committee of Yanan Hospital of Kunming City, Kunming, China. Patients signed informed consent forms before participating. Meanwhile, this study has complied with the Declaration of Helsinki and followed the STROBE Statement.

Funding

This project was funded by the Chunchen Scholar Foundation of Kunming City of Yunnan Province, China (grant No. ts201712089), and the Kunming Health Technology Talent Project (grant No. 2022-09-02-010 and 2023-SW-07).

Disclosure

The authors report no conflicts of interest in this work.

References

1. Fischer L, Barop H, Ludin SM, Schaible H. Regulation of acute reflectory hyperinflammation in viral and other diseases by means of stellate ganglion block. A conceptual view with a focus on Covid-19. *Auton Neurosci*. 2022;237:102903. doi:10.1016/j.autneu.2021.102903
2. Feigin G, Velasco Figueroa S, Englesakis MF, Souza D, Hoydonckx R, Bhatia A Y. Stellate ganglion block for non-pain indications: a scoping review. *Pain Med*. 2023;24(7):775–781. doi:10.1093/pm/pnad011
3. Winnie AP, Ramamurthy S, Durrani Z, Radonjic R, Shaker MH. Pharmacologic reversal of Horner's syndrome following stellate ganglion block. *Anesthesiology*. 1974;41(6):615–617. doi:10.1097/00000542-197412000-00017
4. Kim E, Lim JA, Choi CH, Lee SY, Kwak S, Kim J. Assessment of the changes in cardiac sympathetic nervous activity using the pupil size changes measured in seated patients whose stellate ganglion is blocked by interscalene brachial plexus block. *Korean J Anesthesiol*. 2023;76(2):116–127. doi:10.4097/kja.22324
5. Kim YU, Cheong Y, Kong YG, et al. The prolongation of pulse transit time after a stellate ganglion block: An objective indicator of a successful block. *Pain Res Manag*. 2015;20(6):305–308. doi:10.1155/2015/324514
6. Parker KH, Jones CJ. Forward and backward running waves in the arteries: analysis using the method of characteristics. *J Biomech Eng*. 1990;112(3):322–326. doi:10.1115/1.2891191
7. N K, Motoaki S, Dehua C, et al. A new noninvasive measurement system for wave intensity: evaluation of carotid arterial wave intensity and reproducibility. *Heart Vessels*. 2002;17(1).doi:10.1007/s003800200037

8. Gopal D, Singh N, Jagadeesh AM, Ture A, Thimmarayappa A. Comparison of left internal mammary artery diameter before and after left stellate ganglion block. *Ann Card Anaesth.* 2013;16(4):238. doi:10.4103/0971-9784.119161
9. Kawabata K, Sago T, Oowatari T, Shiiba S. Prolonged blockade of the cervical sympathetic nerve by stellate ganglion block accelerates therapeutic efficacy in trigeminal neuropathy. *J Oral Sci.* 2022;64(1):6–10. doi:10.2334/josnusd.21-0245
10. Guo J, Guo W, Jin X, et al. Effects of stellate ganglionic block on hemodynamic changes and intrapulmonary shunt in perioperative patients with esophageal cancer. *Eur Rev Med Pharm Sci.* 2014;18(24):3864.
11. De Cassai A, Calandra S, Iori D, et al. Stellate ganglion block effects on cerebral vascular tone: A missing piece of the puzzle. *J Neurosurg Anesth.* 2022;34(1):84. doi:10.1097/ANA.0000000000000740
12. Moshe C, Kaczorowski D, Bigeleisen P, Burrows W, Mazzeffi M. stellate ganglion blockade should be considered for patients with drug-refractory electrical storm on venoarterial extracorporeal membrane oxygenation. *Crit Care Med.* 2021;49(3):e333–e334. doi:10.1097/CCM.00000000000004743
13. Yongpeng Z, Rui X, Xin P, et al. Transection of the cervical sympathetic trunk inhibits the progression of pulmonary arterial hypertension via ERK-1/2 Signalling. *Respir Res.* 2019;20(1).doi:10.1186/s12931-019-1090-2
14. Zhang J, Nie Y, Pang Q, Zhang X, Wang Q, Tang J. Effects of stellate ganglion block on early brain injury in patients with subarachnoid hemorrhage: a randomised control trial. *BMC Anesthesiol.* 2021;21(1):23. doi:10.1186/s12871-020-01215-3
15. Wendel C, Scheibe R, Wagner S, et al. Decrease of blood flow velocity in the middle cerebral artery after stellate ganglion block following aneurysmal subarachnoid hemorrhage: a potential vasospasm treatment? *J Neurosurg.* 2019;133:773–779. doi:10.3171/2019.5.JNS182890
16. Kowligi GN, Cha YM. Continuous infusion versus single injection for stellate ganglion blockade. *JACC Clin Electrophys.* 2021;7(4).doi:10.1016/j.jacep.2020.10.008
17. Wei N, Chi M, Deng L, Wang G. Antioxidation role of different lateral stellate ganglion block in isoproterenol-induced acute myocardial ischemia in rats. *Reg Anesth Pain Med.* 2017;42(5):588–599. doi:10.1097/AAP.0000000000000647
18. Yamazaki H, Nishiyama J, Suzuki T. Use of perfusion index from pulse oximetry to determine efficacy of stellate ganglion block. *Local Reg Anesth.* 2012;5 doi:10.2147/LRA.S30257.
19. Chung BY, Holfelder C, Feldmann RE, Kleinboehl D, Raum RC, Benrath J. Magnetic resonance imaging validation of medial transthyroid ultrasound-guided stellate ganglion block: A pilot study. *Pain Pract.* 2021 doi:10.1111/papr.13085.
20. Çeliktas M, Birbiçer H, Aikimbaev K, Özbek H, Akgül E, Binokay F. Utility of color duplex sonography in the assessment of efficacy of the stellate ganglion blockade. *Acta Radiol.* 2003;44(5):494–497. doi:10.1080/j.1600-0455.2003.00106.x
21. Kim MK, Yi MS, Park PG, Kang H, Lee JS, Shin HY. Effect of stellate ganglion block on the regional hemodynamics of the upper extremity: a randomized controlled trial. *Anesthesia Analg.* 2018;126(5):1705–1711. doi:10.1213/ANE.0000000000002528
22. Williams B, Mancia G, Spiering W, et al. ESC/ESH Guidelines for the management of arterial hypertension. *Eur Heart J.* 2018;39(33):3021–3104. doi:10.1093/eurheartj/ehy339
23. Reavette RM, Sherwin SJ, Tang M, Weinberg PD. Comparison of arterial wave intensity analysis by pressure–velocity and diameter–velocity methods in a virtual population of adult subjects. *Proc Inst Mech Eng.* 2020;234(11):1260–1276. doi:10.1177/0954411920926094
24. Piraccini E, Munakomi S, Chang KV Stellate Ganglion Blocks; 2021.
25. Lipov E, Ritchie EC. A review of the use of stellate ganglion block in the treatment of PTSD. *Curr Psychiatry Rep.* 2015;17(8):599. doi:10.1007/s11920-015-0599-4
26. Nitahara K, Dan K. Blood flow velocity changes in carotid and vertebral arteries with stellate ganglion block: measurement by magnetic resonance imaging using a direct bolus tracking method. *Reg Anesth Pain Med.* 1998;23(6):600–604. doi:10.1016/s1098-7339(98)90088-8
27. Jin F, Li X, Tan W, et al. RETRACTED ARTICLE: effects of ultrasound-guided stellate-ganglion block on sleep and regional cerebral oxygen saturation in patients undergoing breast cancer surgery: a randomized, controlled, double-blinded trial. *J Clin Monit Comput.* 2018;32(5):855–862. doi:10.1007/s10877-017-0074-3
28. Yasuda M, Kuroda H, Suzuki K, et al. Impact of stellate ganglion block on tissue blood flow/oxygenation and postoperative mandibular nerve hypoesthesia: a cohort study. *J Oral Maxillofac Surg.* 2022;80(2):266.e1–266.e8. doi:10.1016/j.joms.2021.08.161
29. Kasahara M, Terakawa Y, Ichinohe T, Kaneko Y. Unilateral Stellate ganglion block produces bidirectional changes in tissue oxygen tension of the mental nerve in Rabbits. *J Oral Maxillofac Surg.* 2012;70(1):45–48. doi:10.1016/j.joms.2011.06.217
30. Terakawa Y, Ichinohe T, Kaneko Y. Redistribution of tissue blood flow after stellate ganglion block in the rabbit. *Reg Anesth Pain Med.* 2009;34(6):553–556. doi:10.1097/AAP.0b013e3181b4c505
31. Vriz O, Favretto S, Jaroch J, et al. Left ventricular function assessed by one-point carotid wave intensity in newly diagnosed untreated hypertensive patients. *J ultra med.* 2017;36(1):25–35. doi:10.7863/ultra.16.02031