

Relationship Between Temporomandibular Joint Effusion, Pain, and Jaw Function Limitation: A 2D and 3D Comparative Study

Sophie Lau Rui Han^{1,*}, Jie Xiang^{1,*}, Xiang-Xiang Zeng², Pei-Di Fan¹, Qiao-Yu Cheng¹, Xue-Man Zhou¹, Zheng Ye², Xin Xiong¹, Jun Wang¹

¹State Key Laboratory of Oral Diseases & National Center for Stomatology & National Clinical Research Center for Oral Diseases & Department of Orthodontics, West China Hospital of Stomatology, Sichuan University, Chengdu, Sichuan Province, People's Republic of China; ²Department of Radiology, West China Hospital, Sichuan University, Chengdu, Sichuan, People's Republic of China

*These authors contributed equally to this work

Correspondence: Xin Xiong; Jun Wang, State Key Laboratory of Oral Diseases & National Center for Stomatology & National Clinical Research Center for Oral Diseases, West China Hospital of Stomatology, Sichuan University, Chengdu, 610041, People's Republic of China, Tel +86-28-85503898; +86-28-85501425, Email drxiongxin@scu.edu.cn; wangjunv@scu.edu.cn

Purpose: This study aimed to investigate the relationship between temporomandibular joint (TMJ) effusion and TMJ pain, as well as jaw function limitation in patients via two-dimensional (2D) and three-dimensional (3D) magnetic resonance imaging (MRI) evaluation.

Patients and Methods: 121 patients diagnosed with temporomandibular disorder (TMD) were included. TMJ effusion was assessed qualitatively using MRI and quantified with 3D Slicer software, then graded accordingly. In addition, a visual analogue scale (VAS) was employed for pain reporting and an 8-item Jaw Functional Limitations Scale (JFLS-8) was utilized to evaluate jaw function limitation. Statistical analyses were performed appropriately for group comparisons and association determination. A probability of $p < 0.05$ was considered statistically significant.

Results: 2D qualitative and 3D quantitative strategies were in high agreement for TMJ effusion grades ($\kappa = 0.766$). No significant associations were found between joint effusion and TMJ pain, nor with disc displacement and JFLS-8 scores. Moreover, the binary logistic regression analysis showed significant association between sex and the presence of TMJ effusion, exhibiting an Odds Ratio of 5.168 for females ($p = 0.008$).

Conclusion: 2D qualitative evaluation was as effective as 3D quantitative assessment for TMJ effusion diagnosis. No significant associations were found between TMJ effusion and TMJ pain, disc displacement or jaw function limitation. However, it was suggested that female patients suffering from TMD may be at a risk for TMJ effusion. Further prospective research is needed for validation.

Keywords: temporomandibular disorder, temporomandibular joint pain, three-dimensional analysis, 3D slicer

Introduction

Temporomandibular disorder (TMD) refers to a group of conditions that affect the temporomandibular joint (TMJ) and its surrounding structures, including muscles, ligaments, and bony components serving for the movement and function of the jaw.¹ It presents as a range of symptoms, such as joint and muscle tenderness, difficulty chewing or opening mouth, audible joint sounds during jaw movements (clicking or crepitus) and may often lead to orofacial pain.² As one of the most common symptoms associated with TMD, TMJ pain is characterized by discomfort in the joint and surrounding muscles, which can be intermittent or chronic and radiate to regions like dental arches, temples and forehead.³ In most cases, conservative therapies, such as occlusal splint treatment, massage and manual therapy are considered to be the first-choice strategy for managing TMJ pain, while invasive procedures would be adopted in severe cases. It has been

accepted that the treatment methods selected for TMJ pain management should be conformable to the origin and contributing factors of the dysfunction.⁴

Another pathological change that can result from TMD is TMJ effusion, an abnormal accumulation of fluid in the joint space.⁵ The etiology of TMJ effusion is multifactorial and may be attributed to secondary reactions to inflammation caused by trauma, injury, or degenerative changes in the joint. Several studies have reported that TMJ effusion is frequently observed in TMD patients and could serve as an important indicator for inflammatory processes or potential joint disease.⁶ In addition, patients with TMD who experience TMJ effusion may also experience joint pain. To date, considerable effort has been devoted to investigating the influence of TMJ effusion on TMJ pain and the underlying relationship between them. For instance, previous researchers claimed that there was an association between the risk of effusion formation and pain, along with structural changes in the temporomandibular joint disc and disc displacement.⁷⁻⁹ Conversely, some studies suggested that there is no direct relationship between joint effusion and TMJ pain as a predictor.^{6,10} Moreover, Guarda-Nardini et al suggested that there might be limited therapeutic benefit from eliminating joint effusion in their research on the treatment efficacy of TMJ arthrocentesis.¹¹ Therefore, the association between TMJ effusion and pain, alongside TMJ disc displacement, is still a matter of debate, and more research is necessary to further validate the controversy.

Recently, magnetic resonance imaging (MRI) has emerged as a key diagnostic tool in the field of TMD research due to its excellent soft tissue resolution that helps visualize the three-dimensional (3D) anatomical structure of TMJ. Specifically, MRI assists in the detection of abnormalities, including TMJ effusion, disc displacement, and degenerative changes,¹² which makes it the gold standard for diagnosing and characterizing TMJ pathology.¹³ Generally, TMJ effusion is identifiable by a high signal intensity on a T2 weighted MRI. Sagittal and coronal T2 sequences in MRI imaging facilitate the identification and assessment of TMJ effusion by evaluating its location and extent, thereby determining changes in the joint synovial fluid.¹⁴

To date, most current assessment methods rely primarily on the qualitative evaluation of two-dimensional (2D) slice images from MRI sequences. However, this approach may have limitations in assessing the accurate effusion size and severity. The rising application of 3D reconstruction provided new means to quantitatively assess joint effusion.¹⁵ 3D methods facilitate a more detailed and visual understanding of the pathological changes in TMJ and may potentially enhance the current analysis of MRI slice images. Nonetheless, there are still insufficient studies focused on the effectiveness of 3D quantification in TMJ effusion diagnosis, as well as its necessity over 2D qualitative assessment since it often requires extra temporal and financial cost.

Therefore, with an attempt to answer the questions mentioned above, in this study we firstly analyzed the TMJ effusion of included participants through 2D qualitative evaluation and 3D quantitative assessment respectively and explored the consistency of these two methods. After that, the relationship between TMJ effusion and TMJ pain reported by patients with a Visual Analogue Scale (VAS) was examined. In addition, the influence of joint effusion on TMJ disc displacement was also studied. Lastly, a short form of the Jaw Functional Limitation Scale (JFLS-8) was employed as a holistic assessment of the patients' jaw function limitations, and the impact of TMJ effusion on it was investigated.¹⁶ By doing so, we wish to provide the clinicians with more reference information on the diagnosis and management of TMJ effusion in the treatment of TMD patients.

Materials and Methods

Ethics Approval

This study was conducted in accordance with the ethical principles of the Declaration of Helsinki and was approved by the Research Ethics Committee of the West China Hospital of Stomatology (WCHSIRB-2020-378). All participants or their legal guardians provided fully informed consent prior to the study.

Study Population and Sample Selection

Patients who sought treatment at the Temporomandibular Joint Department of West China Hospital of Stomatology between December 2021 and December 2023 were recruited in the study for selection according to the inclusion and

exclusion criteria as follows. The inclusion criteria comprised: 1. Individuals diagnosed with unilateral or bilateral TMD according to the Diagnostic Criteria for Temporomandibular Disorders (DC/TMD);³ 2. Participants with complete bilateral TMJ MRI records and TMJ VAS pain scores; 3. Patients with full demographic information record and valid responses to JFLS-8. Whereas the exclusion criteria included: 1. Patients with a history of TMJ-related surgeries or invasive treatments, TMJ trauma/tumors/extensive deformities; 2. Patients diagnosed with autoimmune or systemic diseases; 3. Patients with long-term use of opioids, steroids, or non-steroidal anti-inflammatory drugs (NSAIDs); 4. The pain reported by patients was verified to derive from myalgia or TMD headache.

Sample Size Calculation

The sample size was calculated through an appropriate calculator (<https://www.surveymonkey.com/mp/sample-size-calculator/>) based on similar previous studies.^{8,15,17} Assuming a confidence level of 95%, a margin of error of 5%, and a population proportion of 50%, the minimum sample size required was determined to be 92 participants.

Data Collection

MRI Protocol

MRI images were obtained using MRI scanners with settings the same as a previous study.¹⁸ Scans were taken in the closed mouth position and T2 weighted images on the oblique sagittal plane were utilized.

2D Qualitative Grading of TMJ Effusion from MRI

MRI scans were read on a radiography imaging program, RadiAnt DICOM Viewer (Version 2023.1 64-bit). The image pathologies were interpreted by two experts: a radiologist with 3 years of experience and a TMJ expert with 5 years of experience, both proficient in interpreting TMJ MRI. Both experts were blinded to the patients' diagnoses and information. Any disagreements were resolved by consulting a third expert. The imaging program was used to qualitatively assess the area of effusion in each imaging slice, with the slice containing the largest effusion area selected for analysis.

Joint effusions in bilateral TMJs were then identified and graded, as shown in [Figure 1](#), using classifications established by previous studies as follows:^{19,20}

Grade 0 (No visible effusion): no visible area of effusion.

Grade I (Little effusion): a fine streak or blot of high signal intensity in the upper or lower joint cavity.

Grade II (Moderate effusion): a notable area of high signal intensity in upper and/or lower joint cavities, the extent of which is between little and large effusion.

Grade III (Large effusion): large area of effusion pooling in the upper and/or lower joint cavities.

The effusion in the left and right TMJs of the same patient was compared, and the side with a higher grade was chosen for subsequent research. Based on the side with more joint effusion, the disc displacement of the TMJ was analyzed and recorded as superior (normal) disc position, disc displacement with reduction (DDWR) or disc displacement without reduction (DDWoR).

3D Quantitative Evaluation of Joint Effusion

Joint effusions identified above were further analyzed using a high-performance laptop running Windows 11 Home (Version 23H2) with a 13th Gen Intel Core i9-13900H (2.60 GHz), 16.0 GB GDDR6 RAM, and a 1TB M.2 NVMe PCIe 4.0 SSD.

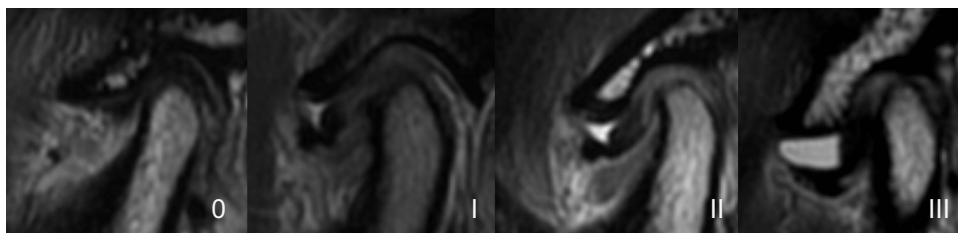


Figure 1 2D Qualitative grading of joint effusion: Grade 0 – no visible effusion, Grade I – little effusion, Grade II- moderate effusion, Grade III – large effusion.

3D Slicer (Version 5.4.0) (<https://www.slicer.org/>), an open source medical image processing and visualization software platform featuring solid image registration and segmentation capabilities,^{21,22} was employed to import the manually-segmented MRI scans for reconstructing the presence of joint effusion three-dimensionally in both left and right TMJs. Within the “Segment Editing” module, the 3D-reconstructed model of joint effusion was produced by “drawing” and detailing the outline of the effusion on every image slice of the MRI scans.²³ Uneven surfaces on the segmented model were smoothed out and finally, a volumetric quantitative analysis of the joint effusion model was performed and recorded. Similar to the qualitative grading previously mentioned, the side with more severe joint effusion was chosen from each participant.

To ensure accuracy, the 3D reconstructions of joint effusion and volume analysis were performed twice, with a one-month interval between the attempts. The average of the two readings was taken down for grading. An intra-rater reliability correlation (ICC) test was conducted on the two sets of measurements, which showed high reliability (ICC = 0.940, $p < 0.001$).

Based on the joint effusions as graded by the qualitative analysis before, a range of volumetric values was derived to quantify the joint effusion segments into four grades, where grades I to III are shown in [Figure 2](#)

Grade 0 (No visible effusion): volume is 0 cm³.

Grade I (Little effusion): total volume measured from more than 0–0.0399 cm³.

Grade II (Moderate effusion): total volume measured from 0.0400–0.0999 cm³.

Grade III (Large effusion): total volume measured more than 0.1000 cm³.

Assessment of TMJ Pain and Jaw Function Limitation

TMJ pain and jaw function limitation were assessed primarily by means of self-reporting. Participants were examined in clinic to distinguish the origin of pain and then required to rate the current pain level in their TMJs according to a VAS from 0–10, with 0 being no pain while 10 being the most intense.

In addition, a validated Chinese version of JFLS-8 was given to each participant for rating the degree of their jaw function limitation during the past one month on scales of 0–10 with eight items, where 0 is no limitation and 10 is severe limitation.²⁴ A total score was recorded for all the eight items.

Statistical Analysis

Statistical analysis was performed with the Statistical Package for the Social Sciences (SPSS) (version 27.0; IBM Corporation). The collected data were initially analyzed with descriptive statistics and normality tests. Afterwards, independent t-tests were used to compare the difference of normally distributed continuous variables between two independent samples, and Chi-square tests were employed for the comparison of proportions. Non-parametric tests, including the Mann–Whitney *U*-test, were conducted as appropriate. In addition, Cohen’s weighted kappa was utilized for the consistency test and binary logistic regression analysis was performed to figure out the correlation between joint effusion grade and TMJ pain presence while controlling for other confounding variables. The significance level was set at $p < 0.05$.

Results

A total of 618 patients were recruited in the study and screened for the inclusion and exclusion criteria. After the initial selection, 121 patients (104 females, 17 males; mean age 26.52 ± 9.54 years) were included ultimately for further research. The selection process was detailed in [Figure 3](#).

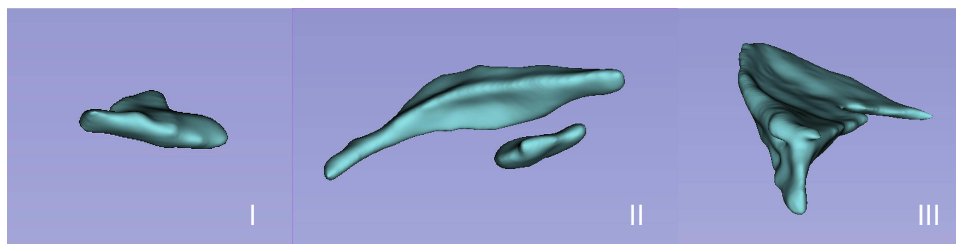


Figure 2 3D Quantitative evaluation of joint effusion: Grade I – little effusion, Grade II- moderate effusion, Grade III – large effusion.

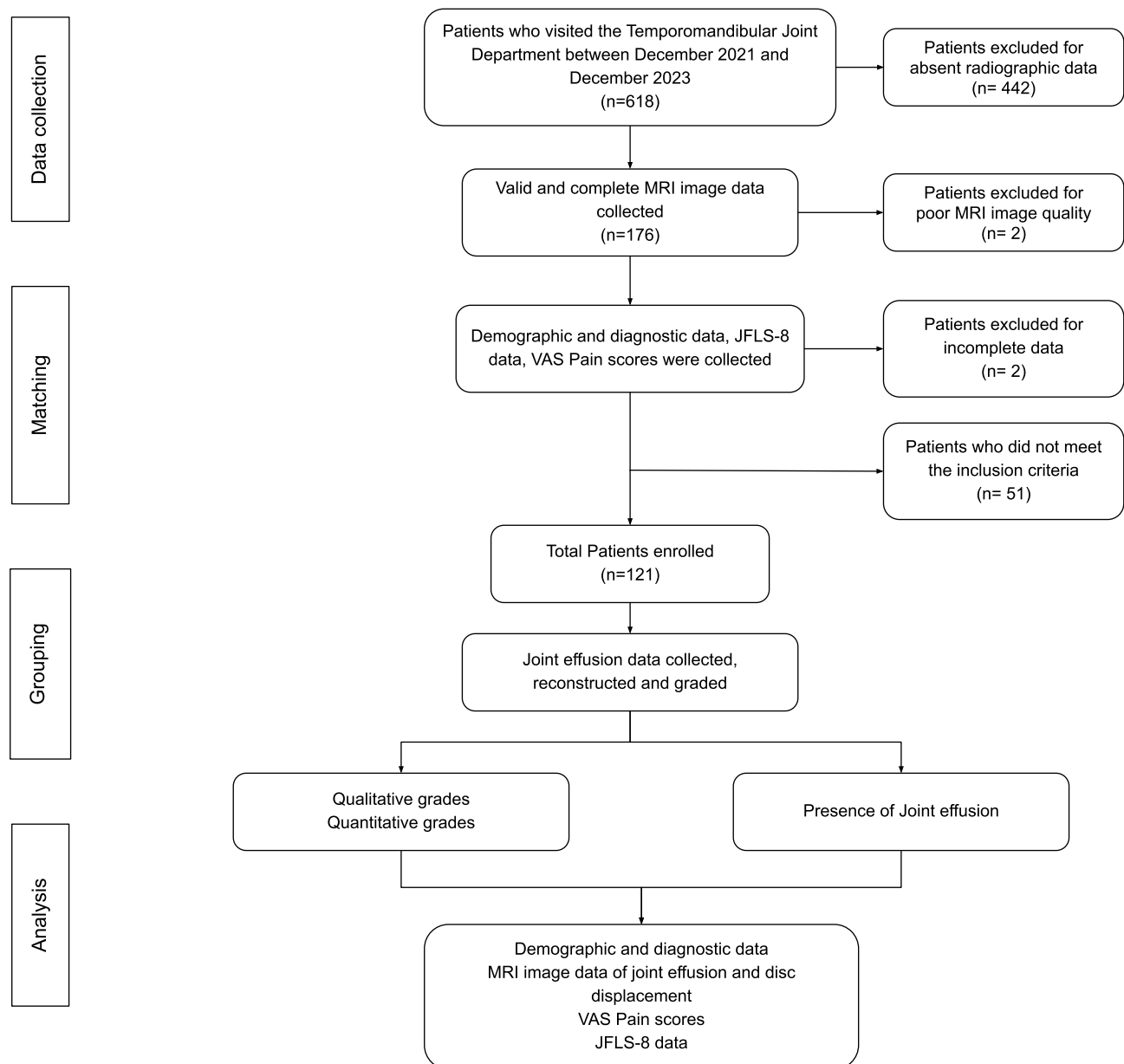


Figure 3 The participant selection and analysis process.

Abbreviations: n, Number of patients; MRI, Magnetic Resonance Imaging; JFLS-8, 8-item Jaw Functional Limitation Scale; VAS, Visual Analogue Scale.

The Overall Characteristics of Included Patients

As described in [Table 1](#) and [Figure 4](#), a total of 104 patients were diagnosed with varying degrees of TMJ effusion via both 2D qualitative and 3D quantitative methods, while 17 participants were proved to be absent from this symptom. No significant difference was found in age between these two groups, but the sex distribution difference was statistically significant ($p = 0.007$). As for TMJ pain, 42 out of 104 patients with joint effusion (JE) present reported painful TMJs, and the ratio was slightly higher than that of JE-absent patients (40.4% versus 35.3%). However, the difference was not statistically significant ($p = 0.691$).

Agreement Between 2D Qualitative and 3D Quantitative Grades

The results of 2D qualitative and 3D quantitative grades for TMJ effusion were compared against each other to verify the agreement level between them. Consequently, the calculated Cohen's weighted kappa coefficient was 0.766 and it was

Table 1 Distribution of Patients with or Without Joint Effusion

	JE Absent			JE Present			p value
	n (%)	Mean	SD	n (%)	Mean	SD	
Age	17 (14.0)	25.6	11.5	104 (86.0)	26.7	9.2	0.666
Sex							
Male	6 (35.3)			11 (10.6)			0.007*
Female	11 (64.7)			93 (89.4)			
TMJ pain							
Absent	11 (64.7)			62 (59.6)			0.691
Present	6 (35.3)			42 (40.4)			

Note: * $p < 0.05$ is significant for Pearson's Chi-square test;

Abbreviations: JE, Joint Effusion; n, Number of patients; SD, Standard Deviation; %, Percentage.

statistically significant ($p = 0.000$), indicating a statistically significant substantial consistency between the two types of grading strategies (seen in Table 2).

Relationship Between Joint Effusion and TMJ Pain

After the joints were graded qualitatively and quantitatively, a Chi-square test was conducted to find out any association between TMJ effusion of varying degrees and the presence of TMJ pain; however, no statistically significant difference was found as illustrated in Figure 4.

Additionally, a binary logistic regression analysis was performed between the binary-divided TMJ effusion (0: no effusion; 1: little to severe effusion) and age, sex, as well as TMJ pain existence. The results revealed that sex showed a significant correlation with TMJ effusion presence in this logistic regression model, exhibiting an Odds Ratio (OR) of 5.168 for females regardless of the evaluation strategy for effusion ($p = 0.008$). By contrast, age and TMJ pain were not found to be significantly correlated with TMJ effusion presence, as presented in Table 3.

Relationship Between Joint Effusion and Disc Displacement at Closed Mouth Position

Since there was a slight difference between the sides of joint effusion chosen with qualitative and quantitative grades, disc displacements were evaluated accordingly under the two circumstances based on the displacement and reduction

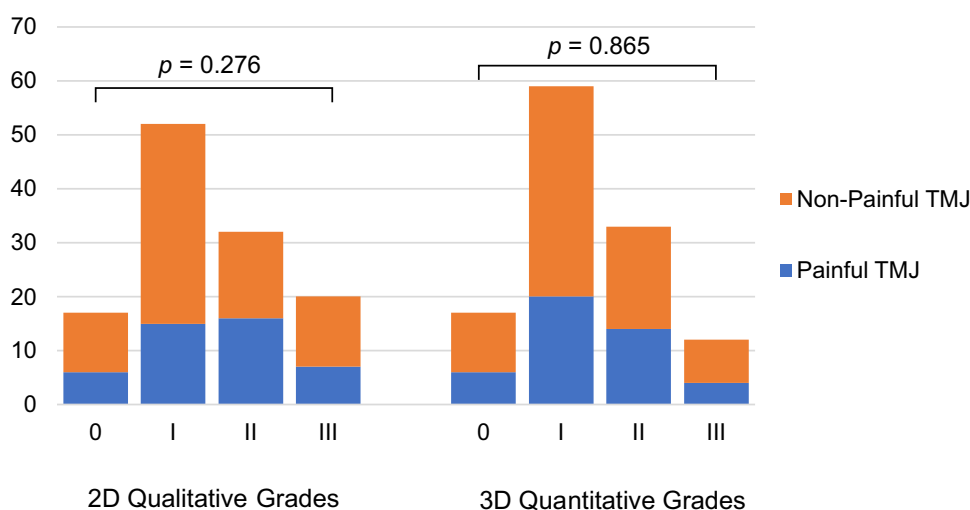


Figure 4 Graded joint effusion classified by the presence of pain in TMJs.

Note: $p < 0.05$ is significant.

Abbreviations: TMJ, Temporomandibular Joint; 2D, Two-dimensional; 3D, Three-dimensional.

Table 2 Consistency of Joint Effusion Grades Between 2D Qualitative and 3D Quantitative Methods

3D Quantitative Grades		2D Qualitative Grades							
		0	No effusion	I	Little effusion	II	Moderate effusion	III	Large effusion
0	No effusion	17	–	–	–	–	–	–	17
I	Little effusion	–	49	9	–	–	–	–	59
II	Moderate effusion	–	3	20	–	–	–	–	33
III	Large effusion	–	–	3	–	–	–	–	12
Total		17	52	32	–	–	–	20	121
Cohen's Weighted Kappa		0.766*							

Note: * $p < 0.05$ is significant.

Abbreviations: 2D, Two-dimensional; 3D, Three-dimensional.

Table 3 Logistic Regression of TMJ Effusion Presence and Other Variables

Variables	Qualitative joint effusion				Quantitative joint effusion			
	OR	95% CI		<i>p</i> value	OR	95% CI		<i>p</i> value
		LL	UL			LL	UL	
Constant	0.166			0.226	0.166			0.226
Age	1.026	0.967	1.090	0.397	1.026	0.967	1.089	0.397
Sex								
Male	1.000				1.000			
Female	5.168	1.534	17.415	0.008*	5.168	1.534	17.415	0.008*
TMJ pain								
No Pain	1.000				1.000			
Painful	0.985	0.323	3.007	0.979	0.986	0.323	3.010	0.981

Note: * $p < 0.05$ is significant.

Abbreviations: OR, Odds Ratio; CI, Confidence Interval; LL, Lower Limit; UL, Upper Limit; %, Percentage.

capability of TMJ discs. The result showed that there was no significant difference in the proportion of normal position, DDWR and DDWoR between JE-absent and JE-present groups regardless of whether the effusion was assessed in a 2D or 3D way (seen in Table 4).

Relationship Between Joint Effusion and Jaw Function Limitation

Mann–Whitney *U*-tests were conducted to determine the relationship between the presence of joint effusion and items in JFLS-8. As presented in Table 5, the total score of JFLS-8 showed no significant difference although a higher score median was found in JE-present group ($p = 0.458$). Similarly, differences between JE-present and JE-absent groups in each individual item were recognized to be statistically insignificant.

Discussion

Although it has been studied by previous research, there is still a debate regarding the correlation between TMJ effusion and TMJ pain, as well as disc displacement. Additionally, few studies have focused on whether TMJ effusion contributes to the limitation of jaw function in TMD patients so far. Here in this study, we made an attempt to answer these questions by analyzing the TMJ effusion of included participants through a 2D qualitative evaluation of MRI image slices, and

Table 4 Number of Joints with Effusion Divided by Disc Displacement at Closed Mouth Position

Disc Displacement	JE Absent	JE Present	p value
	n (%)	n (%)	
Under 2D Qualitative JE Grade			
Normal	0 (0.0)	8 (7.7)	0.391
DDWR	7 (41.2)	48 (46.2)	
DDWoR	10 (58.8)	48 (46.2)	
Under 3D Quantitative JE Grade			
Normal	0 (0.0)	7 (6.7)	0.450
DDWR	7 (41.2)	48 (46.2)	
DDWoR	10 (58.8)	49 (47.1)	

Note: $p < 0.05$ is significant for Pearson's Chi-square test.

Abbreviations: n, Number of patients; 2D, Two-dimensional; 3D, Three-dimensional; JE, Joint Effusion; %, Percentage; DDWR, Disc Displacement with Reduction; DDWoR, Disc Displacement without Reduction.

Table 5 JFLS-8 Results Comparison Between Patients with and without TMJ Effusion

JFLS-8	JE Absent			JE Present			p value
	n	Median	(Quartiles)	n	Median	(Quartiles)	
Chew tough food	17	5.00	(1.00, 5.50)	104	4.00	(2.00, 7.00)	0.638
Chew chicken		5.00	(2.00, 6.00)		5.00	(2.00, 7.00)	0.309
Eat soft food		0.00	(0.00, 0.00)		0.00	(0.00, 0.00)	0.057
Wide enough to drink from a cup		0.00	(0.00, 3.50)		0.00	(0.00, 2.00)	0.750
Swallow		0.00	(0.00, 0.00)		0.00	(0.00, 0.00)	0.097
Yawn		3.00	(0.00, 6.00)		3.00	(1.00, 5.00)	0.372
Talk		0.00	(0.00, 1.50)		0.00	(0.00, 1.00)	0.893
Smile		0.00	(0.00, 0.00)		0.00	(0.00, 0.00)	0.329
JFLS-8 Total Score		13.00	(7.50, 19.00)		14.00	(7.25, 22.00)	0.458

Note: $p < 0.05$ is significant for Mann-Whitney *U*-test.

Abbreviations: JFLS-8, 8-item Jaw Functional Limitation Scale; JE, Joint Effusion.

a 3D quantification strategy was also utilized for the effusion grading. Results showed that the two types of joint effusion assessments were in high agreement with each other, and 3D quantitative evaluation did not exhibit too much superiority over 2D qualitative grade throughout the following analyses. Consequently, we believe that 2D qualitative assessment of TMJ effusion can provide sufficient diagnostic information compared to the 3D approach and is more practical for clinical use. In addition, the study found no statistically significant correlation between TMJ effusion and pain, nor with disc displacement and jaw function limitation.

As reported in previous investigations, the association between TMJ effusion and pain remains controversial. Some studies claimed that there was a significant relationship between these two symptoms, and joint effusion might be a screening sign for painful TMJ,^{8,9,20,25} whereas Yamamoto et al suggested that the conclusion could be drawn only in DDWoR patients.²⁶ However, in contrast to previous literature, no significant associations were found between the TMJ effusion and pain in our study. Although a painful TMJ was more frequent in the group suffering from TMJ effusion (40.4% versus 35.3%), the difference was not statistically significant. Furthermore, the results of Mann-Whitney *U*-test and binary logistic regression also suggested that there may not be a direct correlation between the presence or severity of joint effusion and TMJ pain reported by patients, which was in accordance with several previous studies.^{6,10} The disagreement between studies may be attributed to the subjects enrolled for research. In this study, to minimize

confounding factors as much as possible, patients with TMJ pain originating from muscles and headache were not included. Moreover, the intrinsic subjectivity of pain perception and a possible time lag between TMJ effusion development and pain perception may also result in variability. It may not be appropriate to simply regard TMJ effusion as a screening sign for TMJ pain, as stated above.

A Pearson's Chi-square test revealed a statistically significant association between sex and the presence of joint effusion, which was consistent with previous studies where females were associated with a higher risk of joint effusion.^{9,27} This association was supported in the logistic regression analysis, with an odds ratio of 5.168 for females in predicting TMJ effusion suffering. Therefore, sex may be considered as a reliable predictor of joint effusion presence in TMD patients.

In addition to TMJ pain, the relationship between disc displacement and joint effusion has also been examined in literature. Earlier studies recognized a correlation between TMJ effusion and DDWoR but not DDWR, and the researchers conjectured that more inflammatory mediators or abnormal mechanical stress might be produced by DDWoR, which resulted in effusion formation in some TMJs.^{28,29} Another study reported a significant association between DDWR and joint effusion.⁹ Meanwhile, Khawaja et al found significant associations between joint effusion and both DDWR and DDWoR.⁶ However, on the contrary, our study did not find any significant relationships between the presence of joint effusion and TMJ disc displacement, whether with normal position, DDWR or DDWoR. One possible explanation for the non-significant association could be the limited variety of disc displacement evaluated between joints. Additionally, the displacement of the TMJ disc and effusion formation may take place in different pathological stages, making it more complicated to find a simple correlation between them.

The relationship between TMJ effusion and impaired jaw functions was also investigated with JFLS-8. The items are largely classified by assessing individuals on "mastication", "vertical jaw mobility", "verbal and emotional expression", and "miscellaneous" activities, such as swallowing and yawning.¹⁶ Although previous research have suggested that TMD patients tend to experience more difficulty in chewing and more severe jaw function limitations,^{16,30} few studies explored the influence of TMJ effusion on jaw function. It was reported in an earlier study by Thomas et al that TMJ effusion was significantly associated with mouth opening, an important mandibular movement for the functioning of yawning and swallowing.³¹ However, the results of our study did not find any significant difference between JE-present and JE-absent groups in both JFLS total scores, and each JFLS-8 item, which did not necessarily support the hypothesis that TMJ effusion could directly impose an adverse effect on jaw functions. Hence, whether the impaired jaw functions of TMD patients could be relieved through eliminating joint effusion alone still needs to be investigated.

Collectively, TMJ effusion was not found to be significantly associated with TMJ pain, disc displacement and impaired jaw functions of TMD patients in this study. Therefore, to simply regard TMJ effusion as a screening sign for these symptoms or pathological changes may be inappropriate to some extent. Clinicians should be cautious enough when prescribing invasive treatments to eliminate joint effusion in hopes of alleviating pain and the limitation of jaw functions. It is also important to consider other factors during treatment planning. Furthermore, reconstructing the joint effusion in three dimensions may have limited benefits in clinical practice, and clinicians may find it more convenient to examine the qualitative grade of joint effusion to arrive at a quicker diagnosis of TMD and generating treatment plans.

Our study utilized MRI for the diagnosis of TMJ effusion, which is regarded as a gold standard for diagnosing TMJ pathology. However, it is also limited in its wide application due to its restricted availability, time-consuming procedures, and high costs. Additionally, interpreting MRI results requires a well-trained professional. An alternative diagnostic method for detecting TMJ effusion is ultrasound, which can visualize joint effusion by assessing the distension of the TMJ capsule.³² Compared to MRI, ultrasound is less expensive, quicker, and more accessible, making it favorable for detecting soft tissue changes in the TMJ. However, the resolution of ultrasound is lower for an accurate and detailed observation. Similar to MRI, skilled operators and appropriate transducer frequency are required for the utilization of ultrasound in TMJ diagnosis.³³ Therefore, clinicians may choose the optimal diagnosing instrument based on their accessibility and diagnostic requirement. Meanwhile, some emerging technologies also deserve attention. For example, a recent study by Girondi et al reported the employment of MRI texture analysis (TA) in detecting changes in TMJ discs

due to effusion.³⁴ The findings revealed that patients with effusion showed lower average imaging parameters, suggesting the presence of underlying changes that are not discernible through conventional visual inspection of MRI.³⁴

On the other hand, our study used VAS and JFLS-8, two kinds of classical patient-reported outcome measures (PROMs) to evaluate the subjective perception of participants about the influence of TMD symptoms. Other frequently used PROMs include the Oral Health Impact Profile-14 (OHIP-14), Generalized Anxiety Disorder-7 (GAD-7), and Patient Health Questionnaire-9 (PHQ-9) for assessing quality of life and mental well-being.³⁵ Since TMD patients often report a lower quality of life and higher risks of anxiety and depression, particularly those with pain-related and intra-articular TMDs,^{36,37} incorporating corresponding PROMs into future research can significantly enhance the understanding of how TMJ effusion may affect the life quality and mental health of TMD patients.

This study has several limitations. Firstly, the retrospective research design makes it hard to exclude the influence of a potential time lag between TMJ effusion presence and pain perception, as well as changes in disc displacement. This may have increased the difficulty of determining the correlations between these symptoms. As a result, prospective or longitudinal studies are warranted to further clarify the aforementioned issues and to discuss a causal relationship between joint effusion and pain, disc displacement, and jaw function limitation. Secondly, a larger sample size with varying severities of joint effusion and a wider range of disc displacements would provide a more comprehensive understanding of joint effusion and disc displacement. Finally, the retrospective study was not able to analyze the specific composition of TMJ effusion through arthrocentesis, nor compare the differences in components between large and small effusions in relation to TMJ pain. Future research could address this shortcoming by including both quantitative analysis and detailed component comparison.

Additionally, future studies could also quantify qualitative measurements to establish a clearer grading scale for joint effusion. This will aid in diagnosing joint effusion and determining appropriate treatment plans for patients.

Conclusions

Through the quantitative and qualitative analysis of joint effusion in this study, it was found that joint effusion does not have a significant association with TMJ pain, disc displacement or impaired jaw functions of TMD patients. Additionally, female TMD patients may be at a higher risk for TMJ effusion. It was also found that a 2D qualitative evaluation of MRI slice images was equally as effective as a 3D quantitative assessment for diagnosing TMJ effusion. Prospective or longitudinal studies may be preferred in the future to further validate the correlations and possible causal relationships between TMJ effusion and pain perception, disc displacement, and impaired jaw function.

Data Sharing Statement

The data used to support the findings of this study are available from the corresponding author upon request.

Funding

This work was supported by the National Natural Science Foundation of China (82301129), Clinical Research Project of West China Hospital of Stomatology, Sichuan University (LCYJ-2023-YY-2), the Sichuan Science and Technology Program (2021ZYD0104) and Major Special Science and Technology Project of Sichuan Province (grant no. 2022ZDZX0031).

Disclosure

The authors declare that there is no conflict of interest regarding the publication of this paper.

References

1. Carlsson GE. Epidemiology and treatment need for temporomandibular disorders. *J Orofac Pain*. 1999;13(4):232–237.
2. Gil-Martinez A, Paris-Aleman A, Lopez-de-Uralde-Villanueva I, La Touche R. Management of pain in patients with temporomandibular disorder (TMD): challenges and solutions. *J Pain Res*. 2018;11:571–587. doi:10.2147/JPR.S127950
3. Schiffman E, Ohrbach R, Truelove E, et al. Diagnostic criteria for temporomandibular disorders (DC/TMD) for clinical and research applications: recommendations of the international RDC/TMD consortium network* and orofacial pain special interest groupdagger. *J Oral Facial Pain Headache*. 2014;28(1):6–27. doi:10.11607/jop.1151

4. Wieckiewicz M, Boening K, Wiland P, Shiau YY, Paradowska-Stolarz A. Reported concepts for the treatment modalities and pain management of temporomandibular disorders. *J Headache Pain*. 2015;16(1):106. doi:10.1186/s10194-015-0586-5
5. Ohkubo M, Sano T, Otonari-Yamamoto M, et al. Magnetic resonance signal intensity from retrodiscal tissue related to joint effusion status and disc displacement in elderly patients with temporomandibular joint disorders. *Bull Tokyo Dent Coll*. 2009;50(2):55–62. doi:10.2209/tdpublication.50.55
6. Khawaja SN, Crow H, Mahmoud RF, Kartha K, Gonzalez Y. Is There an Association Between Temporomandibular Joint Effusion and Arthralgia? *J Oral Maxillofac Surg*. 2017;75(2):268–275. doi:10.1016/j.joms.2016.08.027
7. Mizuhashi F, Ogura I, Mizuhashi R, et al. Examination for the factors involving to joint effusion in patients with temporomandibular disorders using magnetic resonance imaging. *J Imaging*. 2023;9(5):101. doi:10.3390/jimaging9050101
8. Hosgor H. The relationship between temporomandibular joint effusion and pain in patients with internal derangement. *J Cranio-Maxillofacial Surg*. 2019;47(6):940–944. doi:10.1016/j.jcms.2019.03.010
9. Pinto GNS, Grossmann E, Iwaki Filho L, et al. Correlation between joint effusion and morphology of the articular disc within the temporomandibular joint as viewed in the sagittal plane in patients with chronic disc displacement with reduction: a retrospective analytical study from magnetic resonance imaging. *Cranio*. 2021;39(2):119–124. doi:10.1080/08869634.2019.1582166
10. Diaz Reverand S, Munoz Guerra M, Rodriguez Campo J, Escorial V, Cordero J. Correlation between joint effusion and clinical symptoms, magnetic resonance imaging and arthroscopic findings in patients with temporomandibular joint disease. *J Craniomaxillofac Surg*. 2020;48(12):1146–1151. doi:10.1016/j.jcms.2020.10.003
11. Guarda-Nardini L, De Almeida AM, Manfredini D. Arthrocentesis of the temporomandibular joint: systematic review and clinical implications of research findings. *J Oral Facial Pain Headache*. 2021;35(1):17–29. doi:10.11607/ofph.2606
12. Yilmaz D, Kamburoglu K. Comparison of the effectiveness of high resolution ultrasound with MRI in patients with temporomandibular joint disorders. *Dentomaxillofac Radiol*. 2019;48(5):20180349. doi:10.1259/dmfr.20180349
13. Talmaceanu D, Lenghel LM, Bolog N, et al. Imaging modalities for temporomandibular joint disorders: an update. *Clujul Med*. 2018;91(3):280–287. doi:10.15386/cjmed-970
14. Xiong X, Ye Z, Tang H, et al. MRI of temporomandibular joint disorders: recent advances and future directions. *J Magn Reson Imaging*. 2021;54(4):1039–1052. doi:10.1002/jmri.27338
15. Xu J, Wang D, Yang C, Wang F, Wang M. Reconstructed magnetic resonance image based effusion volume assessment for temporomandibular joint arthralgia. *J Oral Rehabil*. 2023;50(11):1202–1210. doi:10.1111/joor.13551
16. Ohrbach R, Larsson P, List T. The jaw functional limitation scale: development, reliability, and validity of 8-item and 20-item versions. *J Orofac Pain*. 2008;22(3):219–230.
17. Serdar CC, Cihan M, Yucel D, Serdar MA. Sample size, power and effect size revisited: simplified and practical approaches in pre-clinical, clinical and laboratory studies. *Biochem Med*. 2021;31(1):010502. doi:10.11613/BM.2021.010502
18. Zhang Q, Ye Z, Wu Y, et al. Nonlinear relationship between temporomandibular joint disc displacement distance and disc length: a magnetic resonance imaging analysis. *J Clin Med*. 2022;11(23):7160. doi:10.3390/jcm11237160
19. Bas B, Yilmaz N, Gokce E, Akan H. Ultrasound assessment of increased capsular width in temporomandibular joint internal derangements: relationship with joint pain and magnetic resonance grading of joint effusion. *Oral Surg*. 2011;112(1):112–117. doi:10.1016/j.tripleo.2011.02.020
20. Park HN, Kim KA, Koh KJ. Relationship between pain and effusion on magnetic resonance imaging in temporomandibular disorder patients. *Imaging Sci Dent*. 2014;44(4):293–299. doi:10.5624/isd.2014.44.4.293
21. Kikinis R, Pieper S, Vosburgh K. 3D Slicer: a platform for subject-specific image analysis, visualization, and clinical support. 2014; 3(19):277–289. doi:10.1007/978-1-4614-7657-3_19
22. Mandolini M, Brunzini A, Facco G, Mazzoli A, Forcellese A, Gigante A. Comparison of three 3D segmentation software tools for hip surgical planning. *Sensors*. 2022;22(14):5242. doi:10.3390/s22145242
23. Pinter C, Lasso A, Fichtinger G. Polymorph segmentation representation for medical image computing. *Comput Meth Prog Bio*. 2019;171:19–26. doi:10.1016/j.cmpb.2019.02.011
24. Xu L, He Y, Fan S, Cai B, Fang Z, Dai K. Validation of a Chinese version of the jaw functional limitation scale in relation to the diagnostic subgroup of temporomandibular disorders. *J Oral Rehabil*. 2020;47(1):1–8. doi:10.1111/joor.12868
25. Higuchi K, Chiba M, Sai Y, et al. Relationship between temporomandibular joint pain and magnetic resonance imaging findings in patients with temporomandibular joint disorders. *Int J Oral Maxillofac Surg*. 2020;49(2):230–236. doi:10.1016/j.ijom.2019.06.028
26. Yamamoto M, Sano T, Okano T. Magnetic resonance evidence of joint fluid with temporomandibular joint disorders. *J Comput Assist Tomogr*. 2003;27(5):694–698. doi:10.1097/00004728-200309000-00006
27. Ogura I, Mizuhashi F, Sugawara Y, Oohashi M, Sekiguchi H, Saegusa H. Characteristics of the patients with temporomandibular joint effusion on magnetic resonance imaging. *J Oral Maxil Radi*. 2019;7(2):30. doi:10.4103/jomr.jomr_20_19
28. Manfredini D, Basso D, Arboretti R, Guarda-Nardini L. Association between magnetic resonance signs of temporomandibular joint effusion and disk displacement. *Oral Surg*. 2009;107(2):266–271. doi:10.1016/j.tripleo.2008.03.033
29. Haley DP, Schiffman EL, Lindgren BR, Anderson Q, Andreasen K. The relationship between clinical and MRI findings in patients with unilateral temporomandibular joint pain. *J Am Dent Assoc*. 2001;132(4):476–481. doi:10.14219/jada.archive.2001.0210
30. Dan R, Li J, Xie T, et al. Impact of different types of temporomandibular disorders on jaw functional limitation and psychological distress in orthodontic patients. *J Oral Rehabil*. 2023;50(8):644–654. doi:10.1111/joor.13463
31. Thomas N, Harper DE, Aronovich S. Do signs of an effusion of the temporomandibular joint on magnetic resonance imaging correlate with signs and symptoms of temporomandibular joint disease? *Br J Oral Maxillofac Surg*. 2018;56(2):96–100. doi:10.1016/j.bjoms.2017.11.011
32. Almeida FT, Pacheco-Pereira C, Flores-Mir C, Le LH, Jaremko JL, Major PW. Diagnostic ultrasound assessment of temporomandibular joints: a systematic review and meta-analysis. *Dentomaxillofac Radiol*. 2019;48(2):20180144. doi:10.1259/dmfr.20180144
33. Talmaceanu D, Lenghel LM, Csutak C, et al. Diagnostic value of high-resolution ultrasound for the evaluation of capsular width in temporomandibular joint effusion. *Life*. 2022;12(4):1.
34. Girondi CM, de Castro Lopes SLP, Ogawa CM, Braz-Silva PH, Costa ALF. Texture analysis of temporomandibular joint disc changes associated with effusion using magnetic resonance images. *Dent J*. 2024;12(3). doi:10.3390/dj12030082
35. Taimeh D, Ni Riordain R, Fedele S, Leeson R. Patient-reported outcome measures used in temporomandibular disorders: a review of the literature. *J Oral Facial Pain Headache*. 2023;37(2):113–129. doi:10.11607/ofph.3264

36. Almoznino G, Zini A, Zakuto A, et al. Oral health-related quality of life in patients with temporomandibular disorders. *J Oral Facial Pain Headache*. 2015;29(3):231–241. doi:10.11607/ofph.1413
37. Ye C, Xiong X, Zhang Y, et al. Psychological profiles and their relevance with temporomandibular disorder symptoms in preorthodontic patients. *Pain Res Manag*. 2022;2022:1039393. doi:10.1155/2022/1039393

Journal of Pain Research

Dovepress

Publish your work in this journal

The Journal of Pain Research is an international, peer reviewed, open access, online journal that welcomes laboratory and clinical findings in the fields of pain research and the prevention and management of pain. Original research, reviews, symposium reports, hypothesis formation and commentaries are all considered for publication. The manuscript management system is completely online and includes a very quick and fair peer-review system, which is all easy to use. Visit <http://www.dovepress.com/testimonials.php> to read real quotes from published authors.

Submit your manuscript here: <https://www.dovepress.com/journal-of-pain-research-journal>