


# EOG and the En-Face Inner Segment/Outer Segment-Ellipsoid Complex Image in Multiple Evanescent White Dot Syndrome

Fubin Wang , Aijun Wang\*, Xiaoyan Leng, Lin Yong

Department of Ophthalmology, Shanghai Bright Eye Hospital, Shanghai, People's Republic of China

\*These authors contributed equally to this work

Correspondence: Fubin Wang, Shanghai Bright Eye Hospital, 899 Maotai Road, Changning District, Shanghai, 200336, People's Republic of China, Email wfb\_528@163.com

**Introduction:** This study presents a rare case of multiple evanescent white dot syndrome (MEWDS) with atypical electrooculogram (EOG) findings, as well as abnormal en-face images of minimum intensity projection (Min-IP) and the en-face inner segment/outer segment-ellipsoid complex.

**Methods:** A 25-year-old female patient presented with painless visual impairment and photopsia in her right eye for a duration of two days. Multimodal imaging was employed including color fundus photography (CFP), fundus autofluorescence (FAF), spectral-domain optical coherence tomography (SD-OCT), and optical coherence tomography angiography (OCTA), and en-face images of Min-IP and the en-face inner segment/outer segment-ellipsoid complex were performed.

**Results:** In the right eye, multifocal small white spots were observed surrounding the posterior pole and optic disc of retina with the granular appearance of the fovea. FAF displayed of hyperfluorescence. SD-OCT appearance of MEWDS demonstrated primarily disrupted ellipsoid zone (EZ), photoreceptor outer segments, and interdigitation zone (IZ) complex within the fovea. The en-face images of the inner segment/outer segment-ellipsoid complex and Min-IP exhibited hyperreflective spots in the right eye. In the left eye, interestingly, hyperreflective spots were also observed on the en-face image of the inner segment/outer segment-ellipsoid complex. EOG revealed an Arden ratio of 2.5 for the right eye, while the left eye exhibited an Arden ratio of 1.7.

**Conclusion:** The en-face image of the inner segment/outer segment-ellipsoid complex in MEWDS exhibits aberrant features and it is noteworthy that a similar alteration may occur in the fellow eye. Further investigation is required to explore the relationship between MEWDS and EOG. The en-face images of the inner segment/outer segment-ellipsoid complex and Min-IP may help to elucidate the pathogenesis of MEWDS.

**Keywords:** multiple evanescent white dot syndrome, EOG, inner segment/outer segment-ellipsoid complex, minimum intensity projection, multimodal imaging

## Introduction

Multiple evanescent white dot syndrome (MEWDS) is a unilateral inflammatory disorder characterized by the presence of multiple subretinal white dots extending from the posterior pole to the mid-periphery, which spontaneously resolve without leaving any scarring.<sup>1</sup> This study reports a rare case of MEWDS with aberrant supernormal response of electrooculogram (EOG) and abnormal en-face images of Minimum intensity projection (Min-IP) and the en-face inner segment/outer segment-ellipsoid complex.

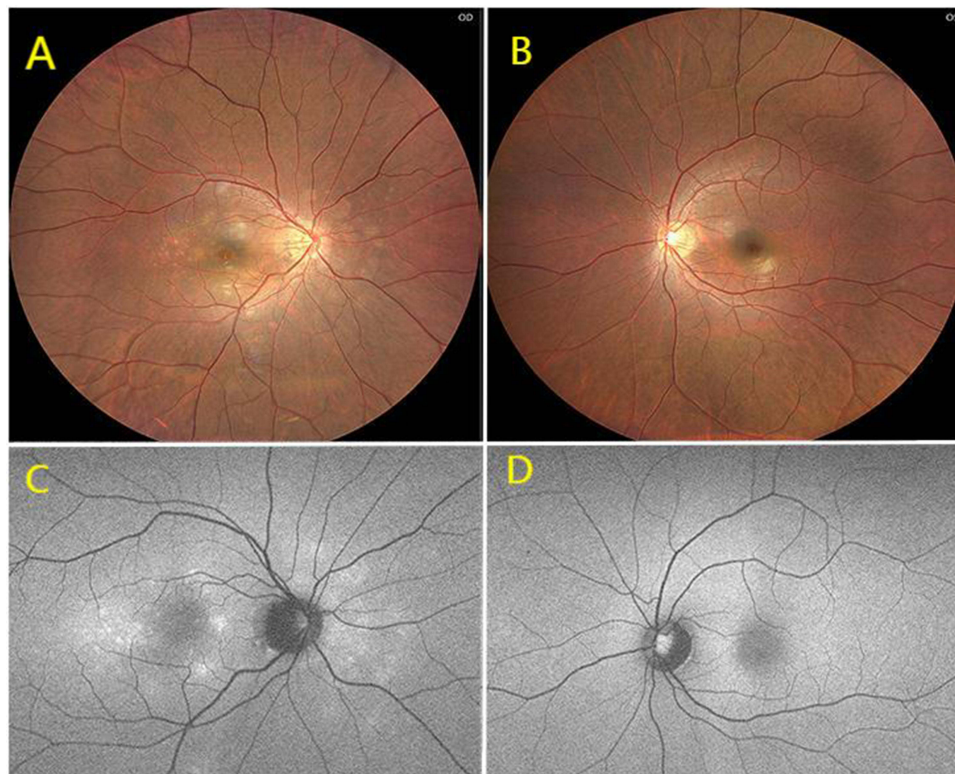
## Case Presentation

A 25-year-old female patient presented with painless visual impairment and photopsia in her right eye for a duration of two days. The ocular disease is reported to be preceded by a flu-like viral episode based on patient complaints, while no significant family history was reported.

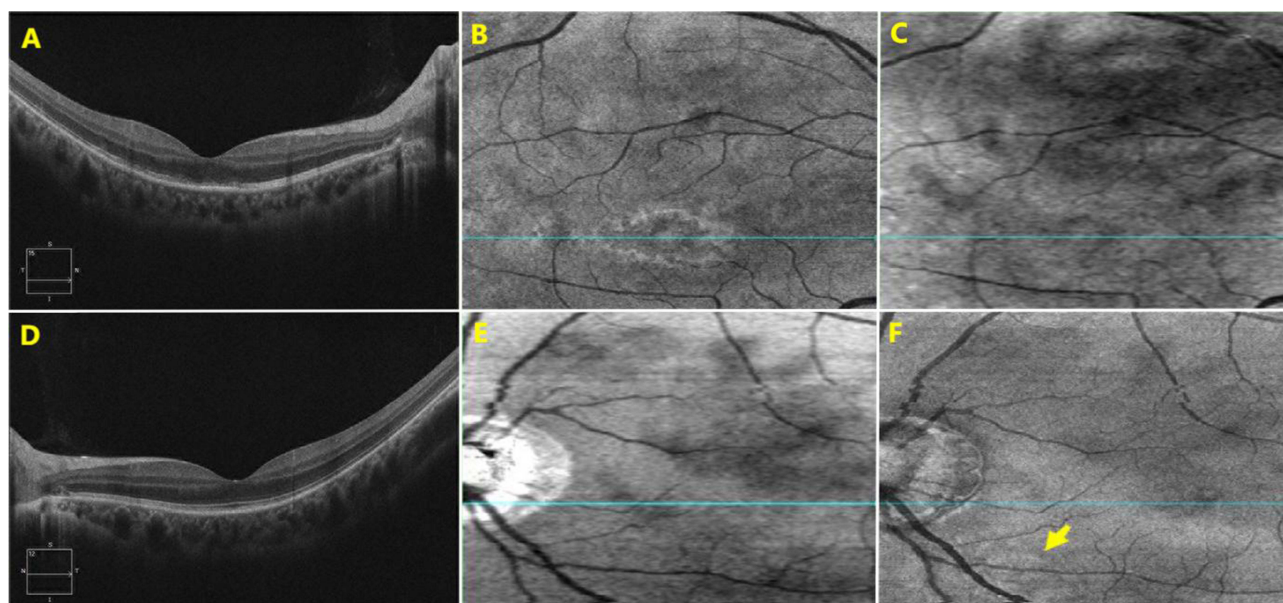
The decimal best-corrected visual acuity (BCVA) of the patient was 0.2 with a correction of  $-8.00$  DS =  $-1.00$  DC Ax $180^\circ$  in the right eye and 1.0 with  $-7.25$  DS =  $-1.00$  DC Ax $10^\circ$  in the left eye, both indicating high myopia. The intraocular pressure was measured as 16 mmHg in the right eye and 15 mmHg in the left eye. The anterior segments of both eyes appeared unremarkable upon slit-lamp examination, revealing no evidence of intraocular inflammation in the anterior chamber or vitreous cavity.

Multimodal imaging, EOG, and visual field (VF) techniques were employed for the evaluation of both eyes. In the right eye, on the color fundus photograph (CFP), multifocal small white spots were observed at the deep retinal layers surrounding the posterior pole and optic disc with the granular appearance of the fovea (Clarus 500, Carl Zeiss Meditec, Inc). Fundus autofluorescence (FAF) displayed hyperfluorescence on a wide-field picture (Panoramic ophthalmoscope, Daytona P200T). The left eye exhibited normal characteristics except for high myopia (Figure 1).

The spectral-domain optical coherence tomography (SD-OCT) and optical coherence tomography angiography (OCTA) were performed (Cirrus HD-OCT 5000, Germany). The en-face Min-IP and the en-face inner segment/outer segment-ellipsoid complex images are two novel algorithms (Default settings of Min-IP: upper: 90%ILM+10%RPE layer, lower: RPE layer; Default settings of the inner segment/outer segment-ellipsoid complex: upper: 39 $\mu$ m above the RPE layer, lower: 19 $\mu$ m above the RPE layer). The SD-OCT appearance of MEWDS demonstrated primarily disrupted ellipsoid zone (EZ), photoreceptor outer segments, and interdigitation zone (IZ) complex within the fovea in the right eye. Routine examination of OCTA did not reveal significant abnormalities; however, the en-face images of the inner segment/outer segment-ellipsoid complex and Min-IP exhibited hyperreflective spots in the right eye. Especially, in the left eye, no abnormalities were detected either CFP or FAF, but hyperreflective spots were observed on the en-face image of the inner segment/outer segment-ellipsoid complex; however, no such hyperreflective spots were found on Min-IP images (Figure 2).



**Figure 1** CFP showing multifocal small white spots surrounding the posterior pole and optic disc with the granular appearance of the fovea in the right eye (A) and the normal left eye (B). FAF showing hyperfluorescence spots in the right eye (C) and the normal left eye (D).



**Figure 2** In the right eye, SD-OCT showing disrupted ellipsoid zone, photoreceptor outer segments and interdigitation zone within the fovea (A); the en-face image of the inner segment/outer segment-ellipsoid complex showed hyperreflective spots (B) and Min-IP image exhibited hyperreflective spots (C). In the left eye, no abnormalities were detected either SD-OCT (D) or Min-IP image (E), but hyperreflective spots were observed on the en-face image of the inner segment/outer segment-ellipsoid complex (F, yellow arrow).

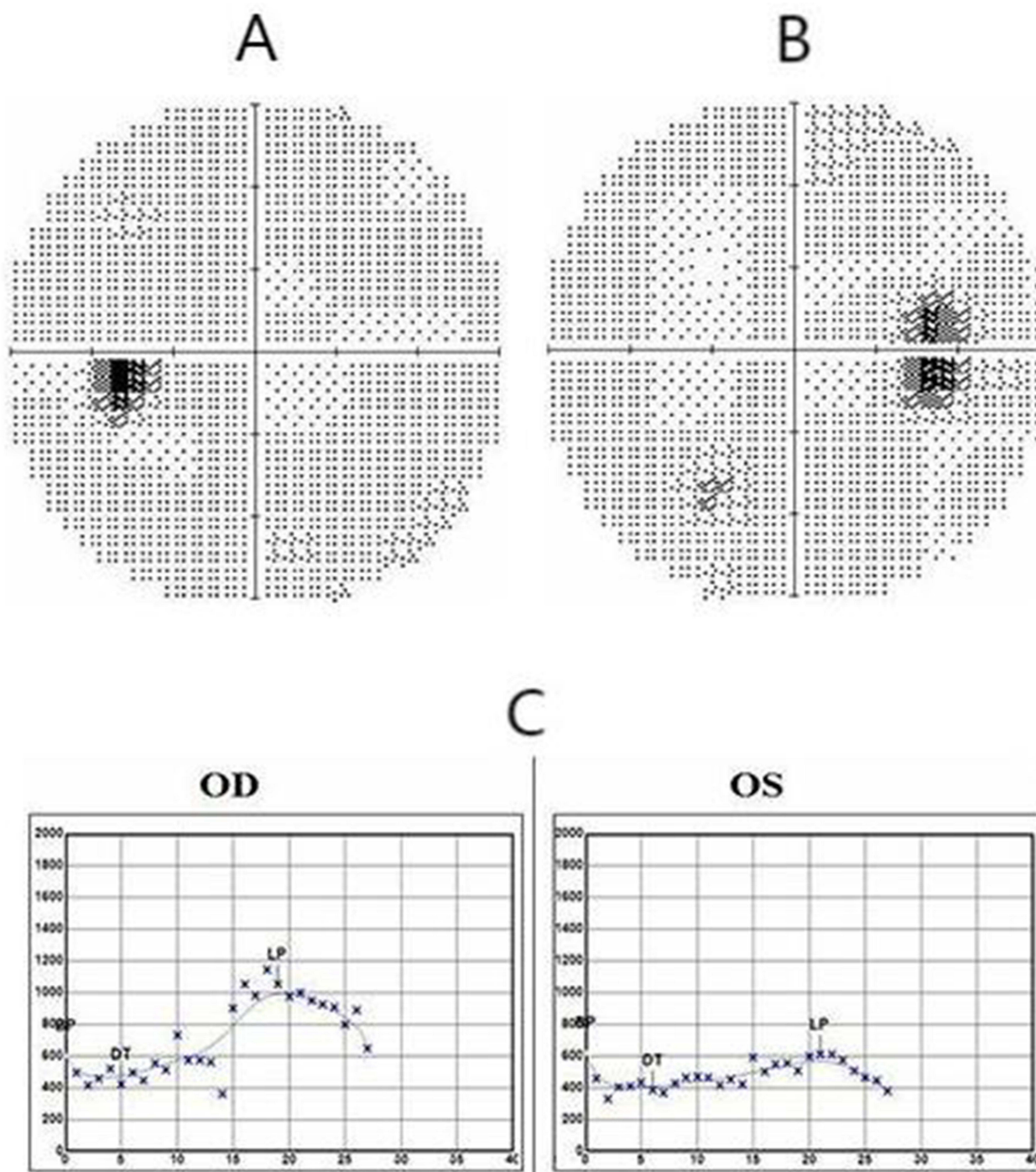
According to ISCEV criteria,<sup>2,3</sup> EOG examination with the pupils were dilated before testing (GT-2008V-1, Chongqing, China) revealed an Arden ratio of 2.5 for the right eye (Dark trough: 5.0 min/422.0 $\mu$ V; Light peak: 19.0 min/1051.1 $\mu$ V), while the left eye exhibited an Arden ratio of 1.7 (Dark trough: 7.0 min/351.5 $\mu$ V; Light peak: 21.0 min/611.7 $\mu$ V). Interestingly, the Arden ratio of the right eye was higher than that of the left eye. The Indocyanine green angiography (ICGA) and fluorescein angiography (FA) tests were not conducted due to specific reasons. The B-mode ultrasonography (SW-2100, Tianjin, China) of both eyes revealed no significant abnormalities. The physiological blind spot in the right eye, however, exhibited a slight enlargement (Humphrey field analyzer 860, Carl Zeiss Meditec, Inc) (Figure 3).

Low-dose prednisone was prescribed considering potential inflammatory etiology; nevertheless, the patient opted against initiating prednisone treatment. After a duration of 5 weeks, the patient exhibited no symptoms and the previously observed white spots completely resolved. BCVA demonstrated significant improvement, escalating from 0.2 to 1.0 in the right eye while maintaining a consistent value of 1.0 in the left eye. The patient exhibited features consistent with MEWDS, as indicated by multimodal imaging and the presence of acute outer retinopathy. Further systemic investigation was postponed due to the classic appearance and self-resolving nature of her retinal lesions.

## Discussion

The multiple evanescent white dot syndrome is an uncommon manifestation of posterior uveitis, characterized by the presence of numerous pale whitish dots observed in the posterior pole and midperiphery. The utilization of multimodal imaging has become the cornerstone for diagnosing MEWDS, representing a pivotal advancement in its diagnostic approach. Notably, impaired choroidal perfusion has been identified as a shared characteristic among choriocapillaritis entities, including MEWDS.<sup>4</sup> The weight of evidence is sufficiently compelling to consider MEWDS as a primary form of choriocapillaritis or inflammatory choriocapillaropathy.<sup>5</sup>

By employing a formalized methodology for developing classification criteria, the key criteria encompassed the presence of multifocal chorioretinal gray spots exhibiting foveal granularity, minimal to absent anterior chamber and vitreous inflammation, as well as either a distinctive FA displaying “wreath-like” hyperfluorescence or an optical coherence tomogram revealing lesions extending from the retinal pigment epithelium into the retina.<sup>6</sup> However, FA, traditionally employed in posterior uveitis, offers limited value-added potential and demonstrates restricted utility in the



**Figure 3** The visual field of left eye was normal (A) and the physiological blind spot in the right eye exhibited a slight enlargement (B). EOG revealed an Arden ratio of 2.5 for the right eye, while the left eye exhibited an Arden ratio of 1.7 (C).

context of MEWDS. Consequently, due to its invasive nature, FA is currently infrequently utilized as a clinical examination technique for MEWDS.<sup>5</sup> The use of FA to detect discrete hyperfluorescence in the affected areas may not be the most optimal approach for characterizing MEWDS. However, the combination of ICGA, FAF, and SD-OCT constitutes a robust triad that effectively complements clinical findings in the diagnosis of MEWDS.

ICGA findings reveal the presence of patchy hypofluorescent areas in the posterior pole, mid periphery, and surrounding the optic disc. The hypofluorescence of ICGA is particularly prominent during the late angiographic

phase, indicating choriocapillaris hypoperfusion rather than complete non-perfusion. This could also explain the usually benign course of the disease. ICGA, in conjunction with FAF, represents the foremost imaging modality for confirming the diagnosis of MEWDS and is also the optimal approach to delineate the extent of lesion progression and elucidate the severity of visual impairment. However, ICGA, which used to be the most valuable follow-up parameter, has now been effectively replaced by FAF due to its non-invasive nature. The lesions exactly co-localise with FAF hyper-autofluorescent areas and correspond to photoreceptor outer segment loss or damage on SD-OCT. Therefore, now ICGA is rarely useful to detect MEWDS as the origin of inflammatory choroidal neovascularization (CNV).<sup>7</sup> This highlights the practical value of FAF, especially when FA and ICG tests cannot be performed for some reason.

Previous studies have indicated that OCTA may not be optimal for the detection of MEWDS. The analysis of the retinal microvasculature, choriocapillaris, and choroid using optical coherence tomography angiography revealed no significant abnormalities in all patients.<sup>8</sup> Unlike acute posterior multifocal placoid pigment epitheliopathy (APMPPE), multifocal choroiditis (MFC), and serpiginous choroiditis (SC), which can be detected by OCTA, its limited ability in detecting choriocapillary drop out makes it unsuitable for most MEWDS cases.<sup>5</sup> However, this study revealed significant alterations in the en-face images of Min-IP and the inner/outer segment-ellipsoid complex in OCTA. The en-face image of the inner/outer segment-ellipsoid complex provides a comprehensive assessment of its overall condition. Some lesions that are not detectable using conventional OCTA may be visualized in the en-face images of Min-IP and/or the inner/outer segment-ellipsoid complex.

MEWDS is considered to be on the benign end of the primary choriocapillaritis entities, as it is usually reversible without treatment.<sup>9</sup> It is well established that EOG primarily reflects the function of photoreceptor and RPE complex, thus the abnormality observed in MEWDS can be comprehended. Interestingly, the observations recorded in this study revealed a disparity in the Arden ratio between the two eyes, with a significantly higher Arden ratio observed in the affected eye compared to the normal eye. It is postulated that this circumstance may be associated with compromised choroidal perfusion, choriocapillaritis, and involvement of the photoreceptor layer. However, the underlying reason for the significantly elevated Arden ratio in the affected eye remains unclear. Although it is commonly believed that MEWDS is a unilateral inflammatory disorder, in contrast to the original description of unilateral monophasic nature of MEWDS, recent large cohorts have shown simultaneous or sequential involvement of both eyes in up to 10% of patients and recurrences in up to 14%.<sup>10–12</sup>

The en-face image of the inner segment/outer segment-ellipsoid complex in MEWDS exhibits abnormalities and it is noteworthy that a similar alteration may manifest in the fellow eye. Further investigation is warranted to research the relationship between MEWDS and EOG. The utilization of the en-face images depicting the inner segment/outer segment-ellipsoid complex and Min-IP may help to elucidate the pathogenesis of MEWDS.

## Data Sharing Statement

The original contributions presented in the study are included in the article, and further inquiries can be directed to the corresponding author.

## Ethics Statement

Written informed consent was obtained from the individual for the publication of any potentially identifiable images or data included in this article. This study adhered to the tenets of the Declaration of Helsinki. Institutional review board approval (Approval number: Pr20240527001, Ethics Review Committee of Shanghai Bright Eye Hospital) and informed consent from patients was obtained.

## Disclosure

The author declares that the research was conducted in the absence of any commercial or financial relationships that could be construed as a potential conflict of interest.

## References

1. Mizuuchi K, Saito W, Namba K, Ishida S. Multiple evanescent white dot syndrome and panuveitis: a case report. *J Ophthalmic Inflamm Infect*. 2020;10(1):26. doi:10.1186/s12348-020-00221-3
2. Constable PA, Bach M, Frishman LJ, Jeffrey BG, Robson AG; The International Society for Clinical Electrophysiology of Vision. ISCEV Standard for clinical electro-oculography (2017 update). *Doc Ophthalmol*. 2017;134(1):1–9. doi:10.1007/s10633-017-9573-2
3. McCulloch DL, Bach M, Brigell M, et al. ISCEV guidelines for calibration and verification of stimuli and recording instruments (2023 update). *Doc Ophthalmol*. 2023;146(3):199–210. doi:10.1007/s10633-023-09932-z
4. Wang JC, Lains I, Sobrin L, Miller JB. Distinguishing white dot syndromes with patterns of choroidal Hypoperfusion on optical coherence tomography angiography. *Ophthalmic Surg Lasers Imaging Retina*. 2017;48(8):638–646. doi:10.3928/23258160-20170802-06
5. Papasavvas I, Mantovani A, Tugal-Tutkun I, Herbot CP. Multiple evanescent white dot syndrome (MEWDS): update on practical appraisal, diagnosis and clinicopathology; a review and an alternative comprehensive perspective. *J Ophthalmic Inflamm Infect*. 2021;11(1):45. doi:10.1186/s12348-021-00279-7
6. The Standardization of Uveitis Nomenclature (SUN) Working Group. Classification criteria for multiple evanescent white dot syndrome. *Am J Ophthalmol*. 2021;228:198–204. doi:10.1016/j.ajo.2021.03.050
7. Papadia M, Herbot CP. Idiopathic choroidal neovascularisation as the inaugural sign of multiple evanescent white dot syndrome. *Middle East Afr J Ophthalmol*. 2010;17(3):270–274. doi:10.4103/0974-9233.65490
8. Pichi F, Srivastava SK, Chexal S. En face optical coherence tomography and optical coherence tomography angiography of multiple evanescent white dot syndrome: new insights into pathogenesis. *Retina*. 2016;36(Suppl 1):S178–S188. doi:10.1097/IAE.0000000000001255
9. Herbot CP, Mantovani A, Tugal-Tutkun I, Papasavvas I. Classification of non-infectious and/or immune mediated choroiditis: a brief overview of the essentials. *Diagnostics*. 2021;11(6):939. doi:10.3390/diagnostics11060939
10. Marsiglia M, Gallego-Pinazo R, Cunha de Souza E. Expanded clinical spectrum of multiple evanescent white dot syndrome with multimodal imaging. *Retina*. 2016;36(1):64–74. doi:10.1097/IAE.0000000000000685
11. Bosello F, Westcott M, Casalino G, et al. Multiple evanescent white dot syndrome: clinical course and factors influencing visual acuity recovery. *Br J Ophthalmol*. 2020;317357. doi:10.1136/bjophthalmol-2020-317357
12. Ramakrishnan MS, Patel AP, Melles R, Vora RA. Multiple evanescent white dot syndrome: findings from a large northern California cohort. *Ophthalmol Retina*. 2021;5(9):850–854. doi:10.1016/j.oret.2020.11.016

International Medical Case Reports Journal

Dovepress

### Publish your work in this journal

The International Medical Case Reports Journal is an international, peer-reviewed open-access journal publishing original case reports from all medical specialties. Previously unpublished medical posters are also accepted relating to any area of clinical or preclinical science. Submissions should not normally exceed 2,000 words or 4 published pages including figures, diagrams and references. The manuscript management system is completely online and includes a very quick and fair peer-review system, which is all easy to use. Visit <http://www.dovepress.com/testimonials.php> to read real quotes from published authors.

Submit your manuscript here: <https://www.dovepress.com/international-medical-case-reports-journal-journal>