




Delayed Inflammatory Reaction to Hyaluronic Acid Dermal Filler Following Zoledronic Acid Administration: A Case Report

Nada J Alghamdi ^{1,*}, Serene R Almuhaideb ^{2,*}, Abdulmajeed S Alharbi ^{2,*},
Abdullah Ali N Aljalfan ^{1,*}, Khalid M Al-Husain ¹

¹Department of Dermatology, King Fahd University Hospital, Al Khobar, Saudi Arabia; ²College of Medicine, Imam Abdulrahman bin Faisal University, Dammam, Saudi Arabia

*These authors contributed equally to this work

Correspondence: Abdullah Ali N Aljalfan, Department of Dermatology, King Fahd University Hospital, P.O. Box 34246, Al Khobar, Saudi Arabia, Email A.jalfan7@hotmail.com

Abstract: Zoledronic acid is a bisphosphonate that can be administered intravenously and used to treat several bone disorders. It decreases bone resorption, thereby improving bone mineral density (BMD) and reducing fractures. The Food and Drug Administration (FDA) has approved zoledronic acid for the prevention and treatment of osteoporosis in postmenopausal females and males and for other conditions. Zoledronic acid is generally well tolerated, with most side effects being musculoskeletal or gastrointestinal. Cutaneous side effects include maculopapular rash and other mild skin reactions. Rare severe skin rashes, such as toxic epidermal necrolysis, have been reported. Here, we report the case of a 64-year-old female with a medical history of breast cancer status post-radical mastectomy and chemotherapy presenting with delayed hypersensitivity reaction to a hyaluronic acid dermal filler two days after receiving zoledronic acid intravenously given to maintain bone density, symptoms completely resolved with oral prednisolone 20 mg once daily and cetirizine 10 mg. Cases of delayed inflammatory reaction to hyaluronic acid soft tissue filler have previously been reported in patients who have received vaccination or those with viral infections. However, to our knowledge, there have been no reports of delayed inflammatory reactions to facial hyaluronic acid injections after zoledronic acid administration.

Keywords: delayed inflammation, filler, zoledronic acid, hyaluronic acid

Introduction

Zoledronic acid (ZA) is an intravenous bisphosphonate used to treat several benign and malignant bone disorders. It is mainly used for the treatment of primary and secondary osteoporosis.

Zoledronic acid decreases bone resorption by increasing osteoclast apoptosis.¹ The most common side effects of zoledronic acid are musculoskeletal pain, gastrointestinal symptoms, conjunctivitis, and nephrotoxicity, and, to a lesser extent, atypical fractures and jaw osteonecrosis.²

Rarely, cutaneous side effects can occur, and are mostly mild and self-limiting. These include maculopapular rashes, dermatitis, figurate erythema, erythema multiforme, vasculitis, and lip ulceration. Nonetheless, severe cutaneous adverse events such as toxic epidermal necrolysis may occur.^{3,4} Hyaluronic acid soft tissue fillers are non-permanent and non-invasive aesthetic procedure. They have become one of the most prevalent non-surgical treatments due to their excellent safety profile and delivering significant results in facial rejuvenation and high patient satisfaction. Immune reactions to hyaluronic acid dermal fillers are rare and can be early-onset or late-onset.⁵

To the best of our knowledge, this is the first report of a hypersensitivity reaction to a hyaluronic acid dermal filler following the administration of zoledronic acid to a 64-year-old female patient.

Case Presentation

A 64-year-old female presented to the outpatient clinic of our hospital with a two-day history of localized and progressively increasing firm swelling on her face in the jaw and cheeks at sites of previously injected fillers (Figure 1). There was no pain, erythema, itchiness, shortness of breath, visible erythema, or other systemic involvement. Two days prior to onset, she received her first-ever dose of zoledronic acid 5 mg intravenously. A further history of the patient ruled out any previous allergies or angioedema, and she had not been taking any medications and had no recent viral illness, dental or other potential bacterial infections, recent vaccination, or history of trauma. One year later, she was injected with 1 mL of hyaluronic acid filler Juvederm Voluma into the lateral cheek and 1 mL of Juvéderm VOLUX into the chin area with good results and no subsequent complications.

Her medical history was significant for stage three breast cancer status after left radical mastectomy nine years ago, followed by chemotherapy and trastuzumab therapy for one year. She is currently receiving tamoxifen 10 mg once daily. The oncologist advised her to administer zoledronic acid to maintain bone density. The patient was diagnosed with a delayed inflammatory reaction to the HA filler and treated with oral prednisolone 20 mg once daily and cetirizine 10 mg for three days, with significant improvement. After two weeks of follow-up, the symptoms entirely resolved without the need to dissolve the filler. Furthermore, the patient was educated to replace zoledronic acid with other alternative medications, and she was reassured to retreat with fillers if she wanted. Subsequently, her oncologist changed her medication from zoledronic acid to denosumab, and 60 mg was administered subcutaneously every six months.

Discussion

Zoledronic acid is a bisphosphonate and antiresorptive medication approved by the Food and Drug Administration (FDA) for the prevention and treatment of osteoporosis in postmenopausal females, osteoporosis in males, Paget's disease of the bone, hypercalcemia of malignancy, multiple myeloma, and solid tumor bone metastasis.¹ Common side effects of zoledronic acid are musculoskeletal pain, gastrointestinal symptoms, conjunctivitis, and nephrotoxicity, and lesser common side effects are atypical fractures and jaw osteonecrosis.²

Zoledronic acid has very limited cutaneous adverse effects, and reported side effects from previous studies and post-marketing after prolonged treatment with zoledronic acid are pruritus, maculopapular rash, and infusion site reaction.³

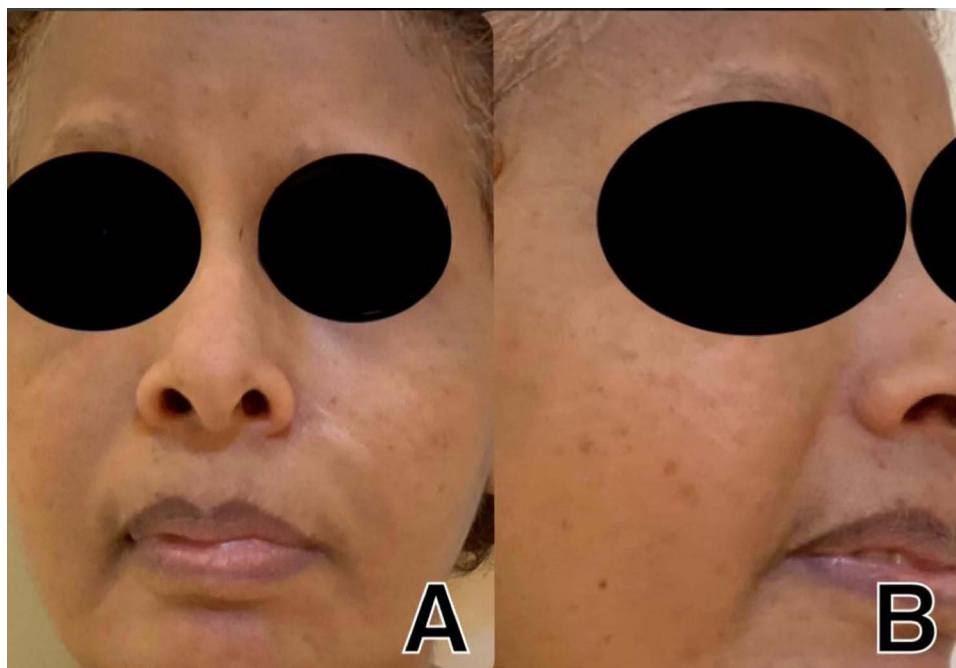


Figure 1 (A and B) Induration and edema at sites of dermal filler injection most prominent in the lateral cheek area.

Other rare side effects are dermatitis, figurate erythema, erythema multiforme, vasculitis, and lip ulceration.⁴ Cases of Stevens-Johnson syndrome and toxic epidermal necrolysis are very rare (1/10,000) and have been reported for all of the bisphosphonates.⁶ Zoledronic acid-induced dermatomyositis has been reported in a small number of patients who have been treated with zoledronic acid for osteoporosis.^{7,8} Baboon syndrome, a rare maculopapular rash secondary to a rare type IV hypersensitivity reaction associated with zoledronic acid, was reported in one patient.⁹

In 2021, according to the International Society for Aesthetic Surgery (ISAPS), hyaluronic acid dermal filler was ranked as the second most common noninvasive aesthetic procedure performed internationally, with a 30.3% notable increase.¹⁰ Delayed inflammatory reactions have been reported following hyaluronic acid dermal injection but are uncommon. Delayed inflammatory reactions, including induration, edema, painful nodules, and discoloration, may occur weeks or months after dermal injection. The pathogenesis is still poorly understood, but has been related to viral infection and vaccination, which triggers an immune response. Other immunological triggers have been proposed (eg, antibodies against HA, residual bacterial proteins transmitted during the filler procedure, low-quality products, bacterial infections from sinusitis, or dental procedures). Turkmani et al reported multiple cases of hypersensitivity reactions to hyaluronic acid dermal fillers after a flu-like illness.¹¹ Similarly, during the COVID-19 pandemic a few cases of delayed inflammatory reactions were reported after COVID-19 vaccination.^{5,12} Most delayed inflammatory reactions to dermal fillers after COVID-19 vaccination are self-limiting and resolve within a few days to weeks. In mild cases, when a nodule is present, with a small size (less than 0.5 cm), and without erythema and bothersome symptoms, a watchful waiting approach is recommended. Intervention is necessary if painful and tender nodules with edema and erythema do not resolve with a watchful waiting approach. The possible etiology of filler abnormalities is usually inflammatory; however, the possibility of an underlying infectious process must be ruled out. Management options for delayed inflammatory reactions to dermal fillers, including antihistamines, systemic steroids, and intralesional steroids, alone or in combination with 5-Fluorouracil, have all shown significant effects. Antibiotics can be added when the symptoms suggest infection, and intralesional hyaluronidase (10 units of hyaluronidase per 0.1 mL of soft tissue filler) administered for more intense reactions. Another treatment option that has shown promising results for hyaluronic acid dermal filler following COVID-19 vaccination is the use of oral angiotensin-converting enzyme inhibitors.^{5,13}

To the best of our knowledge, this is the first case of a delayed hypersensitivity response to zoledronic acid in a patient who had previously received hyaluronic acid dermal filler. The mechanism is unknown, but data suggest that systemic mechanisms in addition to local irritation, such as the direct effect of zoledronic acid on fibroblasts and epithelial cells, contribute to pathogenesis.

Some patients with delayed hypersensitivity have been treated with oral glucocorticoids. However, others had mild reactions and their symptoms resolved without any intervention.¹² Because this is the first case of this kind, potential limitations should be considered, such as the single-case nature and the inability to establish causality and lastly the poor understanding of the mechanism.

Conclusion

Zoledronic acid is well tolerated in the treatment of osteoporosis and other conditions. It has limited cutaneous side effects, generally mild, self-limiting, and rarely severe. Similarly, hyaluronic acid dermal filler is safe when administered by an expert, a well-trained injector. Here, we report the first hyaluronic acid-delayed inflammatory reaction to zoledronic acid. It will be informative for dermatologists and physicians who practice cosmetology to know that zoledronic acid can potentially trigger a delayed inflammatory response to hyaluronic acid dermal filler, and this case may help identify other medications or vaccines that can trigger a filler reaction.

Statement of Ethics and Informed Consent

Written informed consent for publication of this case report including photography and medical data was obtained and signed by the patient's parents. Institutional ethical approval was not required to publish this case report.

Funding

The authors report no source of funding to disclose.

Disclosure

The authors report no conflicts of interest to declare.

References

1. Cremers SC, Pillai G, Papapoulos SE. Pharmacokinetics/pharmacodynamics of bisphosphonates: use for optimisation of intermittent therapy for osteoporosis. *Clin Pharmacokinet*. 2005;44(6):551–570. doi:10.2165/00003088-200544060-00001
2. Dhillon S. Zoledronic acid (Reclast[®], Aclasta[®]): a review in osteoporosis. *Drugs*. 2016;76(17):1683–1697. doi:10.1007/s40265-016-0662-4
3. Nassar K, Janani S. Diffuse adverse cutaneous reactions induced by zoledronic acid administration: a case report: eruptions cutanées diffuses induites par l'administration de l'acide zolédronique. *Osteoporos Int*. 2021;32(12):2583–2586. doi:10.1007/s00198-021-06021-2
4. Andreadis D, Mauroudis S, Pouloupoulos A, et al. Lip ulceration associated with intravenous administration of zoledronic acid: report of a case. *Head Neck Pathol*. 2012;6(2):275–278. doi:10.1007/s12105-011-0313-8
5. Michon A. Hyaluronic acid soft tissue filler delayed inflammatory reaction following COVID-19 vaccination - A case report. *J Cosmet Dermatol*. 2021;20(9):2684–2690. doi:10.1111/jocd.14312
6. Rizzoli R, Reginster JY, Boonen S, et al. Adverse reactions and drug-drug interactions in the management of women with postmenopausal osteoporosis. *Calcif Tissue Int*. 2011;89(2):91–104. doi:10.1007/s00223-011-9499-8
7. Tong PL, Yu LL, Chan JJ. Drug-induced dermatomyositis after zoledronic acid. *Australas J Dermatol*. 2012;53(4):e73–e75. doi:10.1111/j.1440-0960.2011.00771.x
8. Apalla Z, Tzellos T, Lallas A, et al. Possible zoledronic acid-induced dermatomyositis. *Clin Exp Dermatol*. 2012;37(3):309–311. doi:10.1111/j.1365-2230.2011.04198.x
9. Cohen PR. Zoledronic acid-associated symmetrical drug-related intertriginous and flexural exanthema (SDRIFE): report of baboon syndrome in a woman with recurrent metastatic breast cancer after receiving zoledronic acid. *Dermatol Online J*. 2015;21(8):13030/qt5kk0g864.
10. International Society of Aesthetic Plastic Surgery. ISAPS International survey on Aesthetic/Cosmetic Procedures Performed in 2021. Number of worldwide non-surgical procedures. Available from: https://isaps.org/media/vdpdanke/isaps-global-survey_2021.pdf. Accessed June 7, 2024.
11. Turkmani MG, De Boule K, Philipp-Dormston WG. Delayed hypersensitivity reaction to hyaluronic acid dermal filler following influenza-like illness. *Clin Cosmet Invest Dermatol*. 2019;12:277–283. doi:10.2147/CCID.S198081
12. Osmond A, Kenny B. Reaction to dermal filler following COVID-19 vaccination. *J Cosmet Dermatol*. 2021;20(12):3751–3752. doi:10.1111/jocd.14566
13. López Pérez V. COVID y rellenos faciales ¿realmente debemos preocuparnos? [COVID-19 and dermal fillers: should we really be concerned?] *Actas Dermosifiliogr*. 2022;113(9):888–894. Spanish. doi:10.1016/j.ad.2022.05.019

Clinical, Cosmetic and Investigational Dermatology

Dovepress

Publish your work in this journal

Clinical, Cosmetic and Investigational Dermatology is an international, peer-reviewed, open access, online journal that focuses on the latest clinical and experimental research in all aspects of skin disease and cosmetic interventions. This journal is indexed on CAS. The manuscript management system is completely online and includes a very quick and fair peer-review system, which is all easy to use. Visit <http://www.dovepress.com/testimonials.php> to read real quotes from published authors.

Submit your manuscript here: <https://www.dovepress.com/clinical-cosmetic-and-investigational-dermatology-journal>