

# Recalcitrant Reactive Perforating Collagenosis Successfully Treated with Dupilumab: A Case Report

Jiecheng Li , Cheng Zhou

Department of Dermatology, Peking University People's Hospital, Beijing, People's Republic of China

Correspondence: Cheng Zhou, Department of Dermatology, Peking University People's hospital, Beijing, People's Republic of China, Email [chengzhou@live.cn](mailto:chengzhou@live.cn)

**Abstract:** Reactive perforating collagenosis (RPC) is the most common form of the perforating dermatoses, which include RPC, elastosis perforans serpiginosa (EPS), perforating folliculitis (PF), and Kyrle disease (KD). In RPC, altered collagen of the dermis is extruded through the epidermis, which can be misdiagnosed as other skin diseases, such as vasculitis or prurigo nodularis. RPC is associated with a number of conditions, including diabetes mellitus, hepatitis, and renal failure, and thus the management of the coexisting diseases is important. There is currently no standardized and effective treatment method for RPC. Here, we report a patient with RPC who was resistant to topical corticosteroids, oral loratadine, and thalidomide, and responded well to dupilumab without significant side effects.

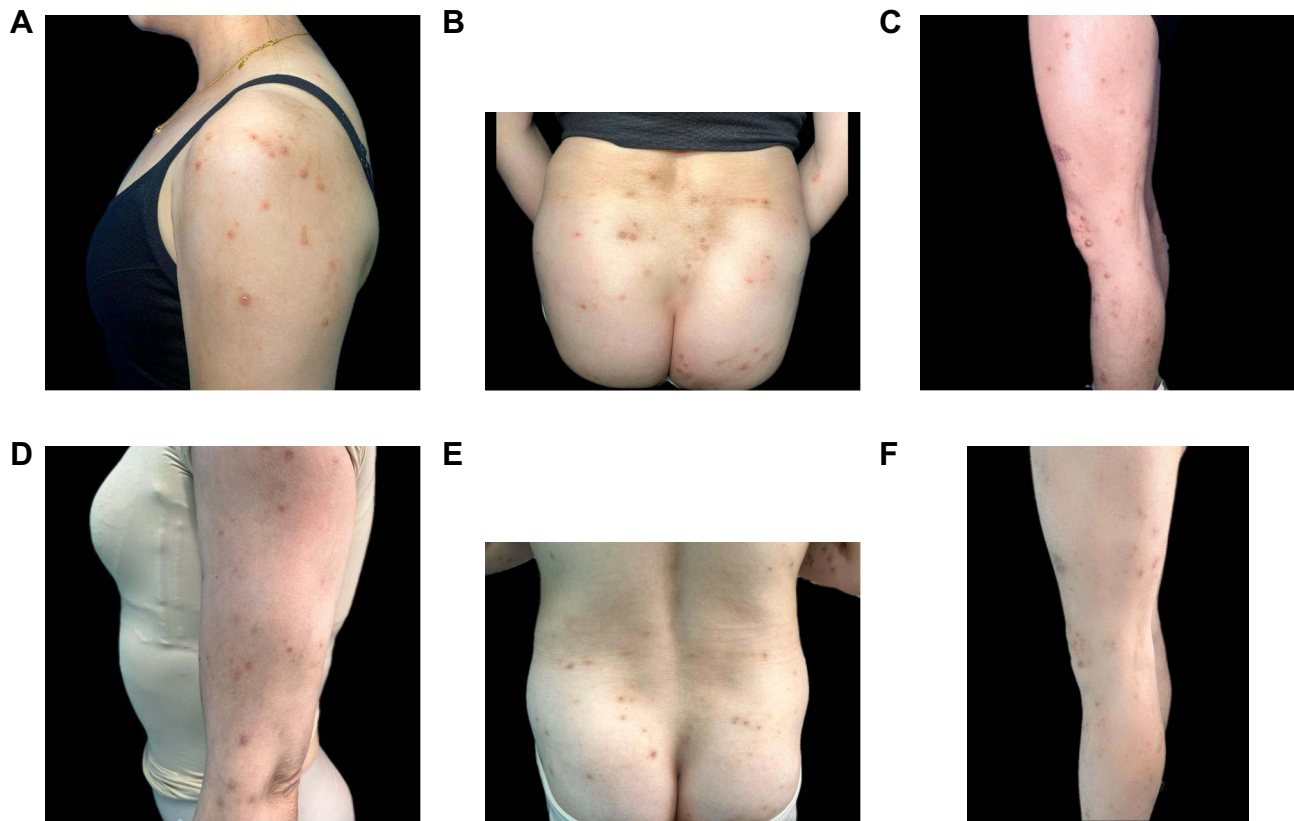
**Keywords:** reactive perforating collagenosis, dupilumab, perforating dermatosis, biologic drug

## Introduction

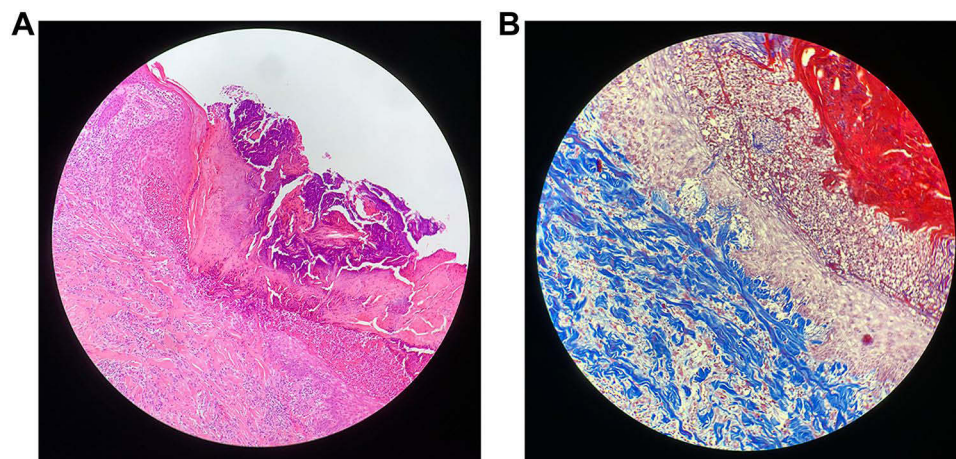
Reactive perforating collagenosis (RPC) is the most common form of the perforating dermatoses, which include RPC, elastosis perforans serpiginosa (EPS), perforating folliculitis (PF), and Kyrle disease (KD).<sup>1</sup> In RPC, altered collagen of the dermis is extruded through the epidermis, which can be misdiagnosed as other skin diseases, such as vasculitis. RPC is associated with a number of conditions, including diabetes mellitus, hepatitis, and renal failure, and thus the management of the coexisting diseases is important.<sup>2</sup> The lesion erupts but there are no clear guidelines for treatment. Here, we report a patient with RPC who was resistant to topical corticosteroids, oral loratadine, and thalidomide, and responded well to dupilumab without significant side effects.

## Case Report

A 39-year-old female presented to our department with multiple well-defined keratotic papules and nodules with excoriations and crusts, on the trunk and limbs, which had appeared 6 months earlier without any specific trigger. Before presentation, she had been diagnosed with vasculitis at a local hospital and treated with topical corticosteroids, oral loratadine, and thalidomide, but with no response. Physical examination revealed brown keratotic papules with an erythematous border, crateriform appearance, and a central necrotic crust (Figure 1A–C). Laboratory tests revealed mildly elevated transaminase, which was related to her past history of hepatitis B infection, while a complete blood count, renal function, and thyroid function were normal. Antinuclear antibody and extractable nuclear antigen (ENA) panels were all negative. Skin biopsy and dermatopathological examination showed prominent epidermal hyperplasia with broad channels and invagination, with vertical extrusion of degenerated basophilic collagen bundles (Figure 2G). Masson's trichrome stain verified the transepidermal elimination of blue-stained collagen fibers (Figure 2H). The clinical and histopathological manifestations suggested the diagnosis of RPC. Considering that she was resistant to routine treatment and the risk of hepatitis B infection, she was treated with



**Figure 1 (A–C)** At the initial visit, excessive keratinization, umbilical papules, well-defined keratotic papules, nodules, and small vesiculation were observed on the trunk and limbs. **(D–F)** After nearly 12 weeks of subcutaneous dupilumab treatment, the lesions were flattened and showed post-inflammatory hyperpigmentation.



**Figure 2 (A)** Biopsy examination (H&E stain) revealed a well-circumscribed area of necrosis filled with a keratotic plug and penetrating collagen fibers. There was a perivascular infiltration of lymphocytes and eosinophils in the superficial dermis. **(B)** Masson's trichrome stain showed transepidermal elimination of blue-stained collagen fibers.

dupilumab, at an initial dosage of 600 mg and then 300 mg fortnightly. Three days after treatment, the pruritus improved significantly, with the numeric rating scale score dramatically decreasing from 9 to 1. After 12 weeks of treatment, the skin lesions had subsided, with no adverse effects reported ([Figure 1D–F](#)).

## Discussion

RPC was first reported by Mehregan et al in 1967.<sup>3</sup> There are two types of RPC, the hereditary form and the acquired form, which often coexist with diabetes, chronic renal failure, and other systemic diseases. The patient often presents with multiple diffusely distributed well-defined keratotic papules, which are most likely to occur on the trunk, limbs, and face, after scratching or irritating the skin.<sup>4</sup> The skin lesion biopsy exhibits a clearly demarcated area of necrosis, filled with lymphocytic infiltration, parakeratotic cells, and keratotic plugs. In the dermis, sparse fiber bundles are seen traversing the epidermis. Elastic fiber staining can show blue-stained collagen fibers within the epidermal channels.<sup>5</sup>

The pathogenesis of RPC is not fully understood. Wagner and Sachse found that the accompanying pruritus is a considerable pathogenic factor, which can lead to persistent scratching and cause further damage to the skin.<sup>6</sup> Several pathological hypotheses have been proposed, including abnormal collagen metabolism, immune dysfunction, genetic variations, and chronic venous insufficiency.<sup>7</sup> Liu et al found enhanced dermal infiltration of CD3<sup>+</sup> T-cells with a predominance of Th2 cells.<sup>8</sup> In addition, the cytokines interleukin (IL)-4 and IL-13 were also significantly upregulated in RPC.<sup>8</sup>

There is currently no standardized and effective treatment method for RPC. The reported treatment options in the relevant literature include glucocorticoids, retinoids, vitamin D<sub>3</sub> analogues, ultraviolet radiation, allopurinol, thalidomide, systemic antibiotics, and antihistamines. However, the treatment of RPC is frequently unsatisfactory.

Dupilumab is a human monoclonal antibody which targets the IL-4 receptor- $\alpha$  subunit of IL-4 and IL-13 receptors,<sup>9</sup> thus inhibiting the signaling of both cytokines. Dupilumab improves itching in patients with atopic dermatitis, prurigo nodularis, allergic contact dermatitis, bullous pemphigoid, and other pruritic disorders.<sup>10</sup> Based on existing reports in the literature, the treatment of RPC mainly targets the comorbidities and control of itching.<sup>11</sup> Dupilumab may represent a potential treatment option for RPC patients because of the blockade of IL-4 and IL-13 signaling pathways and Th2-type inflammation,<sup>8</sup> and could be considered as a substitute for systemic steroids or immunosuppressants. The patient's rapid response to dupilumab may help to illustrate the probable pathogenic agent and the unclear pathogenesis of RPC.

## Abbreviations

RPC, reactive perforating collagenosis; EPS, elastosis perforans serpiginosa; PF, perforating folliculitis; KD, Kyrle disease; ENA, extractable nuclear antigen; IL, interleukin.

## Declaration of Patient Consent

The patient provided written informed consent to publish not only the details of the case but also any accompanying images. The informed consent form clearly states that the institution has agreed to publish relevant information about this case.

## Acknowledgments

We would like to thank the patient and physicians for participating in our study.

## Disclosure

The authors report no conflicts of interest in this work.

## References

1. Rapini RP, Herbert AA, Drucker CR. Acquired perforating dermatosis. Evidence for combined transepidermal elimination of both collagen and elastic fibers. *Arch Dermatol*. 1989;125(8):1074–1078. PMID: 2757403. doi:10.1001/archderm.125.8.1074
2. Kim RH, Kwa M, Adams S, Meehan SA, Stein JA. Giant acquired reactive perforating collagenosis in a patient with diabetes mellitus and metastatic breast carcinoma. *JAAD Case Rep*. 2016;2(1):22–24. PMID: 27051818; PMCID: PMC4809472. doi:10.1016/j.jcdr.2015.11.013
3. Faver IR, Daoud MS, Su WP. Acquired reactive perforating collagenosis. Report of six cases and review of the literature. *J Am Acad Dermatol*. 1994;30(4):575–580. PMID: 8157784. doi:10.1016/s0190-9622(94)70065-6
4. de Rezende LN, Nuñez MG, Clavery TG, et al. Elastosis perforans serpiginosa. *Indian Dermatol Online J*. 2014;5(2):236–237. PMID: 24860779; PMCID: PMC4030372. doi:10.4103/2229-5178.131156

5. Kawakami T, Akiyama M, Ishida-Yamamoto A, et al. Clinical practice guide for the treatment of perforating dermatosis. *J Dermatol.* 2020;47(12):1374–1382. PMID: 33094871. doi:10.1111/1346-8138.15647
6. Wagner G, Sachse MM. Acquired reactive perforating dermatosis. *J Dtsch Dermatol Ges.* 2013. 11(8):723–9, 723–30. English, German. PMID: 23718268. doi:10.1111/ddg.12131
7. Bk P, Asati D, Panwar H, Joshi D. Unraveling the enigma of perforating itches: a comprehensive report of reactive perforating collagenosis in three patients. *Cureus.* 2023;15(9):e44531. PMID: 37790021; PMCID: PMC10544657. doi:10.7759/cureus.44531
8. Liu B, Wu Y, Wu X, Zhong X, Xue R, Zhang Z. Dupilumab improve acquired reactive perforating collagenosis characterized by type 2 inflammation. *Front Immunol.* 2023;14:1240262. PMID: 37638036; PMCID: PMC10449391. doi:10.3389/fimmu.2023.1240262
9. Erickson S, Heul AV, Kim BS. New and emerging treatments for inflammatory itch. *Ann Allergy Asthma Immunol.* 2021;126(1):13–20. PMID: 32497711. doi:10.1016/j.anai.2020.05.028
10. Ying Y, Shuang C, Zhen-Ying Z. Dupilumab may be an alternative option in the treatment of acquired reactive perforating collagenosis combined with AD. *Immun Inflamm Dis.* 2022;10(3):e574. PMID: 34953055; PMCID: PMC8926492. doi:10.1002/iid3.574
11. Karpouzis A, Giatromanolaki A, Sivridis E, Kouskoukis C. Acquired reactive perforating collagenosis: current status. *J Dermatol.* 2010;37(7):585–592. PMID: 20629824. doi:10.1111/j.1346-8138.2010.00918.x

### Clinical, Cosmetic and Investigational Dermatology

Dovepress

### Publish your work in this journal

Clinical, Cosmetic and Investigational Dermatology is an international, peer-reviewed, open access, online journal that focuses on the latest clinical and experimental research in all aspects of skin disease and cosmetic interventions. This journal is indexed on CAS. The manuscript management system is completely online and includes a very quick and fair peer-review system, which is all easy to use. Visit <http://www.dovepress.com/testimonials.php> to read real quotes from published authors.

Submit your manuscript here: <https://www.dovepress.com/clinical-cosmetic-and-investigational-dermatology-journal>