

# Aberrant Splicing of *COL4A5* Intronic Variant Contribute to the Pathogenesis of X-Linked Alport Syndrome: A Case Series

Yang Li<sup>1</sup>, Xue Yan<sup>2</sup>, Zhen Luo<sup>1</sup>, Xianxian Fu<sup>1</sup>, Zhongju Li<sup>1</sup>, Qiuzhu Xu<sup>3</sup>, Juanjuan Chen<sup>1</sup>, Jingmin Yang<sup>2,4,5</sup>, Daru Lu<sup>4,5</sup>

<sup>1</sup>Department of Nephropathy, Affiliated Haikou Hospital of Xiangya Medical College, Central South University, Hainan, People's Republic of China; <sup>2</sup>Department of Medicine, Shanghai WeHealth Biomedical Technology Co., Ltd., Shanghai, People's Republic of China; <sup>3</sup>Department of Central Supply Service Department, Haikou Orthopedic and Diabetes Hospital, Hainan, People's Republic of China; <sup>4</sup>NHC Key Laboratory of Birth Defects and Reproductive Health (Chongqing Key Laboratory of Birth Defects and Reproductive Health, Chongqing Population and Family Planning, Science and Technology Research Institute), Chongqing, People's Republic of China; <sup>5</sup>State Key Laboratory of Genetic Engineering and MOE Engineering Research Center of Gene Technology, School of Life Sciences, Fudan University, Shanghai, People's Republic of China

Correspondence: Jingmin Yang; Daru Lu, Email [jingmin.yang@we-health.vip](mailto:jingmin.yang@we-health.vip); Email [drlu@fudan.edu.cn](mailto:drlu@fudan.edu.cn)

**Introduction:** X-linked Alport syndrome (XLAS) is caused by pathogenic variants in *COL4A5* which lead to abnormalities of the glomerular basement membrane (GBM) structural and is characterized by progressive kidney disease, hearing loss, and ocular abnormalities. The aim of this study was to identify gene mutations in a Chinese family with XLAS by whole-exome sequencing (WES) and verified the pathogenicity of the mutation in vitro experiments.

**Case Presentation:** A five-generation pedigree with a total of 49 family members originating from Hainan province of China was investigated in this study. The proband was a 23-year-old male who developed microscopic hematuria, proteinuria and end-stage kidney disease (ESKD) at age 17. WES identified a novel splicing mutation c.321+5G>A of *COL4A5*, which cause exon skip. Further co-segregation analysis confirmed that this mutation exists in relatives who had renal abnormalities using Sanger sequencing. According to American College of Medical Genetics and Genomics guidelines (ACMG), the mutation was determined to be of uncertain significance (VUS). In vitro splicing experiments have shown that the *COL4A5* variant induces aberrant mRNA splicing and transcript deletion.

**Conclusion:** We identified a novel intronic *COL4A5* pathogenic mutation (c.321+5G>A) in a Chinese XLAS family and described the phenotypes of affected relatives. This study expands the mutation spectrum of *COL4A5* gene in XLAS and demonstrates the importance of gene screening for AS.

**Keywords:** Alport syndrome, *COL4A5*, whole exome sequencing, mRNA splicing, case series

## Introduction

Alport syndrome (AS), also known as hereditary progressive nephritis, is an inherited glomerulopathy characterized by hematuria, proteinuria, and progressive kidney failure, with some patients having extra-renal manifestations such as sensorineural deafness and ocular abnormalities.<sup>1</sup> The abnormalities of the glomerular basement membrane (GBM) structural caused by mutations in *COL4A5* on chromosome X, which encodes type IV collagen  $\alpha 5$  chain and causes X-linked AS (XLAS).<sup>2</sup> There are three inheritance patterns of AS, the X-linked genetic phenotype resulting from mutations in *COL4A5* gene is the most common, accounting for approximately 85% of cases,<sup>3</sup> followed by autosomal recessive<sup>4</sup> and autosomal dominant.<sup>5</sup>

Over 90% of male<sup>6</sup> and 12% of female XLAS patients are reported to develop end-stage kidney disease (ESKD) by age 40, respectively. Genotypic phenotypes exhibit a high correlation in males XLAS.<sup>6</sup> Males exhibit proteinuria and hematuria in early childhood compared to female patients with XLAS, and the disease develops to ESKD by 25 to 3.<sup>7</sup> The severity of male patients with early onset to ESKD correlated with the type of variants, patients with nonsense

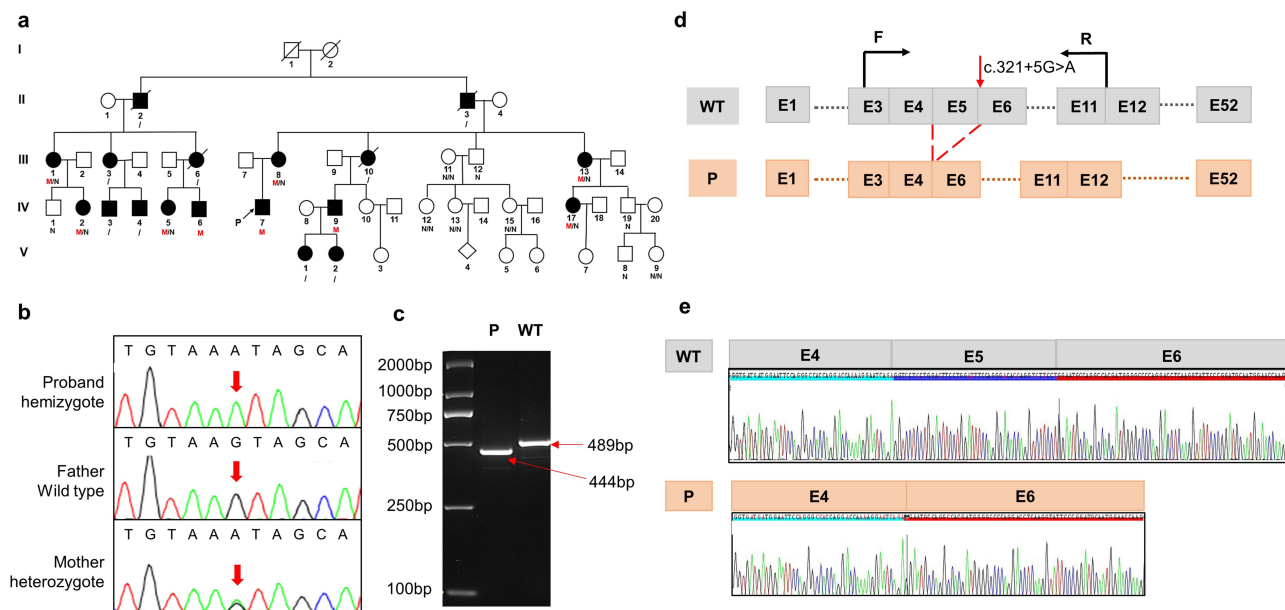
variants have the most severe phenotypes, whereas patients with splicing variants have moderate phenotypes and patients with missense variants have mild phenotypes,<sup>8</sup> in contrast to female patients with XLAS, in whom no genotype–phenotype correlation was presented.<sup>9,10</sup> Genetic testing is more sensitive and specific than renal biopsy for the diagnosis of AS and can provide predictive information about disease severity and prognosis. It has been shown that 10% of the pathogenic variants in XLAS are typically aberrant splicing mutations,<sup>11</sup> which could exhibit a different prognosis depending on whether the variants result in truncated transcript.<sup>12</sup> In this study, we used whole-exome sequencing (WES) to identify one splicing variant in a Chinese family with XLAS and verified the pathogenicity of the mutation in vitro experiments.

## Materials and Methods

A five-generation pedigree with a total of 49 family members originating from the remote rural areas in Hainan province of China was investigated in this study (Figure 1a). For all participants, we collected clinical data including family relationship, gender, age at onset of disease, renal function (hematuria, proteinuria, stage of chronic kidney disease (CKD)), sensorineural hearing loss, ocular lesions and medical history. Patients' CKD was staged according to the K/DOQI clinical practice guideline.<sup>13</sup> There are no consanguineous marriages in the family. WES and Sanger sequencing were performed for proband (IV-7) and their parents. In vitro splicing analysis was performed to verify the effect of mutation on mRNA splicing. Peripheral blood samples were collected from 17 family members and verified by Sanger sequencing. Renal pathology of the proband's brother (IV-6) was assessed using hematoxylin-eosin (HE) staining, periodic acid-Schiff (PAS) staining, periodic acid silver methenamine (PASM) staining, Masson examination, immunofluorescence staining and electron microscopy (EM) analysis. Consent was obtained from all patients to collect and publish the data.

## Case Presentation

As shown in Table 1, the progression and severity of AS varied considerably between affected individuals in the family. There were no ocular lesions or hearing loss in the proband, his mother, or other family members. WES and Sanger sequencing were performed for proband (IV-7) and their parents. Peripheral blood samples were collected from 17 family members and verified



**Figure 1** Sequence analysis of the pedigree and in vitro splicing experiments (a) pedigree of the Chinese family with XLAS. Black filled symbols represent affected individuals; The symbols with a slash correspond to deceased individuals; Arrow indicates the proband; M represent mutation (c.321+5G>A), N represent normal, / indicate not detect. (b) Sanger sequencing of the proband and his parents. (c) Electrophoresis for amplification of *COL4A5* cDNA from the skin tissue of healthy individual and proband. (d) Schematic overview of the region harboring c.321+5G>A mutation in *COL4A5* and representation of the abnormal splicing. Representation of the alternative splicing of exon 5 in *COL4A5*. (e) Sequencing chromatogram of *COL4A5* wild-type cDNA and splice variants.

**Table I** Clinical Data of Patients with the COL4A5 Gene Variant

No.	Sex	Age (year)	Age Of Onset (year)	Hematuria	Proteinuria	Stage Of CKD	Age Of Onset CKD (year)	Ultrasound	Renal Function
IV-7	Male	22	11	+++	+++	V	17	Enhanced echogenicity of both renal parenchyma with indistinct corticomedullary demarcation	Abnormal
III-8	Female	48	34	+	+++	V	43	Enhanced echogenicity and decreased blood flow in both renal parenchyma	Abnormal
IV-2	Female	23	20	+	++	III	20	Enhanced echogenicity of both renal parenchyma with indistinct corticomedullary demarcation; echogenic enhancement of the left renal calyx margin	Abnormal
IV-5	Female	24	17	+++	-	I	17	Enhanced echoes of the calyx margins of both kidneys; calcification	Normal
IV-6	Male	15	15	+++	++	I	16	Enhanced echoes of the calyx margins of both kidneys; calcification	Normal
IV-9	Male	34	21	+	+++	V	28	Macular dense shadows in the medulla of the left kidney clustered around the calyx	Normal
IV-17	Female	28	16	+++	+	I	17	Few punctate strong echoes at the cortico-medulla junction	NA
III-1	Female	43	31	++	+++	III	43	NA	Abnormal
III-13	Female	55	54	+	+	I	54	NA	NA

**Abbreviations:** NA, not available; "-", negative; "+", minor; "++", moderate; "+++", massive.

by Sanger sequencing. Co-segregation analysis revealed that several members of the family had c.321+5G>A mutation in *COL4A5*; however, the severity of their clinical phenotypes was inconsistent (Figure 1a and Table 1).

#### IV-7

The proband was a 23-year-old male who developed foamy urine, microscopic hematuria (BC250/UL), and moderate-to-severe proteinuria at the age of 11 years, and soon progressed to ESKD, with serum creatinine more than 700  $\mu\text{mol/L}$ , which was treated with peritoneal dialysis. Ultrasound showed both kidneys to be normal size, with enhanced parenchymal echogenicity and unclear demarcation of the cortex from the medulla.

Comprehensive whole-exome sequencing revealed a hemizygous splice variant in *COL4A5* (NM\_000495: c.321+5G>A) in the proband, which inherited from his mother. The Sanger sequencing in the proband's parents confirmed that the mutation was indeed inherited from the mother (Figure 1B). Prediction tools such as Varseak (<https://varseak.bio>), Splice AI (<https://spliceailookup.broadinstitute.org/>), and Mutation Taster (<http://www.mutationtaster.org/>) suggested that the mutation may affect the function of 5' donor splice site. According to the American College of Medical Genetics and Genomics Guidelines (ACMG), the variant was initially determined to be of uncertain significance (VUS), with no or very low incidence in healthy populations (PM2), and multiple calculations predicted that the mutation could potentially have deleterious effects on genes or gene products (PP3). Thus, it is necessary to confirm the pathogenicity by further functional studies.

To investigate whether the *COL4A5* variant could lead to mRNA splicing defects, we isolated total RNA from the skin tissue of the proband and a wild-type individual. The RNA was then reverse transcribed into cDNA. To confirm the splicing predictions, cDNA sequencing was performed. Alongside normal splicing, aberrant splicing products were observed. The presence of the splicing mutation c.321+5G>A in the proband, which was inherited from his mother, resulted in the generation of an abnormal transcript lacking the entire exon 5, in addition to the normal-length transcript. Electrophoresis of the amplified *COL4A5* cDNA from the proband and wild-type individuals revealed a large-sized fragment (489 bp) corresponding to the correctly spliced mRNA, and a small-sized fragment (444 bp) corresponding to the skipping of exon 5. This skipping caused a 45 bp deletion in the coding sequence of the mRNA (Figure 1c and d). The sequencing chromatogram of the normal *COL4A5* cDNA and the splicing variant are shown in Figure 1e.

#### III-8

The proband's mother presented with microhematuria and proteinuria at the age of 34 with normal renal function and developed ESKD and started hemodialysis by the age of 43. Ultrasound showed increased parenchymal echogenicity and decreased blood flow in both kidneys. WES showed a heterozygous variant c.321+5G>A in *COL4A5* gene.

#### IV-2

The female cousin of proband, 23 years old, presented with leg edema, hypertension (230/140mmHg), microscopic hematuria and proteinuria, blood creatinine of 256 $\mu\text{mol/l}$ , and moderate to severe renal function loss (CKD stage 3). Abdominal ultrasound revealed echogenic enhancement of both renal parenchyma with indistinct corticomedullary demarcation and echogenic enhancement of the left renal calyx margin. After 11 months of blood pressure control, proteinuria decreased, and renal function partially recovered with a creatinine of 179 $\mu\text{mol/l}$ .

#### IV-5

Another female cousin of proband, 23-year-old, presented with microscopic hematuria (RBC84/ul) at the age of 17 years, no proteinuria, normal renal function, and ultrasound showed punctate strong echogenicity at the dermo-medullary junction with calcification, which could be easily confused with medullary sponge kidneys. Blood pressure was normal (110/70 mmHg).

#### IV-6

Proband' male cousin, 15 years old, presented with microscopic hematuria, a small amount of proteinuria (516 mg/L), RBCs with full field of view. About one year after the onset of the disease, it progressed to moderate proteinuria (1–2g/L). Uric acid

518  $\mu\text{mol/l}$ , blood pressure 128/85mmHg. Ultrasound showed enhanced echo at the margins of the renal calyces in both kidneys, suggesting calcification. In addition to this, the patient had strabismus.

Renal pathology of IV-6 was assessed using hematoxylin-eosin (HE) staining, periodic acid-Schiff (PAS) staining, periodic acid silver methenamine (PASM) staining, Masson examination, immunofluorescence staining and electron microscopy images (EM) analysis. The renal histopathology of IV-6 showed focal segmental glomerulosclerosis with mild enlargement of the kidney volume. The renal tubular epithelial cells exhibited granular degeneration, and a few tubular lumens were dilated. (SFigure 1A). EM images showed glomerular capillary endothelial cells, renal tubular epithelial cells and visceral epithelial cells with vacuolar degeneration. It also revealed that segmental fusion of foot processes is irregular with an uneven density of GBM thickness (Figure 2A–C). No deposition of immune complexes was observed via Immunofluorescence staining (SFigure 1B).

## IV-9

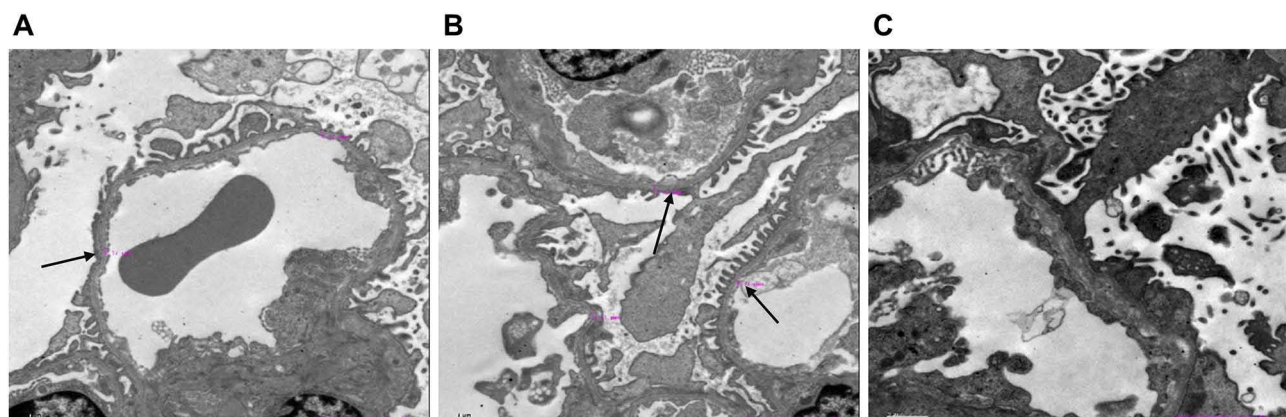
The other male cousin of the proband is 34 years old. At the early stage of illness at the age of 21, there was microscopic hematuria, a small amount or trace proteinuria, 24-hour urine protein of 0.26 with normal renal function. B-ultrasound showed punctate hyperechogenicity, with numerous patchy dense shadows clustered around the renal calyx in the left renal medulla. The diagnosis is medullary sponge kidney, and no abnormalities were found in the right kidney. After 7 years, the disease progressed to ESKD and began hemodialysis.

## IV-17

The other cousin of the proband is 28 years old, who developed microscopic hematuria and proteinuria (162 mg/l) at the age of 11, with RBC250/UL, blood creatinine as high as 700 $\mu\text{mol/l}$  or above. As the disease progressed, peritoneal dialysis begins. Blood pressure was normal at 118/81mmHg, and ultrasound showed no renal abnormalities.

## III-1

The proband's aunt, 43 years old, presented with intermittent microscopic hematuria at the age of 29, with normal urine protein and creatinine levels. At that time, her renal function and blood pressure were normal. Afterwards, she reported an increase in nocturia. At the age of 43, a physical examination revealed abnormal kidney function, with hematuria, urine trace protein 1726 mg/l, urine albumin 1203 mg/l, creatinine 147  $\mu\text{mol/l}$ , uric acid 402  $\mu\text{mol/L}$ , Hb113 g/L, and blood pressure 159/99mmHg. B-ultrasound showed normal size and morphology of both kidneys, with diffuse changes. As renal function deteriorated, she was in CKD-III at age of 43.



**Figure 2** Electron microscopy images of his kidney of IV-6 (A–C) show two glomeruli under electron microscopy. Electron microscopy of renal showed glomerular capillary endothelial cells, renal tubular epithelial cells, and visceral epithelial cells with vacuolar degeneration; segmental fusion of foot processes; irregular with an uneven density of glomerular basement membrane thickness. The black arrow indicates an abnormally thick basement membrane.

### III-13

The older aunt (III-13) had a later onset and presented with microscopic hematuria without proteinuria and normal renal function at the age of 54. At the age of 51, she developed stomach cancer and underwent surgery.

### Other Cases

The proband's grandfather, II-3, as well as his younger brother, II-2, developed ESRD at the age of 70, and 30, respectively, and both of them have passed away. The proband's aunts III-6 developed ESRD at the age of 31 and began hemodialysis. She passed away at the age of 36. Another aunt III-10 died of ESRD at the age of 28. The two nieces of the proband, V-1 and V-2, presented with gross hematuria, and Sanger sequencing was not performed for them. The other aunt of the proband III-3 and two male cousins IV-3 and IV-4 did not undergo Sanger sequencing, so their genotypes could not be obtained. According to family recollections, they all experienced hematuria, but no further clinical phenotypes were provided.

### Discussion

In this study, a novel intronic mutation in *COL4A5* was identified by WES and Sanger sequencing in an affected Chinese family with a history of kidney disease, which demonstrated the benefit of genetic sequencing in determining the etiology of hereditary kidney disease.

In the 19th century, Fliter and Gregory et al proposed the AS clinical diagnostic criteria that most cases could be clearly diagnosed by clinical manifestations, family history, renal histopathological examination and type IV collagen  $\alpha$ -chain staining.<sup>14</sup> However, in actual clinical work, AS patients often show atypical renal histopathological changes and lack of unique symptoms, which usually exhibit low awareness rates of chronic kidney diseases. Unfortunately, due to the lack of symptoms, patients often do not seek medical help until renal failure has already occurred. Approximately 10% of affected individuals, however, develop kidney failure by the age of 60, making it difficult to provide effective treatments.<sup>15</sup> Male XLAS patients with hemizygous pathogenic variants in *COL4A5* have a 100% risk of progression to ESRD, and female patients with heterozygous pathogenic variants have an approximately 25% risk of developing ESRD,<sup>1</sup> which is consistent with our findings. Therefore, genetic diagnosis became an effective method for diagnosing AS,<sup>16</sup> which promoted a demand for a comprehensive understanding of the genetic causes of AS. Genetic analysis, such as WES, may be effective in increasing awareness and enabling early intervention in the treatment of AS, which may delay the course of AS and reduce the severity of the disease.

Studies have shown that almost all females with XLAS and kidney failure had a history of proteinuria.<sup>17</sup> This is consistent with our findings that IV-5 and III-3 did not present a history of proteinuria and had stage I of ESKD compared with those females in families with a history of proteinuria. Furthermore, girls with proteinuria detected before the age of 15 years developed to ESKD more rapidly than those without proteinuria, suggesting that proteinuria is associated with a risk of serious disease. Hemizygous male patients with AS are typically more severely affected than females with heterozygotes variants,<sup>18,19</sup> who have recurrent hematuria, early-onset proteinuria and ESKD, often requiring dialysis or kidney transplantation before thirty years old.<sup>20</sup> Female carriers of X-linked AS exhibit a lack of genotype–phenotype correlation, with significant intrafamilial variability in disease severity. The same observation is evident in our family. Despite being of the same age as IV-5, IV-2 progressed to CKD stage 3 with massive proteinuria, while IV-5 manifested a milder phenotype. III-8 developed ESKD at 48 years, while III-13, at 55 years, presented with microscopic hematuria with a small amount of proteinuria. This intrafamilial heterogeneity might be attributed to random X-chromosome inactivation. Research has shown that 90% of female patients with severe AS phenotype have X-chromosome inactivation of the normal *COL4A5* allele in their kidneys.<sup>21</sup> In peripheral leukocytes, the relative activity of the mutated X chromosome compared to the normal allele varies among AS heterozygotes, and this ratio is not associated with renal function.<sup>22</sup> Furthermore, proteinuria onset and progression, as well as hearing loss, are risk factors for renal failure. In this family, female patients with significant proteinuria have relatively more severe disease severity,<sup>9</sup> and there are no patients with hearing abnormalities.

Literatures have reported that some individuals with AS are associated with a phenotype of hypertension.<sup>23</sup> We aimed to investigate whether a genotype–phenotype correlation exists within this large family. However, we only observed hypertension in patient IV-2 (230/140mmHg), while no such phenotype was present in the other family members. This discrepancy might be attributed to clinical heterogeneity.

It is widely acknowledged that there is a strong correlation between mutation type and phenotype in patients with XLAS. The type of variants and the location of the variant affecting the collagen  $\alpha$  chain are the predominant factors of the age of onset of ESKD, and the likelihood of sensorineural hearing loss and ocular abnormalities.<sup>24</sup> It was found that the male with splicing variants leading to in-frame transcription had a milder phenotype than those with out-of-frame transcription.<sup>7,12</sup> Nonsense mutations have a 90% chance of developing ESRD at age 30, and splicing mutations and missense mutations have a 70% and 50% risk of developing ESRD, respectively.<sup>6</sup> A study analyzing 14 XLAS pedigrees with atypical splicing mutations showed that the median age of ESKD onset was 20 years and 29 years for families with truncating variants and non-truncating variants, respectively.<sup>12</sup> In our study, we identified a novel mutation, c.321+5G>A, in *COL4A5* gene. This mutation resulted in the production of an abnormal transcript lacking exon 5, in addition to the normal-length transcript. The expression level of *COL4A5* RNA in peripheral blood is extremely low, while the expression level in skin and kidney tissues is relatively high. The most direct and effective way to determine whether an intronic mutation affects splicing is to extract RNA from the patient's kidney or skin tissue for analysis, which is an invasive experiment. There are also studies that use in vitro Minigene technology to analyze potential splicing mutations.<sup>25</sup>

Splice variants account for a significant proportion of the total variants in XLAS, and this proportion is likely to increase with future advances in genetic analysis. It is essential to clarify the pathogenicity and transcript patterns by in vitro functional splicing assays.

## Conclusion

Our study identified an intronic variant and demonstrated its pathogenicity in vitro experiment. This finding contributes to the enrichment of database resources for AS. AS should be suspected when there is a family history of persistent glomerular hematuria and renal impairment. Furthermore, we also highlight the critical role that genetic analysis can play in personalized AS diagnosis.

## Statement of Ethics

Written informed consent was obtained from all participants in accordance with principles of the Declaration of Helsinki. The protocol of the study was approved by the Medical Ethics Committee of Central South University Xiangya School of Medicine Affiliated Haikou Hospital in Haikou, Hainan, China (ZY-IRB-FOM-063).

## Funding

This research was supported by the Key project of Chongqing Natural Science Foundation (cstc2020jcyj-zdxmX0011, cstc2021jxjl130017) and Special funding for science and technology in Hainan Province (ZDYF2020122).

## Disclosure

Jingmin Yang and Daru Lu should be regarded as co-corresponding authors for this study. All authors declare no competing interests in this work.

## References

1. Kashtan CE, Ding J, Garosi G, et al. Alport syndrome: a unified classification of genetic disorders of collagen IV  $\alpha$ 345: a position paper of the Alport syndrome classification working group. *Kidney Int.* 2018;93(5):1045–1051. doi:10.1016/j.kint.2017.12.018
2. Nozu K, Nakanishi K, Abe Y, et al. A review of clinical characteristics and genetic backgrounds in Alport syndrome. *Clin Exp Nephrol.* 2019;23(2):158–168. doi:10.1007/s10157-018-1629-4
3. Savage J, Gregory M, Gross O, Kashtan C, Ding J, Flinter F. Expert guidelines for the management of Alport syndrome and thin basement membrane nephropathy. *J Am Soc Nephrol.* 2013;24(3):364–375. doi:10.1681/asn.2012020148

4. Heidet L, Arrondel C, Forestier L, et al. Structure of the human type IV collagen gene COL4A3 and mutations in autosomal Alport syndrome. *J Am Soc Nephrol.* 2001;12(1):97–106. doi:10.1681/asn.V12197
5. Feingold J, Bois E, Chompret A, Broyer M, Gubler MC, Grünfeld JP. Genetic heterogeneity of Alport syndrome. *Kidney Int.* 1985;27(4):672–677. doi:10.1038/ki.1985.63
6. Jais JP, Knebelmann B, Giatras I, et al. X-linked Alport syndrome: natural history in 195 families and genotype-phenotype correlations in males. *J Am Soc Nephrol.* 2000;11(4):649–657. doi:10.1681/asn.V114649
7. Yamamura T, Horinouchi T, Nagano C, et al. Genotype-phenotype correlations influence the response to angiotensin-targeting drugs in Japanese patients with male X-linked Alport syndrome. *Kidney Int.* 2020;98(6):1605–1614. doi:10.1016/j.kint.2020.06.038
8. Bekheirnia MR, Reed B, Gregory MC, et al. Genotype-phenotype correlation in X-linked Alport syndrome. *J Am Soc Nephrol.* 2010;21(5):876–883. doi:10.1681/asn.2009070784
9. Yamamura T, Nozu K, Fu XJ, et al. natural history and genotype-phenotype correlation in female X-Linked Alport Syndrome. *Kidney Int Rep.* 2017;2(5):850–855. doi:10.1016/j.ekir.2017.04.011
10. Jais JP, Knebelmann B, Giatras I, et al. X-linked Alport syndrome: natural history and genotype-phenotype correlations in girls and women belonging to 195 families: a “European Community Alport Syndrome Concerted Action” study. *J Am Soc Nephrol.* 2003;14(10):2603–2610. doi:10.1097/01.asn.0000090034.71205.74
11. Savige J, Storey H, Watson E, et al. Consensus statement on standards and guidelines for the molecular diagnostics of Alport syndrome: refining the ACMG criteria. *Eur J Hum Genet.* 2021;29(8):1186–1197. doi:10.1038/s41431-021-00858-1
12. Horinouchi T, Nozu K, Yamamura T, et al. Detection of splicing abnormalities and genotype-phenotype Correlation in X-linked Alport Syndrome. *J Am Soc Nephrol.* 2018;29(8):2244–2254. doi:10.1681/asn.2018030228
13. K/DOQI clinical practice guidelines for bone metabolism and disease in chronic kidney disease. *Am J Kidney Dis.* 2003;42(4 Suppl 3).
14. Churg J, Sherman RL. Pathologic characteristics of hereditary nephritis. *Arch Pathol.* 1973;95(6):374–379.
15. Pierides A, Voskarides K, Athanasiou Y, et al. Clinico-pathological correlations in 127 patients in 11 large pedigrees, segregating one of three heterozygous mutations in the COL4A3/ COL4A4 genes associated with familial haematuria and significant late progression to proteinuria and chronic kidney disease from focal segmental glomerulosclerosis. *Nephrol Dial Transp.* 2009;24(9):2721–2729. doi:10.1093/ndt/gfp158
16. Kashtan CE. Alport Syndrome: Achieving early diagnosis and treatment. *Am J Kidney Dis.* 2021;77(2):272–279. doi:10.1053/j.ajkd.2020.03.026
17. Gibson JT, de Gooyer M, Huang M, Savige J. A systematic review of pathogenic COL4A5 variants and proteinuria in women and girls with X-linked Alport Syndrome. *Kidney Int Rep.* 2022;7(11):2454–2461. doi:10.1016/j.ekir.2022.08.021
18. Migeon BR. X inactivation, female mosaicism, and sex differences in renal diseases. *J Am Soc Nephrol.* 2008;19(11):2052–2059. doi:10.1681/asn.2008020198
19. Temme J, Peters F, Lange K, et al. Incidence of renal failure and nephroprotection by RAAS inhibition in heterozygous carriers of X-chromosomal and autosomal recessive Alport mutations. *Kidney Int.* 2012;81(8):779–783. doi:10.1038/ki.2011.452
20. Gross O, Netzer KO, Lambrecht R, Seibold S, Weber M. Meta-analysis of genotype-phenotype correlation in X-linked Alport syndrome: impact on clinical counselling. *Nephrol Dial Transp.* 2002;17(7):1218–1227. doi:10.1093/ndt/17.7.1218
21. Guo C, Van Damme B, Vanrenterghem Y, Devriendt K, Cassiman JJ, Marynen P. Severe Alport phenotype in a woman with two missense mutations in the same COL4A5 gene and preponderant inactivation of the X chromosome carrying the normal allele. *J Clin Invest.* 1995;95(4):1832–1837. doi:10.1172/jci117862
22. Vetrie D, Flinter F, Bobrow M, Harris A. X inactivation patterns in females with Alport’s syndrome: a means of selecting against a deleterious gene? *J Med Genet.* 1992;29(9):663–666. doi:10.1136/jmg.29.9.663
23. Kalmár T, Turkevi-Nagy S, Bitó L, et al. Phenotype-genotype correlations in three different cases of adult-onset genetic focal segmental glomerulosclerosis. *Int J Mol Sci.* 24(24). doi:10.3390/ijms242417489
24. Savige J, Huang M, Croos Dabrera MS, Shukla K, Gibson J. Genotype-Phenotype Correlations for Pathogenic COL4A3-COL4A5 Variants in X-Linked, Autosomal Recessive, and Autosomal Dominant Alport Syndrome. *Front Med Lausanne.* 2022;9:865034. doi:10.3389/fmed.2022.865034
25. Malone AF, Funk SD, Alhamad T, Miner JH. Functional assessment of a novel COL4A5 splice region variant and immunostaining of plucked hair follicles as an alternative method of diagnosis in X-linked Alport syndrome. *Pediatr Nephrol.* 2017;32(6):997–1003. doi:10.1007/s00467-016-3565-4