

# Heatstroke Comorbid with SARS-CoV-2 Infection: A Case Report and Literature Review

Xiao-xiao Ni<sup>1,\*</sup>, Zhe-ying Liu<sup>2,\*</sup>, Yan-yan Zeng<sup>1,\*</sup>, Zhi-feng Liu<sup>2</sup>

<sup>1</sup>Department of Hyperbaric Oxygen Medicine and Rehabilitation, General Hospital of Southern Theater Command of PLA, Guangzhou, Guangdong, People's Republic of China; <sup>2</sup>Department of Medicine Intensive Care Unit, General Hospital of Southern Theater Command of PLA, Guangzhou, Guangdong, People's Republic of China

\*These authors contributed equally to this work

Correspondence: Zhi-feng Liu, Department of Medicine Intensive Care Unit, General Hospital of Southern Theatre Command of PLA, Guangzhou, Guangdong, People's Republic of China, Email Zhifengliu7797@163.com

**Background:** Hyperthermia and multiple organ dysfunction syndrome (MODS) are the main characteristics of heatstroke and COVID-19. Differentiating between these illnesses is crucial during a summer COVID-19 pandemic, but cases of heatstroke comorbid with COVID-19 are rarely reported.

**Case description:** We report the first case of heatstroke comorbid with Severe Acute Respiratory Syndrome Coronavirus 2 (SARS-CoV-2) infection in a 52-year-old male. After receiving intravenous antibiotics, organ protection measures, and treatment for coagulation disorders, his fever and coma resolved. However, he developed dyspnea and cerebral hemorrhage after several days. This patient experienced a multi-pathogen pulmonary infection and an intractable coagulopathy that ultimately resulted in MODS and death.

**Conclusion:** The combination of heatstroke and SARS-CoV-2 infection exacerbated inflammation, immune abnormalities, and coagulation disorders. The interaction between inflammation and coagulation disturbances contributed to the underlying mechanism in this case, highlighting the importance of early anti-infection, treatment for coagulopathy, immune regulation, and organ protection as crucial interventions.

**Keywords:** heatstroke, COVID-19, infection, coagulation disorder, cerebral hemorrhage

## Background

The Severe Acute Respiratory Syndrome Coronavirus 2 (SARS-CoV-2) has rapidly spread worldwide since 2019, demonstrating high infectivity and the ability to cause multi-organ damage. Specific comorbidities such as hypertension are associated with an increased risk of SARS-CoV-2 infection, leading to severe lung injury and higher mortality rates.<sup>1</sup> The pathophysiology of SARS-CoV-2 infection involves activation of the immune and hematologic systems, triggering a cytokine storm through endotoxin and tumor necrosis factor (TNF- $\alpha$ ). This cascade activates coagulation and causes systemic inflammation.<sup>2</sup> Therefore, the Corona Virus Disease 2019 (COVID-19) is a complex disease that affects multiple organs and can lead to systemic complications.

The prevalence of heatstroke (HS) has increased in recent years, coinciding with global climate warming. The year 2023 set a new record for ocean temperatures, becoming the warmest on record. HS is a life-threatening systemic disease characterized by a core body temperature exceeding 40°C and subsequent development of multiple organ dysfunction syndrome (MODS). HS leads to an increased permeability of endotoxin from the intestinal mucosa into the systemic circulation, triggering the development of systemic inflammatory response syndrome (SIRS).<sup>3</sup> Both HS and COVID-19 are systemic febrile diseases. Despite the potential for numerous eligible patients in recent years, there is still a lack of reports on comorbidity between severe HS and COVID-19. We present a case report of a 52-year-old male patient

admitted to our hospital with both conditions. This report aims to emphasize the distinctive clinical and pathophysiological features that differentiate this case from others with HS, ensuring accurate diagnosis and appropriate treatment.

## Description

The 52-year-old man tested positive for SARS-CoV-2 using a self-test kit after having a cold. He returned to work without fever after resting for two days, but lost consciousness while working outdoors in an ambient temperature of 35°C for five hours. Upon admission to the local hospital's emergency department, his core temperature (T<sub>c</sub>) was recorded as 40°C. The patient presented with persistent coma, dyspnea and gastrointestinal hemorrhage. No underlying diseases and relative family history was noted. Based on the characteristic presentation of hyperpyrexia, coma and multiple organ damage, a diagnosis of HS was established. He was admitted to emergency intensive care unit (ICU) of the local hospital and then received mechanical ventilation. The test results indicated the presence of pulmonary infection, hepatic and renal dysfunction, myocardial ischemia and coagulation disorders. The patient received initial management including rehydration (intravenously infused Lactated Ringer's solution and normal saline at a rate of 2.5mL/kg·h), intravenous administration of Piperacillin Sodium and Tazobactam Sodium, vasoactive medications for blood pressure support, continuous mechanical ventilation, and continuous renal replacement therapy (CRRT) to manage subsequent anuria. The patient received plasma transfusion and was administered Tranexamic acid on day 5. The worsening of his condition led to his admission to the medical ICU of our hospital 7 days after HS.

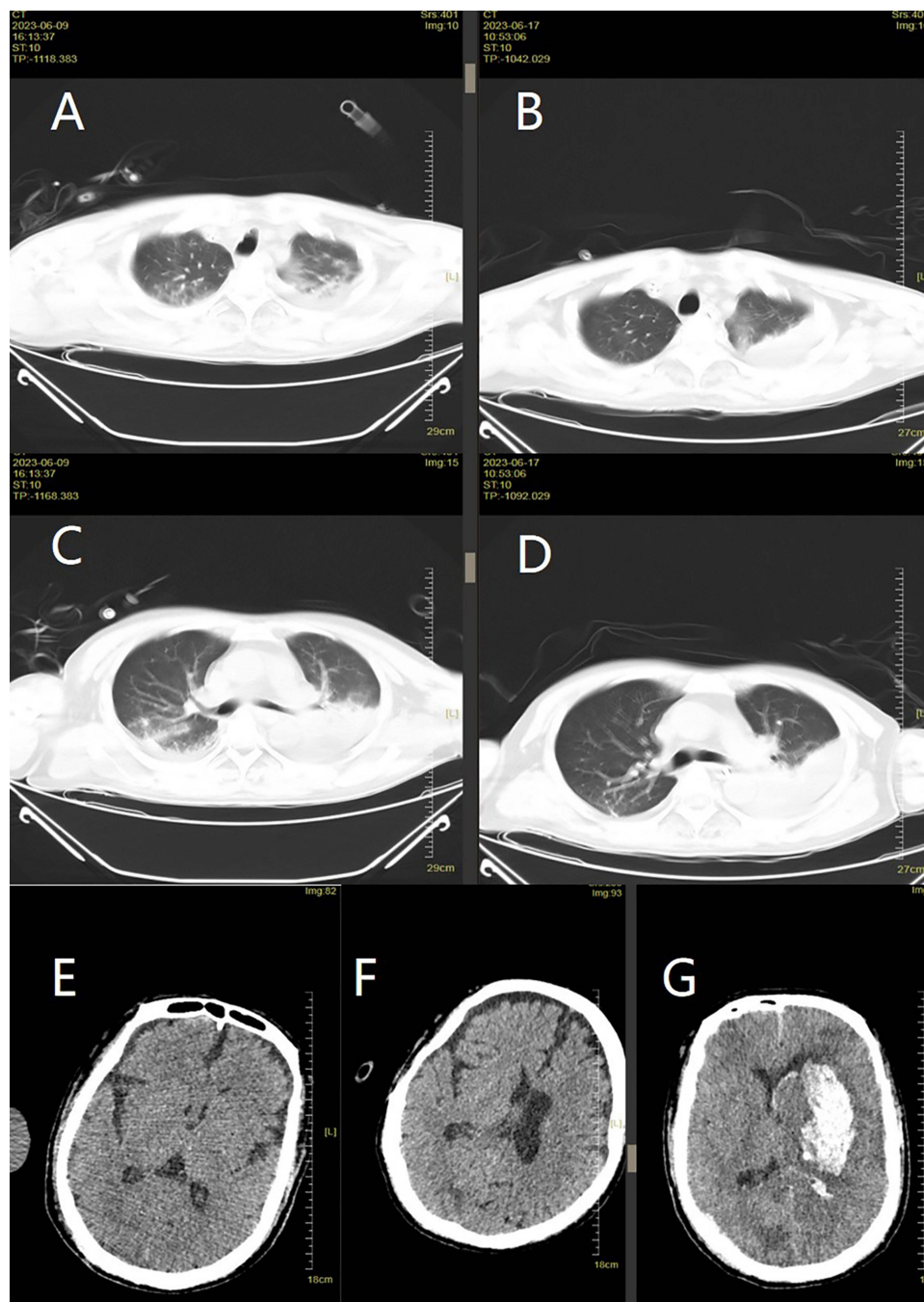
Following admission, Reverse-transcription polymerase chain reaction (RT-PCR) testing of a nasopharyngeal swab yielded positive results for SARS-CoV-2. The patient was diagnosed with HS and severe COVID-19 based on China's COVID-19 Diagnosis and Treatment Program (trial version 10):<sup>4</sup> 1. real-time fluorescent RT-PCR detection of SARS-CoV-2 nucleic acid is positive; 2. respiratory failure and requires mechanical ventilation; 3. shock; 4. combined with multiple organ failure requiring intensive care. The patient had no contact with COVID-19 diagnosed patients or healthcare workers in the hospital, indicating community-acquired infection. The physical examination showed a Glasgow Coma Scale (GCS) score of 3/15, with scores of 1 for eye-opening, verbal response, and motor response. Additionally, the pupils were symmetrical and non-reactive. The heart rate was recorded at 106 bpm and blood pressure was maintained at 126/77 mmHg by continuously infusing norepinephrine at a rate of 0.4 ug/kg·min. The laboratory test results indicated a severe infection, along with anemia, thrombocytopenia, disseminated intravascular coagulation (DIC), as well as acute liver and kidney injury. The white blood cell count (WBC) decreased from  $3.55 \times 10^9/L$  to  $3.13 \times 10^9/L$ , lymphocytes significantly decreased from  $0.25 \times 10^9/L$  to  $0.1 \times 10^9/L$ , and neutrophil percentage (N%) increased to 85.3%. The Procalcitonin level measured 2.81 ng/mL and C-reactive protein (CRP) level was 32.6 mg/L. (Table 1). Sputum culture testing yielded *Stenotrophomonas maltophilia* and *Candida lipolytica*. The central venous catheter culture test detected *Staphylococcus epidermidis*, but the continuous blood culture test yielded no positive results. The Computed Tomography (CT) scan revealed bilateral frontal subdural effusion, consolidation and atelectasis in the lower lungs, inflammation in the right upper lobe, bilateral pleural effusion, and a small amount of abdominal fluid. (Figure 1A, C and E)

The patient received synchronized intermittent mandatory ventilation with a positive end expiratory pressure of 5 mmH<sub>2</sub>O and an oxygen concentration of 80% and continuous administration of norepinephrine and pituitrin to sustain normal blood pressure. Polyene phosphatidylcholine, adenosylmethionine budisulfonate, ulinastatin, and hemofiltration have been employed for the management of hepatic and renal dysfunction. The antibiotic was substituted with Meropenem and Thymalfasin was administered for 20 days to augment immune function. Mannitol was used to alleviate intracranial pressure for 3 days. To improve coagulation dysfunction, the patient received plasma and cryoprecipitate transfusions, continuous intravenous infusion of heparin sodium at 6000u/day and CRRT with sodium citrate for anticoagulant (8g/day) on day 7. Platelet transfusion was administered after 9 days of HS. His T<sub>c</sub> fluctuated between 36 °C and 38.5 °C. CRRT was administered without anticoagulant on day 8. The patient had gastrointestinal hemorrhage and fever after 9 days of HS, but electronic gastroenteroscopy showed no signs of active bleeding. He underwent red blood cell suspension transfusion, hemostasis treatment and gastric acid suppression. Teicoplanin was added due to the presence of Methicillin-resistant *Staphylococcus aureus* isolated from sputum culture. The patient regained consciousness on day 13 with a GCS score of 14/15 and presented with a moderate fever. Gastrointestinal hemorrhage was not

**Table I** Clinical and Laboratory Findings

Finding	Days from Heat Stroke									
	1	5	7	9	13	17	20	22	26	28
<b>Clinical</b>										
Tc (°C)	40	38	36.5	38.2	38.5	39	37.5	36.8	37.7	36
GCS	3	3	3	9	14	5	3	3	3	3
BP(mmHg)	–	–	124/79	129/77	135/89	148/83	108/75	134/81	116/78	98/49
HR(bpm)			58~106	54~104	61~100	72~112	80~123	68~84	56~105	55~80
<b>Indicators of infection and immunity</b>										
WBC (10 <sup>9</sup> /L)	3.55	1.96	3.13	9.88	14.28	14.94	14.12	15.93	25.56	35.07
NEU (10 <sup>9</sup> /L)	3.14	1.54	2.67	8.15	13.24	13.77	13.32	15.37	24.1	33.7
L (10 <sup>9</sup> /L)	0.25	0.13	0.1	0.39	0.58	0.74	0.48	0.21	1.01	1.17
Neut%	88.5	78.6	85.3	82.5	92.7	92.2	94.3	96.5	94.3	96.1
CRP (mg/L)	–	–	32.6	61.3	–	38.9	–	–	–	–
PCT (ng/mL)	–	–	2.81	1.41	3.06	16.66	11.89	17.77	24.05	91.6
B-cell abs(/μL)	-	-	38	-	67	79	-	-	-	-
T-cell abs (/μL)	-	-	90	-	214	221	-	-	-	-
NK-cell abs(/μL)	-	-	1	-	22	19	-	-	-	-
CD4 abs (/μL)	-	-	51	-	130	133	-	-	-	-
CD8 abs (/μL)	-	-	20	-	71	40	-	-	-	-
CD4+/CD8+	-	-	2.5	-	1.83	3.3	-	-	-	-
IL-6 (pg/mL)	-	-	-	-	25.33	251.03	-	-	3689.8	-
IL-8 (pg/mL)	-	-	-	-	82.69	100.9	-	-	371.9	-
<b>Indicators of coagulation function</b>										
Hb (g/L)	127	97	82	73	95	83	92	81	80	75
PLT (10 <sup>9</sup> /L)	18	11	5	40	61	107	46	54	78	57
D-D(mg/L)	>40	6.17	10.3	10.17	11.7	15.25	17.3	10.28	>20	>20
Fib (g/L)	<0.3	1.91	2.3	2.7	2.6	3.6	3.1	3.7	4.1	4
FDP (μg/mL)	-	-	21.8	36.5	43.2	80.1	67.8	37	135	135
PT (sec)	28.91	21.22	22.6	16.1	17.3	19.8	20.2	21	17.6	36.8
INR	2.47	1.8	1.98	1.28	1.4	1.68	1.71	1.81	1.48	3.64
APTT (sec)	66.67	63.3	45.2	41.8	41.9	51.1	59.3	55.6	42.9	63.8
TT (sec)	100	23.0	20.9	19.8	22	22.5	17.1	15.7	21.3	21
<b>Indicators of multiple organ functions</b>										
TBIL (umol/L)	24.13	183.8	256.2	205.5	192.9	235.2	219.7	193.1	134.2	270.6
ALT (U/L)	88.8	769.5	423	201	71	44	34	51	30	134
AST (U/L)	256.4	433.6	197	76	58	118	93	86	124	1587
LDH (U/L)	1003.56	452.6	397	-	426	-	-	-	-	-
Cr (μmol/L)	223.1	82.9	133	175	374	441	158	195	317	119
BUN (mmol/L)	-	-	10.3	18.9	37.5	47.1	18.1	20.3	37.3	17.2
Cys-C(mg/L)	-	-	3.44	2.51	4.33	4.79	2.09	3.99	5.91	2.75
hs-TnT (pg/mL)	-	-	307.9	219.7	-	152.2	-	-	-	-
cTnl (μg/L)	-	-	<0.1	<0.1	1.5	<0.1	-	2.06	2.76	-

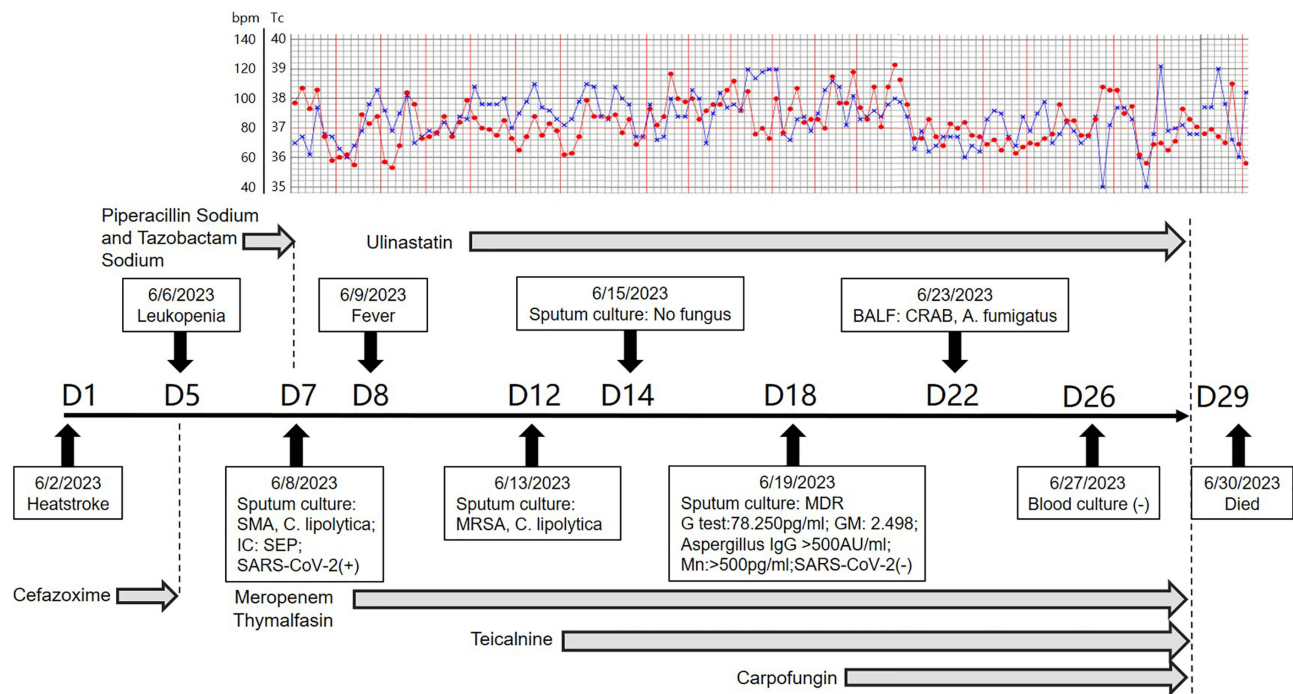
**Abbreviations:** Tc, core Temperature; GCS, Glasgow Coma Scale; BP, blood pressure; HR, heart rate; bpm, beat per minute; WBC, White blood cell count; NEU, neutrophil cell count; L, lymphocyte count; Neut%, the ratio of neutrophil to White blood cell count; CRP, C-reactive protein; PCT, Procalcitonin; abs, absolute value; Hb, hemoglobin; PLT, Platelet count; D-D, D-dimer; Fib, Fibrinogen; FDP, Fibrinogen degradation product; PT, Prothrombin time; INR, international normalized ratio; APTT, activated partial thromboplastin time; TT, thrombin time; TBIL, Total bilirubin; ALT, Alanine transaminase; AST, Aspartate aminotransferase; LDH, Lactate dehydrogenase; Cr, creatinine; BUN, blood urea nitrogen; Cys-C, cystatin-C; hs-TnT, high-sensitivity cardiac troponin T; cTnl, cardiac troponin I.



**Figure 1** The computed tomography (CT) scanning images of the brain and lung. (A and C) CT scanning images of lung on day 8 after heatstroke; (B and D) CT scanning images of lung on day 16 after heatstroke; (E) CT scanning images of brain on day 8 after heatstroke; (F) CT scanning images of lung on day 16 after heatstroke; (G) CT scanning images of lung on day 20 after heatstroke.

observed. Mechanical ventilation was discontinued and the tracheal tube was removed. But the creatinine levels increased following the suspension of CRRT on day 12.

On day 17, he developed sudden dyspnea with desaturation (oxygen saturation <85%) followed by a high fever (Tc: 39.3°C), necessitating reintubation and mechanical ventilation. Bronchoscopy revealed less sputum in both lungs and subbranches. He experienced a recurrence of coma, with a GCS score of 3/15. WBC increased to  $14.94 \times 10^9/L$  and NEU increased to  $13.77 \times 10^9/L$ . The levels of serum total bilirubin rose to 235.2  $\mu\text{mol/L}$ , while creatinine increased to 441  $\mu\text{mol/L}$ . The brain CT scan revealed an ischemic stroke in the right frontal lobe and a hemorrhagic infarction in



**Figure 2** The management of infection, alterations in core temperature, and findings from pathogen testing for the patient. The line in blue indicated body temperature and the line in red indicated the heart rates of the patient.

**Abbreviations:** SC, Sputum culture; CVCC, central venous catheter clture; BC, blood culture; SMA, *Stenotrophomonas maltophilia*; C. lipolytica, *Candida lipolytica*; SEP, *Staphylococcus epidermidis*; MRSA, Methicillin resistant *Staphylococcus aureus*; G, I, 3-beta-D glucan test; GM, *Aspergillus galactomannan* test; Mn, *Candida mannan*; CRAB, Carbapenem-resistant *Acinetobacter baumannii*.

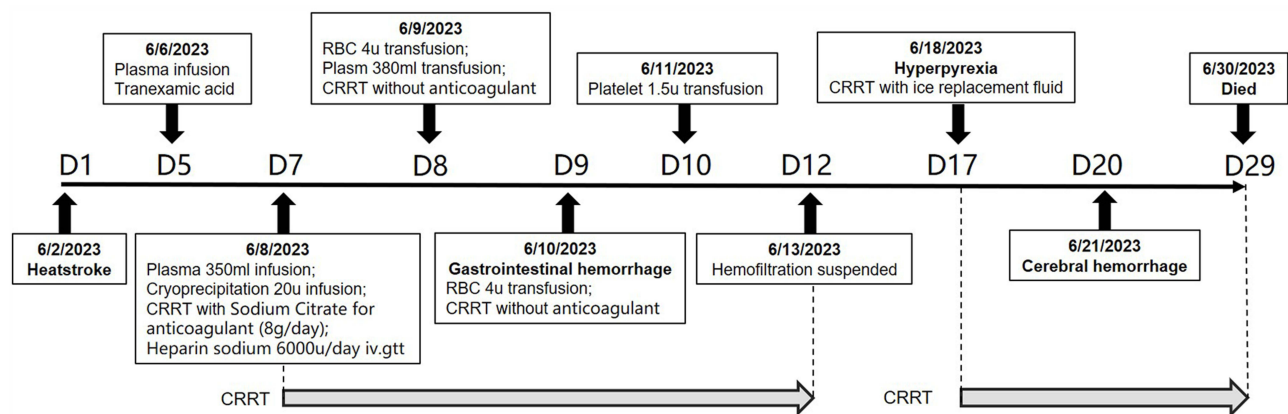
the right occipital lobe. (Figure 1F). The patient underwent cooling therapy using CRRT with ice-cold replacement fluid, along with persistent administration of Meropenem and Teicoplanin for anti-infection treatment. Carprofungin was added on day 18 due to the observed elevation in serum levels of *Aspergillus galactomannan*, *Aspergillus IgG* antibody, and *Candida mannan*. The RT-PCR testing for SARS-CoV-2 returned negative results.

The patient's fever and infection improved on day 20, but he subsequently developed cerebral hemorrhage and hernia with bilateral dilated pupils (Figure 1G). The dehydration therapy was used to reduce intracranial pressure, as surgery was refused by his family. On day 22, indicators of infection, levels of aspartate aminotransferase and creatinine increased again. Carbapenem-resistant *Acinetobacter baumannii* and *A. fumigatus* were cultured in the bronchoalveolar lavage fluid. The combination of Meropenem, Teicoplanin, and Carprofungine was administered for anti-infective therapy. The patient's condition progressively worsened over the next 7 days, ultimately resulting in his demise on day 29. The patients' inflammatory indicators, cytokines, and coagulation indicators are presented in Table 1. Figure 2 illustrates the administration of anti-infective therapy, while Figure 3 depicts the management of coagulation disorder and acute kidney injury (AKI).

## Discussion

Few cases of COVID-19 comorbid with HS have been reported so far. This case report suggested a susceptibility to heatstroke following COVID-19 and presented a persistent and challenging condition to treat, considering the concurrent SARS-CoV-2 infection and disruption of the fibrinolysis coagulation system following HS. The pneumonia and thrombocytopenia entered remission, and consciousness was regained within 2 weeks after HS. However, aggravated infection on day 17 led to deterioration in the patient's condition, and subsequently cerebral hemorrhage developed on day 20. Therefore, managing this case was challenged by persistent inflammation and coagulation-immune disorders.

High fever is frequently observed in both HS and COVID-19.<sup>5</sup> COVID-19 patients with a body temperature above 37 °C, especially those reaching a maximum value of 40 °C, face an increased risk of death. The effectiveness of cooling



**Figure 3** The protocol for the management of coagulation disorder.

**Abbreviations:** CRRT, Continuous renal replacement therapy; RBC, Red blood cell suspension; iv.gtt, intravenous infusion.

therapies for COVID-19 remains controversial. Some studies suggested that managing fever in critically ill adult patients does not improve survival rates. Fever at admission might have a positive role, making cooling therapy unnecessary for all patients.<sup>6</sup> Cooling therapy is the primary treatment for HS. In the case, the patient developed HS after recovering from COVID-19 fever and had a body temperature exceeding 40 °C, which posed a fatal risk. Therefore, implementing cooling therapy was imperative.

The first feature of this case was the persistent infection, especially respiratory infections. The worsening of the infection played a crucial role in the progression of the disease. The risk of infection increases after HS as it can cause microbial toxins to enter the bloodstream from the intestinal mucosa, leading to the release of proinflammatory cytokines and subsequent inflammation.<sup>7</sup> The combination of heat stress and endotoxemia triggers SIRS and a secondary “sepsis-like reaction”, causing coagulation dysfunction, which serves as the underlying mechanism for MODS development.<sup>8</sup> This case involved a complication of HS following COVID-19, leading to immunohypofunction, prolonged severe inflammatory response and multipathogen infection. Bacterial pathogens were primarily present during the acute stage, with fungal infection occurring in the later stage. The infection remained uncontrolled even after the SARS-CoV-2 nucleic acid tested negative. The immune system can continue to be affected even after recovering from acute SARS-CoV-2 infection, with elevated levels of inflammatory cytokines persisting for 8 months.<sup>9,10</sup> SARS-CoV-2 can proliferate and parasitically infect respiratory epithelial cells and immune cells.<sup>11</sup> In the acute stage of COVID-19, proinflammatory reaction was dominant, followed by chronic immunosuppression. During the recovery phase, persistent inflammation-immunosuppression-catabolism syndrome dominated. T cell hypofunction was found in individuals with long COVID-19 and persisted for at least 13 months.<sup>9</sup> When the SIRS induced by HS and SARS-CoV-2 coexists with immune deficiency caused by COVID-19, the infection becomes severe and shows reduced susceptibility to antibiotics. Clinicians should enhance the patient’s immune response, provide comprehensive anti-infective therapy against various pathogens, and take early measures to prevent infection in such cases.

The presence of a coagulation disorder is another distinguishing feature. The direct cause of death was cerebral herniation resulting from cerebral hemorrhage. The presence of coagulopathy and thrombocytopenia throughout the disease may have contributed to the occurrence of cerebral hemorrhage. The heat-induced inflammatory and coagulation responses damage the vascular endothelium and lead to clinically evident microthromboses known as DIC.<sup>3</sup> The imbalance between anticoagulation and fibrinolysis system causes DIC.<sup>12</sup> DIC may occur in the acute stage of HS and platelet abnormalities is an independent risk factor for death in patients with HS.<sup>13</sup> The increase of inflammatory mediators induces endothelial cell injury and impairs the anticoagulation function of endothelial cells. Moreover, sub-cortical bleeding had been observed in COVID-19.<sup>14</sup> Endothelial cells are also targets of the SARS-CoV-2. The vascular endothelium was attacked by the direct viral infection by angiotensin-converting enzyme 2 (ACE2) receptors and that of subsequent induced cytokine storm.<sup>15</sup> In contrast to HS, the virus can cause microthrombosis in microcirculation.<sup>16</sup> Therefore, the administration of early anticoagulant therapy is imperative for HS and COVID-19 patients during the

acute stage. Additionally, similar to HS, the virus can also then lead to platelet decline, increased FDP and D-dimer, and disturb the anticoagulation function.<sup>16</sup> The implementation of blood replacement therapy, including platelet supplementation, is important for optimal patient care.

An extensive cross-talk between inflammation and coagulation was found in the mechanism of severe infection.<sup>17</sup> Pro-inflammatory cytokines are capable of activating the coagulation system and down-regulating physiologic anticoagulant pathways. Activated coagulation proteases also affect specific cellular receptors on inflammatory cells and endothelial cells and thereby modulate the inflammatory response. Neutrophil activation also plays a crucial role in the acute activation of coagulation observed during severe HS.<sup>18</sup> The cytokine storm appears to be a pivotal factor in the potential mechanisms underlying coagulation dysfunction observed in COVID-19.<sup>19</sup> Therefore, the cross-talk between inflammation and coagulation disorders may be exacerbated when COVID-19 in conjunction with HS.

Both HS and COVID-19 can cause acute hepatic failure (AHF) and AKI. Liver injury occurs in 14.8% to 53% of COVID-19 cases, with a high incidence of AKI in hospitalized patients linked to a mortality rate of 20%.<sup>20</sup> Potential mechanisms for AHF and AKI in COVID-19 include cytokine storm, macrophage activation syndrome, lymphopenia endothelial dysfunction, hypercoagulability, ischemic injury, and sepsis.<sup>21,22</sup> Similar mechanisms involving endothelial dysfunction, mitochondrial dysfunction, coagulopathy, SIRS, and ischemic injury have also been implicated in the pathogenesis of HS-induced AHF and AKI.<sup>23,24</sup> The prolonged effects of SARS-CoV-2 necessitated the continuation of CRRT and liver protection therapy in patients with HS. Therefore, the management of multiple organ damage is urgent during a COVID-19 pandemic on hot days.

The treatment approaches exhibit both similarities and distinctions between the two diseases. Early infection prevention and control, reinforcement of immune function, anticoagulation therapy, transfusion of blood products, as well as comprehensive multi-organ protection are all indispensable therapeutic measures. In the early stage of HS, cooling therapy is given greater emphasis, while short-term administration of glucocorticoids may prove efficacious in the anti-inflammatory management of severe COVID-19.<sup>25</sup> When two conditions are present, the aggressive management strategies targeting major issues such as infection, coagulation, immunity, multisystem disorders, and risk prevention can facilitate patient recovery.

## Conclusion

There are similarities between HS and COVID-19 in terms of fever, inflammatory response, coagulation disorders and multiple organ damages. The differentiation of these two illnesses necessitates special attention to the treatment of inflammation and infection, coagulation disorders, and immune dysfunction, as well as continuous organ protection therapy.

## Data Sharing Statement

The datasets used and analyzed during the current study are available from the corresponding author on reasonable request.

## Ethics Approval and Consent to Participate

The experimental protocol was established, according to the ethical guidelines of the Helsinki Declaration and was approved by the Human Ethics Committee of General Hospital of Southern Theater Command of PLA (No. NZLLKZ2023002). Written informed consent was obtained from individual or guardian participants.

## Consent for Publication

All authors reviewed the manuscript and approved the publication. Written informed consent is obtained from the patient's parents/legal guardians for publication of the case report.

## Acknowledgments

Xiao-xiao Ni, Zhe-ying Liu and Yan-yan Zeng are co-first authors for this study.

## Author Contributions

All authors made a significant contribution to the work reported, whether that is in the conception, study design, execution, acquisition of data, analysis and interpretation, or in all these areas; took part in drafting, revising or critically reviewing the article; gave final approval of the version to be published; have agreed on the journal to which the article has been submitted; and agree to be accountable for all aspects of the work.

## Disclosure

The authors declare that they have no competing interests in this work.

## References

1. Ejaz H, Alsrhani A, Zafar A, et al. COVID-19 and comorbidities: deleterious impact on infected patients. *J Infect Public Health*. 2020;1833–1839. doi:10.1016/j.jiph.2020.07.014
2. Robba C, Battaglini D, Pelosi P, et al. Multiple organ dysfunction in SARS-CoV-2: MODS-CoV-2. *Expert Rev Respir Med*. 2020;14(9):865–868. doi:10.1080/17476348.2020.1778470
3. Hifumi T, Kondo Y, Shimizu K, et al. Heat stroke. *J Intensive Care*. 2018;30. doi:10.1186/s40560-018-0298-4
4. National Health Commission of the People's Republic of China. *China's COVID-19 Diagnosis and Treatment Program (Trial Version 10)*. Beijing, China; 2023.
5. Zheng X-Y, Guan W-J, Zhong N-S. Clinical characteristics of COVID-19 in developing countries of western pacific: low case-fatality rate unraveled. *Lancet Reg Health West Pac*. 2021;6:100073.
6. Pasero D, Terragni P. Should we treat fever in critically ill COVID-19 patients? *Minerva Anesthesiol*. 2021;87(11):1168–1170.
7. K-C L, Wang J-Y, Lin S-H, et al. Role of circulating cytokines and chemokines in exertional heatstroke. *Crit Care Med*. 2004;32(2):399–403. doi:10.1097/01.CCM.0000108884.74110.D9
8. Asmara IGY. Diagnosis and Management of Heatstroke. *Acta Med Indones*. 2020;52(1):90–97.
9. Davis HE, McCorkell L, Vogel JM, et al. Long COVID: major findings, mechanisms and recommendations. *Nat Rev Microbiol*. 2023;21(3):133–146. doi:10.1038/s41579-022-00846-2
10. Kim Y-M, Shin E-C. Type I and III interferon responses in SARS-CoV-2 infection. *Exp. Mol. Med*. 2021;53:750–760. doi:10.1038/s12276-021-00592-0
11. Ren X, Wen W, Fan X, et al. COVID-19 immune features revealed by a large-scale single-cell transcriptome atlas. *Cell*. 2021;184(7):1895–1913. doi:10.1016/j.cell.2021.01.053
12. Iba T, Connors JM, Levi M, et al. Heatstroke-induced coagulopathy: biomarkers, mechanistic insights, and patient management. *EClinicalMedicine*. 2022;44:101276. doi:10.1016/j.eclinm.2022.101276
13. Zhong L, Wu M, Ji J, et al. Association Between Platelet Levels on Admission and 90-day Mortality in Patients With Exertional Heatstroke, a 10 Years Cohort Study. *Front Med Lausanne*. 2021;8:716058. doi:10.3389/fmed.2021.716058
14. Coolen T, Lolli V, Sadeghi N, et al. Early postmortem brain MRI findings in COVID-19 non-survivors. *Neurology*. 2020;95(14):e2016–e2027. doi:10.1212/WNL.0000000000010116
15. Alifano M, Alifano P, Forgez P, et al. Renin-angiotensin system at the heart of COVID-19 pandemic. *Biochimie*. 2020;174:30–33. doi:10.1016/j.biochi.2020.04.008
16. Asakura H, Ogawa H. COVID-19-associated coagulopathy and disseminated intravascular coagulation. *Int J Hematol*. 2021;113(1):45–57. doi:10.1007/s12185-020-03029-y
17. Levi M, Poll T. Inflammation and coagulation. *Crit Care Med*. 2010;38(2 Suppl):S26–34. doi:10.1097/CCM.0b013e3181c98d21
18. Huisse M-G, Pease S, Hurtado-Nedelec M, et al. Leukocyte activation: the link between inflammation and coagulation during heatstroke. A study of patients during the 2003 heat wave in Paris. *Crit Care Med*. 2008;36(8):2288–2295. doi:10.1097/CCM.0b013e318180dd43
19. Lazzaroni MG, Piantoni S, Masneri S, et al. Coagulation dysfunction in COVID-19: the interplay between inflammation, viral infection and the coagulation system. *Blood Rev*. 2021;46:100745. doi:10.1016/j.blre.2020.100745
20. Chan L, Chaudhary K, Saha A, et al. AKI in Hospitalized Patients with COVID-19. *J Am Soc Nephrol*. 2021;32(1):151–160. doi:10.1016/j.blre.2020.100745
21. Ahmadian E, Khatibi SMH, Soofiyan SR, et al. Covid-19 and kidney injury: pathophysiology and molecular mechanisms. *Rev Med Virol*. 2021;31(3):e2176. doi:10.1002/rmv.2176
22. Ali FEM, El-Aziz MKA, Ali MM, et al. COVID-19 and hepatic injury: cellular and molecular mechanisms in diverse liver cells. *World J Gastroenterol*. 2023;29(3):425–449. doi:10.3748/wjg.v29.i3.425
23. Wang F, Zhang Y, Li J, et al. The pathogenesis and therapeutic strategies of heat stroke-induced liver injury. *Crit Care Med*. 2022;26(1):391. doi:10.1186/s13054-022-04273-w
24. Goto H, Kinoshita M, Oshim N. Heatstroke-induced acute kidney injury and the innate immune system. *Front Med Lausanne*. 2023;10:1250457. doi:10.3389/fmed.2023.1250457
25. Alexaki VI, Henneicke H. The Role of Glucocorticoids in the Management of COVID-19. *Horm Metab Res*. 2021;53(1):9–15.

### International Medical Case Reports Journal

Dovepress

### Publish your work in this journal

The International Medical Case Reports Journal is an international, peer-reviewed open-access journal publishing original case reports from all medical specialties. Previously unpublished medical posters are also accepted relating to any area of clinical or preclinical science. Submissions should not normally exceed 2,000 words or 4 published pages including figures, diagrams and references. The manuscript management system is completely online and includes a very quick and fair peer-review system, which is all easy to use. Visit <http://www.dovepress.com/testimonials.php> to read real quotes from published authors.

Submit your manuscript here: <https://www.dovepress.com/international-medical-case-reports-journal-journal>