

Neurovascular Adverse Effects of Sars-Cov-2 Vaccination

Leonidas D Panos^{1,2}, Panagiotis Bargiotas², Georgios Hadjigeorgiou², Georgios D Panos^{3,4}

¹Department of Neurology, Bern University Hospital « Inselspital », Bern, Switzerland; ²Department of Neurology, School of Medicine, University of Cyprus, Nicosia, Cyprus; ³Department of Ophthalmology, Queen's Medical Centre, Nottingham University Hospitals (NUH), Nottingham, U.K.; ⁴Division of Ophthalmology and Visual Sciences, School of Medicine, University of Nottingham, Nottingham, U.K

Correspondence: Leonidas D Panos, Department of Neurology, Bern University Hospital "Inselspital", Freiburgstrasse 16, 3010, Bern, Switzerland, Tel +41 31 632 70 00, Email ldpanos@yahoo.gr; Georgios D Panos, Department of Ophthalmology, Queen's Medical Centre, NUH, Derby Road, Lenton, Nottingham, NG7, 2UH, UK, Tel +44 115 924 9924, Email gpanos@gmail.com

Abstract: The global deployment of SARS-CoV-2 vaccines has been pivotal in curbing the COVID-19 pandemic, reducing morbidity and mortality associated with the virus. While most of these vaccines have demonstrated high efficacy and overall safety, emerging reports have highlighted potential neurovascular adverse effects, albeit uncommon, associated with these vaccinations. This review aims to assess and summarize the current knowledge on the neurovascular complications arising post-SARS-CoV-2 vaccination. We conducted an extensive literature review, focusing on clinical studies and case reports to identify reported neurovascular events, such as ischemic stroke, cerebral sinus venous thrombosis, intracerebral hemorrhage, pituitary apoplexy and primary CNS angiitis. Despite the relative rarity of these events, their impact on affected individuals underscores the importance of ongoing surveillance, early detection, and management strategies. We aim to provide healthcare professionals with the latest evidence on neurovascular adverse effects, facilitating informed decision-making in the context of SARS-CoV-2 vaccination programs. Furthermore, we highlight areas requiring further research to understand the pathophysiology of these adverse events better and to develop targeted prevention and treatment strategies.

Keywords: neurovascular adverse effects, COVID-19, vaccines, SARS-CoV-2, coronavirus, pandemic, BNT162b2, mRNA-1273, ChAdOx1, NVX-CoV2373

Introduction

The COVID-19 pandemic, caused by the novel coronavirus SARS-CoV-2, has been a defining global health crisis of our time.¹ In response, the development and global deployment of COVID-19 vaccines have been pivotal in combating the spread of the virus. Representing a monumental achievement in the fields of medicine and biotechnology, these vaccines have been developed using various innovative platforms. Messenger RNA (mRNA) vaccines, like BNT162b2 (Comirnaty, Pfizer-BioNTech) and mRNA-1273 (SpikeVax, Moderna Inc.), use mRNA to teach cells to create the spike protein that prompts an immune response.² Viral vector vaccines, including ChAdOx1-S/ nCoV-19 (Vaxzevria, Oxford-AstraZeneca), Ad26.COV2.S (Jcovden, Johnson & Johnson/Janssen), and Gam-Covid-Vac (Sputnik V) employ a different virus to deliver genetic material.² Additionally, inactivated or protein subunit vaccines, such as PiCoVacc (CoronaVac, Sinovac) and NVX-CoV2373 (Covovax, Novavax) use a version of the virus that has been killed or parts of the virus like the spike protein.²

The widespread administration of these vaccines has significantly altered the course of the pandemic. They have been instrumental in reducing the rates of infection, severe illness, hospitalisation and mortality.³⁻⁵ This large-scale vaccination effort has not only illuminated their immediate efficacy and safety but also offered insights into their long-term impact on public health. Billions of doses administered globally have helped societies to gradually reopen and have reduced the burden on healthcare system.⁶ Furthermore, the adaptability of these vaccines in addressing emerging variants underscores the agility and responsiveness of modern vaccine technology.^{7,8}

However, as with all medical interventions, COVID-19 vaccinations come with potential side effects. While the majority are mild and transient, such as pain at the injection site, fatigue, headache, muscle pain, chills, fever, and nausea, there has been a focus on understanding the rare but significant adverse events.⁹ Serious side effects like anaphylaxis, myocarditis and pericarditis (particularly after mRNA vaccines in younger males), as well as thrombosis with thrombocytopenia syndrome (TTS) associated with viral vector vaccines, though rare, are areas of ongoing research and monitoring.^{10–13}

Among these concerns are the neurovascular complications linked to these vaccines. These complications, though infrequent, raise crucial questions about the underlying mechanisms and the predisposing factors for such adverse reactions. Vaccine-Induced Thrombotic Thrombocytopenia (VITT) and Autoimmune/Autoinflammatory Syndrome Induced by Adjuvants (ASIA) are considered potential associated conditions.^{14,15} The pathophysiology of VITT is discussed separately in the manuscript. ASIA includes a spectrum of autoimmune and inflammatory responses but remains controversial and not universally recognized due to debates over the causal role of adjuvants and the lack of clear diagnostic criteria.¹⁵

This review aims to explore these neurovascular complications associated with COVID-19 vaccinations. It will examine the types of vaccines, the reported neurovascular events, their potential mechanisms, and implications for healthcare decision-making.

Ischemic Stroke

In assessing the relationship between COVID-19 vaccination and the incidence of ischemic stroke, a range of studies conducted globally employing various methodologies and vaccine types are summarized in [Table 1](#).

Komarek et al conducted an extensive prospective study at Innsbruck University Hospital, Austria, involving 572 patients.¹⁶ This research assessed both mRNA and adenovirus-vector vaccines, finding no significant association between COVID-19 vaccination and the incidence of stroke, thus offering reassurance about vaccine safety in the context of ischemic stroke.

In Hong Kong, a “self-controlled case series study” involving 4,492,167 individuals, which represents 65.2% of the eligible population, found no increased risk of thromboembolic events for either BNT162b2 or PiCoVacc vaccines but noted an increased risk of hemorrhagic events associated with the BNT162b2 vaccine.²⁷ This study’s observation period was approximately seven months, focusing only on incident cases and not examining the risk of recurrent thromboembolic events and hemorrhagic stroke.

A large-scale retrospective study in Israel analyzed medical records from over 1.5 million individuals receiving monovalent and bivalent BNT162b2 mRNA booster doses and observed a slight increase in ischemic rates for the second monovalent booster but concluded no significant overall association between booster vaccination and ischemic stroke risk, suggesting the vaccines’ protective benefits likely outweigh any minimal risk.¹⁷

Further supporting vaccine safety, a retrospective cohort study involving 236,785 patients aged 65 and older in the USA found no increased risk of ischemic stroke with BNT162b2 or mRNA-1273 boosters, emphasizing the vaccines’ efficacy and safety in older adults.¹⁹ Additionally, a retrospective cohort analysis in the United States involved 148,066 patients aged 65 and over who received either the BNT162b2 bivalent, mRNA-1273 bivalent, or BNT162b2/mRNA-1273 monovalent COVID-19 booster vaccine.²⁶ This analysis, focusing on ischemic stroke encounters 1–21 and 22–42 days after vaccination, found no significant difference in stroke risk between BNT162b2 bivalent and mRNA-1273 bivalent cohorts, with a lower risk observed in the BNT162b2 bivalent cohort compared to the monovalent cohorts. Similarly, an English study examined 6882 admissions with ischemic stroke in individuals aged 50 years and older who were hospitalized with stroke after receiving a bivalent COVID-19 booster dose (BNT162b2 or mRNA-1273).²⁴ The study used the self-controlled case series method and found no evidence of an increased risk of stroke in the 21 days immediately after vaccination with either of the two mRNA COVID-19 bivalent vaccines. Limitation of the above studies is the exclusion of younger adults.

A French study, employing a self-controlled case series design and including 73,325 adults younger than 75 years hospitalized for cardiovascular events, evaluated the risk of myocardial infarction, stroke, and pulmonary embolism following vaccination with Pfizer-BioNTech’s BNT162b2, Moderna’s mRNA-1273, Janssen’s Ad26.COV2.S, and Oxford-AstraZeneca’s ChAdOx1-S/nCoV-19.²² This study found no association between vaccination and ischemic stroke events, though it noted an increased risk of acute myocardial infarction and pulmonary embolism after the first dose of the Oxford-AstraZeneca’s ChAdOx1-S/nCoV-19 vaccine and a potential risk of myocardial infarction with the Janssen’s Ad26.COV2.S vaccine.

Table 1 Summary of Studies About Sars-Cov-2-Vaccination and Ischemic Stroke

Authors	Study Method	Population	Age	Vaccination	Vaccine Dose	Results
Komarek et al ¹⁶	Single center prospective cohort study	572 participants Innsbruck University Hospital, Austria	≥ 18 years	SARS-CoV-2 vaccine (mRNA and adenovirus-vector)	1st, 2nd, 3rd	No significant association between vaccination and ischemic stroke or TIA
Yamin et al ¹⁷	Self controlled case series	1,073,110 individuals (Israel)	≥ 12 years	BNT162b2 mRNA COVID-19 vaccine boosters	Monovalent and bivalent first, second and third booster	No significant association; higher ischemic rates only for the second monovalent booster
El Naamani et al ¹⁸	Single center retrospective study	203 COVID-19 positive stroke patients (Thomas Jefferson University Hospital)	≥ 50 years	Pfizer, Johnson & Johnson, Moderna	Fully vaccinated (2 to 4 doses)	Lower morbidity and mortality among vaccinated stroke patients at discharge
Gorenflo et al ¹⁹	Retrospective cohort study	236,785 patients in USA	≥ 65 years	Pfizer and Moderna	Bivalent and monovalent boosters	No increased risk of ischemic stroke
Torabi et al ²⁰	Self-controlled case series study	2,062,144 in Wales	≥ 65 years	Pfizer-BioNTech, Oxford-AstraZeneca, Moderna	1st, 2nd, booster doses	Increased risk of arterial thrombosis and stroke post ChAdOx1 and post-booster doses of mRNA vaccines
Hippisley-Cox et al ²¹	Self-controlled case series study	>29 million people	≥ 16 years	Oxford-AstraZeneca, Pfizer-BioNTech	1st dose	Slightly increased risk for arterial thromboembolism and ischemic stroke post BNT162b2, thrombocytopenia and venous and arterial thromboembolism after AstraZeneca
Botton et al ²²	Self-controlled case series study	73,325 adults	<75 years	Pfizer-BioNTech, Moderna, Janssen, Oxford-AstraZeneca	1st and 2nd Dose	No association with ischemic stroke; increased risk of AMI and PE post first dose of ChAdOx1
Dag Berild et al ²³	Self-controlled case series study	265,339 patients (Norway, Finland, Denmark)	All age groups	Oxford-AstraZeneca Pfizer-BioNTech, Moderna	1st or 2nd Dose	Elevated risk for ischemic stroke post vaccination for all 3 vaccines

(Continued)

Table 1 (Continued).

Authors	Study Method	Population	Age	Vaccination	Vaccine Dose	Results
Andrews et al ²⁴	Self-controlled case series study	14.6 Million people	>50 years	Pfizer-BioNTech, Moderna	Bivalent booster	No increased risk of stroke post vaccination
Ihle-Hansen et al ²⁵	Prospectively collected cohort	4,139,888 in Norway	≥ 18 years	mRNA SARS-CoV-2 vaccines	1st, 2nd, 3rd dose	No increased risk of ischemic stroke
Gorenflo et al ²⁶	Retrospective cohort analysis	148,066 in the USA	≥ 65 years	Pfizer and Moderna	Bivalent vs monovalent boosters	Pfizer und Moderna bivalent booster with lower risk for ischemic stroke than monovalent boosters.
Chui et al ²⁷	Self-controlled case series study	4,492,167 individuals in Hong Kong	≥ 16 years	BNT162b2, CoronaVac	Two doses	Incidence of thromboembolic event or hemorrhagic stroke following vaccination is lower than that among SARS CoV-2 test positive cases
Rojko et al ²⁸	Prospective study	28 PFO-associated stroke patients in Slovenia	21–70 years	Oxford-AstraZeneca Pfizer-BioNTech, Moderna	At least one dose	Temporal coincidence of vaccination and stroke
Kim et al ²⁹	Retrospective cohort study	231,037 COVID-19 diagnosed patients	≥18 years	mRNA or viral vector vaccine	2 Doses	Lower risks of AMI and ischemic stroke in fully vaccinated Covid-19 positive patients compared to unvaccinated
Dorajoo et al ³⁰	Self-controlled case series study	5.5 million in Singapore	≥5 years	mRNA vaccines	1st, 2nd and 3rd Dosis	No elevated risks for ischemic stroke, but elevated risk for myocarditis/pericarditis, appendicitis and cerebral venous thrombosis
Lopez-Mena et al ³¹	Retrospective analysis	52 patients with ischemic stroke in Mexico	>18 years	mRNA or viral vector vaccines	1st, 2nd Dosis	Ischemic Stroke after Vaccination predominantly due to atherosclerosis
Hidayat et al ³²	Case series	3 patients in Indonesia	>60 years	CoronaVac	1st, 2nd Dosis	Ischemic Stroke after Vaccination predominantly due to atherosclerosis
Deuschl et al ⁴⁰	Retrospective analysis	137 COVID patients in Austria and Germany	Not mentioned	mRNA or viral vector vaccines	Not mentioned	No impact of Vaccination on angiographic findings and clinical outcomes of thrombectomy in COVID patients.

A retrospective cohort study in South Korea investigated 231,037 patients comparing the incidence of acute myocardial infarction (AMI) and ischemic stroke in unvaccinated versus fully vaccinated (two doses of mRNA or viral vector vaccine) patients.²⁹ The study found significantly lower risks of AMI and ischemic stroke in fully vaccinated individuals for the median follow-up duration of 3 months, indicating a considerable reduction in the risk of these events among the vaccinated group compared to the unvaccinated one. Limitations of this study include potential diagnostic inaccuracies due to the use of diagnosis codes for reimbursement and possible unobserved bias due to imbalances in patient characteristics by vaccination status. Similarly, a retrospective analysis at Thomas Jefferson University Hospital, Philadelphia, compared 203 vaccinated and unvaccinated COVID-19 positive stroke patients.¹⁸ This study highlighted lower morbidity and mortality among vaccinated individuals at discharge, underscoring the vaccines' role in mitigating severe outcomes in stroke patients.

Other studies, including a nationwide retrospective cohort study in Norway involving records of 4,139,888 individuals after receiving the first, second, or third dose of any mRNA SARS-CoV-2 vaccines, and a self-controlled case series study in Hong Kong, have further corroborated the absence of a significant increase in ischemic stroke risk post-vaccination.^{25,27} However, key limitations include the potential for undetected subgroups with an increased stroke risk within the large sample and a healthy vaccinee bias. Moreover, the Singapore study, a nationwide post-market safety surveillance of COVID-19 mRNA vaccines that included vaccine recipients aged 5 years and older, found no elevated risks for ischemic stroke.³⁰ Instead, it noted elevated risks for myocarditis/pericarditis, appendicitis, and cerebral venous thrombosis (CVT) post-vaccination.

Conversely, a self-controlled case series in Wales noted an increased risk of Immune Thrombocytopenia (ITP) and arterial thrombosis after the first dose of the ChAdOx1 vaccine, as well as an increased risk of arterial thrombosis and stroke following the second dose and post-booster doses of mRNA vaccines.²⁰ However, the overall risk appeared low. The study indicates that both COVID-19 vaccination and infection carry measurable risks, particularly for Venous Thromboembolism (VTE) and hemorrhagic events, with a greater risk observed post-infection compared to post-vaccination.

An English study focusing on the first doses of Oxford-AstraZeneca and Pfizer-BioNTech vaccines observed slightly increased events of blood and circulatory system disorders leading to either hospitalization or death shortly after the initial doses of the ChAdOx1 nCoV-19 and BNT162b2 mRNA vaccines.²¹ Specifically, it showed slightly increased risks for arterial thromboembolism and ischemic stroke after the BNT162b2 vaccine up to 21 days after vaccination. However, the risks associated with the vaccine were four times lower compared to those following a SARS-CoV-2 infection.

A Nordic study, including 265,339 patients from Norway, Finland, and Denmark, who had hospital contacts for cardiovascular or cerebrovascular diseases, showed a slightly elevated risk for cerebrovascular disease, including ischemic stroke, in the 28 days following vaccination.²³ Specifically, the relative risk (RR) was 1.32 for ChAdOx1 nCoV-19/AZD1222 (AstraZeneca), 1.09 for BNT162b2 (Pfizer-BioNTech), and 1.21 for mRNA-1273 (Moderna). Notably, high rates were observed for cerebral venous thrombosis (CVT) and thrombocytopenia following the ChAdOx1 nCoV-19/AZD1222 vaccination.

In a prospective study conducted in Slovenia, PFO-associated strokes were investigated during COVID-19 vaccination.²⁸ Of the 28 patients presented with PFO-associated stroke, 12 (42.9%) were vaccinated. Stroke occurred within 35 days post-vaccination in six patients. The study concludes a temporal coincidence of vaccination and stroke but highlights that a cause-effect relationship is only hypothetical. Indeed, three of the 12 patients were also on hormone therapy/contraceptives, which could provide an alternative explanation for PFO-associated stroke.

To our knowledge, there is only one case report of spinal cord ischemia following COVID-19 vaccination. A 59-year-old male in Greece developed acute-onset right lower limb weakness and abdominal pain, which progressed to paraplegia 20 days after receiving the BNT162b2 mRNA COVID-19 vaccine.³³ MRI revealed non-contiguous foci of T2 hyperintensities from the T6 level to the conus medullaris, indicative of spinal cord ischemia. Despite treatment, including antiplatelet therapy, the patient's condition showed limited improvement, with an American Spinal Injury Association (ASIA) impairment scale improvement from grade B to grade C over 8 months.

Pathophysiology and Diagnosis

Laboratory results for patients with arterial stroke mirrored those with CVST, including thrombocytopenia, elevated D-dimer levels, reduced fibrinogen, and the presence of anti-PF4 IgG antibodies.³⁴ These similarities suggest a common pathological pathway related to vaccine-induced coagulopathy.

However, some patients do not exhibit these paraclinical findings.

Several studies have demonstrated that endothelial function assessed by flow mediated vasodilation (FMD) staff is a surrogate marker for organ damage and cardiovascular events. In a Japanese study involving a total of 23 vaccinated people, FMD was significantly reduced two weeks after the second dose of the BNT162b2 mRNA COVID-19 vaccine compared to pre-vaccination levels. However, FMD returned to baseline levels six months post-vaccination.³⁵

Moreover, similarly to Sars-cov-2 virus though much rarer Sars-cov2-vaccinations could induce blood–brain barrier and choroid plexus barrier impairments and vascular inflammation in mice, as well as changes in perivascular astrocytes, neurons and microglia, thus impairing the neurovascular unit.^{36,37}

Interestingly, pro-atherosclerotic risk factors and a history of previous ischemic strokes are common among patients without evidence of coagulopathy.

Acute ischemic stroke observed after COVID-19 vaccines are commonly due to large artery atherosclerosis (34.9%), as has been reported in Mexico- and Indonesia-based studies.^{31,32} Therefore, it is hypothesized that these events may also be attributed to the underlying conditions of vaccine recipients, such as hypertension, diabetes mellitus, smoking, and dyslipidemia.²² Nonetheless, it could be assumed that the vaccine administration may have further predisposed these individuals to such outcomes.

Symptoms

Large retrospective studies showed that around two-thirds of arterial events occurred in women, with nearly 90% experiencing an anterior circulation stroke, particularly in the middle cerebral artery.³⁸ Motor deficits were the most prevalent symptom, seen in 75% of cases, followed by language impairments.³⁹

Therapy

In patients with suspicion of vaccine-induced immune thrombotic thrombocytopenia (VITT), thrombolysis is usually contraindicated due to low platelet count. Mechanical thrombectomy (MER) should be considered in large vessel occlusion. High-dose IVIG should be administered immediately. Alternative anticoagulation to heparin should be initiated as soon as possible after stroke onset, unless significant hemorrhagic transformation has occurred. Platelet transfusion is contraindicated and should be considered only in cases of severe hemorrhagic complications. Due to the hypercoagulable state in VITT, restenosis or reocclusion of the revascularized artery is possible, making angiographic surveillance after the procedure advisable.³⁴

In a retrospective analysis of 137 patients with COVID-19 treated with mechanical thrombectomy for acute ischemic stroke at 20 tertiary care centers in Austria and Germany COVID-19 vaccination did not impact angiographic or clinical outcomes for COVID-19–positive patients, with acute ischemic stroke undergoing mechanical thrombectomy. However, the presence of acute COVID-19 infection was associated with worse outcomes.⁴⁰

Across diverse populations and vaccine types, the overwhelming evidence suggests that the risk of ischemic stroke post-vaccination is not significantly elevated. While some studies identified minimal increases in risk for specific vaccine doses or types, these findings must be contextualized within the broader benefits of COVID-19 vaccination, including reduced risk of severe disease, hospitalization, neurovascular side effects of COVID, and death. Limitations across these studies, including retrospective designs, potential under-reporting, lack of unvaccinated control groups and exclusion of younger patients in some analyses, necessitate cautious interpretation of results. Nonetheless, the consistent lack of a significant association between COVID-19 vaccination and increased ischemic stroke risk provides strong support for the continued use of these vaccines in public health efforts against the pandemic. While the Self-Controlled Case Series (SCCS) analysis inherently adjusts for constant, individual-specific factors, there is a possibility of potential time-varying covariates such as body weight, lifestyle factors, and COVID-19 infection which increase the risks over time, especially among the oldest participants.

Cerebral Venous Sinus Thrombosis

A series of studies have delved into this issue, providing valuable insights into the incidence of CVST following vaccination with different COVID-19 vaccines. The most important studies are summarised in [Table 2](#).

Table 2 Summary of Studies Examining Cerebral Venous Sinus Thrombosis Following COVID-19 Vaccination

Authors	Study Method	Population	Age	Vaccination	Vaccine Dose	Results
Hippisley-Cox et al ²¹	Self-controlled case series	>29 million in England	≥16 years	Oxford-AstraZeneca, Pfizer-BioNTech	1st dose	Increased risk of CVST after first dose of both vaccines. IRR: 4.01 for ChAdOx1 nCoV-19 at 8–14 days, 3.58 for BNT162b2 at 15–21 days.
Sanchez Van Kammen et al ⁴¹	International registry, retro- and prospective collected	116 patients with CVST	All age groups	All Vaccinations	1st Dose	TTS in 67.2% of CVST patients, 97% of TTS received ChAdOx1 nCoV-19. High in-hospital mortality rate for TTS group.
Whiteley et al ⁴²	Whole Population Cohort Study, Reporting of studies Conducted using Observational Routinely collected Data (RECORD)	46 million adults	All age groups	ChAdOx1-S, BNT162b2	1st dose	Increased rates of CVST and thrombocytopenia after ChAdOx1-S. for people >70 years. No significant increase for BNT162b2.
Kerr et al ⁴³	Self-controlled case series	11.6 million in England, Scotland, Wales	>16years	Oxford-AstraZeneca, Pfizer-BioNTech	1st Dose	Increased risk of CVST after vaccination with ChAdOx1 nCoV-19, but not after BNT162b2.
McKeigue et al ⁴⁴	Case-crossover study	6,894,008 vaccination doses, 50 CVST cases	All age groups	AstraZeneca, Pfizer-BioNTech, Moderna	1st and 2nd doses	Causal association between CVT and AstraZeneca vaccine
Van de Munckhof et al ⁴⁵	International observational study	More than 12 billion vaccination doses, 228 CVST cases	All age groups	All vaccines	Not specified	Lower in-hospital mortality rate in middle-income countries compared to high-income countries for CVST-VITT cases.

A self-controlled case series in England involving over 29 million individuals aged ≥ 16 years vaccinated with either the Oxford-AstraZeneca or Pfizer-BioNTech COVID-19 vaccines found an increased risk of CVST after the first dose of both vaccines.²¹ Despite this increased risk, it was significantly lower than the risk associated with SARS-CoV-2 infection itself.

Further analysis from another English study assessing risks from 46 million adults indicated increased rates of CVST and thrombocytopenia post-ChAdOx1-S vaccination, particularly in those under 70, albeit these risks were deemed small relative to the vaccine's benefits.⁴² This contrasts with the findings for the Pfizer-BioNTech vaccine, where no significant increase in thrombotic events was observed. A pooled analysis across the UK echoed these findings, observing a slight increase in CVST incidence following the AstraZeneca vaccine, a pattern not seen with the Pfizer-BioNTech vaccine.⁴³ Similarly, a case-crossover study from Scotland evaluating CVT cases post-vaccination supported a causal link between CVST and the AstraZeneca vaccine, with incidence rates suggesting a higher risk following this vaccine compared to Pfizer-BioNTech and Moderna.⁴⁴

Another multicenter observational case series study involving 116 patients with CVST identified a substantial proportion (67.2%) who developed thrombosis with thrombocytopenia syndrome (TTS), primarily after receiving the Oxford-AstraZeneca vaccine (97% of CVST-TTS cases).⁴¹ Patients with CVST-TTS often presented with comatose states (24%), had intracerebral hemorrhage (68%), and a high rate of concomitant thromboembolism (36%). The in-hospital mortality rate was significantly high at 47% for the TTS group. The study highlighted a distinct clinical profile and high mortality rate in patients with CVST post-vaccination meeting the criteria for TTS.

Comparative research between middle-income (MIC) and high-income countries (HIC) reported CVST cases post-vaccination, noting a lower in-hospital mortality rate in MICs.⁴⁵ This study also pointed out the infrequent testing for anti-PF4 antibodies in MICs, a key diagnostic marker for VITT, suggesting variations in diagnostic and management practices across different settings.

Common across these studies is the observation of an increased risk of CVST following vaccination, particularly with the Oxford-AstraZeneca vaccine. This research underscored a unique clinical pattern and a significant mortality risk among patients who developed CVST following vaccination and fulfilled the criteria for TTS. The findings underscore the need for vigilance and prompt recognition of symptoms associated with CVST to mitigate risks effectively.

Limitations across these studies include potential under-reporting, reliance on coded healthcare data, and the inherent challenges in measuring rare events in large populations. Furthermore, the variation in diagnostic criteria and management practices, especially concerning the testing for anti-PF4 antibodies, highlights the need for standardized approaches in identifying and treating VITT. Despite these challenges, the concerted effort to understand and mitigate vaccine-related adverse events continues to be crucial in navigating the path forward in the COVID-19 pandemic.

Pathophysiology

The development of Vaccine-Induced Immune Thrombotic Thrombocytopenia (VITT) following the administration of the ChAdOx1-S vaccine is believed to be associated with the generation of IgG antibodies targeting Platelet Factor 4 (PF4). This mechanism is reminiscent of the pathophysiological process observed in Heparin-Induced Thrombocytopenia (HIT), where PF4 forms complexes with heparin, triggering an immune response in certain individuals.^{46,47} These immune complexes activate platelets via Fc γ RIIIa receptors, leading to platelet activation and aggregation, followed by the release of procoagulant substances that ultimately result in thrombosis. VITT presents a similar immune response, wherein antibodies specifically recognize PF4 regions, initiating platelet activation.⁴⁷ A "two-hit" hypothesis suggests that vaccine components may modify PF4, creating new antigens, while a systemic inflammatory response heightens the production of autoantibodies, particularly with adenoviral vector vaccines.⁴⁸

A study disclosed that 9.8% of healthy individuals immunized against COVID-19 developed IgG antibodies targeting the PF4 complex within two weeks post-vaccination, without leading to platelet activation, indicating a potential asymptomatic seroconversion.⁴⁹ This finding suggests that a minor fraction of vaccinated individuals may produce PF4 complex antibodies, with a smaller subset possibly developing VITT, likely due to genetic predispositions that favor the production of such antibodies and, consequently, VITT.

Regarding mRNA vaccines, research involving nonhuman primates has shown that they elicit a T helper (Th)1 immune response, characterized by the production of cytokines such as interferon-gamma, tumor necrosis factor (TNF),

and interleukin-2 (IL-2).⁵⁰ Typically, endothelial cells regulate thrombogenic states, influenced by cytokines. TNF, among others, promotes the expression of tissue factors that initiate coagulation. This implies that the Th1 response induced by mRNA vaccines could be linked to prothrombotic conditions.⁵¹

Symptoms

Patients experiencing CVST following vaccination with adenoviral vector vaccines like ChAdOx1-S or Ad26.COV2.S reported a range of neurological symptoms. Initially, some only showed minor signs like headaches, while others exhibited severe neurological effects, including vertigo, vision loss, speech difficulties, seizures, paralysis, behavioral changes, and consciousness alterations.^{46,52–54} Interestingly, the symptoms of CVST were similar regardless of whether patients received mRNA or adenovirus-based vaccines, with common complaints including persistent headaches, fatigue, vomiting, and motor issues.^{46,55–57}

Diagnosis

Diagnosing VITT requires the identification of consumptive coagulopathy and is characterized by several key features: thrombocytopenia, elevated D-dimer levels, hypofibrinogenemia, and high-titer anti-PF4 IgG antibodies.⁵⁸ The UK Hematology Expert Group has delineated five criteria for a definitive diagnosis, which include the onset of symptoms 5 to 30 days post-vaccination, the presence of thrombosis, confirmation of thrombocytopenia, a positive anti-PF4 antibody test, and significantly increased D-dimer levels.⁵⁹ Diagnostic assays for VITT, which are adapted from those used in Heparin-Induced Thrombocytopenia (HIT) tests, primarily utilize ELISA to detect anti-PF4 antibodies, reflecting the similarities in the pathobiology between VITT and HIT.

A recent study evaluated the effectiveness of competitive anti-PF4 enzyme immunoassays (EIA) in distinguishing VITT from HIT. Using F(ab')₂ fragments of monoclonal anti-PF4 antibodies (1E12, 1C12, and 2E1). The researchers assessed their ability to inhibit binding of human VITT and HIT antibodies to PF4. The antibody 1E12 showed strong inhibition of VITT IgG binding (93%) but not HIT antibodies (6%), whereas 1C12 and 2E1 inhibited both VITT and HIT antibodies. Thus, a competitive anti-PF4 EIA with 1E12 can assist in confirming VITT diagnosis and distinguishing it from HIT.⁶⁰

When ELISA results are negative, functional assays, specifically platelet activation assays, serve as alternative diagnostic tests.⁵⁸ These assays are notably effective for detecting platelet-activating antibodies and have demonstrated high sensitivity and specificity for VITT.⁵⁸ A positive outcome from a heparin-free platelet activation test, coupled with reduced activation in a test with low heparin levels, indicates that platelet activation is mediated through a pathway not involving heparin.⁵⁸

In this context, promptly recognizing CVST following vaccination is essential. Healthcare professionals and individuals should be alert to any neurological symptoms, even subtle ones that manifest particularly within 48 hours post-vaccination and they should be aware of the potential for severe neurological adverse events. Thrombocytopenia serves as a critical warning sign, acting as a primary indicator of this condition. Comprehensive blood analysis and imaging are pivotal in differentiating between typical vaccine reactions and significant neurological adverse events. VITT cases often exhibit variable levels of thrombocytopenia, increased D-dimer, and occasionally, prolonged clotting times, requiring continuous and meticulous monitoring.^{54,61–63} In addition to detailed blood work, targeted imaging studies are vital for diagnosis. Reports have shown that CVST typically affects the sigmoid and transverse sinuses and is associated with hemorrhages in the cerebellum and frontal brain regions.^{46,62,64,65} Furthermore, VITT-related thrombosis can extend beyond the cerebral veins to other venous areas, such as the superior ophthalmic vein, and even to arteries, resulting in arterial events.⁶⁶

Therapy

For treating VITT, reports highlight positive outcomes using therapies such as intravenous immunoglobulin (IVIG) and anticoagulation with heparin alternatives.^{52,67,68} IVIG has shown efficacy in stopping platelet activation and quickly raising platelet counts in conditions like spontaneous HIT, which resembles VITT in its pathophysiology, characterized by autoimmune-activated platelets due to heparin-independent antibodies without heparin exposure.⁶⁹ IVIG's action is believed to involve FcγRIIIa receptor inhibition through IgG.⁶⁹ Research showed that platelet activation could be halted by an FcγRIIIa-blocking antibody and high IgG levels.⁴⁹

Endovascular treatment (EVT) should be considered, especially for patients with extensive thrombosis or clinical and/or radiological deterioration. In the largest cohort study, 18 out of 136 CVST-VITT cases underwent EVT (92% aspiration and/or stent retrieval, 8% local thrombolysis), which resulted in improved local blood flow in 83% of cases. Survivors largely attained functional independence, showcasing EVT's potential benefits despite a high mortality rate. Moreover, EVT was not linked to an increase in mortality rates.⁷⁰

Prognosis

A retrospective study conducted in Netherlands from April 2021 to July 2021 examined the outcomes of patients with cerebral venous thrombosis (CVT) due to vaccine-induced immune thrombotic thrombocytopenia (VITT) post-SARS-CoV-2 vaccination.⁷¹ Out of 107 CVT-VITT cases, 43 (40%) died during initial hospitalization. For the 64 survivors, follow-up was available for 60, showing a median age of 40 years, with 75% being women. After a median follow-up of 150 days, functional independence (modified Rankin Scale (mRS) score of 0 to 2) was achieved by 88% of patients, with two deaths reported during follow-up and one major bleeding event, indicating low mortality and new thrombotic events post-discharge.

Hemorrhagic Complications

Intracerebral hemorrhage (ICH) is a significant health concern, and there have been infrequent reports of ICH following COVID-19 vaccination.

One noteworthy study conducted in Hong Kong involved a substantial population of 4,492,167 individuals, representing 65.2% of the eligible population, with 60.1% having received two doses of the COVID-19 vaccines, either Pfizer-BioNTech BNT162b2 or CoronaVac.²⁷ This is the only self-controlled case series study that identified an increased risk of hemorrhagic events associated with the BNT162b2 vaccine, particularly 14–27 days after the first dose (adjusted IRR of 2.53) and 0–13 days after the second dose (adjusted IRR of 2.69). A limitation highlighted by the study is the Self-Controlled Case Series (SCCS) model's inability to adjust for potential time-varying covariates, such as body weight, lifestyle factors, and COVID-19 infection.

In Japan, two cases of ruptured vertebral artery dissecting aneurysm (VADA) in the V4 segment one and seven days following mRNA COVID-19 vaccination were reported.⁷² The patients, following vaccination with either the Moderna mRNA-1273 or Pfizer-BioNTech BNT162b2 vaccine experienced good recovery, being discharged with a modified Rankin Scale (mRS) score of 1.

Additionally, three cases of intracranial aneurysm rupture within three days post-administration of the Pfizer-BioNTech BNT162b2 vaccine were documented.⁷³ These cases involved intracranial artery segments (bifurcation of the middle cerebral artery, internal carotid-posterior communicating artery, and anterior communicating artery), with symptoms appearing from 0 to 3 days post-vaccination, leading to severe headaches. Treatment outcomes were favorable, with modified Rankin scale scores ranging from 0 to 2.

Another reported case involved a 56-year-old woman who suffered an intracerebral hemorrhage in the left temporal lobe extending into the intraventricular space immediately after receiving the Pfizer-BioNTech COVID-19 vaccine.⁷⁴ Despite surgical efforts to clip a ruptured aneurysm, the patient unfortunately passed away on the second postoperative day.

Beyond ICH, there are rare instances of spinal hemorrhage following COVID-19 vaccination. One case describes a spinal epidural hematoma between T10-L1 in an 80-year-old male after the first dose of the Sputnik V COVID-19 vaccine.⁷⁵ Despite surgical intervention, there was no clinical improvement one month post-surgery. Another case, involved a 67-year-old female who developed a spontaneous intramedullary hematoma after her first dose of the Sinopharm COVID-19 vaccine extending from the brainstem to T2.⁷⁶ Initial treatment including plasmapheresis and high-dose methylprednisolone therapy did not yield significant improvement, but after 18 months, she showed notable neurological recovery with an improved modified Rankin Scale score to 1.

Despite the global administration of billions of COVID-19 vaccine doses, the literature reveals limited evidence of the risk for hemorrhagic events, typically in patients with pre-existing pathologies and primarily associated with mRNA vaccines. This scarcity of adverse incidents further underscores the safety of vaccination.

Primary Angiitis of the Central Nervous System (PACNS)

Whereas several cases of PACNS after COVID-19 have been reported,^{77,78} we found only a case of primary angiitis of the central nervous system in a 9-year-old boy following his second dose of the Pfizer-BioNTech COVID-19 vaccine (BNT162b2).⁷⁹ Symptoms began one day post-vaccination, including persistent headache and fever. Diagnostic MRI on the sixth day revealed stenosis of the left middle cerebral artery. Treatment with three courses of methylprednisolone pulse therapy with gradually tapering and aspirin as an antiplatelet therapy led to the disappearance of symptoms and improvement in vascular stenosis, with the patient in remission for over a year.

Pituitary Apoplexy

There are some case reports describing cases of pituitary bleeding and following apoplexy, mostly on the basis of pre-existing adenomas. A 50-year-old man experienced severe headache, vomiting, nausea, and diplopia after receiving his third Moderna COVID-19 vaccine dose treatment included stress dexamethasone for potential adrenal insufficiency and to reduce edema. The patient underwent transsphenoidal resection of the pituitary tumor. Post-surgery, the patient showed significant improvement, with normal pituitary hormone levels and resolution of headache and diplopia at the 4-month follow-up.¹⁴

Another case involved a 45-year-old man with a giant pituitary tumor and bitemporal hemianopsia, whose surgery was delayed due to COVID-19. After receiving the second dose of the Pfizer/BioNTech vaccine, he experienced a severe headache and vision loss due to pituitary apoplexy, necessitating emergency surgery.⁸⁰

A summary of all neurovascular side effects of Sars-Cov2 Vaccination is depicted in Figure 1.

Future Directions

Future approaches to address neurovascular complications following COVID-19 vaccinations should prioritize comprehensive surveillance systems to monitor adverse events over extended periods, enhancing our understanding of long-term effects. Research should include comparative studies involving vaccinated and unvaccinated cohorts to establish clearer

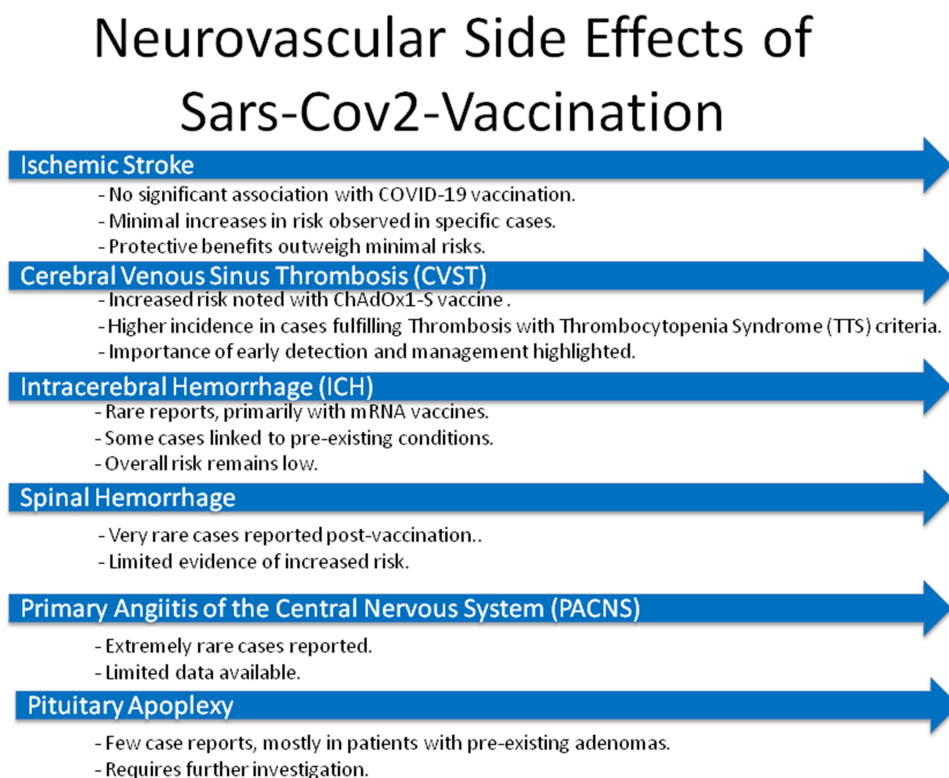


Figure 1 Neurovascular side effects of Sars-Cov2 Vaccination.

causal relationships. Emphasis on elucidating the biological mechanisms behind these rare complications could lead to targeted prevention strategies. Additionally, public health communication must balance the risks and benefits of vaccination, reassuring the public about vaccine safety while promoting vaccination among at-risk groups to prevent severe COVID-19 outcomes.

Conclusions

While large-scale studies, primarily self-controlled case series focusing on hospitalized patients, suggest rare neurovascular complications post-COVID vaccination, limitations exist in data comprehensiveness and short follow-up duration, potentially under-reporting long-term effects. However, the increased risk of CVST, especially with the ChAdOx1 nCoV-19 (AstraZeneca) vaccine, has led to the recent withdraw of the vaccine from sales and underscores the need for vigilant monitoring and prompt recognition of symptoms to mitigate risks effectively.⁸¹

Comparative analyses with unvaccinated cohorts are lacking, and the causal relationship between mRNA vaccines and neurovascular events remains speculative. Despite these concerns, the incidence of similar complications following COVID-19 infection is higher, reinforcing that the benefits of vaccination, especially in preventing severe COVID-19 outcomes in at-risk populations and outweighing the rare risks of neurovascular complications.

Disclosure

The authors report no conflicts of interest in this work.

References

- Asante Antwi H, Zhou L, Xu X, Mustafa T. Beyond COVID-19 pandemic: an integrative review of global health crisis influencing the evolution and practice of corporate social responsibility. *Healthcare (Basel)*. 2021;9(4):1.
- Fathizadeh H, Afshar S, Masoudi MR, et al. SARS-CoV-2 (Covid-19) vaccines structure, mechanisms and effectiveness: a review. *Int J Biol Macromol*. 2021;188:740–750. doi:10.1016/j.ijbiomac.2021.08.076
- Vitiello A, Ferrara F, Troiano V, La Porta R. COVID-19 vaccines and decreased transmission of SARS-CoV-2. *Inflammopharmacology*. 2021;29(5):1357–1360. doi:10.1007/s10787-021-00847-2
- Tenforde MW, Self WH, Adams K, et al. Association between mRNA vaccination and COVID-19 hospitalization and disease severity. *JAMA*. 2021;326(20):2043–2054. doi:10.1001/jama.2021.19499
- Jablonska K, Aballea S, Toumi M. The real-life impact of vaccination on COVID-19 mortality in Europe and Israel. *Public Health*. 2021;198:230–237. doi:10.1016/j.puhe.2021.07.037
- Marcellusi A, Fabiano G, Sciattella P, Andreoni M, Mennini FS. The impact of COVID-19 vaccination on the Italian healthcare system: a scenario analysis. *Clin Drug Investig*. 2022;42(3):237–242. doi:10.1007/s40261-022-01127-9
- Sobczak M, Pawliczak R. COVID-19 vaccination efficacy in numbers including SARS-CoV-2 variants and age comparison: a meta-analysis of randomized clinical trials. *Ann Clin Microbiol Antimicrob*. 2022;21(1):32. doi:10.1186/s12941-022-00525-3
- Firouzabadi N, Ghasemiyeh P, Moradishooli F, Mohammadi-Samani S. Update on the effectiveness of COVID-19 vaccines on different variants of SARS-CoV-2. *Int Immunopharmacol*. 2023;117:109968. doi:10.1016/j.intimp.2023.109968
- Kouhpayeh H, Ansari H. Adverse events following COVID-19 vaccination: a systematic review and meta-analysis. *Int Immunopharmacol*. 2022;109:108906. doi:10.1016/j.intimp.2022.108906
- Maltezou HC, Hatziantoniou S, Theodoridou K, Vasileiou K, Anastassopoulou C, Tsakris A. Anaphylaxis rates following mRNA COVID-19 vaccination in children and adolescents: analysis of data reported to EudraVigilance. *Vaccine*. 2023;41(14):2382–2386. doi:10.1016/j.vaccine.2023.02.067
- Oster ME, Shay DK, Su JR, et al. Myocarditis cases reported after mRNA-based COVID-19 vaccination in the US from December 2020 to August 2021. *JAMA*. 2022;327(4):331–340. doi:10.1001/jama.2021.24110
- Diaz GA, Parsons GT, Gering SK, Meier AR, Hutchinson IV, Robicsek A. Myocarditis and pericarditis after vaccination for COVID-19. *JAMA*. 2021;326(12):1210–1212. doi:10.1001/jama.2021.13443
- MacIntyre CR, Veness B, Berger D, Hamad N, Bari N. Thrombosis with Thrombocytopenia Syndrome (TTS) following AstraZeneca ChAdOx1 nCoV-19 (AZD1222) COVID-19 vaccination - A risk-benefit analysis for people < 60 years in Australia. *Vaccine*. 2021;39(34):4784–4787. doi:10.1016/j.vaccine.2021.07.013
- Aliberti L, Gagliardi I, Rizzo R, et al. Pituitary apoplexy and COVID-19 vaccination: a case report and literature review. *Front Endocrinol (Lausanne)*. 2022;13:1035482. doi:10.3389/fendo.2022.1035482
- Reinke S, Thakur A, Gartlan C, Bezbradica JS, Milicic A. Inflammation-mediated immunogenicity of clinical and experimental vaccine adjuvants. *Vaccines (Basel)*. 2020;8(3). doi:10.3390/vaccines8030554
- Komarek S, Dejakum B, Moelgg K, et al. No association between SARS-CoV-2 vaccination and ischaemic stroke or high-risk transient ischaemic attack. *J Neurol Sci*. 2024;456:120834. doi:10.1016/j.jns.2023.120834
- Yamin D, Yechezkel M, Arbel R, et al. Safety of monovalent and bivalent BNT162b2 mRNA COVID-19 vaccine boosters in at-risk populations in Israel: a large-scale, retrospective, self-controlled case series study. *Lancet Infect Dis*. 2023;23(10):1130–1142. doi:10.1016/S1473-3099(23)00207-4
- El Naamani K, Amlly A, Chen CJ, et al. The effect of COVID-19 vaccines on stroke outcomes: a single-center study. *World Neurosurg*. 2023;170:e834–e839. doi:10.1016/j.wneu.2022.11.132

19. Gorenflo MP, Davis PB, Kaelber DC, Xu R. Ischemic stroke after COVID-19 bivalent vaccine administration in patients aged 65 years and older in the United States. *NPJ Vaccines*. 2023;8(1):180. doi:10.1038/s41541-023-00777-w
20. Torabi F, Bedston S, Lowthian E, et al. Risk of thrombocytopenic, haemorrhagic and thromboembolic disorders following COVID-19 vaccination and positive test: a self-controlled case series analysis in Wales. *Sci Rep*. 2022;12(1):16406. doi:10.1038/s41598-022-20118-6
21. Hippisley-Cox J, Patone M, Mei XW, et al. Risk of thrombocytopenia and thromboembolism after covid-19 vaccination and SARS-CoV-2 positive testing: self-controlled case series study. *BMJ*. 2021;374:n1931.
22. Botton J, Jabagi MJ, Bertrand M, et al. Risk for myocardial infarction, stroke, and pulmonary embolism following COVID-19 vaccines in adults younger than 75 years in France. *Ann Intern Med*. 2022;175(9):1250–1257. doi:10.7326/M22-0988
23. Dag Berild J, Bergstad Larsen V, Myrup Thiesson E, et al. Analysis of thromboembolic and thrombocytopenic events after the AZD1222, BNT162b2, and mRNA-1273 COVID-19 vaccines in 3 Nordic countries. *JAMA Netw Open*. 2022;5(6):e2217375. doi:10.1001/jamanetworkopen.2022.17375
24. Andrews N, Stowe J, Miller E, Ramsay M. BA.1 bivalent COVID-19 vaccine use and stroke in England. *JAMA*. 2023;330(2):184–185. doi:10.1001/jama.2023.10123
25. Ihle-Hansen H, Boas H, Tapia G, et al. Stroke after SARS-CoV-2 mRNA vaccine: a nationwide registry study. *Stroke*. 2023;54(5):e190–e193. doi:10.1161/STROKEAHA.122.040430
26. Gorenflo MP, Davis PB, Kaelber DC, Xu R. Ischemic stroke after COVID-19 bivalent vaccine administration in patients aged 65 years and older: analysis of nation-wide patient electronic health records in the United States. *medRxiv*. 2023. doi:10.1101/2023.02.11.23285801
27. Chui CSL, Fan M, Wan EYF, et al. Thromboembolic events and hemorrhagic stroke after mRNA (BNT162b2) and inactivated (CoronaVac) covid-19 vaccination: a self-controlled case series study. *EClinicalMedicine*. 2022;50:101504. doi:10.1016/j.eclinm.2022.101504
28. Rojko M, Suligoj NC, Zorc M, Noc M. Patent foramen ovale-associated stroke and COVID-19 vaccination. *Interv Cardiol*. 2023;18:e10.
29. Kim YE, Huh K, Park YJ, Peck KR, Jung J. Association between vaccination and acute myocardial infarction and ischemic stroke after COVID-19 infection. *JAMA*. 2022;328(9):887–889. doi:10.1001/jama.2022.12992
30. Dorajoo SR, Tan HX, Teo CHD, et al. Nationwide safety surveillance of COVID-19 mRNA vaccines following primary series and first booster vaccination in Singapore. *Vaccine X*. 2023;15:100419. doi:10.1016/j.jvax.2023.100419
31. Lopez-Mena D, Garcia-Grimshaw M, Saldivar-Davila S, et al. Stroke among SARS-CoV-2 vaccine recipients in Mexico: a nationwide descriptive study. *Neurology*. 2022;98(19):e1933–e1941. doi:10.1212/WNL.000000000000200388
32. Hidayat R, Diafiri D, Zairinal RA, et al. Acute ischaemic stroke incidence after coronavirus vaccine in Indonesia: case series. *Curr Neurovasc Res*. 2021;18(3):360–363. doi:10.2174/1567202618666210927095613
33. Fotiadou A, Tsiptsios D, Kitmeridou S, Mavraki E, Iliopoulos I. Spinal cord ischemia complicating BNT162b2 mRNA COVID-19 vaccination. *Neurol Sci*. 2023;44(2):457–459. doi:10.1007/s10072-022-06483-0
34. Kenda J, Lovric D, Skerget M, Milivojevic N. Treatment of ChAdOx1 nCoV-19 vaccine-induced immune thrombotic thrombocytopenia related acute ischemic stroke. *J Stroke Cerebrovasc Dis*. 2021;30(11):106072. doi:10.1016/j.jstrokecerebrovasdis.2021.106072
35. Yamaji T, Harada T, Hashimoto Y, et al. Effects of BNT162b2 mRNA Covid-19 vaccine on vascular function. *PLoS One*. 2024;19(4):e0302512. doi:10.1371/journal.pone.0302512
36. Qiao H, Deng X, Qiu L, et al. SARS-CoV-2 induces blood-brain barrier and choroid plexus barrier impairments and vascular inflammation in mice. *J Med Virol*. 2024;96(5). doi:10.1002/jmv.29671.
37. Yepes M. Neurological complications of SARS-CoV-2 Infection and COVID-19 vaccines: from molecular mechanisms to clinical manifestations. *Curr Drug Targets*. 2022;23(17):1620–1638. doi:10.2174/1389450123666220919123029
38. Stefanou MI, Palaiodimos L, Aguiar de Sousa D, et al. Acute arterial ischemic stroke following covid-19 vaccination: A systematic review and meta-analysis. *Neurology*. 2022;99(14):e1465–e1474. doi:10.1212/WNL.000000000000200996
39. Cascio Rizzo A, Giussani G, Agostoni EC. Ischemic stroke and vaccine-induced immune thrombotic thrombocytopenia following COVID-19 vaccine: a case report with systematic review of the literature. *Cerebrovasc Dis*. 2022;51(6):722–734. doi:10.1159/000524290
40. Deuschl C, Goertz L, Kabbasch C, et al. Impact of vaccination status on outcome of patients with COVID-19 and acute ischemic stroke undergoing mechanical thrombectomy. *J Am Heart Assoc*. 2024;13(9):e031816. doi:10.1161/JAHA.123.031816
41. van Kammen M S, de Sousa D A, Poli S, et al. Characteristics and outcomes of patients with cerebral venous sinus thrombosis in sars-cov-2 vaccine-induced immune thrombotic thrombocytopenia. *JAMA Neurol*. 2021;78(11):1314–1323. doi:10.1001/jama.2021.3619
42. Whiteley WN, Ip S, Cooper JA, et al. Association of COVID-19 vaccines ChAdOx1 and BNT162b2 with major venous, arterial, or thrombocytopenic events: a population-based cohort study of 46 million adults in England. *PLoS Med*. 2022;19(2):e1003926. doi:10.1371/journal.pmed.1003926
43. Kerr S, Joy M, Torabi F, et al. First dose ChAdOx1 and BNT162b2 COVID-19 vaccinations and cerebral venous sinus thrombosis: a pooled self-controlled case series study of 11.6 million individuals in England, Scotland, and Wales. *PLoS Med*. 2022;19(2):e1003927. doi:10.1371/journal.pmed.1003927
44. McKeigue PM, Burgul R, Bishop J, et al. Association of cerebral venous thrombosis with recent COVID-19 vaccination: case-crossover study using ascertainment through neuroimaging in Scotland. *BMC Infect Dis*. 2021;21(1):1275. doi:10.1186/s12879-021-06960-5
45. van de Munckhof A, Borhani-Haghighi A, Aaron S, et al. Cerebral venous sinus thrombosis due to vaccine-induced immune thrombotic thrombocytopenia in middle-income countries. *Int J Stroke*. 2023;18(9):1112–1120. doi:10.1177/17474930231182901
46. Schultz NH, Sorvoll IH, Michelsen AE, et al. Thrombosis and Thrombocytopenia after ChAdOx1 nCoV-19 Vaccination. *N Engl J Med*. 2021;384(22):2124–2130. doi:10.1056/NEJMoa2104882
47. Huynh A, Kelton JG, Arnold DM, Daka M, Nazy I. Antibody epitopes in vaccine-induced immune thrombotic thrombocytopenia. *Nature*. 2021;596(7873):565–569. doi:10.1038/s41586-021-03744-4
48. Ostrowski SR, Sogaard OS, Tolstrup M, et al. Inflammation and platelet activation after COVID-19 vaccines - possible mechanisms behind vaccine-induced immune thrombocytopenia and thrombosis. *Front Immunol*. 2021;12:779453. doi:10.3389/fimmu.2021.779453
49. Althaus K, Moller P, Uzun G, et al. Antibody-mediated procoagulant platelets in SARS-CoV-2-vaccination associated immune thrombotic thrombocytopenia. *Haematologica*. 2021;106(8):2170–2179. doi:10.3324/haematol.2021.279000
50. Corbett KS, Flynn B, Foulds KE, et al. Evaluation of the mRNA-1273 vaccine against SARS-CoV-2 in nonhuman primates. *N Engl J Med*. 2020;383(16):1544–1555. doi:10.1056/NEJMoa2024671

51. Owens AP, Mackman N. Tissue factor and thrombosis: the clot starts here. *Thromb Haemost.* 2010;104(3):432–439. doi:10.1160/TH09-11-0771
52. Muir KL, Kallam A, Koepsell SA, Gundabolu K. Thrombotic thrombocytopenia after Ad26.COV2.S vaccination. *N Engl J Med.* 2021;384(20):1964–1965. doi:10.1056/NEJMc2105869
53. Wolf ME, Luz B, Niehaus L, Bhogal P, Bazner H, Henkes H. Thrombocytopenia and intracranial venous sinus thrombosis after COVID-19 vaccine astraZeneca. *Exposure. J Clin Med.* 2021;10(8):1.
54. Jamme M, Mosnino E, Hayon J, Franchineau G. Fatal cerebral venous sinus thrombosis after COVID-19 vaccination. *Intensive Care Med.* 2021;47(7):790–791. doi:10.1007/s00134-021-06425-y
55. Dias L, Soares-Dos-Reis R, Meira J, et al. Cerebral venous thrombosis after BNT162b2 mRNA SARS-CoV-2 vaccine. *J Stroke Cerebrovasc Dis.* 2021;30(8):105906. doi:10.1016/j.jstrokecerebrovasdis.2021.105906
56. Zakaria Z, Sapii NA, Ghani ARI. Cerebral venous sinus thrombosis 2 weeks after the first dose of mRNA SARS-CoV-2 vaccine. *Acta Neurochir (Wien).* 2021;163(8):2359–2362. doi:10.1007/s00701-021-04860-w
57. Sorvoll IH, Horvei KD, Ernstsen SL, et al. An observational study to identify the prevalence of thrombocytopenia and anti-PF4/polyanion antibodies in Norwegian health care workers after COVID-19 vaccination. *J Thromb Haemost.* 2021;19(7):1813–1818. doi:10.1111/jth.15352
58. Dorgalaleh A, Shabannezhad A, Hassani S. COVID-19 vaccine-induced immune thrombotic thrombocytopenia: pathophysiology and diagnosis. *Ann Hematol.* 2023. doi:10.1007/s00277-023-05563-1
59. Pavord S, Hunt BJ, Horner D, Bewley S, Karpusheff J, Guideline C. Vaccine induced immune thrombocytopenia and thrombosis: summary of NICE guidance. *BMJ.* 2021;375:n2195.
60. Vayne C, Rollin J, Clare R, et al. The use of 1e12, a monoclonal anti-platelet factor 4 antibody to improve the diagnosis of vaccine-induced immune thrombotic thrombocytopenia. *J Thromb Haemost.* 2024. doi:10.1016/j.jtha.2024.05.005
61. De Michele M, Iacobucci M, Chistolini A, et al. Malignant cerebral infarction after ChAdOx1 nCov-19 vaccination: a catastrophic variant of vaccine-induced immune thrombotic thrombocytopenia. *Nat Commun.* 2021;12(1):4663. doi:10.1038/s41467-021-25010-x
62. Fanni D, Saba L, Demontis R, et al. Vaccine-induced severe thrombotic thrombocytopenia following COVID-19 vaccination: a report of an autoptic case and review of the literature. *Eur Rev Med Pharmacol Sci.* 2021;25(15):5063–5069. doi:10.26355/eurrev_202108_26464
63. Aladdin Y, Algahtani H, Shirah B. Vaccine-induced immune thrombotic thrombocytopenia with disseminated intravascular coagulation and death following the ChAdOx1 nCoV-19 Vaccine. *J Stroke Cerebrovasc Dis.* 2021;30(9):105938. doi:10.1016/j.jstrokecerebrovasdis.2021.105938
64. Castelli GP, Pognani C, Sozzi C, Franchini M, Vivona L. Cerebral venous sinus thrombosis associated with thrombocytopenia post-vaccination for COVID-19. *Crit Care.* 2021;25(1):137. doi:10.1186/s13054-021-03572-y
65. Bano F, Badugama B, Chandra D. Thrombosis and thrombocytopenia after ChAdOx1 nCoV-19 vaccination: a single UK centre experience. *BMJ Case Rep.* 2021;14(7):e243894. doi:10.1136/bcr-2021-243894
66. Bayas A, Menacher M, Christ M, Behrens L, Rank A, Naumann M. Bilateral superior ophthalmic vein thrombosis, ischaemic stroke, and immune thrombocytopenia after ChAdOx1 nCoV-19 vaccination. *Lancet.* 2021;397(10285):e11. doi:10.1016/S0140-6736(21)00872-2
67. John CV, Kumar R, Sivan AK, Jithin S, Abraham R, Philip CC. Vaccine-induced thrombotic thrombocytopenia (VITT): first report from India. *Thromb J.* 2022;20(1):11. doi:10.1186/s12959-022-00370-6
68. Sheikh S. Thrombotic thrombocytopenia and central venous sinus thrombosis post - COVID-19 vaccination and its treatment with heparin alternatives. *J Coll Physicians Surg Pak.* 2021;31(7):149.
69. Tiede A, Sachs UJ, Czwalinna A, et al. Prothrombotic immune thrombocytopenia after COVID-19 vaccination. *Blood.* 2021;138(4):350–353. doi:10.1182/blood.2021011958
70. Weller J, Krzywicka K, van de Munckhof A, et al. Endovascular treatment of cerebral sinus thrombosis due to vaccine-induced immune thrombotic thrombocytopenia. *Eur Stroke J.* 2023;1;23969873231202363.
71. van de Munckhof A, Lindgren E, Kleinig TJ, et al. Outcomes of cerebral venous thrombosis due to vaccine-induced immune thrombotic thrombocytopenia after the acute phase. *Stroke.* 2022;53(10):3206–3210. doi:10.1161/STROKEAHA.122.039575
72. Chida K, Takahashi T, Igarashi S, et al. Rupture of vertebral artery dissecting aneurysm after mRNA anti-COVID-19 vaccination: a report of two cases. *NMC Case Rep J.* 2022;9(1):95–100. doi:10.2176/jns-nmc.2022-0012
73. Oshida S, Akamatsu Y, Matsumoto Y, et al. Intracranial aneurysm rupture within three days after receiving mRNA anti-COVID-19 vaccination: three case reports. *Surg Neurol Int.* 2022;13:117. doi:10.25259/SNI_1144_2021
74. Yangi K, Demir DD, Uzunkol A. Intracranial hemorrhage after pfizer-BioNTech (BNT162b2) mRNA COVID-19 vaccination: a case report. *Cureus.* 2023;15(4):1.
75. Rezvani M, Sabouri M, Aminmansour B, et al. Spontaneous spinal epidural haematoma following COVID-19 vaccination: a case report. *Ann Med Surg (Lond).* 2024;86(1):612–619. doi:10.1097/MS9.0000000000001604
76. Sourani A, Rezvani M, Foroughi M, Baradaran Mahdavi S. Spontaneous intramedullary hematoma following COVID-19 vaccination: a case report. *Clin Case Rep.* 2022;10(12). doi:10.1002/ccr3.6743
77. Poisson KE, Zygmunt A, Leino D, et al. Lethal pediatric cerebral vasculitis triggered by severe acute respiratory syndrome coronavirus 2. *Pediatr Neurol.* 2022;127:1–5. doi:10.1016/j.pediatrneurol.2021.11.003
78. Vaschetto R, Cena T, Sainaghi PP, et al. Cerebral nervous system vasculitis in a Covid-19 patient with pneumonia. *J Clin Neurosci.* 2020;79:71–73. doi:10.1016/j.jocn.2020.07.032
79. Ariyoshi T, Hoshida M, Motonaga T, et al. Childhood primary angiitis of the central nervous system following COVID-19 vaccination (BNT162b2/Pfizer-BioNtech): a case report. *Hum Vaccin Immunother.* 2023;19(2):2261167. doi:10.1080/21645515.2023.2261167
80. Tanaka H, Nishimura F, Nakase K, et al. Case report: giant pituitary neuroendocrine tumor presented along with acute visual loss due to pituitary apoplexy after receiving COVID-19 vaccination. *Front Surg.* 2023;10:1220098. doi:10.3389/fsurg.2023.1220098
81. Vaxzevria (previously COVID-19 Vaccine AstraZeneca). 2024; Available from: <https://www.ema.europa.eu/en/medicines/human/EPAR/vaxzevria-previously-covid-19-vaccine-astrazeneca>. Accessed May 23, 2024.

Drug Design, Development and Therapy

Dovepress

Publish your work in this journal

Drug Design, Development and Therapy is an international, peer-reviewed open-access journal that spans the spectrum of drug design and development through to clinical applications. Clinical outcomes, patient safety, and programs for the development and effective, safe, and sustained use of medicines are a feature of the journal, which has also been accepted for indexing on PubMed Central. The manuscript management system is completely online and includes a very quick and fair peer-review system, which is all easy to use. Visit <http://www.dovepress.com/testimonials.php> to read real quotes from published authors.

Submit your manuscript here: <https://www.dovepress.com/drug-design-development-and-therapy-journal>