


A Fully Guided Sequential Template Immediate Loading Protocol for Dual-Arch Implant Surgery

Lamia Alruhailie^{1,*}, Aliyaa Zaidan^{2,*}, Abeer Alasmari^{2,*}, Ossama Raffa^{1,*} 

¹Department of Prosthodontics, King Abdulaziz Medical City, Jeddah, Saudi Arabia; ²Department of Periodontics, King Abdulaziz Medical City, Jeddah, Saudi Arabia

*These authors contributed equally to this work

Correspondence: Ossama Raffa, Department of Prosthodontics, King Abdulaziz Medical City, Jeddah, Saudi Arabia, Tel +966543322668, Email raffa.ossama@gmail.com

Abstract: A method is described for designing, fabricating and implementing sequential template immediate loading protocols for dual arch implant therapy. A 41-year-old medically-free patient with terminal dentition was treated following stackable guide loading protocols for maxillary and mandibular arches. Implants were placed following extractions and immediately loaded with full arch fixed prostheses. Healing was uneventful and all implants integrated successfully. Special consideration was given to the design and clinical challenges when implementing stackable guide protocols for dual arch implant therapy.

Keywords: prosthodontics, implants, digital dentistry, stackable guides

Introduction

Immediate loading of dental implants has been extensively studied and consistently proven to be effective while providing predictable outcomes.¹⁻⁵ Success rates for immediately loaded full-arch implant prosthetics have been shown to be similar to those of conventional loading protocols.^{1-4,6} Immediate loading is commonly described as a procedure in which implants are connected to a prosthesis that occludes with the opposing arch within 1 week after implant installation.^{3,4,7-9} The number of implants needed to support a full-arch immediately loaded prosthesis has also been studied, with the general consensus being that a range of 4-6 implants for both maxillary and mandibular arches seem optimal.⁷⁻¹⁰ Ideally, these implants should be well distributed in the arch, providing maximum anteroposterior spread while avoiding anatomical limitations.^{2,5-7,10}

Computer-guided implant surgery has several advantages over traditional approaches, particularly when loading protocols are used.^{11,12} Guided surgery can enhance control over treatment outcomes by ensuring more predictable implant placement with fewer errors, thereby shortening treatment time and reducing patient morbidity.^{11,12} For edentulous patients, mucosa-supported guides typically exhibit fewer errors in implant placement than those of bone-supported guides.^{11,13} In dentate patients undergoing complete edentulation with immediate implant placement and immediate prosthetic loading, sequential template-guided surgery can aid in providing accurate guided implant placement and facilitating prosthetic loading procedures.¹⁴⁻¹⁸ Several designs have been proposed for manufacturing and utilizing sequential or stackable surgical guides for transitioning dentate patients to an immediately loaded full-arch prosthesis.¹⁴⁻¹⁹ The use of these post-extractive immediate implant placement and loading protocols allow for quicker patient accommodation and resumption of daily activities.¹⁷ While previous reports have outlined several design principles for stackable surgical guides, a standardized approach has not yet been established and further studies are still needed.¹⁶⁻¹⁹ Furthermore, previous studies have mainly focused on single arch rehabilitations when utilizing the stackable guides concept.¹⁴⁻¹⁹ The purpose of this clinical report was to demonstrate an approach for designing and fabricating stackable surgical guides utilizing digital workflows for a patient undergoing complete edentulation of their maxillary and mandibular arches, followed by immediate implant placement and loading of interim maxillary and mandibular prostheses.

Case Report

A 41-year-old male patient presented to the prosthodontics department seeking the replacement of missing teeth (Figure 1). The patient was medically free and presented with terminal maxillary and mandibular dentition. After performing a thorough case evaluation and reviewing the possible treatment options, the patient opted for complete implant-supported prostheses for the maxillary and mandibular arches. All potential benefits and risks were explained to the patient, and informed consent was obtained.

A cone-beam computed tomography (CBCT) scan was obtained and exported as a Digital Imaging and Communication in Medicine (DICOM) file. The CBCT scan was made with the patient biting on cotton rolls to ensure proper tooth separation. This was performed to facilitate the superimposition of the surface scans in later steps. Since the patient was missing posterior occlusion, conventional impressions were made, and the resulting casts were mounted on a semi-adjustable articulator (Artex CPR, Amman Girschbach, Germany) using bite blocks to record the patient's occlusion and transfer it to the planning software. Indentations were made on the landing areas of the casts to act as reference points for future steps. The articulated casts were then digitized using an extraoral scanner (CeraMap 600+, Amman Girschbach, Germany) and exported as Standard Tessellation Language (STL) files.

All necessary records were transferred to an implant planning software (Blue Sky Plan 4.0, Blue Sky Bio, IL, USA), and digital planning was performed (Figure 2). Alignment of the CBCT images with the surface scan STLs was performed using the teeth as a reference. Adequate alignment was confirmed by ensuring that the outline of the teeth and gingival tissues in the surface scans coincided with that on CBCT. Prosthetically driven implant planning was performed, starting with facial analysis, and digital teeth set-up based on esthetic and functional principles. This teeth set-up was then used to plan the implant positions according to the best available bone, favorable prosthetic distribution, and maximum anteroposterior spread. Six implants (Bone level tapered Roxolid SLA active, 3.3 and 4.1 mm, Institut Straumann AG, Switzerland) were planned in the maxillary arch with four vertical anterior implants and two distally angled terminal implants to avoid the maxillary sinuses. For the mandibular arch, five implants (Bone level tapered Roxolid SLA active, 3.3 and 4.1 mm, Institut Straumann AG, Switzerland) were planned with three vertical anterior implants and two distally angled terminal implants to avoid the mental foramens and inferior alveolar nerves. For both arches, implants were planned 13–15 mm apical to the occlusal plane with planned concurrent alveoloplasty to achieve adequate restorative space, bone thickness, and curettage of the diseased tissues.

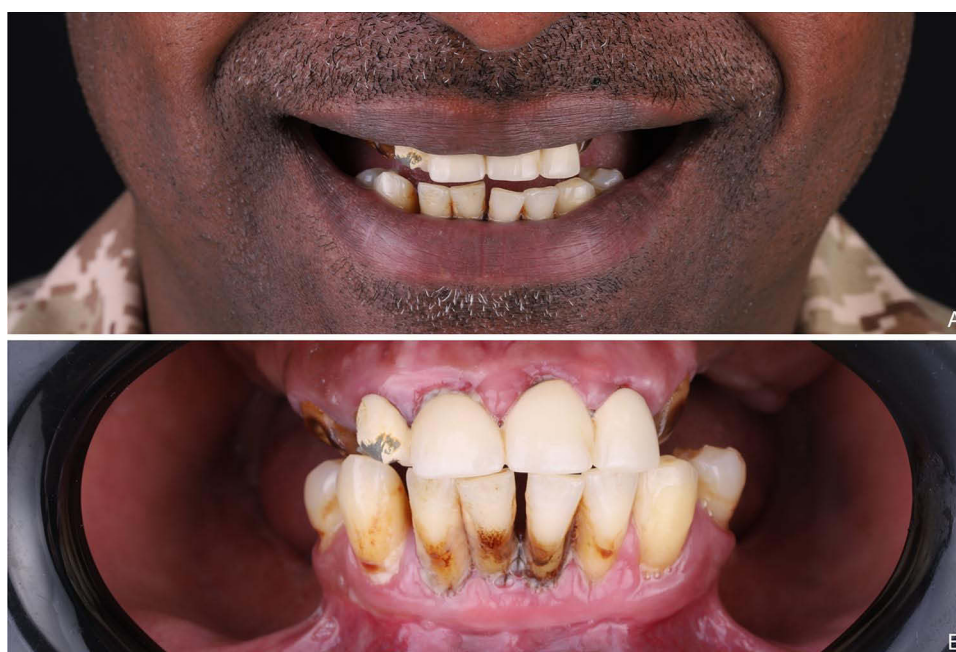

Figure 1 Pre-operative presentation. (A) Close-up Smile. (B) Retracted MIP.

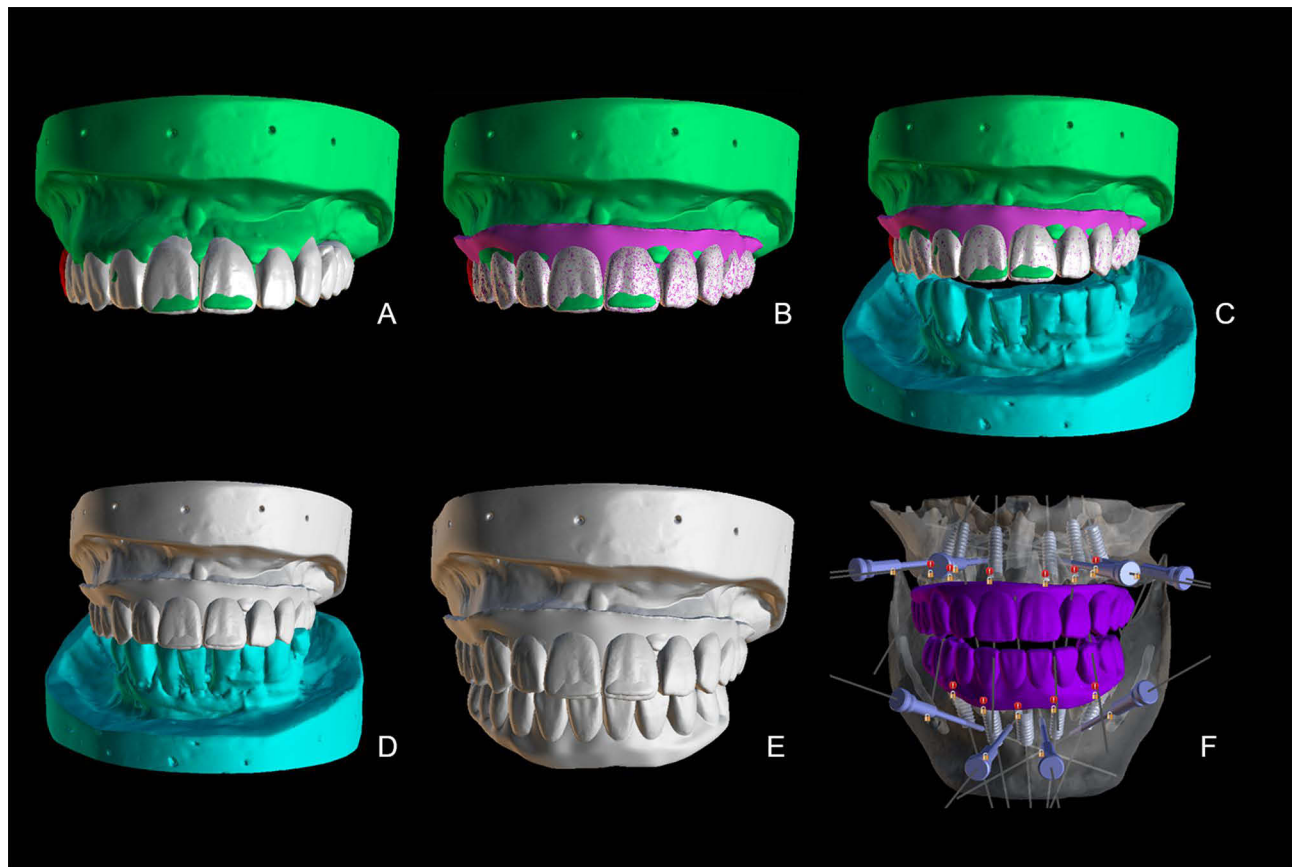


Figure 2 Digital planning steps. **(A)** Initial maxillary teeth set-up. **(B)** Gingival design. **(C)** Maxillary wax up opposing mandibular cast, which was aligned with the CBCT. **(D)** Transfer of maxillary wax-up to mandibular occlusion based on saved coordinates of the articulated model scans. **(E)** Design of mandibular wax-up. **(F)** Finalized maxillary and mandibular wax ups and implant planning.

Once the implant positions were finalized, each component of the stackable surgical guide was designed in the planning software (Blue Sky Plan 4.0; Blue Sky Bio, IL, USA) using the associated CAD tools (Figure 3). A base guide was designed for the maxillary and mandibular arches with a minimum cross section of 3 mm and an average vertical height of 5 mm. Four sleeves for fixation pins (template fixation pin – Ø 1.3 mm, Institut Straumann AG, Switzerland) were planned into each base guide to ensure stability through the surgical procedures. A 200-micron spacer was incorporated into the sleeve portion of the base guides to facilitate drilling and fixation through the guide. Adaptation guides were then designed to help orient the base guides during the initial phase of the procedure. Next, osteotomy guides were designed based on the planned implant positions. The sleeve portion of the osteotomy guides included a 200-micron spacer to aid in drilling and implant placement through the osteotomy guide. Timing markers were incorporated into the osteotomy guides for the distally angulated implants to coincide with angle-correcting multiunit abutments placement (RC Screw retained abutment, 30°, Ø 4.6 mm, 2.5 mm GH, Type A, Institut Straumann AG, Switzerland). Timing markers were incorporated by exporting the osteotomy guide and implant position into an open-source 3D design software program (Meshmixer 3.5; Autodesk, CA, USA) and utilizing the “sculpt tools” function within the software (Figure 4). Finally, the prosthetic loading guide was designed based on the digital wax-up and the finalized implant positions.

After designing all the guides, they were exported as STL files and then imported into the same open-source 3D design software program (Meshmixer 3.5, Autodesk, CA, USA) to create attachment and retentive mechanisms (Figure 5).^{16,19} Each guide incorporated retentive and anti-rotational positioning features which were designed using the standard geometrical meshes available within the software. The designs featured magnet housings for retention, while

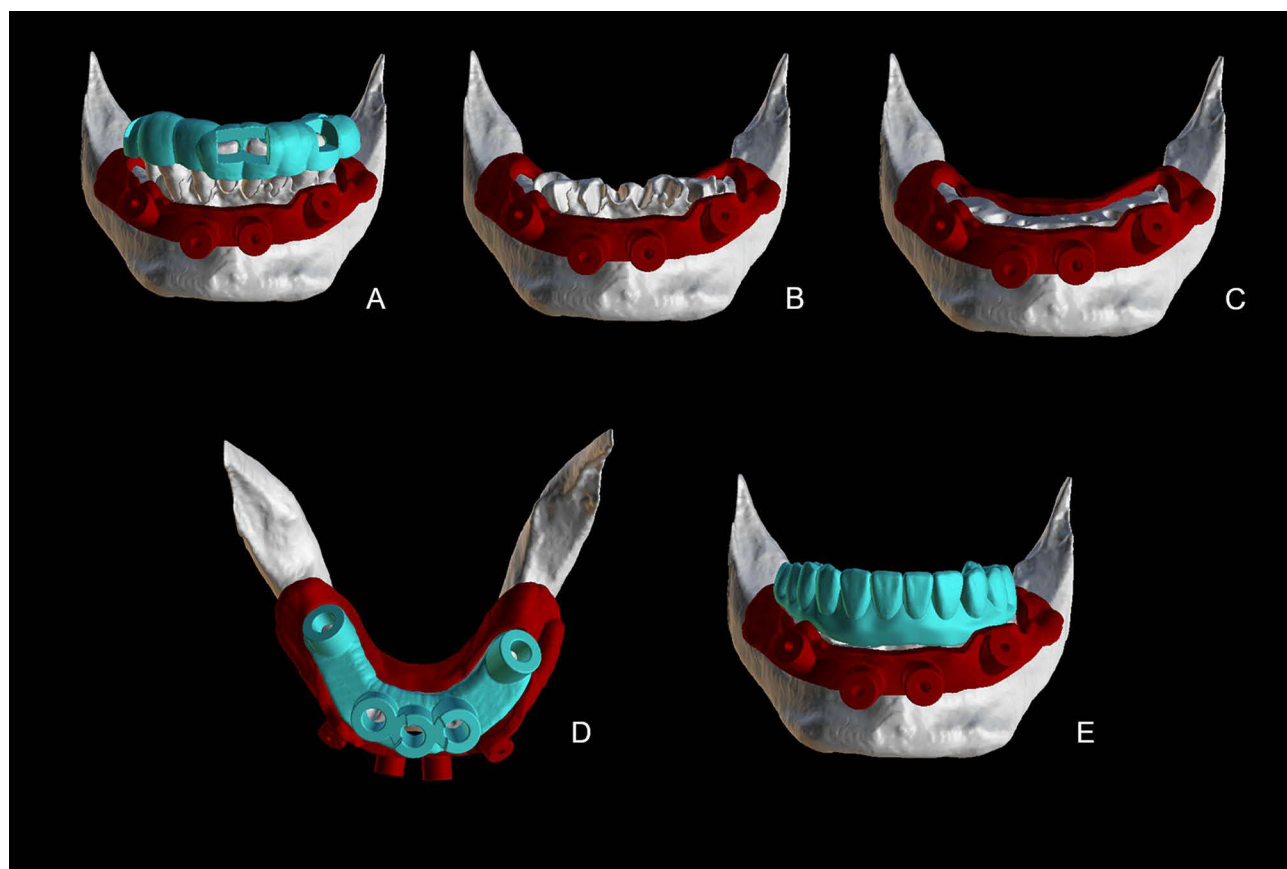


Figure 3 Guide designing sequence for mandibular arch. (A) Adaptation guide and base guide designs. (B) Virtual extractions completed for mandibular arch. (C) Virtual alveoloplasty completed based on implant positions and restorative space requirements. (D) Design of osteotomy guide. (E) Design of prosthetic loading guide.

cylinders and rings were used for anti-rotation. The different components were then attached to each guide utilizing the “add tube” function within the software. The finalized guides were then exported as STL files and prepared for 3D-prototyping.

The STL files of the surgical guides were imported into a nesting software (Asiga Composer, Asiga, Australia) and prepared for printing using a digital light processing 3D printer (Asiga Max, Asiga, Australia). The base guides and provisional loading guides for the maxillary and mandibular arches were printed using a micro-filled hybrid resin (NextDent C&B MFH, 3D Systems, Netherlands) to enhance the mechanical properties. The adaptation and osteotomy guides were printed using clear resin (Freeprint Ortho, Detax, Ettlingen, Germany). After printing, post-processing was performed according to the manufacturer’s instructions, and the fit of the guides was verified (Figure 6). Minimal adjustments were made to the interlocking components to improve the fit as necessary. Neodymium magnets, measuring 5×1 mm, were cemented into all the housings using a universal dual-curing self-adhesive resin cement (Calibra Universal, Dentsply Sirona, NC, USA). To enhance the esthetics of the immediate-load prostheses, a cut-back was completed following the outline of the prosthetic gingiva, and cold-cure acrylic resin (Lucitone 199, Dentsply, NC, USA) was used to build artificial gingival tissues. Finally, to verify the accuracy of the surgical guides and prepare for the surgical date, a complete model surgery was performed on the articulated stone casts (Figures 7 and 8). Further verification was performed by repeating the model surgery on 3D printed replicas of the maxillary and mandibular jaws (Freeprint Ortho, Detax Ettlingen, Germany).

Maxillary and mandibular surgeries were performed under local anesthesia on 2 consecutive days (Figures 9 and 10). The patient was prescribed a course of antibiotics (oral Amoxicillin + Clavulanic acid 1 g BID for 7 days) starting on the first operative day 1 hour before the procedure. At the start of each surgery, the adaptation

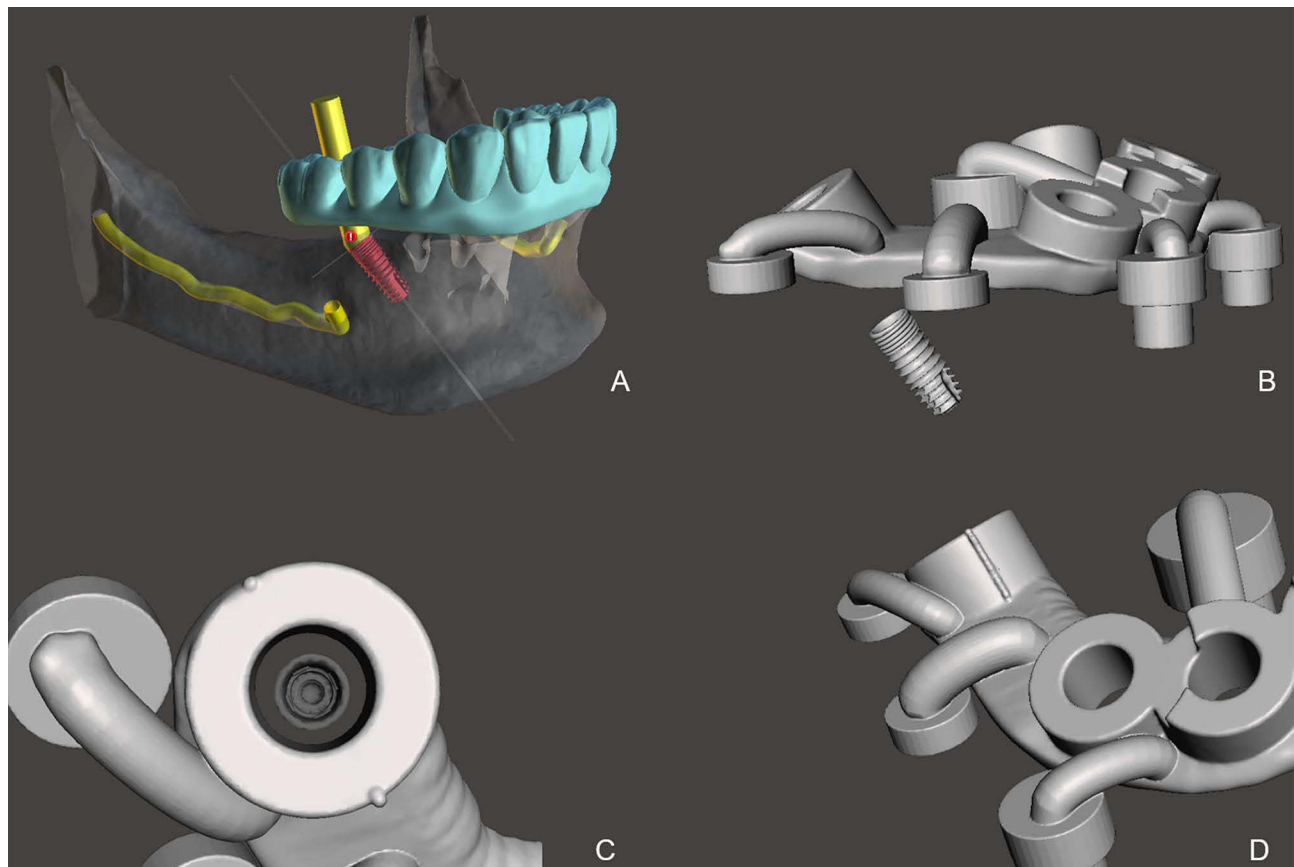


Figure 4 Implant timing demarcation for the distally angulated implants. **(A)** Implant planning illustrating the desired anteroposterior spread and angle correction required. **(B)** Importing the planned implant position and osteotomy guide into the 3D design open-source software (Meshmixer 3.5, Autodesk, CA, USA). **(C)** Marking the desired implant timing into the osteotomy guide using CAD sculpt tools. **(D)** Frontal view after marking desired implant timing.

guide was used to orient the base guide into place, and fixation holes were drilled through the base guide. The guides were then removed and a mucoperiosteal flap was elevated to a level that would not interfere with base-guide seating. After elevation, the base guide was re-oriented using the adaptation guide and fixated into place with the use of fixation pins (template fixation pin – Ø 1.3 mm, Institut Straumann AG, Switzerland). Extractions and alveoloplasty were completed, followed by implant drilling and placement through the osteotomy guide according to the manufacturer's instructions. All implants were placed at a torque of >35 Ncm (~ 40–50 Ncm), followed by preparation for prosthetic loading. For the vertically oriented anterior implants in the maxillary and mandibular arches, bone-level temporary cylinders were placed (RC, NC BL/BLT Crossfit non-engaging temporary abutment; Institut Straumann AG, Switzerland). As for the distally angled implants, angle-correcting multiunit abutments (RC Screw retained abutment, 30°, Ø 4.6 mm, 2.5 mm GH, Type A, Institut Straumann AG, Switzerland) were first seated followed by abutment level temporary cylinders (Non-engaging Titanium Coping, Institut Straumann AG, Switzerland) to prepare for pick-up procedure. The prosthetic loading guides were seated in place; access holes were adjusted as necessary to avoid interference with the titanium cylinders, and mechanical undercuts were incorporated into the provisional to enhance adhesion with the pick-up material. Isolation was achieved by injecting a light body impression material (Express Impression Light Body, 3M ESPE, MN, USA) underneath the prosthesis, and pick-up of the cylinders was completed using a self-adhesive dual curing resin luting material (Quick Up, Voco Dental, Germany). The prostheses were then removed from the mouth, and the support areas were trimmed, followed by finishing and polishing. Finally, the prostheses were reinserted into the patient's mouth, minimal occlusal adjustments were made, and the access holes were sealed with Teflon tape and a flowable composite (Filtek Supreme Flowable Restorative; 3M ESPE, MN, USA). Care

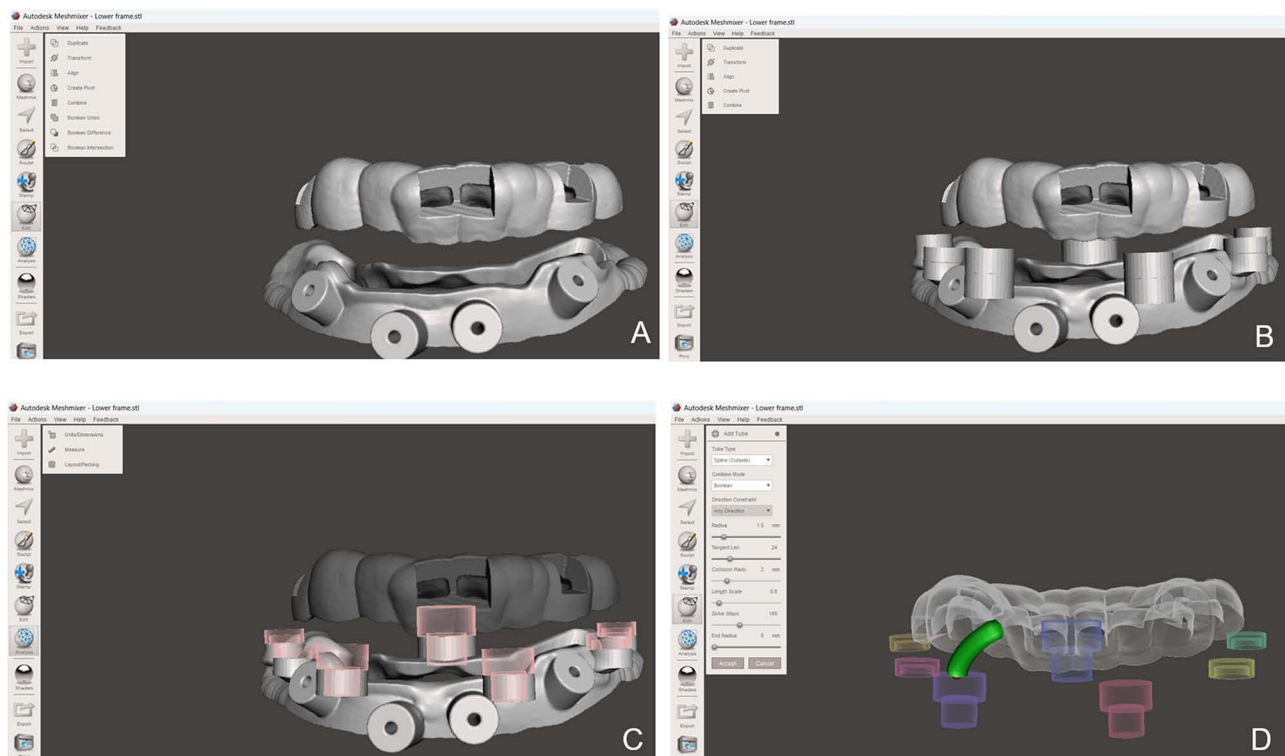


Figure 5 Attaching the different components of each surgical guide. (A) Mandibular base guide and adaptation guide imported into a 3D design open-source software (Meshmixer 3.5, Autodesk, CA, USA). (B) Attaching the interlocking and retentive components with their corresponding parts onto the base guide. (C) Transparent illustration of the patric/matrix complex with 500 microns spacer to allow for ease of fit. (D) Attaching the patric component to the adaptation guide utilizing the “add tube” function.

was taken to provide even bilateral simultaneous occlusal contacts during centric relation, and a shallow canine guidance was also provided. The patient was discharged with over-the-counter analgesics and instructed to complete the previously prescribed antibiotic course (Figure 11). Post-operative radiographs were made (Figure 12), and follow-up appointments were scheduled at intervals of 1 week, 2 weeks, 1 month, 3 months and 5 months. The patient had no complaints throughout the course of healing; no post-operative complications were observed, and all the implants were successfully integrated. The patient was satisfied with the care provided and continued treatment for the definitive prosthesis with the prosthodontics department.

Discussion

The case presented aimed to expand on previously published protocols involving stackable surgical guides. To the authors’ knowledge, previous reports have primarily described the use of these protocols for single-arch surgeries.^{14–18} Implementing this technique on dentate patients undergoing dual-arch surgeries presents added challenges when designing the occlusion.

Yang et al described a digital workflow for fabrication of single arch stackable surgical guides for treating patients with periodontally hopeless dentition. Their article discussed that mobility of the remaining dentition could lead to the introduction of errors during the planning and implementation phases. To negate this, they recommended fabrication of a splint to hold the teeth in place during record making and treatment. Their guide also featured a 3D printed cobalt-chromium adaptation guide, base guide, and osteotomy guide. They listed the cost of this design as a disadvantage when compared to printed resin guides.¹⁵

Bonmati et al reported utilizing a stackable guided protocol for the management of a single arch mandibular rehabilitation. In their article they used a digital light processing 3D printer for manufacturing resin surgical guides similar to the ones used in the present study. Manfredini et al on the other hand utilized the stackable surgical guide

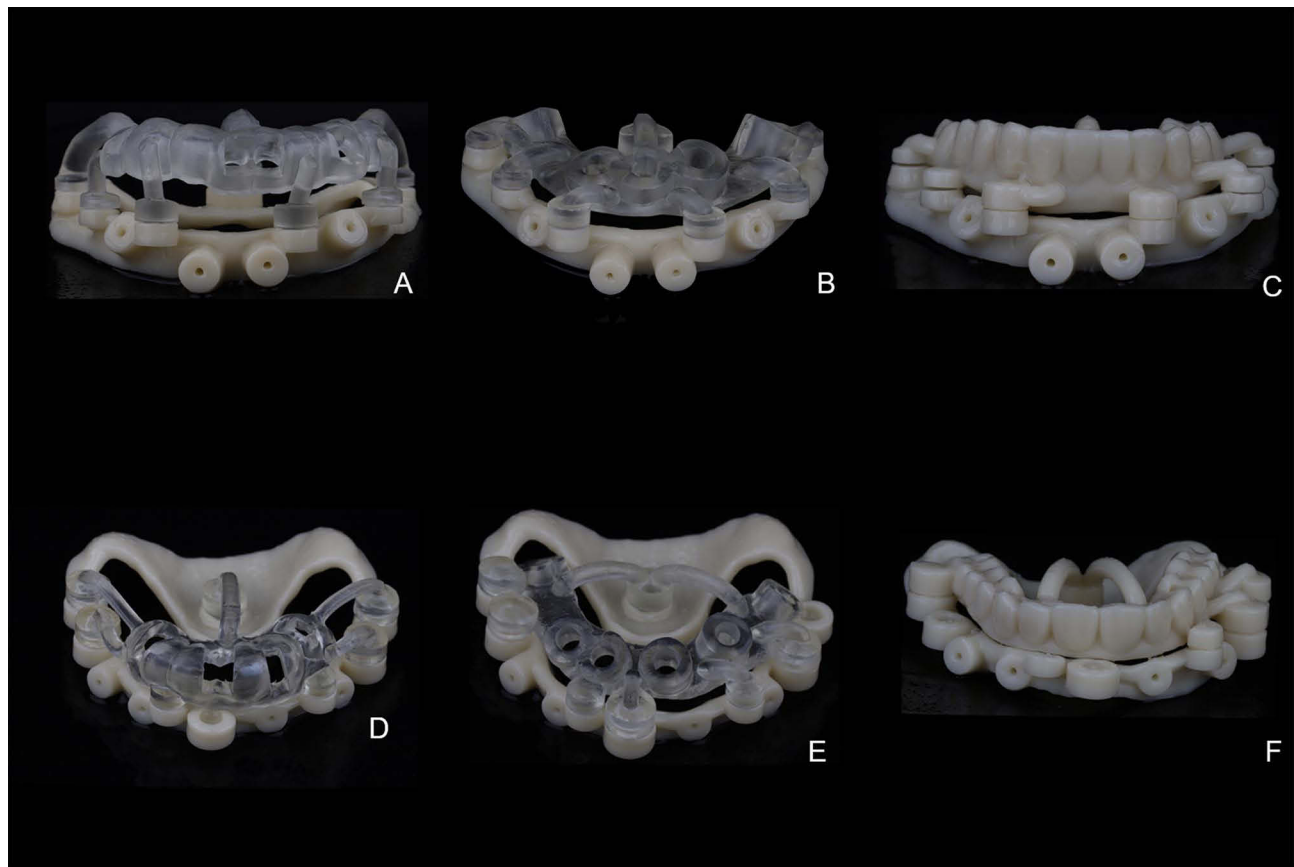


Figure 6 Assembling the different components of each surgical guide after 3D printing. **(A)** Mandibular adaptation guide and base guide. **(B)** Mandibular osteotomy guide and base guide. **(C)** Mandibular prosthetic loading guide and base guide. **(D)** Maxillary adaptation guide and base guide. **(E)** Maxillary osteotomy guide and base guide. **(F)** Maxillary prosthetic loading guide and base guide.

approach coupled with one-piece multi-unit integrated implants to rehabilitate a single edentulous maxillary arch. Their design incorporated milled titanium fixation and osteotomy guides, while the provisional restoration was milled from polymethyl methacrylate.¹⁷

In the current report, the stackable surgical guide concept was used for a dual arch rehabilitation. Physical models were obtained and mounted to capture and transfer the occlusion, as necessary. Before scanning the models, several indentations were made along the landing area of the casts to facilitate the transfer of the completed wax-up from one arch to the other without losing reference.

Angled implants were used in the maxillary and mandibular arches to achieve a favorable distribution and maximize anteroposterior spread while avoiding vital structures. Therefore, angle-correcting multiunit abutments were planned for the distal implants. Customized implant timing markers were incorporated into the osteotomy guide to coincide with the planned orientation of the multiunit abutments. To the authors' knowledge, the technique described for incorporating timing markers has not been utilized in previous studies on stackable guides.^{14–18} The anterior vertical implants were planned and placed without the need for angle correction; hence, multiunit abutments were omitted as this decreased the number of prosthetic components and overall cost of the treatment.

Before performing the procedure in the current report, all the steps were performed on articulated casts and 3D printed jaws. This technique allows for better visualization and practice for the clinicians involved, as well as completion of any required occlusal adjustments leading to reduced chair time on the operative day.

The limitations of the presented technique include the possible deviations that may be evident between the implant planning and placement due to the cumulative errors that may occur throughout the fabrication and treatment steps.

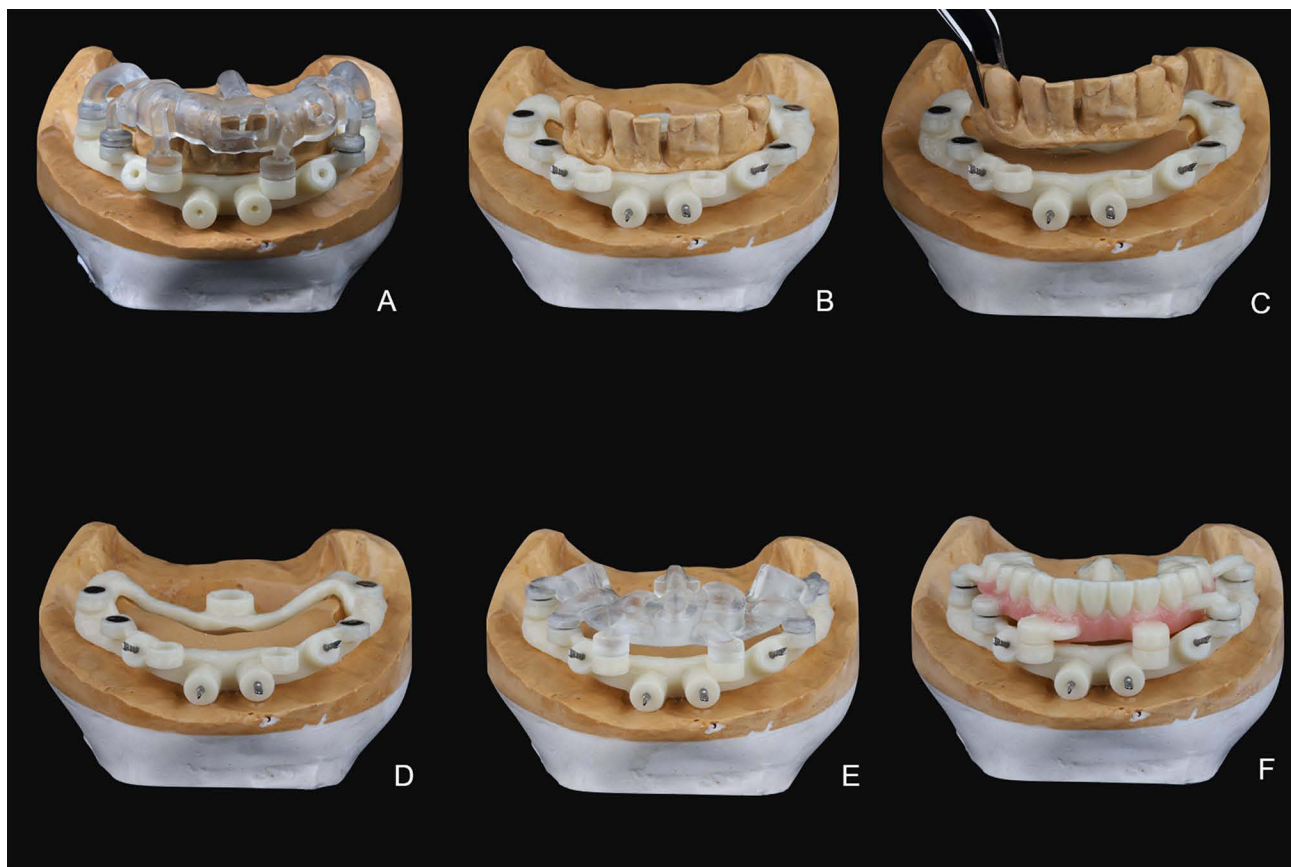


Figure 7 Model surgeries. (A) Adaptation guide used to orient the base guide. (B) Base guide seating and fixation with metallic posts. (C) Extractions and alveoloplasty simulation. (D) Confirmation of alveoloplasty level. (E) Osteotomy guide seating. (F) Prosthetic loading guide seating.

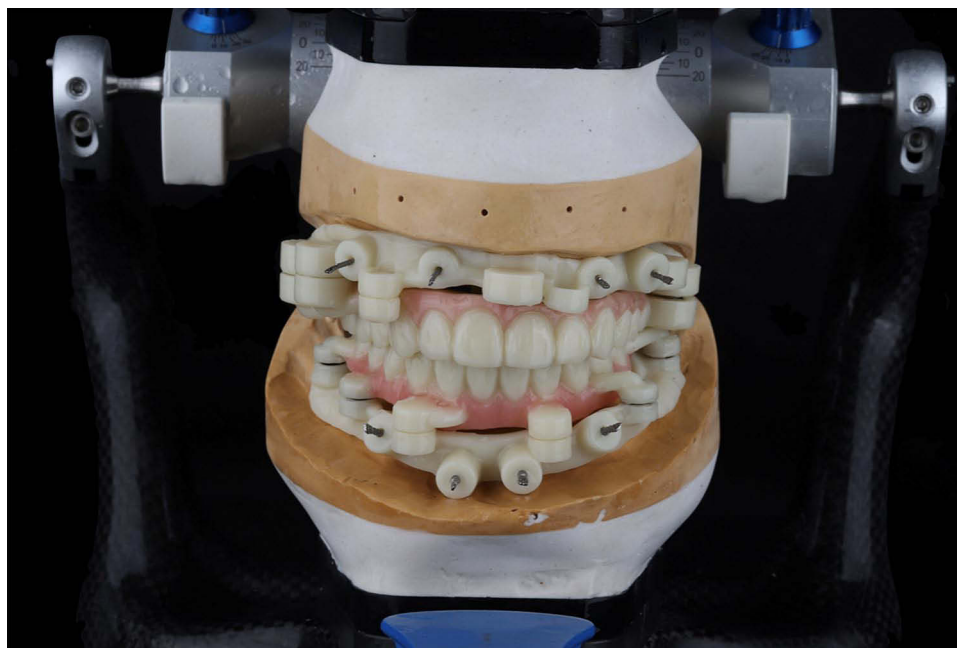


Figure 8 Occlusal equilibration completed on a semi-adjustable articulator (Artex CPR, Amman Girschbach, Germany).

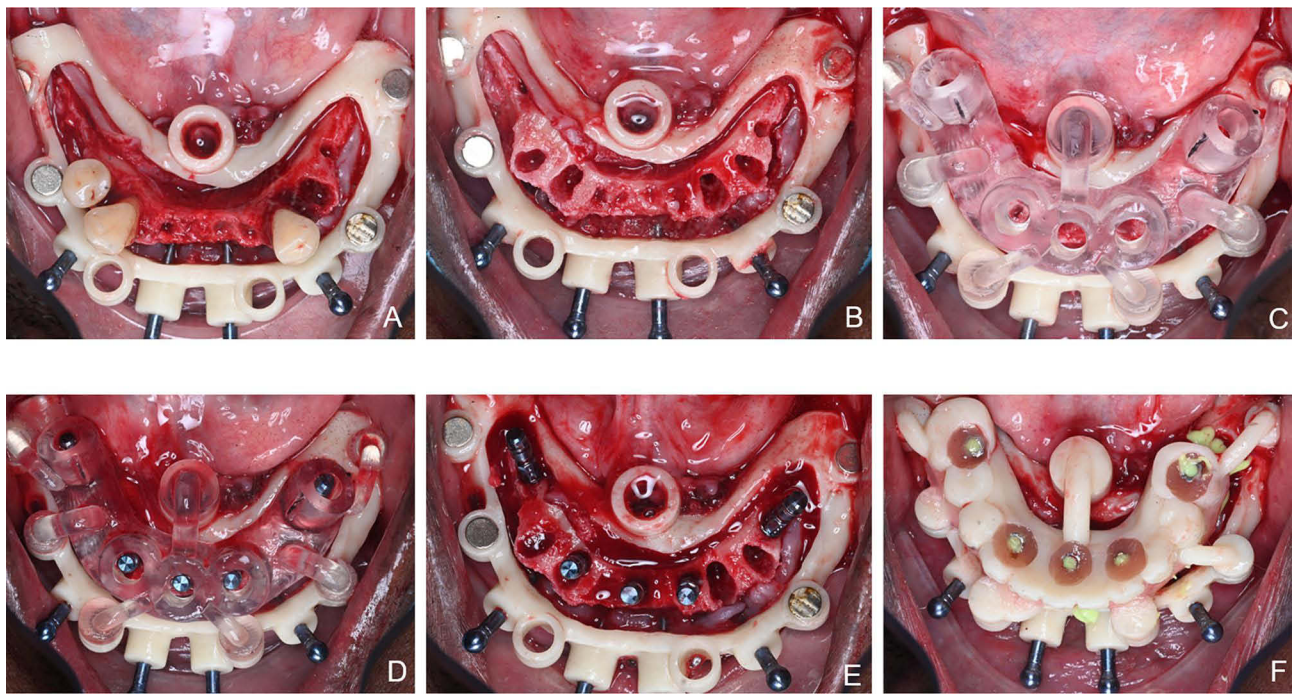


Figure 9 Mandibular surgery and loading protocol. (A) Base guide fixation. (B) Extractions and alveoplasty completed to the level of the base guide. (C) Osteotomy guide seating. (D) Implant placement through the osteotomy guide. (E) Final implant positions. (F) Pick-up procedure completed.

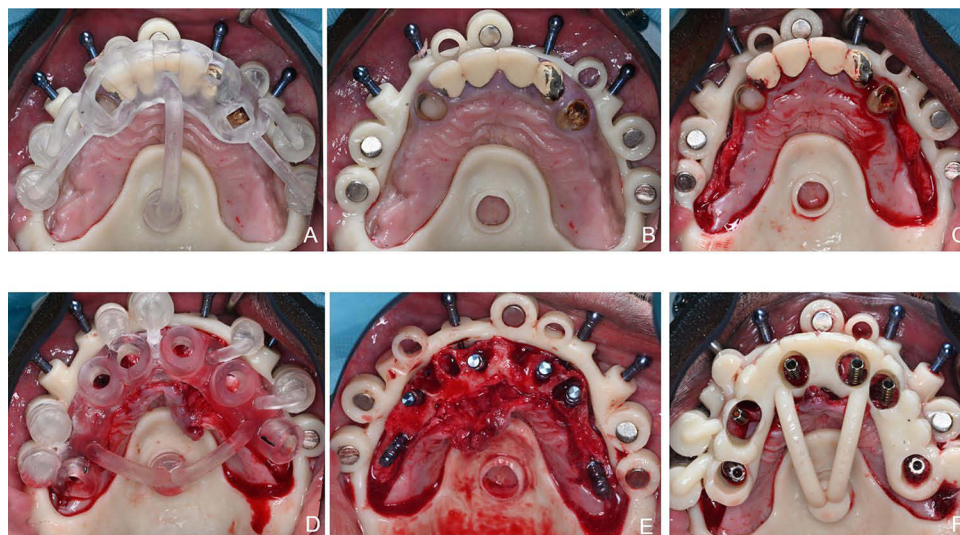


Figure 10 Maxillary surgery and loading protocol. (A) Base guide oriented into place using the adaptation guide. (B) Base guide fixation. (C) Mucoperiosteal flap elevation followed by re-orienting and fixating the base guide. (D) Osteotomy guide seating after completion of extractions and alveoplasty. (E) Final implant positions. (F) Preparation for pick-up procedure.

Another limitation is the necessary learning curve required to produce consistent outcomes when utilizing these protocols.

Conclusion

Overall, the presented treatment approach provided clinically acceptable outcomes, featuring simplified clinical procedures and reduced chair-times based on the authors' experience. Further studies are required to enhance knowledge of these techniques and their related clinical outcomes.

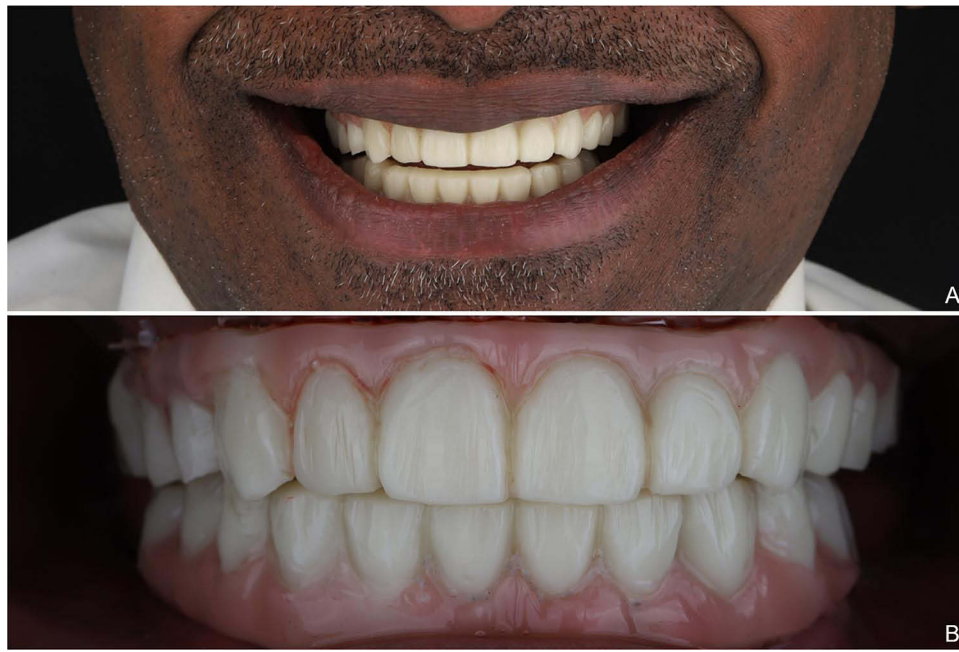

Figure 11 Post-operative records. (A) Close-up smile. (B) Retracted intra-oral MIP.

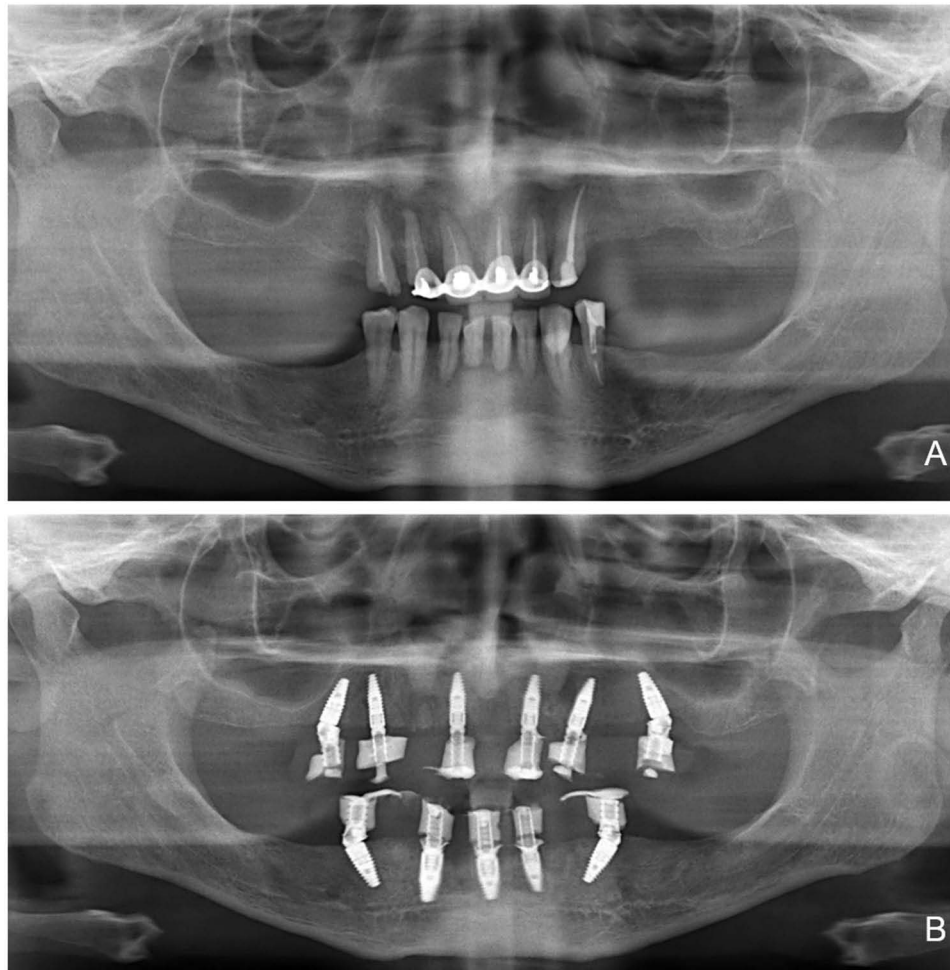


Figure 12 Radiographs. (A) Pre-operative panoramic radiograph. (B) Post-operative panoramic radiograph.

Consent Statement

Consent was obtained from the patient for the documentation and publication of this clinical report. The patient's approval was obtained for the use of all the records presented in this manuscript. Due to the nature of this single patient retrospective case report, IRB approval was not needed.

Disclosure

The authors report no conflicts of interest in this work.

References

1. Del Fabbro M, Testori T, Kekovic V, et al. A systematic review of survival rates of osseointegrated implants in fully and partially edentulous patients following immediate loading. *J Clin Med*. 2019;8(12):2142. doi:10.3390/jcm8122142
2. Drago C. Frequency and type of prosthetic complications associated with interim, immediately loaded full-arch prostheses: a 2-year retrospective chart review. *J Prosthodont*. 2016;25(6):433–439. doi:10.1111/jopr.12343
3. Morton D, Wismeijer D, Chen S, et al. Group 5 ITI consensus report: implant placement and loading protocols. *Clin Oral Implants Res*. 2023;34(S26):349–356. doi:10.1111/clr.14137
4. Gallucci GO, Hamilton A, Zhou W, et al. Implant placement and loading protocols in partially edentulous patients: a systematic review. *Clin Oral Implants Res*. 2018;29(S16):106–134. doi:10.1111/clr.13276
5. Maló P, Rangert B, Nobre M. “All-on-Four” immediate-function concept with Brånemark System® implants for completely edentulous mandibles: a retrospective clinical study. *Clin Implant Dent Relat Res*. 2003;5(s1):2–9. doi:10.1111/j.1708-8208.2003.tb00010.x
6. Velasco-Ortega E, Cracel-Lopes JL, Matos-Garrido N, et al. Immediate functional loading with full-arch fixed implant-retained rehabilitation in periodontal patients: clinical study. *Int J Environ Res Public Health*. 2022;19(20):13162. doi:10.3390/ijerph192013162
7. Papispyridakos P, Chen CJ, Chuang SK, et al. Implant loading protocols for edentulous patients with fixed prostheses: a systematic review and meta-analysis. *Int J Oral Maxillofac Implants*. 2014;2(Supplement):256–270. doi:10.11607/jomi.2014suppl.g4.3
8. Schrott A, Riggi-Heiniger M, Maruo K, et al. Implant loading protocols for partially edentulous patients with extended edentulous sites—a systematic review and meta-analysis. *Int J Oral Maxillofac Implants*. 2014;29(Supplement):239–255. doi:10.11607/jomi.2014suppl.g4.2
9. Weber HP, Morton D, Gallucci GO, et al. Consensus statements and recommended clinical procedures regarding loading protocols. *Int J Oral Maxillofac Implants*. 2009;24:180–183.
10. Daut Polido W, Aghaloo T, Emmett TW, Taylor TD, Morton D. Number of implants placed for complete-arch fixed prostheses: a systematic review and meta-analysis. *Clin Oral Implants Res*. 2018;29(S16):154–183. doi:10.1111/clr.13312
11. Hultin M, Svensson KG, Trulsson M. Clinical advantages of computer-guided implant placement: a systematic review. *Clin Oral Implants Res*. 2012;23(s6):124–135. doi:10.1111/j.1600-0501.2012.02545.x
12. Raico Gallardo YN, da Silva-Olivio IR, Mukai E, et al. Accuracy comparison of guided surgery for dental implants according to the tissue of support: a systematic review and meta-analysis. *Clin Oral Implants Res*. 2017;28(5):602–612. doi:10.1111/clr.12841
13. Van Assche N, Vercauteren M, Coucke W, et al. Accuracy of computer-aided implant placement. *Clin Oral Implants Res*. 2012;23(s6):112–123. doi:10.1111/j.1600-0501.2012.02552.x
14. Granata S, Sforza NM, Giberti L, et al. Computer-guided implant surgery for immediate implanting and loading: the STIL technique. *J Prosthodont*. 2021;126(2):155–163. doi:10.1016/j.prosdent.2020.05.006
15. Yang JW, Liu Q, Yue ZG, et al. Digital workflow for full-arch immediate implant placement using a stackable surgical guide fabricated using SLM technology. *J Prosthodont*. 2021;30(8):645–650. doi:10.1111/jopr.13375
16. Bonmati FG, Pérez-Barquero JA, Ripoll LM, et al. An additively manufactured, magnetically retained, and stackable implant surgical guide: a dental technique. *J Prosthodont*. 2023;130(4):444–452. doi:10.1016/j.prosdent.2021.09.037
17. Manfredini M, Poli PP, Maiorana C, et al. Computer aided full arch restoration by means of one-piece implants and stackable guide: a technical note. *Dent J*. 2023;11(11):256. doi:10.3390/dj11110256
18. Hameed HA, Hebeshi A. Comparative assessment of the positional accuracy of dental implants inserted using computerised stackable surgical guides made using selective laser melting and digital light processing technologies for patients with maxillary terminal dentition. *Int J Oral Implantol*. 2023;16:135–144.
19. Abdelaziz MS. Digital design and manufacture of a stackable implant surgical guide for immediate loading in completely edentulous full-arch cases: a dental technique. *Quintessence Int*. 2023;54(9):750–755. doi:10.3290/j.qi.b4325369

Clinical, Cosmetic and Investigational Dentistry

Dovepress

Publish your work in this journal

Clinical, Cosmetic and Investigational Dentistry is an international, peer-reviewed, open access, online journal focusing on the latest clinical and experimental research in dentistry with specific emphasis on cosmetic interventions. Innovative developments in dental materials, techniques and devices that improve outcomes and patient satisfaction and preference will be highlighted. The manuscript management system is completely online and includes a very quick and fair peer-review system, which is all easy to use. Visit <http://www.dovepress.com/testimonials.php> to read real quotes from published authors.

Submit your manuscript here: <https://www.dovepress.com/clinical-cosmetic-and-investigational-dentistry-journal>